

Spontaneous Ectopic Tubal Pregnancy After Partial Salpingectomy

Huali Fei¹, Yixuan Yin², Xiaoyan Guo³, Xuejing Jin¹

¹Department of Reproductive Endocrinology, Hangzhou Women's Hospital, Hangzhou, People's Republic of China; ²Department of Prenatal Diagnosis Center, Hangzhou Women's Hospital, Hangzhou, People's Republic of China; ³Department of Gynecology, Hangzhou Women's Hospital, Hangzhou, People's Republic of China

Correspondence: Yixuan Yin, Department of Prenatal Diagnosis Center, Hangzhou Women's Hospital, Hangzhou, People's Republic of China, Email yinyixuan83@hotmail.com

Objective: To report a rare case of spontaneous ectopic pregnancy (EP) after partial salpingectomy treated by laparoscopy.

Case Report: A 30-year-old gravida 1 para 0 woman with a history of left adnexectomy, due to left ovarian torsion 13 years ago, was referred to our hospital. She had experienced lower abdominal pain for 1 day and amenorrhea for 1 week. Transvaginal ultrasonography did not reveal an intrauterine pregnancy, but showed a suspected extrauterine gestational sac on the left adnexal area. The patient was diagnosed with ectopic pregnancy, and laparoscopy was performed. During the operation, we found a gestational sac on the left fallopian tube stump.

Conclusion: The most significant risk factors for ectopic pregnancy (EP) are previous procedures and conditions that cause tubal injury. Therefore, it is necessary to be alert to the occurrence of the disease even if there is a history of tubal resection and ensure no part of the fallopian tube is left behind during removal.

Keywords: proximal tubal pregnancy, ectopic pregnancy, partial salpingectomy

Introduction

Ectopic pregnancy happens approximately 1.5–2.0% among all pregnancies, but accounts for 5–10% of all pregnancy-related deaths.^{1,2} Ninety-five percent of ectopic pregnancies occur in the fallopian tube, and approximately 2.5% of cases occur in the interstitial position.^{3,4} Approximately 10% of patients with ectopic pregnancies will experience a recurrent ectopic pregnancy.⁵ Tubal stump pregnancy is rare, Ko et al reported that tubal stump pregnancy after tubectomy with a prevalence of about 0.4%.⁴ Previous literature reports that tubal stump pregnancies are predominantly interstitial tubal pregnancies, often due to the patient having had an ectopic pregnancy and a subsequent salpingectomy.^{6,7} Some tubal stump pregnancies occur secondary to post-tubal ligation.^{3,8} We report a case of spontaneous tubal stump pregnancy after partial salpingectomy due to torsion of the left ovarian cyst pedicle.

Case Report

A 30-year-old gravida 1 para 0 woman with a history of left adnexectomy due to left ovarian torsion 13 years ago was referred to our hospital. She had experienced lower abdominal pain for 1 day and amenorrhea for 1 week. Her serum human chorionic gonadotropin (HCG) level was 2278 IU/L and a pelvic transvaginal ultrasound (TVUS) showed a heterogeneous echo (0.9 cm × 0.8 cm × 0.7 cm) near the left ovary (Figures 1 and 2). CDFI (Color Doppler Flow Imaging) indicates blood flow signal in ectopic pregnancy mass (Figure 3). The clinical examination revealed abdominal pain with stable vital signs. The patient was suspected to have a left interstitial tubal pregnancy; thus, emergency laparoscopy was performed. At laparoscopy, there was no free blood in the pelvic cavity, and on the left salpingeal stump, an ectopic pregnancy was noted (Figure 4). The uterus was of normal size, its surface was smooth, and no abnormalities were seen in the bilateral ovary morphologies. No obvious abnormalities were found in the right fallopian tube (Figure 5). The left salpingeal stump tube was removed, and villous tissue was found in it (Figure 6). The pelvic

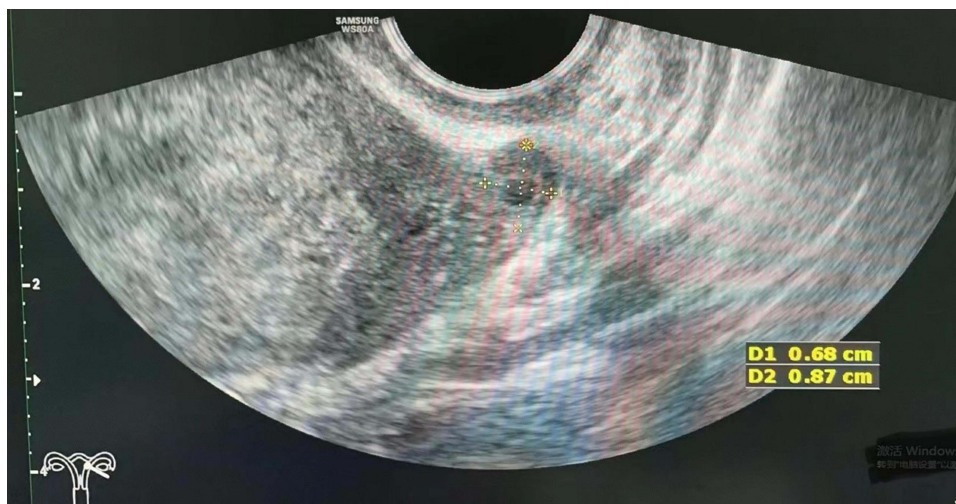


Figure 1 The ultrasound imaging demonstrates a mass at the residual segment of the left fallopian tube (isthmus) consistent with an ectopic pregnancy.

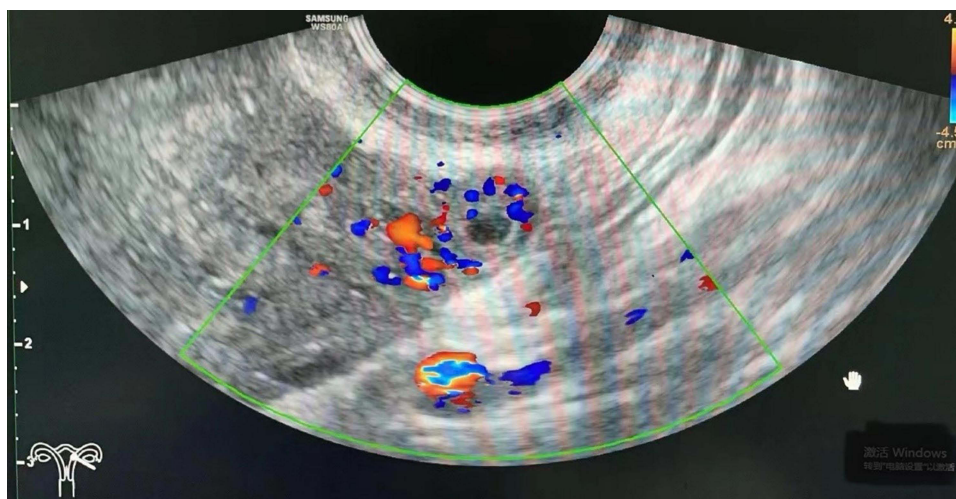


Figure 2 The size of the ectopic pregnancy mass in the left tubal remnant.

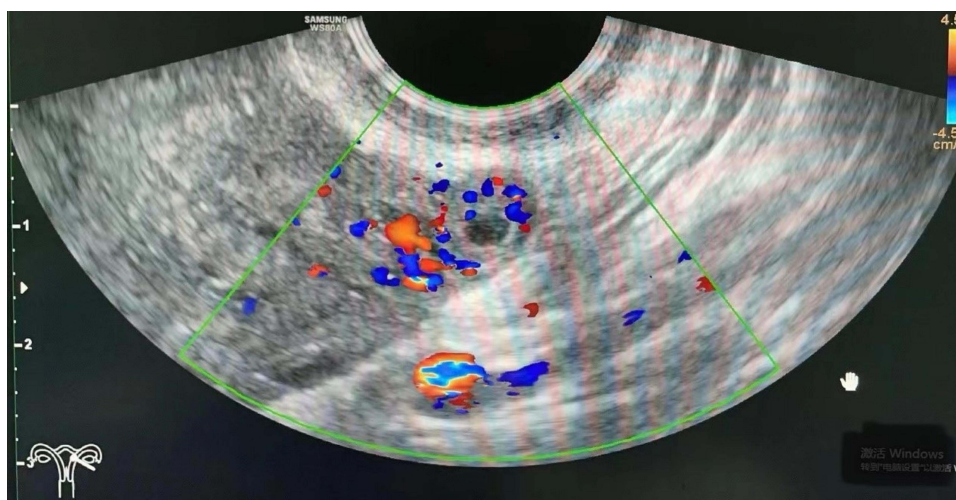


Figure 3 The blood flow pattern of the ectopic pregnancy mass.

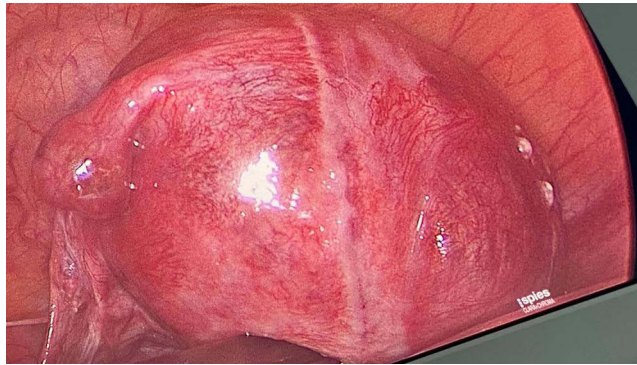


Figure 4 The pregnancy in the left tubal remnant was observed during laparoscopy.

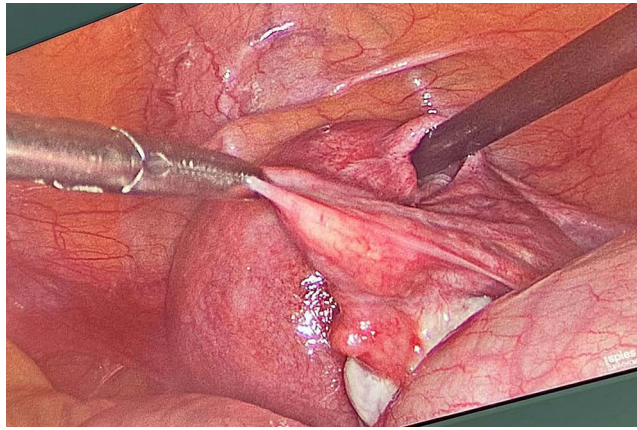


Figure 5 The right fallopian tube exhibits a normal appearance.

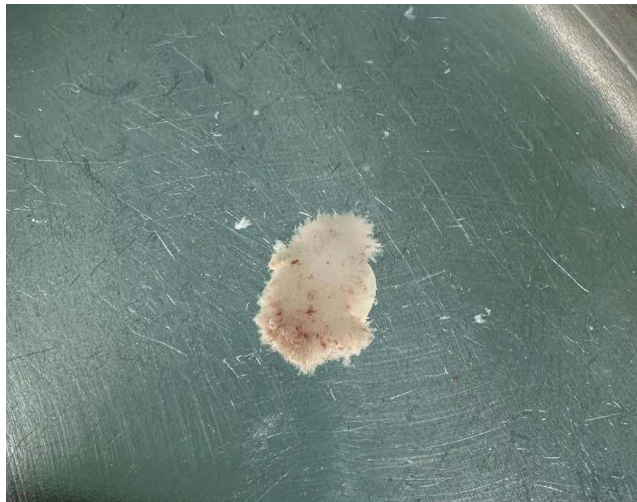

Figure 6 The villous tissue was present within the pregnancy sac of the left tubal remnant.

cavity was washed with saline solution, and the operation was ended. On the first day following the surgery, the patient's HCG levels decreased to 662.1 IU/L. The blood HCG levels continued to decline, and the patient's recovery proceeded without complications. The patient was discharged on the third postoperative day and received follow-up care in an outpatient setting. Histological analysis indicated the presence of trophoblastic tissues, confirming the diagnosis of an ectopic pregnancy (Figure 7).

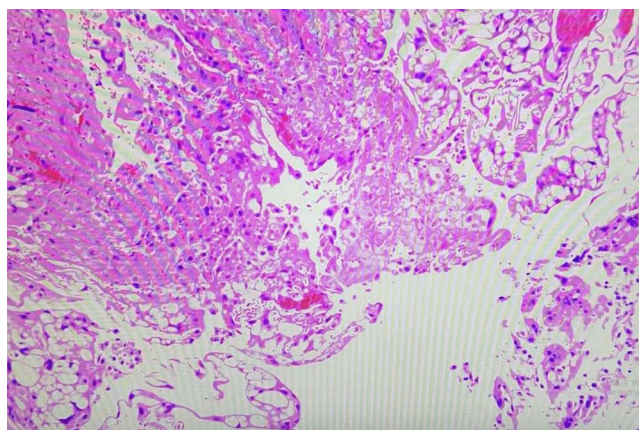


Figure 7 The pathological specimen confirmed chorionic villi (CV) within the ectopic pregnancy mass (haematoxylin and eosin stain, 200×magnification).

Discussion

Ectopic pregnancy (EP) poses a significant threat to the lives of women of childbearing age. In recent years, the incidence of EP has shown an increasing trend, attributed to factors such as delayed childbearing and the use of in vitro fertilization (IVF)-assisted fertility treatments. Notably, half of the patients diagnosed with ectopic pregnancy present with no known risk factors.⁹ Previous surgery on the fallopian tubes or damage to the fallopian tubes constitutes risk factors for ectopic pregnancy (EP).¹⁰ The rates of recurrent ectopic pregnancy following salpingectomy and salpingostomy are reported to be 5% and 8%, respectively.¹¹ Ectopic pregnancy can manifest in either the proximal or distal remnants of the operated fallopian tube. Drakopoulos P reported the inaugural case of an ectopic pregnancy occurring in the distal remnant following a laparoscopic partial segmental isthmic salpingectomy.¹² Subsequently, Lin CM and Xue Ke documented a rare instance of a left ampullary ectopic pregnancy subsequent to the ligation of the left fallopian tube.^{3,8} Both of these ectopic pregnancies occurred after resection of the ipsilateral proximal fallopian tube. In this case, distinct from the cases described in the literature above, the patient had previously undergone a left adnexectomy due to torsion of the pedicle of a left ovarian cyst, left part of the proximal fallopian tube tissue. Under the condition of an unobstructed contralateral fallopian tube, an ectopic pregnancy (EP) occurred in the stump of the fallopian tube previously partially removed, which is extremely rare. Notably, this was her first natural conception. In the existing literature, only one case resembling our description has been documented. However, that case was situated nearer to the interstitial segment of the fallopian tube and was characterized as a recurrent ectopic pregnancy within the fallopian tube.¹³ This phenomenon can be explained by two theories.¹⁴ The first theory suggests that a fertilized ovum could migrate from the intact right fallopian tube, across the endometrial cavity, to the proximal stump of the salpinx on the opposite side, a process known as internal migration of the fertilized ovum. The second theory posits that the ectopic pregnancy's anatomical location may result from the transperitoneal migration of an ovum from the contralateral ovary to the opposite salpinx via the pouch of Douglas, with the early embryo subsequently being captured by the left distal tubal stump. This is called the theory of external migration.^{13,14} It is certain that even the fallopian tube stump still retains physiological function. As such, recurrent ectopic pregnancy is more likely following partial salpingectomy than total salpingectomy. To prevent ectopic pregnancy, complete excision of the affected fallopian tube is recommended. Furthermore, some scholars¹⁵ believe that sufficient diathermy of proximal fallopian tube or its ligation might be used to reduce the risk of re-implantation.

Conclusion

The etiology of ectopic pregnancies following salpingectomies remains uncertain, and they are clinically significant due to their potential to be overlooked and associated high mortality rates. Clinicians should be cognizant of the fact that ectopic pregnancies can present atypically, and it is especially important to remember that a salpingectomy does not completely preclude the diagnosis of an ectopic pregnancy. Since the fallopian tube stump still retains physiological function, complete removal during surgery is necessary.

Abbreviations

EP, ectopic pregnancy; REP, repeated ectopic pregnancy; HCG, human chorionic gonadotropin; TVUS, transvaginal ultrasound; IVF, in vitro fertilization.

Ethical Approval

The study was approved by the ethics committee of Hangzhou Women's hospital (2023-A-181).

Declaration of Patient Consent

Written informed consent was obtained from the patient for publication of this case report and any accompanying images.

Acknowledgments

We would like to acknowledge our patient for consenting to the publication of this case report.

Author Contributions

All authors made a significant contribution to the work reported, whether that is in the conception, study design, execution, acquisition of data, analysis and interpretation, or in all these areas; took part in drafting, revising or critically reviewing the article; gave final approval of the version to be published; have agreed on the journal to which the article has been submitted; and agree to be accountable for all aspects of the work.

Disclosure

The authors declare that they have no conflicts of interest in this work.

References

1. Houser M, Kandalaf N, Khati NJ. Ectopic pregnancy: a resident's guide to imaging findings and diagnostic pitfalls. *Emerg Radiol.* 2022;29(1):161–172. doi:10.1007/s10140-021-01974-7
2. Jin XY, Li C, Xu W, Liu L, Wei ML. Factors associated with the incidence of ectopic pregnancy in women undergoing assisted reproductive treatment. *Chin Med J.* 2020;133(17):2054–2060. doi:10.1097/CM9.0000000000001058
3. Ke X, He L, Zheng J-F, Lin Y-H, Wang F. Rare occurrence of left ampullary ectopic pregnancy after ligation of the left fallopian tube: a case report. *Int J Women's Health.* 2023;4(15):965–970. doi:10.2147/IJWH.S417186
4. Ko PC, Liang CC, Lo TS, Huang HY. Six cases of tubal stump pregnancy: complication of assisted reproductive technology? *Fertil Steril.* 2011;95(7):2432. doi:10.1016/j.fertnstert.2011.03.069
5. Bouyer J, Coste J, Fernandez H, Pouly JL, Job-Spira N. Sites of ectopic pregnancy: a 10 year population-based study of 1800 cases. *Hum Reprod.* 2002;17(12):3224–3230. doi:10.1093/humrep/17.12.3224
6. Horwood G, Warshafsky C, Singh SS. A cautionary tale of the tubal stump. *J Minim Invasive Gynecol.* 2023;30(5):344–345. doi:10.1016/j.jmig.2023.01.009
7. Bernstein M, Han M. Laparoscopic management of short-interval interstitial pregnancy after recent tubal ectopic pregnancy: a case report. *Case Rep Women's Health.* 2024;41:e00585. doi:10.1016/j.crwh.2024.e00585
8. Lin CM, Ku YL, Cheng YT, Giin NY, Ou YC. An uncommon spontaneous right distal tubal pregnancy post bilateral laparoscopic sterilization: a case report. *Medicine.* 2019;98(4):e14193. doi:10.1097/MD.00000000000014193
9. Hendriks E, Rosenberg R, Prine L. Ectopic pregnancy: diagnosis and management—American Family Physician. *Am Fam Physician.* 2020;101(10):599–606.
10. Mullany K, Minneci M, Monjazeb R, Coiado OC. Overview of ectopic pregnancy diagnosis, management, and innovation. *Women's Health.* 2023;19:17455057231160349. doi:10.1177/17455057231160349
11. Mol F, van Mello NM, Strandell A, Strandell K, Jurkovic D. Salpingotomy versus salpingectomy in women with tubal pregnancy (ESEP study): an open-label, multicentre, randomized controlled trial. *Lancet.* 2014;383(9927):1483–1489. doi:10.1016/S0140-6736(14)60123-9
12. Drakopoulos P, Julen O, Petignat P, et al. Spontaneous ectopic tubal pregnancy after laparoscopic tubal sterilization by segmental isthmic partial salpingectomy. *BMJ Case Rep.* 2014;2014:bcr-2013-203131. doi:10.1136/bcr-2013-203131
13. Janbakhshov T, Dogan S, Dogan E. Laparoscopic treatment of recurrent ectopic pregnancy in the ipsilateral salpinx after ovulation induction and intrauterine insemination. *Taiwanese J Obstetrics Gynecol.* 2013;52(4):568–570. doi:10.1016/j.tjog.2013.10.020
14. Banzai C, Matsumoto A, Higeta D, et al. A case of cornual pregnancy after ipsilateral salpingectomy for isthmic pregnancy. *Gynecol Minim Invasive Ther.* 2023;12(1):48–50. doi:10.4103/gmit.gmit_11_22
15. Samiei-Sarir B, Diehm C. Recurrent ectopic pregnancy in the tubal remnant after salpingectomy. *Case Rep Obstet Gynecol.* 2013;2013:753269. doi:10.1155/2013/753269

International Journal of Women's Health

Dovepress

Publish your work in this journal

The International Journal of Women's Health is an international, peer-reviewed open-access journal publishing original research, reports, editorials, reviews and commentaries on all aspects of women's healthcare including gynecology, obstetrics, and breast cancer. The manuscript management system is completely online and includes a very quick and fair peer-review system, which is all easy to use. Visit <http://www.dovepress.com/testimonials.php> to read real quotes from published authors.

Submit your manuscript here: <https://www.dovepress.com/international-journal-of-womens-health-journal>