


Itraconazole Oral Solution for Infantile Complicated Hemangioma with Double Lesions on the Skin and One Inside the Liver

Xian He^{1,2}, Xin Ran¹, Dan Liang², Hongxia Fan³, Yuping Ran¹ 

¹Department of Dermatovenereology, West China Hospital, Sichuan University, Chengdu, People's Republic of China; ²Department of Allergy, Chengdu First People's Hospital, Chengdu, People's Republic of China; ³Department of Ultrasonic, West China Hospital, Sichuan University, Chengdu, People's Republic of China

Correspondence: Yuping Ran, Tel +8618980601697, Email ranyuping@vip.sina.com

Abstract: An infantile hemangioma is a congenital benign tumor formed by the proliferation of vascular cells during the embryonic stage. It is more common in the skin but can also occur in the mucous membranes, liver, brain and muscle. Hepatic hemangioma appears to be a benign tumor; however, it may lead to poor outcomes because of severe complications, such as high-output cardiac failure. The main treatment of hepatic hemangioma in infants is oral drugs, such as propranolol and glucocorticoids, but the clinical response is not always satisfactory. We describe a rare case of a 2-month-old boy who presented with infantile cutaneous and hepatic hemangiomas. By using dermoscopy and observations of the abdominal color Doppler ultrasound, after 9 months of oral treatment with itraconazole solution, the infantile cutaneous hemangioma complicated with hepatic hemangioma was eventually cured. There was no liver or kidney function damage during the whole treatment period. Itraconazole oral solution for the treatment of infantile cutaneous hemangioma complicated with hepatic hemangioma showed good efficacy, compliance, and safety in this case.

Keywords: infantile hemangioma, cutaneous, hepatic, itraconazole oral solution, dermoscopy, color ultrasonic

Introduction

Infantile hemangioma (IH) is a congenital benign tumor formed by the proliferation of vascular cells during embryonic stages, affecting 1% to 2.6% of newborns and up to 10% of children by the first one year of age.¹ It is more common in the skin but can occur in the mucous membranes, liver, brain, and muscle.¹ Infantile hepatic hemangioma (IHH) is a benign tumor that originates from endothelial cells and is usually slowly progressive during childhood. Although most infants are asymptomatic and often overlooked by the parents and doctors, 15% may develop high-output cardiac failure, resulting in considerable mortality.²⁻⁴ Current treatment methods for hepatic hemangioma include oral propranolol, systemic glucocorticosteroids, interferon, vincristine, cyclophosphamide, embolization, hepatic artery ligation, hepatectomy and liver transplantation.⁵⁻¹⁰ However, many treatments have low success rates and a high risk of side effects. Kassarian et al¹¹ reported that pharmacologic therapy fails in about one-third of patients, with an associated mortality rate of 11%. Oral propranolol is the first-line treatment for cutaneous hemangioma with hepatic complications, occasionally, its potential side effects, including drowsiness, bradycardia, low blood pressure, and hypoglycemia, are clinical concerns that needs attention.¹²

Itraconazole (ICZ), a key member of the triazole antifungal family, is widely used in clinical antifungal drugs and has recently been found to possess antiangiogenic and inhibition of mTOR pathway and hedgehog activity. Our team has previously reported cases in which ICZ was used in infants with hemangioma.^{13,14} Herein, we report a case of infantile cutaneous hemangioma complicated with hepatic hemangioma treated by oral ICZ solution. Dermoscopy and color ultrasound images play a vital role in the diagnosis and in the therapeutic efficacy monitoring.

Case Presentation

A full-term fraternal twin male infant presented at 1 week of age with irregular erythema on the left anterior chest and left upper abdomen. The lesions gradually bulged, enlarged, brightened, and developed progressively into elevated erythema plaques (Figure 1). The patient was treated with topical 0.5% timolol maleate eye drops for one month in other hospital before the current treatment, but it did not stop the IH from growing. Physical examination revealed two irregular erythematous plaques of approximately 3.0×1.8 cm in size on the left anterior chest and 2.6×1.4 cm in size on the left upper abdomen (Figure 1). Dermoscopy revealed an intensive vascular network (Figure 2). The multiple lesions prompt us screening for liver hemangioma.¹⁵ Indeed, abdominal ultrasound revealed an approximately $1.3 \times 0.9 \times 1.5$ cm hemangiomatoid solid mass in the patient's right liver (Figure 3), and the hemogram showed an abundant blood flow signal in the mass (Figure 4), the diagnosis was consistent with Infantile hepatic hemangioma (IHH). After fully communicating with the mother and informing her of the benefits and risks of itraconazole and propranolol, the mother gave her consent and chose to be treated with itraconazole. Then, the patient was administered ICZ oral solution (Sporanox, Janssen Pharmaceutica N.V., Belgium) at 5.0 mg/kg/day. After 6 months of treatment, the skin lesion became flat and was significantly reduced in size (Figure 5); dermoscopic features showed a distinct vascular network and fewer capillary branches (Figure 6). Two repeat ultrasounds of the patient's abdomen (4 and 7 months after starting the ICZ oral solution) revealed a progressive decrease in the size of the IHH, and the internal blood flow signal disappeared (Figures 7-9); therefore, the treatment was terminated at 9 months. The total dosage of oral solution is 10,500 mg ICZ. A follow-up 2 months later showed that the lesions had almost disappeared, with only residual skin erythema remaining (Figures 10 and 11), and ultrasounds showed that the IHH had completely disappeared (Figure 12). During the whole course of treatment, the child occasionally had mild diarrhea which spontaneous remission without stop of ICZ, his liver function and blood routine examination are within the normal range, without any other problems. Until the age of 40 months, no recurrence of hemangioma was observed.

Discussion

IH is the most common benign soft tissue tumor in children, and it is usually formed within one week after birth. These lesions usually grow rapidly after birth and gradually degenerate in childhood. The first 3–6 months is known as the proliferating phase, but growth may also last for one year or even longer.^{16–18} Although IH usually presents as isolated skin lesions, multiple IH lesions are not uncommon and may involve extracutaneous organs, most commonly, the liver.¹

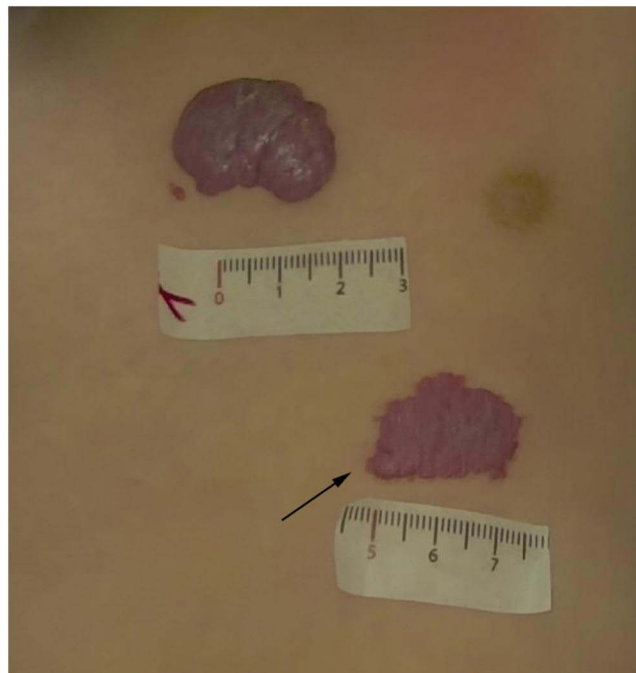


Figure 1 Two irregular erythematous plaques hemangioma on the left anterior chest and on the left upper abdomen. The black arrow indicates the observation area for the dermoscope.

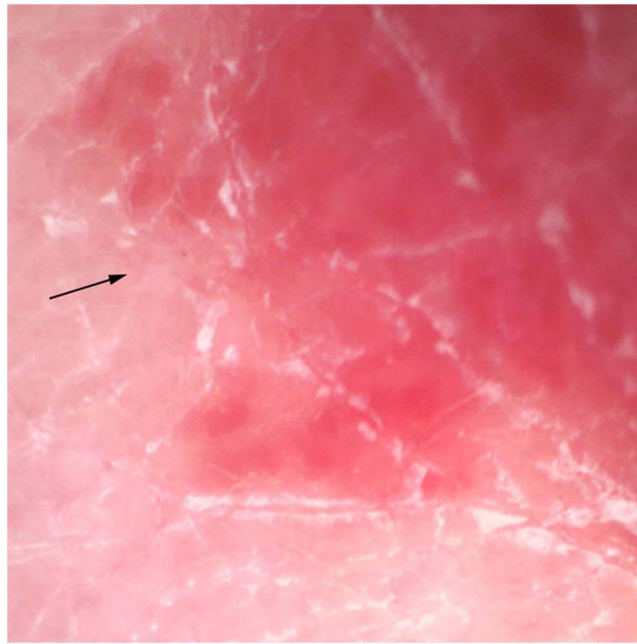


Figure 2 Dermoscopy (amplification $\times 33$) revealed an intensive vascular network. The black arrow indicates the same landmark for comparative dermoscopic observations.

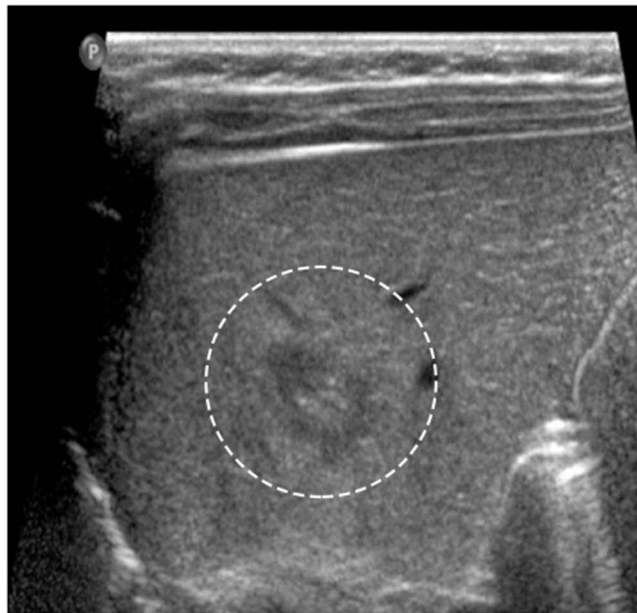

Figure 3 A two-dimensional grayscale diagram before treatment revealed an approximately $1.3 \times 0.9 \times 1.5$ cm hemangiomatoid solid mass in the patient's right liver. The white circle indicates the location of the hepatic hemangioma.

IHH is the most common hepatic tumor in neonates,¹⁹ and it occurs in early infancy, as no clinical symptom it is always overlooked, and most tumors spontaneously resolving, similar to IH. In addition, some IHH lesions express the same glucose transporter (GLUT)-1, a glucose transport protein normally present in erythrocytes and endothelial blood-tissue barriers as IH,^{20,21} which suggests that cutaneous and liver hemangiomas may originate from the same source. According to the imaging features, IHH can be classified into three categories: focal, multifocal, and diffuse.²² Clinical manifestations may include abdominal distention, abdominal mass, or a large liver, and there is occasional discovery without any clinical symptoms. Although focal IHH is a morphologically isolated and rapidly regressing hemangioma,

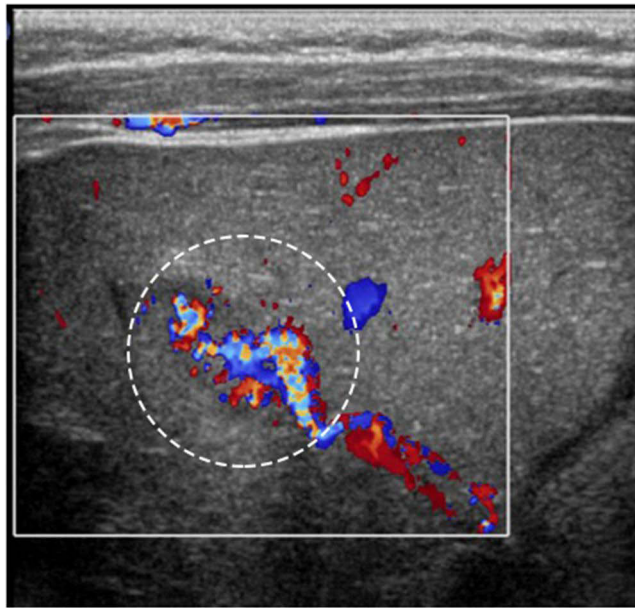


Figure 4 The hemogram showed an abundant blood flow signal in the mass before treatment. The white circle indicates the location of the hepatic hemangioma.

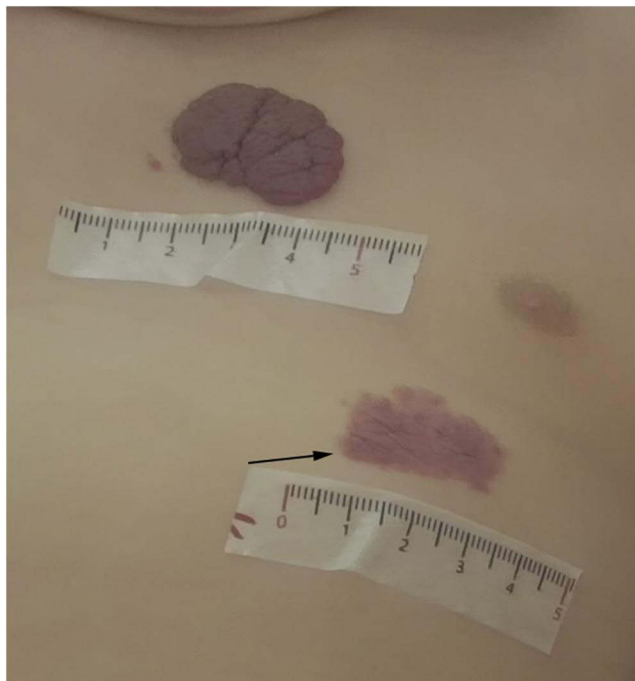


Figure 5 After 3 months of treatment, the two-hemangioma lesion became flat. The black arrow indicates the observation area for the dermoscope.

jaundice, hepatomegaly, cardiac insufficiency and thyroid dysfunction are not uncommon conditions developed from this tumor type. In addition, multifocal and diffuse types are more harmful to infants. Among 91 IHH cases reported by Selby et al, 11% were complicated with cutaneous hemangioma, and 15% were complicated with congestive heart failure.²³ Thus, hepatic hemangioma, although histologically benign, may be associated with significant morbidity and mortality in affected infants and thus requires clinical intervention.²⁴

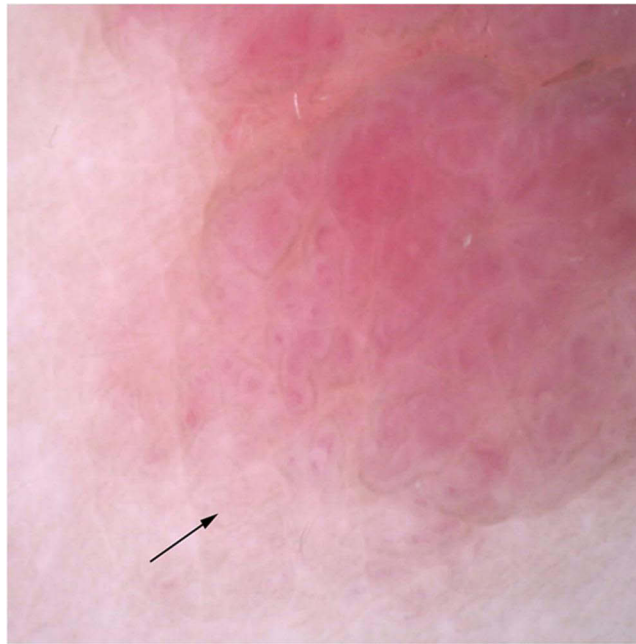


Figure 6 After 3 months of treatment, the intensive vascular network gradually disappeared. The black arrow indicates the same landmark for comparative dermoscopic observations.

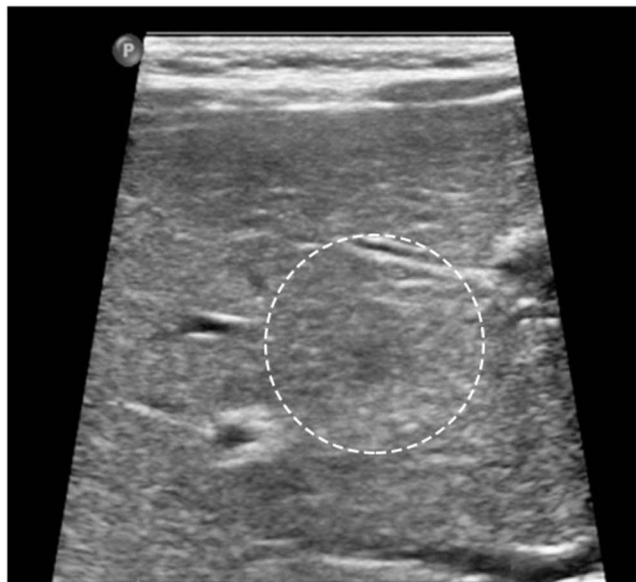


Figure 7 After 4 months of treatment, the solid mass in the right liver shrank to approximately 0.9×0.9 cm. The white circle indicates the location of the hepatic hemangioma.

Oral propranolol is considered a first-line treatment for cutaneous hemangioma complicated with hepatic hemangioma. However, recent studies have found that multifocal and diffuse lesions are sensitive to propranolol with a good effect, but the efficacy of local lesions is still not clear.^{25,26} In addition, there are still potential side effects to consider, which can manifest variably as lethargy, restlessness, cool skin, and decreased appetite.¹² ICZ is a key member of the triazole antifungal family, which has been widely used for more than 40 years,²⁷ the efficacy and safety in infants were approved.²⁸ It has been reported to inhibit angiogenesis.^{29,30} In 2015, our team found that ICZ had a positive effect on the treatment of IH, which was further confirmed in later treatment practice.^{13,14} Research also demonstrated that oral itraconazole can be an equivalent option for oral propranolol while safer and shorter treatment periods.³¹ We found that

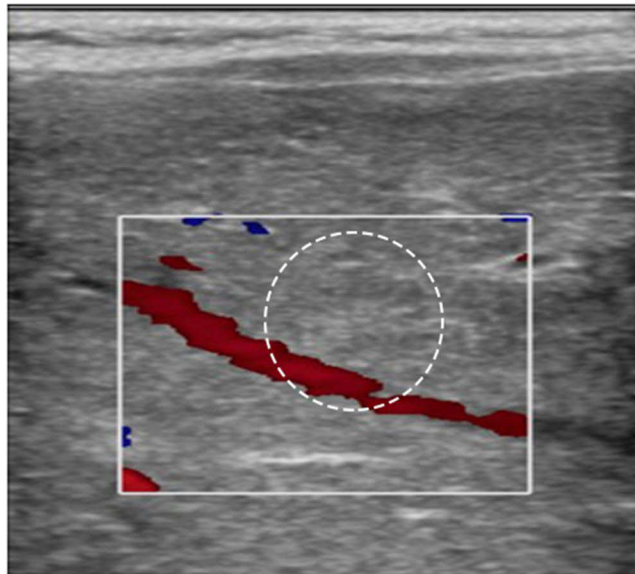


Figure 8 The internal blood flow signal disappeared after 4 months of treatment. The white circle indicates the location of the hepatic hemangioma.

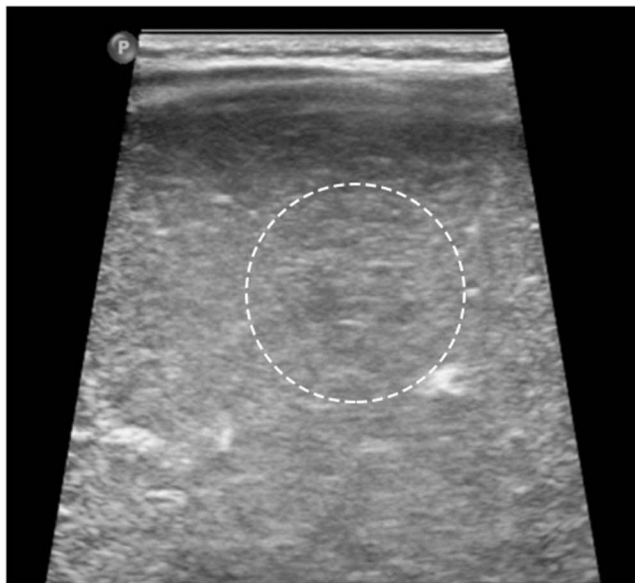

Figure 9 By the seventh month of treatment, the mass had shrunk to a 0.5 cm echogenic area. The white circle indicates the location of the hepatic hemangioma.

ICZ can induce IH regression by downregulating the platelet-derived growth factor-D/PI3K/Akt/mTOR pathway.³² Certainly, research on the use of itraconazole in the treatment of hemangioma is limited at present. Further studies are necessary to comprehensively determine its safety and efficacy, especially in comparison with propranolol.

In this case, IH showed significant improvement after 3 months of ICZ treatment; the abdominal ultrasound revealed a significant reduction in the volume of IHH 4 months later and showed that it had disappeared after nearly 9 months of treatment. During the whole treatment, hepatic and renal function remained normal, with only mild diarrhea. Timolol maleate eye drops were topically applied for 1 month before the current treatment, but it did not stop IH from growing, which suggests that the infant was in the proliferative period during treatment with ICZ and was unlikely to undergo spontaneous resolution alone. Liver function can be conveniently monitored before and after ICZ treatment, and the cherry flavor of the oral liquid preparation is conducive to infant acceptance. The infant in this case had no recurrence of

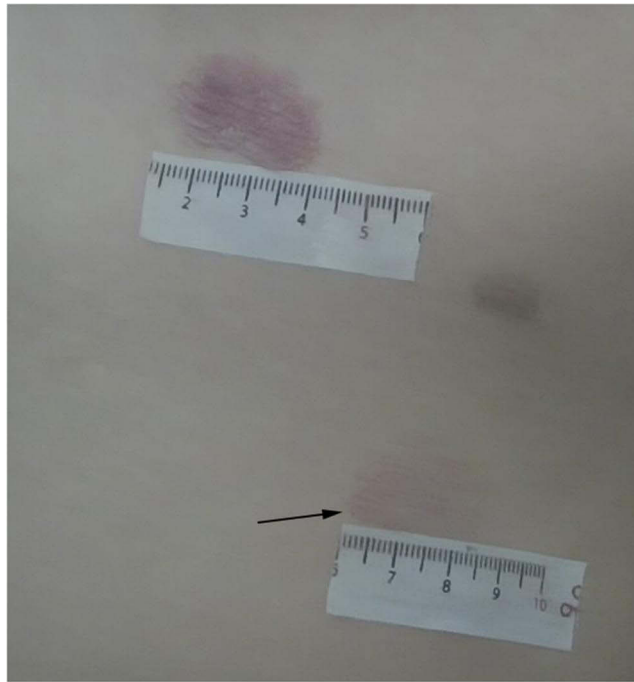


Figure 10 2 months after termination of treatment, the lesions had almost disappeared, with only residual skin erythema remaining. The black arrow indicates the observation area for the dermoscope.

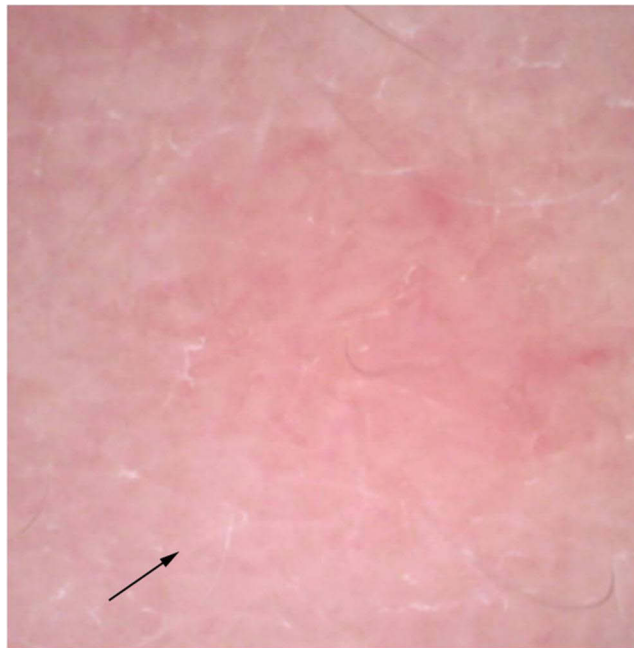


Figure 11 2 months after termination of treatment, the vascular network has almost completely disappeared. The black arrow indicates the same landmark for comparative dermoscopic observations.

skin or liver hemangioma during the nearly 6-month follow-up period. However, since this is the first case using ICZ oral solution for the treatment of infantile cutaneous hemangioma complicated with hepatic hemangioma, more clinical trials are needed for confirmation. Our case indicates, at least, ICZ can be used as one of the complementary therapy for the treatment of IHH.

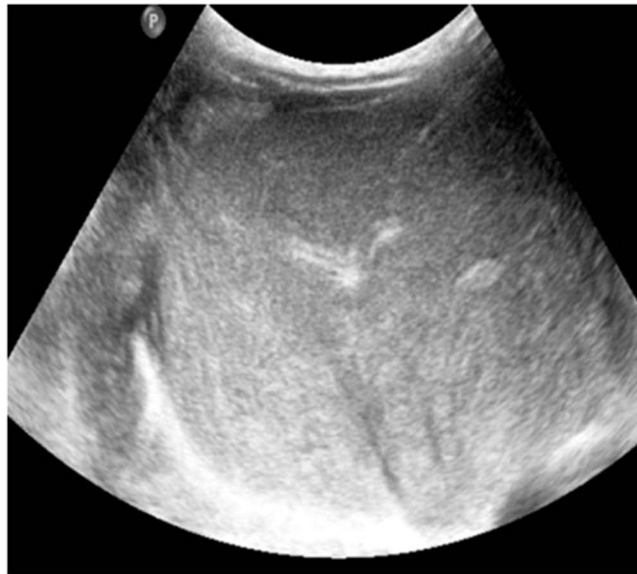


Figure 12 The last follow-up showed no significant liver abnormalities.

As a noninvasive testing tool in dermatology, dermoscopy can be used to observe the changes in skin lesions more clearly by adjusting the magnification ratio. Moreover, apply color Doppler ultrasound to screen out IHH inside liver, and, dynamically monitor the imaging changes during treatment, is very important, especially in the baby with multiple cutaneous hemangioma.^{15,33}

Conclusion

ICZ oral solution for the treatment of infantile cutaneous hemangioma complicated with hepatic hemangioma shows good efficacy, safety, and enables good patient compliance in this case. Thus, it may be used as a complementary therapy for infantile cutaneous hemangioma and liver hemangiomas. Dermoscopy and the observation of abdominal color via ultrasound can be used as tools to monitor changes in disease progression before and after treatment of cutaneous and hepatic hemangiomas for effective treatment evaluation.

Ethics and Consent Statements

We confirm that written informed consent was obtained from the mother of the patient included in this case report for the publication of this manuscript and any accompanying images. No institutional approval was required to publish the case details.

Funding

This work was supported in part by the Sichuan Science and Technology Program (Grant 2020YFS0194), the National Natural Science Foundation of China (Grant 81472539), 1.3.5 project for disciplines of excellence, West China Hospital, Sichuan University, and HX-Academician project (HXYS19003), West China Hospital, Sichuan University.

Disclosure

The authors report no conflicts of interest in this work.

References

1. Metry DW, Hebert AA. Benign cutaneous vascular tumors of infancy. *Arch Dermatol.* 2000;136(7):905–914. doi:10.1001/archderm.136.7.905
2. Zhang XT, Ren WD, Song G, et al. Infantile hepatic hemangiomas associated with high-output cardiac failure and pulmonary hypertension. *BMC Cardiovasc Disord.* 2019;19(1):216. doi:10.1186/s12872-019-1200-6
3. Burke DR, Verstandig A, Edwards O, et al. Infantile hemangioendothelioma: angiographic features and factors determining efficacy of hepatic artery embolization. *Cardiovasc Intervent Radiol.* 1986;9(3):154–157. doi:10.1007/BF02577927

4. Samuel M, Spitz L. Infantile hepatic hemangioendothelioma: the role of surgery. *J Pediatr Surg.* 1995;30(10):1425–1429. doi:10.1016/0022-3468(95)90397-6
5. Wu W, Pradhan S, Ran X, et al. Multifocal infantile hemangiomas treated by oral itraconazole: a case report. *NJDVL.* 2022;20(1):44–46.
6. Cavalli R, Novotna V, Buffon RB, et al. Multiple cutaneous and hepatic infantile hemangiomas having a successful response to propranolol as monotherapy at neonatal period. *G Ital Dermatol Venereol.* 2013;148(5):525–530.
7. Vlahovic A, Simic R, Djokic D, et al. Diffuse neonatal hemangiomatosis treatment with cyclophosphamide: a case report. *J Pediatr Hematol Oncol.* 2009;31:858–860. doi:10.1097/MPH.0b013e3181b536ad
8. Markiewicz-Kijewska M, Kasprzyk W, Broniszczak D, et al. Hemodynamic failure as an indication to urgent liver transplantation in infants with giant hepatic hemangiomas or vascular malformations-report of four cases. *Pediatr Transplant.* 2009;13:906–912. doi:10.1111/j.1399-3046.2008.01050.x
9. Schiavetti A, De Pasquale MD, Di Salvo S, et al. Recombinant interferon alfa 2a in hepatic hemangiomatosis with congestive heart failure: a case report. *Pediatr Hematol Oncol.* 2003;20:161–165. doi:10.1080/0880010390158676
10. Stratte EG, Tope WD, Johnson CL, et al. Multimodal management of diffuse neonatal hemangiomatosis. *J Am Acad Dermatol.* 1996;2(Pt2):56.
11. Kassarian A, Zurakowski D, Dubois J, et al. Infantile Hepatic Hemangiomas: clinical and Imaging Findings and Their Correlation with Therapy. *Am J Roentgenol.* 2004;182(3):785–795. doi:10.2214/ajr.182.3.1820785
12. Lawley LP, Siegfried E, Todd Jane L. Propranolol treatment for hemangioma of infancy: risks and recommendations. *Pediatr Dermatol.* 2009;26(5):610–614. doi:10.1111/j.1525-1470.2009.00975.x
13. Ran Y, Chen S, Dai Y, et al. Successful treatment of oral itraconazole for infantile hemangiomas: a case series. *J Dermatol.* 2015;42(2):202–206. doi:10.1111/1346-8138.12724
14. Huang Y, Ran X, Xu X, et al. Itraconazole oral solution for a case of infantile hemangioma: monitoring the efficacy by dermoscopy and MRI. *Dermatol Ther.* 2021;11(5):1861–1866. doi:10.1007/s13555-021-00579-9
15. Ji Y, Chen S, Yang K, et al. Screening for infantile hepatic hemangioma in patients with cutaneous infantile hemangioma: a multicenter prospective study. *J Am Acad Dermatol.* 2021;84(5):1378–1384. doi:10.1016/j.jaad.2020.11.062
16. Zhu L, Xie J, Liu Z, et al. Pigment epithelium-derived factor/vascular endothelial growth factor ratio plays a crucial role in the spontaneous regression of infant hemangioma and in the therapeutic effect of propranolol. *Cancer Sci.* 2018;109(6):1981–1994. doi:10.1111/cas.13611
17. Chang LC, Haggstrom AN, Drolet BA, et al. Growth characteristics of infantile hemangiomas: implications for management. *Pediatrics.* 2008;122(2):360–367. doi:10.1542/peds.2007-2767
18. Bauland CG, Luning TH, Smit JM, et al. Untreated hemangiomas: growth pattern and residual lesions. *Plast Reconstr Surg.* 2011;127(4):1643–1648. doi:10.1097/PRS.0b013e318208d2ac
19. Isaacs H. Fetal and neonatal hepatic tumors. *J Pediatr Surg.* 2007;42(11):1797–1803. doi:10.1016/j.jpedsurg.2007.07.047
20. North PE, Waner M, Mizeracki A, et al. GLUT1: a newly discovered immunohistochemical marker for juvenile hemangiomas. *Hum Pathol.* 2000;31(1):11–22. doi:10.1016/S0046-8177(00)80192-6
21. Mo JQ, Dimashkieh HH, Bove KE. GLUT1 endothelial reactivity distinguishes hepatic infantile hemangioma from congenital hepatic vascular malformation with associated capillary proliferation. *Hum Pathol.* 2004;35(2):200–209. doi:10.1016/j.humpath.2003.09.017
22. Christison-Lagay ER, Burrows PE, Alomari A, et al. Hepatic hemangiomas: subtype classification and development of a clinical practice algorithm and registry. *J Pediatr Surg.* 2007;42(1):62–67. doi:10.1016/j.jpedsurg.2006.09.041
23. Selby DM, Stocker JT, Waclawiw MA, et al. Infantile hemangioendothelioma of the liver. *Hepatology.* 1994;20(1 Pt 1):39–45. doi:10.1016/0270-9139(94)90132-5
24. Boon LM, Burrows PE, Paltiel HJ, et al. Hepatic vascular anomalies in infancy: a twenty-seven-year experience. *J Pediatr.* 1996;129(3):346–354. doi:10.1016/S0022-3476(96)70065-3
25. Rialon KL, Murillo R, Fevurly RD, et al. Risk factors for mortality in patients with multifocal and diffuse hepatic hemangiomas. *J Pediatr Surg.* 2015;50(5):837–841. doi:10.1016/j.jpedsurg.2014.09.056
26. Mazereeuw-Hautier J, Hoeger PH, Benlahrech S, et al. Efficacy of propranolol in hepatic infantile hemangiomas with diffuse neonatal hemangiomatosis. *J Pediatr.* 2010;157(2):340–342. doi:10.1016/j.jpeds.2010.04.003
27. Grant SM, Clissold SP. Itraconazole: a review of its pharmacodynamic and pharmacokinetic properties, and therapeutic use in superficial and systemic mycoses. *Drugs.* 1989;37(3):310–344. doi:10.2165/00003495-198937030-00003
28. Chen S, Sun KY, Feng XW, et al. Efficacy and safety of itraconazole use in infants. *World J Pediatr.* 2016;12(4):399–407. doi:10.1007/s12519-016-0034-x
29. Del Carratore R, Carpi A, Beffy P, et al. Itraconazole inhibits HMEC-1 angiogenesis. *Biomed Pharmacother.* 2012;66(4):312–317. doi:10.1016/j.biopha.2011.11.004
30. Nacev B, Grassi P, Dell A, et al. The antifungal drug itraconazole inhibits vascular endothelial growth factor receptor 2 (VEGFR2) glycosylation, trafficking, and signaling in endothelial cells. *J Biol Chem.* 2011;286(51):44045–44056. doi:10.1074/jbc.M111.278754
31. Bessar H, Kandil AH, Nasr NM, et al. Itraconazole versus propranolol: therapeutic and pharmacologic effect on serum angiopoietin-2 in patients with infantile hemangioma. *J Dermatol Treat.* 2022;33(1):105–110. doi:10.1080/09546634.2019.1687822
32. Chen S, Zhuang K, Sun K, et al. Itraconazole induces regression of infantile hemangioma via downregulation of the platelet derived growth factor-D/PI3K/Akt/mTOR pathway. *J Invest Dermatol.* 2019;139(7):1574–1582. doi:10.1016/j.jid.2018.12.028
33. Mhanna A, Franklin WH, Mancini AJ. Hepatic infantile hemangiomas treated with oral propranolol-a case series. *Pediatr Dermatol.* 2011;28(1):39–45. doi:10.1111/j.1525-1470.2010.01355.x

Clinical, Cosmetic and Investigational Dermatology

Dovepress

Publish your work in this journal

Clinical, Cosmetic and Investigational Dermatology is an international, peer-reviewed, open access, online journal that focuses on the latest clinical and experimental research in all aspects of skin disease and cosmetic interventions. This journal is indexed on CAS. The manuscript management system is completely online and includes a very quick and fair peer-review system, which is all easy to use. Visit <http://www.dovepress.com/testimonials.php> to read real quotes from published authors.

Submit your manuscript here: <https://www.dovepress.com/clinical-cosmetic-and-investigational-dermatology-journal>