

Ozonated Hydrotherapy Combined with LED Yellow Light Irradiation and Oral Minocycline Treatment for Mild to Moderate Papulopustular Rosacea: A Comparative Retrospective Study

Jingjing Wei¹, Chunhong Zhang¹, Yi Leng¹, Mingming Li¹, Lingyun Du¹, Zhiqiang Cao², Xia Zhu¹, Changyu Han¹, Liya Meng¹

¹Department of Dermato-Venereology, The Second Hospital of Shandong University, Jinan, Shandong, People's Republic of China; ²Department of Dermatology, The Second Affiliated Hospital, Xi'an Jiaotong University, Xi'an, Shaanxi, People's Republic of China

Correspondence: Liya Meng, Department of Dermato-venereology, The Second Hospital of Shandong University, 247 Beiyuan Dajie Street, Jinan, 250033, People's Republic of China, Tel +86-531-85875027, Fax +86-531-88962544, Email mly0706@sina.com

Objective and Design: The treatment of recurrent rosacea has always been a problem. Oral minocycline has been widely used in the treatment of rosacea. However, the efficacy and safety of ozonated hydrotherapy combined with LED yellow light irradiation and oral minocycline for mild to moderate papulopustular rosacea (PPR) has not been thoroughly studied.

Methods: Patients with rosacea who met the criteria and had complete clinical statistic admitted to our hospital from April 2021 to September 2022 were retrospectively collected and divided into combined therapy group and oral only group. The patients in the two groups were treated with minocycline for 8 weeks. In addition, the patients in combined therapy group were treated with ozone hydrotherapy once a week, followed by LED yellow light irradiation for a total of 4 weeks. The Investigator's global assessment (IGA) score was used to assess the condition. The efficacy was evaluated using the patients' subjective symptom scores. Skin lesion images and adverse reactions were recorded. The recurrence rate was observed after 24 weeks of follow-up.

Results: A total of 39 patients included in the study. After 4 weeks of treatment, the effective rate was 90% in combined therapy group and 52.63% in oral only group ($p < 0.05$). After 8 weeks of treatment, the total score of the patients' subjective symptom scores and the scores of itching and burning sensation in combined therapy group were lower than those in oral only group ($p < 0.05$). After 24 weeks of follow-up, the recurrence rate of combined therapy group was 5%, and that of oral only group was 26.32%. The mild adverse reactions experienced by both groups disappeared during follow-up.

Conclusion: This combination therapy has a significant, rapid and safe therapeutic effect, especially in relieving itching and burning sensations, and may reduce the recurrence rate.

Keywords: papulopustular rosacea, ozonated hydrotherapy, LED yellow light, minocycline, combined therapy

Introduction

Rosacea is a chronic inflammatory disease, its pathogenesis is related to genetic, immune regulation and other factors.¹ Papulopustular rosacea (PPR) is one of the four subtypes of rosacea. It is characterized by central facial erythema, transient papules, and/or pustular rash, with or without telangiectasia.² Patients may experience discomfort such as dryness, scaling, burning, swelling, and tightness. Due to the recurrent episodes of rosacea, patients suffer greatly and their quality of life is severely affected. Currently, the treatment of PPR mainly includes avoiding specific triggering factors, oral antibiotics, and topical medications³ to control the inflammatory response.⁴ In addition, laser therapy is also used to eliminate erythema and telangiectasia.^{5,6}

Ozone medical preparations are mainly divided into ozonated hydrotherapy, ozone oil for externally use, and ozone autohemotherapy (OAHT). Currently, the application of ozone therapy in dermatology lacks the support of sufficient

theoretical basis and clinical data. The mechanism of ozonated hydrotherapy mainly includes antibacterial effects, immune regulation, antioxidant defense, and epigenetic modification,^{7,8} so it is widely used in the treatment of infectious skin diseases and pruritic skin diseases.⁹ Ozonated hydrotherapy, as a low-cost and minimal side-effect conservative treatment,¹⁰ can reasonably be predicted to have a positive effect on improving symptoms such as itching in PPR.

The light emitting diode (LED) light currently used in clinical practice mainly includes red, blue, green, and yellow light. Among them, LED yellow light, when absorbed by the skin, can treat telangiectasia, inhibit vascular neurogenic hyperreactivity, enhance skin tolerance and resistance, and reduce skin sensitivity.¹¹ Studies have shown that LED yellow light can inhibit the angiogenesis of human microvascular endothelial cells to improve erythema.¹² Based on this, LED yellow light may improve the itching, burning, stinging, and erythema symptoms of PPR.

Tetracycline antibiotics have been recognized for the treatment of rosacea, and it has a better effect on the clearance of rosacea lesions.^{13,14} Therefore, we used oral minocycline as the control treatment. Additionally, the treatment group added ozonated hydrotherapy and LED yellow light combined therapy to observe the therapeutic effects, adverse reactions, and recurrence rate.

Patients and Methods

Study Design

This study included 39 patients with mild to moderate rosacea who were treated in the dermatology department of our hospital from April 2021 to September 2022 and met the criteria with complete clinical information. At that time, the determination of the treatment method for these patients was determined by the patient according to his own conditions under the advice of the doctor. There were 20 patients in combined therapy group and 19 in oral only group. The gender, age, duration of illness, and clinical characteristics were recorded, and patients' subjective symptom scores were collected. This study complied with the Declaration of Helsinki and was approved by the Ethics Committee of the Second Hospital of Shandong University (Ethics No. KYLL-2022LW163). All participating patients voluntarily signed informed consent forms.

Patients

All patients must meet the following inclusion and exclusion criteria. Inclusion criteria: (1) Male and female patients aged 18 years and above. (2) Patients who are able to understand and comply with the requirements of the study, voluntarily participate in the study, and provide written informed consent. (3) Patients diagnosed with rosacea according to the 2017 National Rosacea Society Expert Committee (NRSEC) diagnostic criteria and presenting with papules or pustules with or without central facial erythema, with an Investigator's Global Assessment (IGA) of 2–3 (mild to moderate). Exclusion criteria: (1) Patients with a history of allergy to LED light sources. (2) Patients with a history of allergy to tetracyclines. (3) Patients who have received tetracycline therapy in the past 3 months. (4) Patients who have used other medications or treatment in the past 1 month. (5) Patients who planned to become pregnant or conceived and breastfed during the study period. (6) Patients who had used immunosuppressive agents or glucocorticoids in the past month. (7) Patients with malignant tumors or severe defects in the heart, lungs, liver, or kidneys.

Methods

All patients included in this study orally took minocycline. For the first 4 weeks, patients took minocycline twice a day, with each dose being 40 mg. For the following 4 weeks, the dosage was reduced to once a day, also at 40 mg per dose. Patients in the combined therapy group received ozonated hydrotherapy in conjunction with LED yellow light irradiation therapy while taking minocycline orally. Starting from the initiation of minocycline treatment, they received ozonated hydrotherapy once a week for 15 minutes, followed by LED yellow light irradiation therapy for 20 minutes each time, for a total of 4 weeks. Patients washed their face with ozonated water (3.0mg/L) for 15 minutes. The temperature of the hydrotherapy was maintained at 20–25°C. Ozonated water was created by Ozone Water Generating Instrument (HZ-2601B, Hunan Health Care Technology, Changsha, China) at the Department of Dermatology of the Second Hospital of Shandong University. Subsequently, the patient was instructed to wear protective eyewear. The LED yellow light therapy

device was used for irradiation treatment, with the light source directed vertically at the patient's face from a distance of 10–15 cm. The input power was 400 VA, and the irradiation time was 20 minutes, carried out over a period of 4 weeks. During the treatment, patients were asked to pay attention to facial moisturizing, avoid direct sunlight, minimize the use of cosmetics, maintain a light diet, and avoid scratching the lesion.

Follow-Up

Follow-up for at least 24 weeks after the last treatment was conducted by combining outpatient visits with WeChat and telephone interviews.

Efficacy Evaluation

The researchers utilized the IGA score to evaluate the severity of PPR in each patient before and after treatment (at 0 and 8 weeks). The efficacy was assessed using the patients' subjective symptom scores, which included five independent ratings for the sensation of burning, dry, stinging, itchy, and edema. A score of 0 indicated no symptoms, while scores of 1–3 indicated mild symptoms that the patient could tolerate, scores of 4–6 indicated moderate symptoms that affected sleep but were still tolerable, and scores of 7–10 indicated severe symptoms that were difficult to tolerate. The scores for each symptom and the total score were recorded before treatment, 4 weeks after treatment, and 8 weeks after treatment. The effect of 8 weeks after treatment was used as the final curative effect evaluation result. The curative effect index = (before treatment score - after treatment 8 weeks score) / before treatment score × 100%. Cured: the curative effect index ≥ 90%; Excellent: the curative effect index was 60–89%; Effective: the curative effect index 20% ~ 59%; Ineffective: the curative effect index < 20%.

The changes of skin lesions and adverse reactions during treatment were recorded. After the last treatment, the patients were followed up for 24 weeks to observe the recurrence rate. During the follow-up period, any aggravation of papules, pustules and erythema was recurrence.

Statistical Analysis

SPSS 27.0 statistical software was used for data analysis. Measurement data were expressed as mean ± SD or M (P25, P75), using *t*-test or rank sum test; enumeration data were expressed as n (%), and χ^2 test was used. *P* < 0.05 was considered statistically significant.

Results

Baseline Characteristics

From April 2021 to September 2022, a total of 39 patients met the criteria, including 20 patients in the combined therapy group and 19 patients in the oral only group (Figure 1). The basic clinical data of the patients were shown in Table 1. The two groups of patients had similar demographic and clinical characteristics on baseline data. About 70% of the patients included in this study were women, with an average age of 35.05 years. According to the IGA score, 25.64% of the patients scored 2 points, that is, mild rosacea, and 74.36% of the patients scored 3 points, that is, moderate rosacea.

Treatment Efficacy

At the end of treatment (8 weeks), the score of each symptom and its total score of the patients' subjective symptom scores of the two groups of patients showed significant improvement (*p*<0.05). The combined therapy group exhibited a more pronounced decrease in itching, burning sensation, and total scores at the end of the treatment compared to the oral only group, with statistically significant differences (*p*<0.05) (Table 2). The distribution of IGA scores in both groups changed, with both groups decreasing to below 3, and the combined therapy group had 12 patients (60%) reaching a score of 0 (Figure 2).

Throughout the entire treatment process, symptoms in both groups of patients gradually improved (Figures 3 and 4), and the corresponding scores decreased (Figure 5). After 4 weeks of treatment, 2 patients (10%) in the combined therapy group were deemed non-responsive to the treatment, while 9 patients (47.37%) in the oral only group were non-

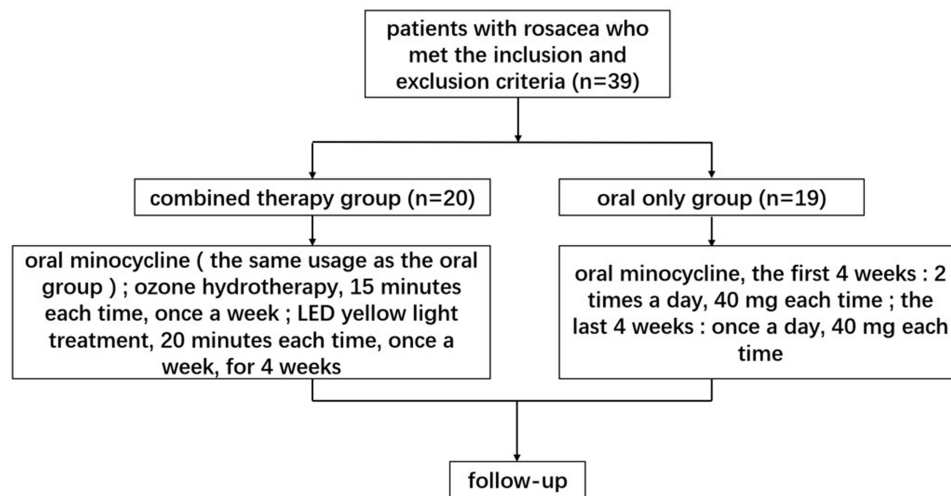


Figure 1 Flowchart of treatment.

responsive. After 8 weeks of treatment, both groups of patients achieved varying degrees of effectiveness (Table 3). The curative effect index in the combined therapy group after 4 weeks was 90%, compared to 52.63% in the oral only group, with statistically significant differences between the two ($p < 0.05$) (Table 4).

Adverse Reactions and Recurrence Rates

During the process of the irradiation of LED yellow light, one patient in the combined therapy group experienced transient stinging on the face during the first irradiation, which was relieved immediately after applying cold compress. And the patient did not experience the same symptoms after several subsequent radiation treatments. One patient in each group experienced mild and tolerable nausea and dizziness, these adverse reactions were not specifically treated and disappeared during follow-up.

After 24 weeks of follow-up, the recurrence rate in the combined therapy group was 5%, while the recurrence rate in the oral only group was 26.32% (Table 5).

Discussion

Oral minocycline have been widely accepted for the treatment of rosacea, but patients should avoid long-term use of minocycline if possible because the duration of oral minocycline may be related to hyperpigmentation.¹⁵ Therefore, it is urgent to find a treatment that can relieve symptoms as soon as possible and reduce recurrence. Combined therapy is not uncommon in the treatment of rosacea, but the use of ozonated hydrotherapy combined with LED yellow light irradiation

Table 1 Characteristics of Clinical Features of Patients with Rosacea

Characteristics	Combined Therapy Group	Oral Only Group	Total
Number of patients	20 (51.28)	19 (48.72)	39
Gender			
Male	7 (35.00)	5 (26.32)	12 (30.77)
Female	13 (65.00)	14 (73.63)	27 (69.23)
Age, years	34.95 ± 11.69	35.16 ± 8.45	35.05 ± 10.11
Rosacea duration, years	2.00 (2.00, 4.50)	2.00 (1.00, 6.00)	2.00 (1.00, 5.00)
IGA			
2	6 (30.00)	4 (21.05)	10 (25.64)
3	14 (70.00)	15 (78.95)	29 (74.36)

Note: n (%), mean ± SD, M (P25, P75).

Abbreviation: IGA, Investigator's global assessment.

Table 2 Comparison of the Patients' Subjective Symptom Scores Between Two Groups

Features	Combined Therapy Group		Oral Only Group		P*
	Mean ± SD	p	Mean ± SD	p	
Burning sensation of the skin					
Before treatment	4.30 ± 1.84	<0.001	4.11 ± 1.37	<0.001	0.005
8 weeks after treatment	0.80 ± 1.40		1.68 ± 1.06		
Dry sensation of the skin					
Before treatment	4.15 ± 2.18	<0.001	4.16 ± 1.68	<0.001	0.773
8 weeks after treatment	0.8 ± 1.11		1.00 ± 0.86		
Stinging sensation of the skin					
Before treatment	2.10 ± 2.29	<0.001	2.21 ± 1.62	<0.001	0.745
8 weeks after treatment	1.15 ± 0.37		0.89 ± 0.94		
Itchy sensation of the skin					
Before treatment	3.75 ± 2.10	<0.001	3.58 ± 1.31	<0.001	0.012
8 weeks after treatment	0.50 ± 0.69		1.47 ± 0.84		
Edema					
Before treatment	1.00 ± 1.56	0.011	0.47 ± 0.70	0.023	0.496
8 weeks after treatment	0.05 ± 0.22		0.05 ± 0.23		
Total					
Before treatment	15.3 ± 7.13	<0.001	14.53 ± 5.07	<0.001	<0.001
8 weeks after treatment	2.3 ± 2.23		5.05 ± 1.65		

Notes: P: Statistical comparison in combined therapy group or oral only group before and after treatment. P*: Statistical comparison between the two groups before and after treatment.

and oral minocycline has not been reported. In this study, we used oral minocycline as the control group to treat mild to moderate PPR, and the treatment group added ozonated hydrotherapy and LED yellow light irradiation. The efficacy, adverse reactions, and recurrence rate of the two groups were compared. In summary, ozonated hydrotherapy combined with LED yellow light irradiation and oral minocycline can improve moderate PPR patients, and reduce the recurrence rate.

For patients with PPR, erythema, burning, dryness, and itching are their characteristics.¹⁶ At the end of treatment, the combined therapy group showed a significant improvement in relieving itching, burning sensation, and delaying recurrence compared to the oral only group. Although both groups eventually achieved relief of symptoms, the combined therapy group required less time to achieve the same efficacy. Such remarkable efficacy may be attributed to the complex treatment mechanisms of ozonated hydrotherapy and LED yellow light.

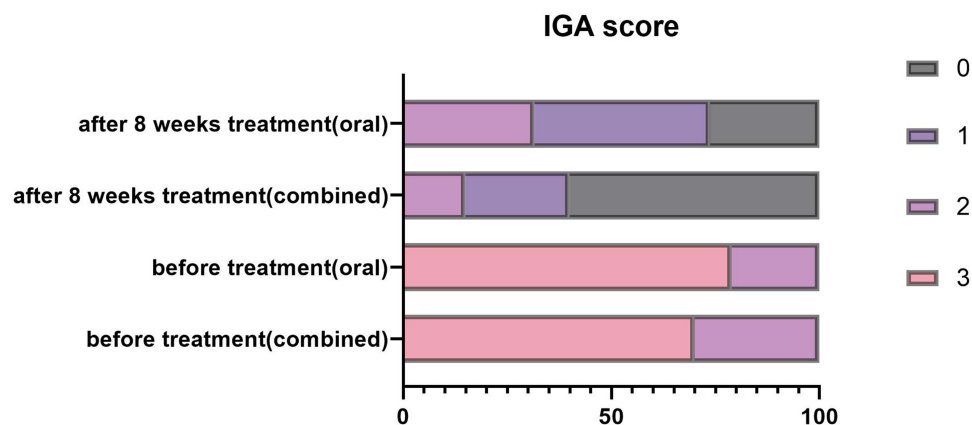
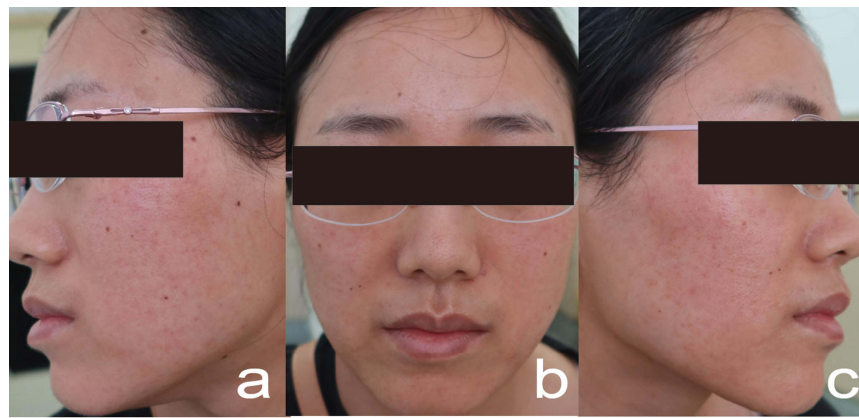
**Figure 2** IGA score before and after 8 weeks treatment.

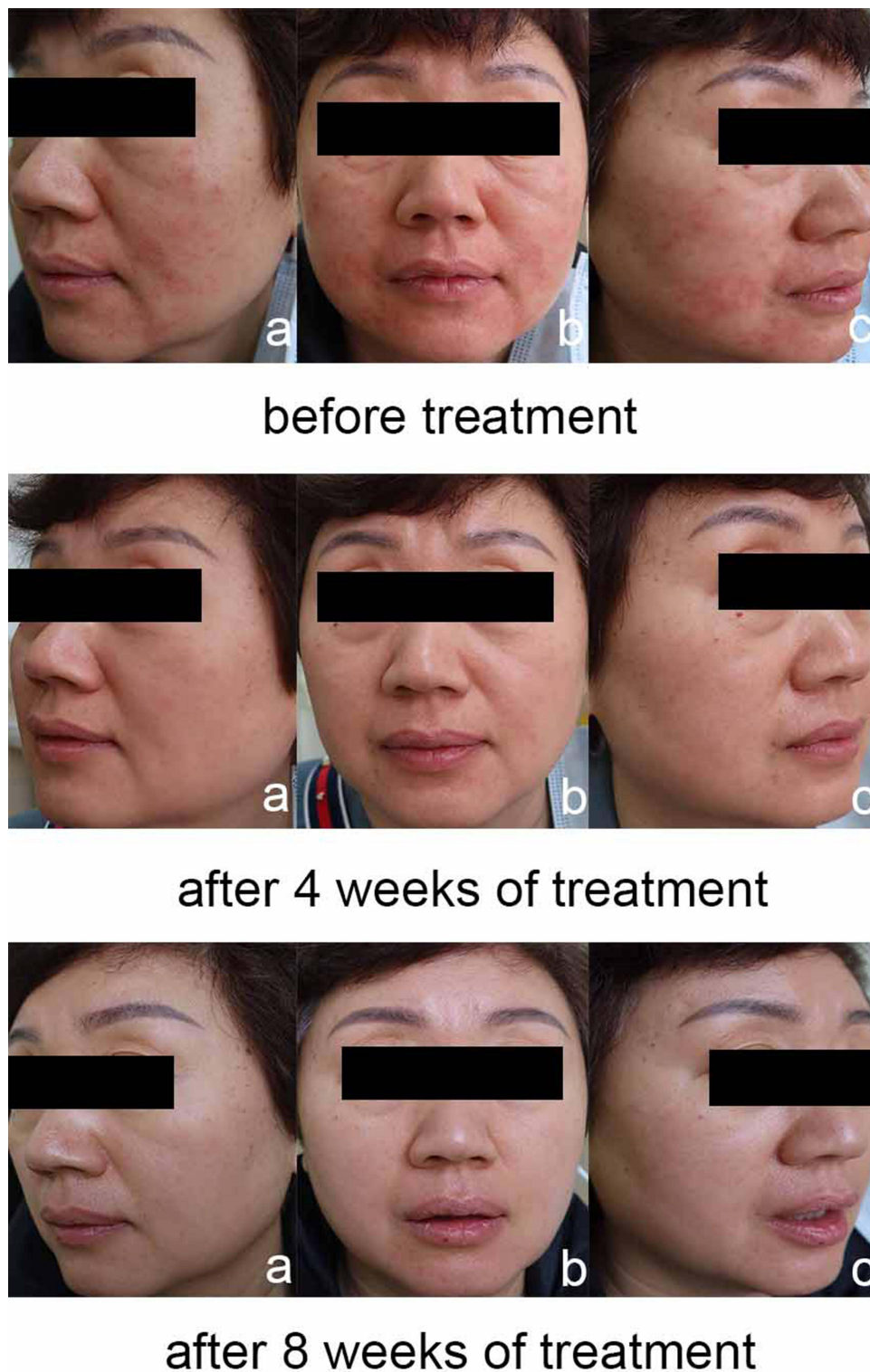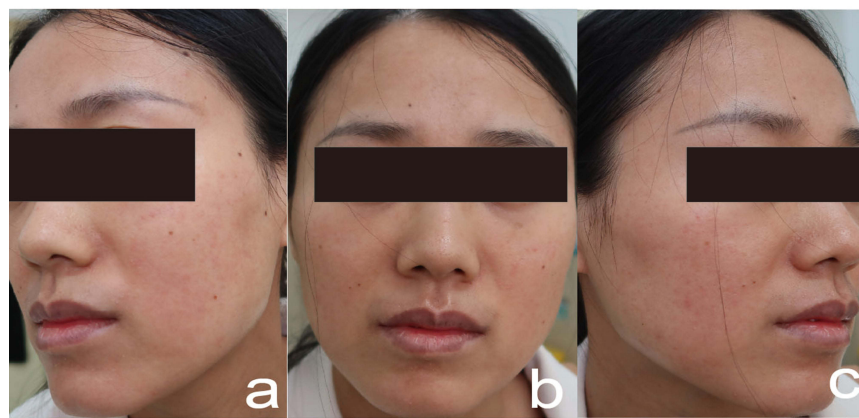


Figure 3 Comparison of the cases in combination therapy group before and after treatment.

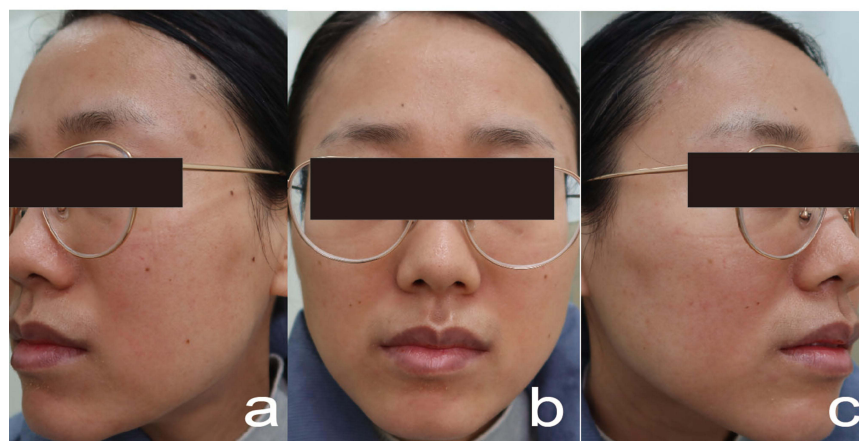
Ozonated hydrotherapy can reduce the exudation of tissue fluid, alleviate inflammatory reactions, and relieve pain and itching.¹⁷ It is often used in clinical practice to relieve the symptoms of rosacea. However, there is not much clinical data and theoretical basis to explore its efficacy and mechanism for rosacea.



before treatment



after 4 weeks of treatment



after 8 weeks of treatment

Figure 4 Comparison of the cases in oral only therapy group before and after treatment.

Total scores of patients' subjective symptom scores

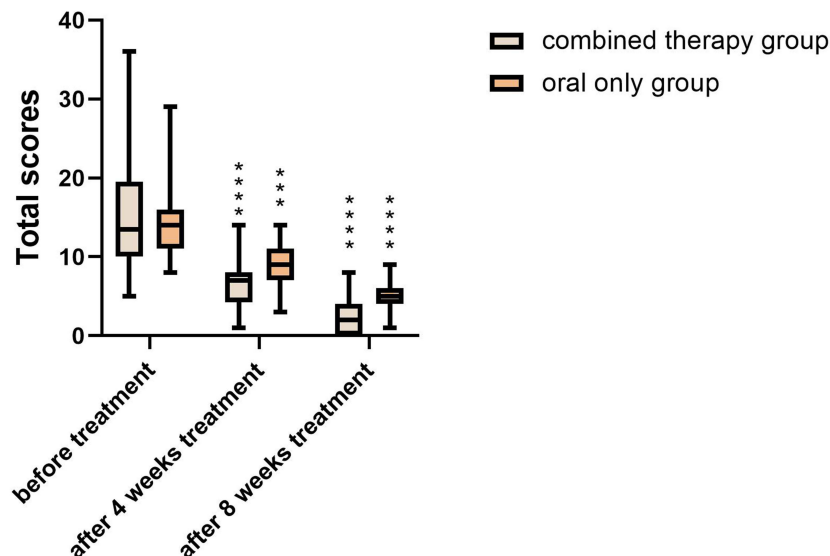


Figure 5 Comparison of total scores of patients' subjective symptom scores before and after treatment. *** $P < 0.0001$, ** $P < 0.001$.

The expression of keratinocyte derived toll-like receptor 2 (TLR2) is up-regulated in patients with rosacea, and the activity of cathelicidin and serine protease in the skin are higher than those in healthy people.¹ The study found that LED light irradiation can down-regulate the activity and expression of TLR2 in keratinocytes and rosacea-like mice skin, as well as the activity of cathelicidin and serine protease,¹⁸ which provides a basis for LED yellow light treatment of rosacea. It has been reported that demodex may be associated with the recurrence of rosacea, and early inhibition of demodex proliferation can reduce its recurrence.¹⁹ LED yellow light treatment can effectively reduce the density of demodex in rosacea patients,²⁰ which suggests that LED yellow light may inhibit the recurrence of rosacea by inhibiting the proliferation of demodex.

Table 3 Comparison of Effective Rate Between Two Groups

Group	Cured	Excellent	Effective	Ineffective
Combined therapy group				
4 weeks after treatment	0 (0)	14 (70)	4 (20)	2 (10)
8 weeks after treatment	9 (45)	9 (45)	2 (10)	0 (0)
Oral only group				
4 weeks after treatment	0 (0)	3 (15.79)	7 (36.84)	9 (47.37)
8 weeks after treatment	0 (0)	13 (68.42)	6 (31.58)	0 (0)

Note: n (%).

Table 4 Comparison of the Curative Effect Index of 4 Weeks After Treatment Between Two Groups

Group	n	Effective	Ineffective	Fisher's Exact Test
				p
Combined therapy group	20	18 (90)	2 (10)	0.014
Oral only group	19	10 (52.63)	9 (47.37)	

Note: n (%).

Table 5 Recurrence Rates Between Two Groups

Group	n	No-Recurrence	Recurrence	Fisher's Exact Test
				p
Combined therapy group	20	19 (95.00%)	1 (5.00%)	0.091
Oral only group	19	14 (73.68%)	5 (26.32%)	

Note: n (%).

The combination treatment was safe, and although one patient experienced stinging during the first LED yellow light treatment, which was quickly relieved and did not occur in the subsequent three irradiation treatments. Nausea and dizziness occurred in one patient in each of the two groups, and the same adverse effects have been seen in other studies on minocycline,²¹ so we speculate that this may be due to oral minocycline. Although there was no statistical significance between the two groups, it can be observed that the recurrence rate in the combined therapy group was significantly lower than that in the oral only group. The mechanism of inhibiting relapse remains to be further explored. The combined therapy can improve symptoms in mild to moderate PPR, suggesting that it should also be beneficial in patients with severe rosacea with more severe symptoms, but this requires further clinical study.

Conclusion

In summary, on the basis of oral minocycline, the application of ozone hydrotherapy combined with LED yellow light irradiation in the treatment of mild to moderate PPR patients is a safe and effective method that is beneficial to reduce the recurrence rate. It's a priority for patients with symptoms like itching and burning sensation. Therefore, the combination therapy should be promoted. The limitation of this study is that it only explored the efficacy of combination therapy for mild and moderate rosacea, and it is unclear whether combination therapy has the same efficacy for severe rosacea. We need to further explore the mechanism of combination therapy for rosacea. And more high-quality, prospective, double-blind, controlled clinical trials are needed to evaluate the efficacy of the combination therapy in this study.

Data Sharing Statement

The data that support the findings of this study are available from the corresponding author upon reasonable request.

Ethics Approval

This retrospective chart review study involving human participants was in accordance with the ethical standards of the institutional and national research committee and with the 1964 Helsinki Declaration and its later amendments or comparable ethical standards. The study was approved by the Ethics Committee of the Second Hospital of Shandong University (Ethics No. KYLL-2022LW163).

Patient Consent

Patients signed informed consent regarding publishing their data and photographs.

Disclosure

The authors report no conflicts of interest in this work.

References

1. van Zuuren EJ, Arents BWM, van der Linden MMD, Vermeulen S, Fedorowicz Z, Tan J. Rosacea: new concepts in classification and treatment. *Am J Clin Dermatol.* 2021;22(4):457–465. doi:10.1007/s40257-021-00595-7
2. Schaller M, Almeida LMC, Bewley A, et al. Recommendations for rosacea diagnosis, classification and management: update from the global ROSacea COnsensus 2019 panel. *Br J Dermatol.* 2020;182(5):1269–1276. doi:10.1111/bjd.18420
3. Trave I, Micalizzi C, Cozzani E, Gasparini G, Parodi A. Papulopustular rosacea treated with ivermectin 1% cream: remission of the demodex mite infestation over time and evaluation of clinical relapses. *Dermatol Pract Concept.* 2022;12(4):e2022201. doi:10.5826/dpc.1204a201

4. Wang L, Li XH, Wen X, et al. Retrospective analysis of 19 papulopustular rosacea cases treated with oral minocycline and supramolecular salicylic acid 30% chemical peels. *Exp Ther Med.* 2020;20(2):1048–1052. doi:10.3892/etm.2020.8740
5. Fan L, Yin R, Lan T, Hamblin MR. Photodynamic therapy for rosacea in Chinese patients. *Photodiagnosis Photodyn Ther.* 2018;24:82–87. doi:10.1016/j.pdpdt.2018.08.005
6. Bao N, Gu T, Zeng J, et al. Combined therapy of 5-aminolevulinic acid photodynamic therapy and intense pulsed light for rosacea. *Lasers Med Sci.* 2022;38(1):17. doi:10.1007/s10103-022-03685-y
7. Zeng J, Lu J. Mechanisms of action involved in ozone-therapy in skin diseases. *Int Immunopharmacol.* 2018;56:235–241. doi:10.1016/j.intimp.2018.01.040
8. Borges G, Elias ST, da Silva SM, et al. In vitro evaluation of wound healing and antimicrobial potential of ozone therapy. *J Craniomaxillofac Surg.* 2017;45(3):364–370. doi:10.1016/j.jcms.2017.01.005
9. Wang X. Emerging roles of ozone in skin diseases. *Zhong Nan Da Xue Xue Bao Yi Xue Ban.* 2018;43(2):114–123. doi:10.11817/j.issn.1672-7347.2018.02.002
10. Leon BR, Romary DJ, Landsberger SA, Bradner KN, Ramirez M, Lubitz RM. Risks of ozonated oil and ozonated water on human skin: a systematic review. *Int Wound J.* 2022;19(7):1901–1910. doi:10.1111/iwj.13760
11. Ngoc LTN, Moon JY, Lee YC. Utilization of light-emitting diodes for skin therapy: systematic review and meta-analysis. *Photodermatol Photoimmunol Photomed.* 2023;39(4):303–317. doi:10.1111/phpp.12841
12. Dai X, Jin S, Xuan Y, et al. 590 nm LED irradiation improved erythema through inhibiting angiogenesis of human microvascular endothelial cells and ameliorated pigmentation in melasma. *Cells.* 2022;11(24):3949. doi:10.3390/cells11243949
13. Shemer A, Gupta AK, Kassem R, Sharon N, Quinlan EM, Galili E. Low-dose isotretinoin versus minocycline in the treatment of rosacea. *Dermatol Ther.* 2021;34(4):e14986. doi:10.1111/dth.14986
14. Mahmud H, Keenan JD, Gonzales J, et al. Ocular Rosacea microBiome Study (ORBS)-sub-microbial versus antibiotic dosing of doxycycline versus placebo in treatment of symptomatic ocular rosacea: study protocol for a parallel-arm randomized clinical trial. *Trials.* 2022;23(1):1033. doi:10.1186/s13063-022-06948-9
15. Kobayashi T, Hayakawa K. Minocycline-induced skin pigmentation. *Infection.* 2017;45(1):129–130. doi:10.1007/s15010-016-0952-5
16. Zhou M, Xie H, Cheng L, Li J. Clinical characteristics and epidermal barrier function of papulopustular rosacea: a comparison study with acne vulgaris. *Pak J Med Sci.* 2016;32(6):1344–1348. doi:10.12669/pjms.326.11236
17. Travagli V, Zanardi I, Valacchi G, Bocci V. Ozone and ozonated oils in skin diseases: a review. *Mediators Inflamm.* 2010;2010:610418. doi:10.1155/2010/610418
18. Lee JB, Bae SH, Moon KR, Na EY, Yun SJ, Lee SC. Light-emitting diodes downregulate cathelicidin, kallikrein and toll-like receptor 2 expressions in keratinocytes and rosacea-like mouse skin. *Exp Dermatol.* 2016;25(12):956–961. doi:10.1111/exd.13133
19. Trave I, Salvi I, Cozzani E, Donadoni R, Parodi A. Has the use of the mask exacerbated rosacea during the pandemic? *Dermatol Pract Concept.* 2023;13(4). doi:10.5826/dpc.1304a230
20. Temiz SA, Durmaz K, Işık B, Ataseven A, Dursun R. The effect of 577-nm pro-yellow laser on demodex density in patients with rosacea. *J Cosmet Dermatol.* 2022;21(1):242–246. doi:10.1111/jocd.14085
21. Martins AM, Marto JM, Johnson JL, Graber EM. A review of systemic minocycline side effects and topical minocycline as a safer alternative for treating acne and rosacea. *Antibiotics.* 2021;10(7):757. doi:10.3390/antibiotics10070757

Clinical, Cosmetic and Investigational Dermatology

Dovepress

Publish your work in this journal

Clinical, Cosmetic and Investigational Dermatology is an international, peer-reviewed, open access, online journal that focuses on the latest clinical and experimental research in all aspects of skin disease and cosmetic interventions. This journal is indexed on CAS. The manuscript management system is completely online and includes a very quick and fair peer-review system, which is all easy to use. Visit <http://www.dovepress.com/testimonials.php> to read real quotes from published authors.

Submit your manuscript here: <https://www.dovepress.com/clinical-cosmetic-and-investigational-dermatology-journal>