

An Unusual Cause of Intestinal Ulcers Masquerading as Inflammatory Bowel Disease: A Case Report of Allied Disorders of Hirschsprung's Disease

Minli Hu^{1*}, Hao Fang^{2*}, Yibing Hu¹, Chong Lu¹, Yuan Chen¹, Zhifeng Zhong³, Hongqi Shi⁴, Qunying Wang¹

¹Department of Gastroenterology, Jinhua Municipal Central Hospital, Jinhua, Zhejiang, People's Republic of China; ²Department of Traumatology, Jinhua Municipal Central Hospital, Jinhua, Zhejiang, People's Republic of China; ³Department of Anus & Intestine Surgery, Jinhua Municipal Central Hospital, Jinhua, Zhejiang, People's Republic of China; ⁴Department of Pathology, Jinhua Municipal Central Hospital, Jinhua, Zhejiang, People's Republic of China

*These authors contributed equally to this work

Correspondence: Qunying Wang, Department of Gastroenterology, Jinhua Municipal Central Hospital, Jinhua, Zhejiang, People's Republic of China, Email wqy616717@126.com

Background: Allied disorders of Hirschsprung's disease (ADHD) exhibit symptoms akin to those of Hirschsprung's disease, primarily characterized by intestinal obstruction, bowel dilatation, and chronic constipation. The occurrence of amyloid complications in patients with ADHD is infrequent. In this report, we present a case of ADHD with intestinal ulcers as the initial gastrointestinal manifestation, and subsequent pathological examination revealed the presence of amyloid deposits in the colonic mucosa.

Case Report: A male patient, aged 20, exhibited recurring abdominal distension and intestinal obstruction for a duration of three years. Multiple colonoscopies revealed the presence of recurrent colonic ulcers, with pathological examination indicating the existence of amyloid deposits within the mucosal layer of the colon. Abdominal CT scans suggested colonic dilatation. Following a multidisciplinary consultation, a subtotal resection of the colon was performed, and subsequent postoperative pathology confirmed a decrease and absence of myenteric plexus ganglion cells. Considering the patient's symptoms and the findings from the postoperative pathology, a diagnosis of ADHD was made. The patient's symptoms resolved postoperatively and he was discharged from the hospital and followed up for 1 year in stable condition.

Conclusion: Our study highlights the potential association between ADHD and the initial presentation of recurrent colonic ulcers, accompanied by amyloid deposition in the intestinal mucosa. This finding suggests a possible pathogenic mechanism for ADHD and offers a novel perspective on its diagnosis.

Keywords: allied disorders of Hirschsprung's disease, colonic ulcer, amyloid, intestinal obstruction, colonoscopy biopsy colonic

Introduction

Allied disorders of Hirschsprung's disease (ADHD) are a relatively uncommon medical condition characterized by intestinal obstruction, bowel dilatation, and chronic constipation (1). Limited case reports and clinical studies have been conducted in recent years, resulting in frequent misdiagnosis and underdiagnosis due to a lack of understanding regarding its pathogenesis. The occurrence of amyloid complications in patients with ADHD is exceedingly rare, as amyloid is primarily associated with conditions such as amyloidosis or Behçet disease (2, 3). So far, no patients with ADHD with amyloid accompanied with Gastrointestinal (GI) manifestations have been reported. Here, we present a case of colonic ulcerations as the first GI manifestation, and amyloid deposits in the intestinal mucosa caused by the ADHD.

Case Presentation

A 20-year-old male was referred to our hospital with recurrent abdominal pain, intestinal obstruction, and colonic ulcer. At the age of 17 years, he presented to the doctor with recurrent lower abdominal distension that lasted for about 1 minute and was relieved by farting, with a high frequency of up to a dozen episodes per day. Normal bowel movements, occasional constipation, sometimes only 1 bowel movement in 2 weeks. He had been treated in a local hospital for intestinal obstruction, colonoscopy revealed multiple ulcers in the colon, Crohn's disease was suspected, and was treated with probiotics. Abdominal distension and pain continued to occur during treatment. At admission, his body temperature was 36.7°C and blood pressure was 135/82 mm Hg.

A blood examination demonstrated anemia (hemoglobin, 106g/L, normal: 130–170 g/L), normal creatinine levels and C-reactive protein level. Urine test is normal and a positive stool test for blood (1+). The Computed Tomography (CT) scan of the whole abdomen indicated dilatation in part of the small intestine and colon (Figure 1a and b), and an Magnetic Resonance Imaging (MRI) of the pelvis revealed no fistula. Colonoscopy demonstrated a circumferential ulcer of the transverse colon with spontaneous bleeding and multiple longitudinal ulcers on the descending colon (Figure 2a–c). A biopsy from the margin of transverse colon ulcer revealed slight structural changes in the crypts, visible cryptitis, crypt abscesses, no granulomas, suspected Crohn's disease. Capsule endoscopy revealed scattered small ulcers were observed in the jejunum. The diagnosis of multiple ulcers of the colon with a high probability of Crohn's disease was made and the patient was treated with mesalazine (4g/day). On repeat colonoscopy 3 months after

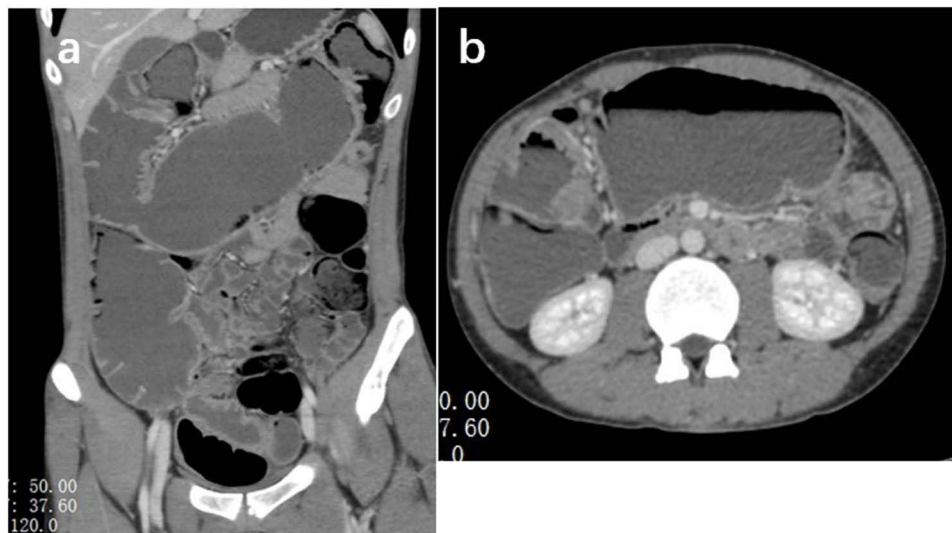


Figure 1 (a and b) Abdominal CT scan indicates gas and fluid accumulation inside the colon and small intestine.

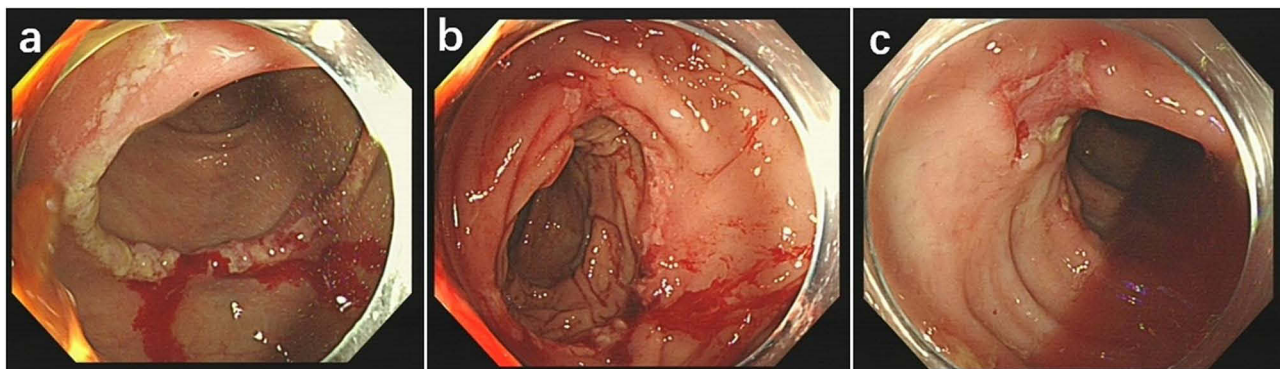


Figure 2 (a–c) Early onset transverse colonic ulcers with spontaneous bleeding, multiple ulcers inside the descending colon.

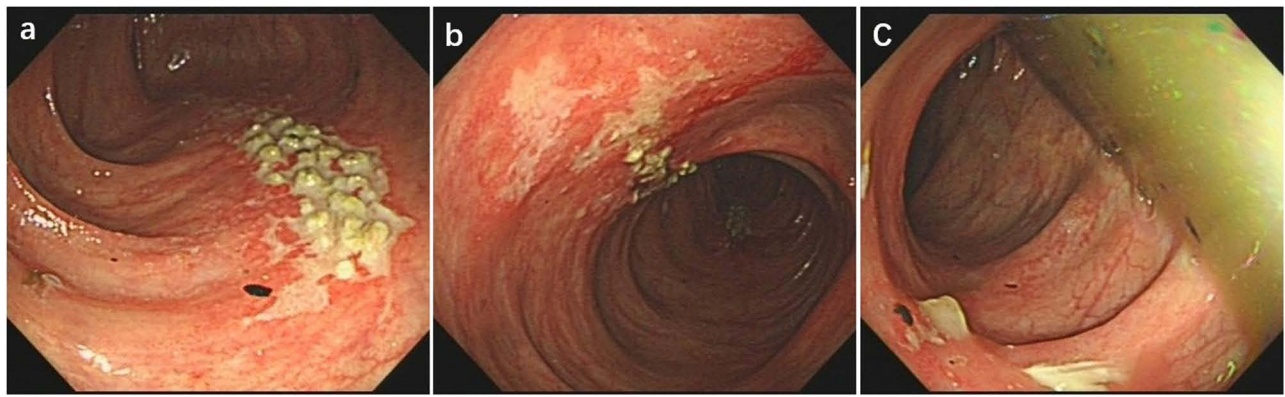


Figure 3 (a–c) Ulcers were present in the transverse colon, and shallow ulcers was seen in the descending colon.

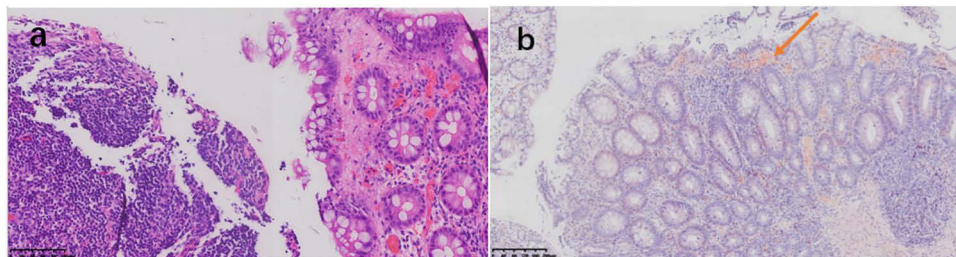


Figure 4 (a and b) Chronic inflammation of the transverse colonic mucosa with lymphocytosis (HE staining, $\times 100$), amyloid deposits are visible in the mucosal layer of the transverse colon through Congo red staining (arrowed).

treatment, multiple small ulcers were still visible in the transverse colon (Figure 3a–c), and biopsy of the ulcers suggested positive Congo red staining (Figure 4a and b). Further checking for normal serum IgA, IgG and IgM levels. Serum M-protein was not detected, and free light chain kappa/lambda ratio was within normal limits. Antinuclear antibody and urine Bence Jones protein were negative. Cardiac ultrasonography and renal ultrasonography were unremarkable, essentially ruling out amyloidosis. On July 2022, the patient had recurrent abdominal distension, abdominal CT scan reveals dilatation and effusion of colon (5.2cm at the most dilatation) (Figure 5a and b). The presence of intestinal obstruction was taken into consideration. Following admission, the patient received supportive treatment, which encompassed fasting and administration of suitable medication. Nevertheless, the abdominal distension and pain were prominently intense.

Following interdisciplinary discussions, it was concluded that the patient's recurrent intestinal obstruction persisted despite appropriate conservative medical treatment, necessitating surgical resection of the affected bowel segment to alleviate the obstruction and ascertain the root cause. Subsequently, a preoperative barium enema angiogram was conducted, revealing sustained contractions and spasms in the transverse colon and left portion of the colon (including the splenic flexure and descending colon) (Figure 6a and b). Anorectal manometry revealed the existence of an inhibitory reflex in the rectum, along with a heightened sensory threshold in the rectal muscles. A laparoscopic resection was conducted on the transverse colon and descending colon, with postoperative pathology revealing a decrease and absence of ganglion cells within the intermuscular layer of the mucosal lamina propria of the affected bowel segment. This finding supported a diagnosis of ADHD (Figure 7a and b), while ruling out Crohn's disease due to the absence of non-caseous granulomas. The patient experienced a successful recovery post-surgery and was discharged with scheduled follow-up appointments. Subsequently, the patient exhibited regular bowel movements occurring 1–2 times per day, without any recurring abdominal pain, constipation, or bleeding, thus demonstrating a relatively stable condition. The patient has given written consent for the publication of this case report.

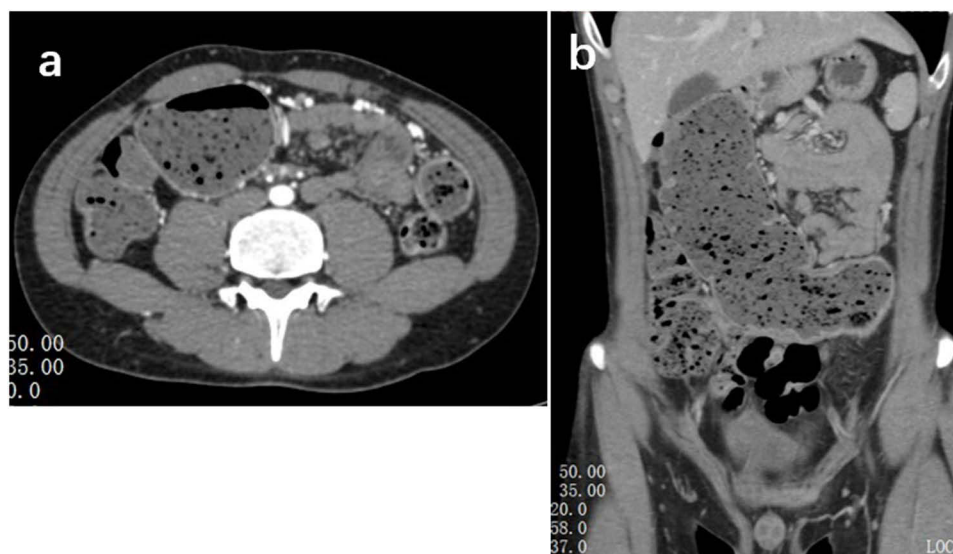


Figure 5 (a and b) Abdominal CT ascending colon, transverse colon, and part of the descending colon showing dilatation and fluid accumulation (most dilated at 5.2 cm).

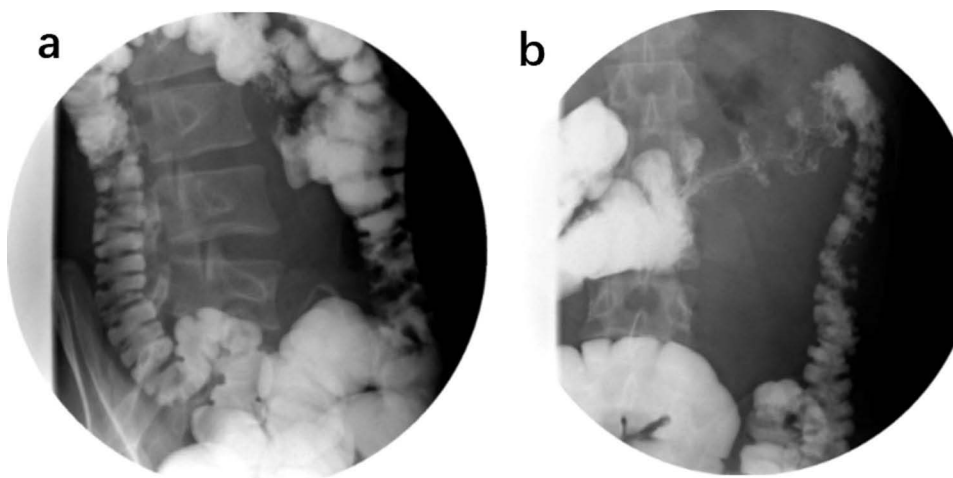


Figure 6 (a and b) Barium enema angiogram indicates revealing sustained contractions and spasms in the transverse colon and left portion of the colon (including the splenic flexure and descending colon).

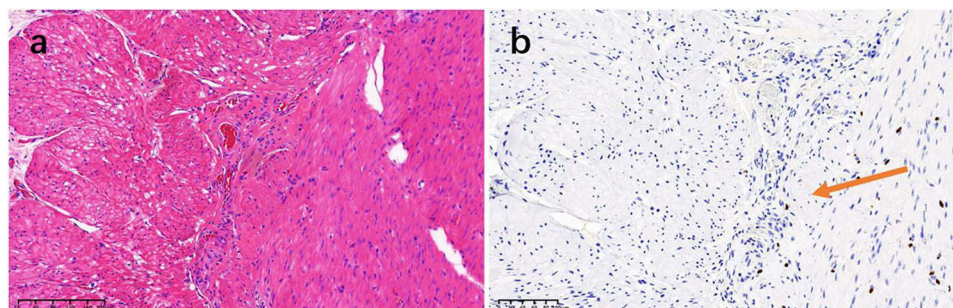


Figure 7 (a and b) The reduced number of intermuscular plexuses are visible in the transverse colon. There were no ganglion cells in some plexuses (HE staining, $\times 100$), the absence of interosseous ganglia seen through SOX10 staining (arrowed).

Discussion

In 1958, Ravitch initially documented ADHD as “pseudo Hirschsprung’s disease” in the *Annals of Surgery*.¹ The clinical manifestations of ADHD closely resemble those of Hirschsprung’s disease (HD). HD is characterized by the absence of rectal-anal reflexes due to the lack of ganglion cells innervating the rectum, as well as reduced or absent distal ganglion cells in other regions of the colon, resulting in impaired intestinal motility. Consequently, symptoms such as constipation, vomiting, intestinal obstruction, and intestinal dilatation are frequently observed during the neonatal period or infancy, necessitating prompt diagnosis. In contrast, rectal ganglion cells persist in individuals with ADHD and have the potential to elicit the recto-anal reflex, thereby frequently manifesting clinical symptoms during adulthood. Consequently, this can result in misdiagnosis and underdiagnosis due to insufficient recognition by physicians. It is noteworthy that ADHD is a relatively uncommon condition with a low occurrence rate, as evidenced by a mere 355 cases identified in a comprehensive nationwide survey conducted in Japan between 2001 and 2010.²

Furthermore, alongside the customary indications of recurring abdominal distension and pain, constipation, and intestinal obstruction, the patient exhibited recurring colonic ulcers as the principal manifestation, a relatively uncommon clinical characteristic of attention deficit hyperactivity disorder (ADHD). Typical clinical origins of colonic ulcers encompass intestinal infections (bacterial, parasitic, tuberculosis, viral, etc.), ischemic bowel disease, inflammatory bowel disease, lymphoma, autoimmune disorders, or tumor involvement.^{3,4} A previously documented case presented a combination of colonic ulcer and pseudomembranous colitis, with the colonic ulcer being attributed to *Clostridium difficile* infection.⁵ Nevertheless, a comprehensive examination revealed no indications of intestinal or other organ infections, tumors, or any other aforementioned factors contributing to colonic ulcers in this particular case. Consequently, we posit that the development of colonic ulcers is primarily associated with the individual’s underlying condition. Therefore, it is our contention that the development of colonic ulcers is primarily associated with an individual’s underlying condition. This assertion can be supported by two key factors. The reduction or absence of ganglion cells disrupts the normal peristaltic movement of the intestines, resulting in disorganized functioning of intestinal contents, mechanical injury, and intraluminal hypertension. Additionally, this reduction or absence hinders the normal movement of the bowel, leading to a lack of normal dilation in affected segments on barium enema contrast and instead presenting with persistent contractile spasm.⁵ Secondly, the activation and infiltration of inflammatory cells, including pro-inflammatory macrophages, at varying degrees contributes to the formation of crypt abscesses and mucosal damage, ultimately resulting in the manifestation of colonic ulcers.^{4,5}

ADHD is classified into two categories according to pathology: (1) abnormal ganglia, including immaturity of ganglia, hypoganglionosis, and intestinal neuronal dysplasia; (2) normal ganglia, including megacystis microcolon intestinal hypoperistalsis syndrome, segmental dilatation, internal anal sphincter achalasia, and chronic idiopathic intestinal pseudo-obstruction.⁵ Full-thickness pathological examination is the gold standard for the diagnosis of ADHD.^{5,6} Currently, Immunohistochemical indicators such as hematoxylin and eosin staining, acetylcholinesterase staining, CD56, S-100 protein, and SOX10 are all used by investigators for diagnosing ADHD.⁷ The patient’s pathology findings revealed a diminished quantity of ganglia in the affected region, a decrease in the plexus area, and an absence of mature ganglion cells in certain plexuses, which aligns with the characteristics of ADHD. However, unlike the documented variations, the pathological biopsies exhibited amyloid deposits in the colonic mucosal layer (confirmed by positive Congo red staining). Additionally, subsequent analysis of serum protein electrophoresis did not detect the presence of M protein, while the levels of serum and urine κ -type light chains and λ -type light chains fell within the normal range. Simultaneously, laboratory tests and imaging evaluations did not detect any amyloid infiltration in the heart and kidneys, thus effectively excluding the possibility of amyloidosis causing amyloid deposition. Previous studies have indicated that the β -site amyloid β precursor protein cleavage enzyme, as identified through whole genome sequence analysis of HD, hinders amyloid β production and impedes amyloid accumulation, thereby safeguarding neurons against apoptosis.⁸ Consequently, this amyloid may be linked to the pathogenesis of ADHD. Based on our current understanding, this represents the inaugural instance of ADHD accompanied by amyloid deposits, which presented as colonic ulcers as the primary gastrointestinal manifestation. As per existing scholarly literature, amyloid refers to an extracellular deposition of misfolded, insoluble protein complexes, specifically monoclonal immunoglobulin light chains.⁹ Various

types of amyloid, such as Immunoglobulin light chain, transthyretin amyloid, serum amyloid A, and A β 2 amyloid, are deposited in organs such as the kidney, heart, and gastrointestinal tract, thereby mimicking the normal function of tissues and organs and leading to the development of multiple myeloma, inflammatory bowel disease, and tumors.^{10,11} Regrettably, the lack of technical capabilities prevented further analysis of the specific type of amyloid deposited in the intestinal amyloid of this patient. This missed opportunity may have potentially generated novel treatment approaches.

Conclusions

This study reports a case of recurrent intestinal obstruction and intestinal ulceration with confirmed pathological evidence following the resection of an affected intestinal segment. To our knowledge, this is the first documented case of ADHD with amyloid deposits, presenting with colonic ulcers as the initial gastrointestinal manifestation. Consequently, additional research is imperative to clarify the mechanisms responsible for amyloid deposition in individuals with ADHD.

Abbreviations

ADHD, Allied disorders of Hirschsprung's disease; GI, Gastrointestinal; CT, Computed Tomography; MRI, Magnetic Resonance Imaging; HD, Hirschsprung's disease.

Ethics Approval and Consent to Participate

Ethics approval is not required for this type of study. Written consent to participate in this study was obtained from the patient.

Consent for Publication

Written informed consent was obtained from the patient for publication of this case report and any accompanying images. A copy of the written consent is available for review by the Editor-in-Chief of this journal.

Acknowledgments

The authors thank the patient for participating in this case study.

Author Contributions

All authors made a significant contribution to the work reported, whether that is in the conception, study design, execution, acquisition of data, analysis and interpretation, or in all these areas; took part in drafting, revising or critically reviewing the article; gave final approval of the version to be published; have agreed on the journal to which the article has been submitted; and agree to be accountable for all aspects of the work.

Funding

This work was supported by the Department of Health of Zhejiang Province (2019RC302).

Disclosure

The authors declare that there is no competing interest to report for this work.

References

1. Ravitch MM. Pseudo Hirschsprung's disease. *Ann Surg.* 1958;147(6):781–795.
2. Taguchi T, Ieiri S, Miyoshi K, et al. The incidence and outcome of allied disorders of Hirschsprung's disease in Japan: results from a nationwide survey. *Asian J Surg.* 2017;40(1):29–34. doi:10.1016/j.asjsur.2015.04.004
3. Magro F, Gionchetti P, Eliakim R, et al. Third European evidence-based consensus on diagnosis and management of ulcerative colitis. part 1: definitions, diagnosis, extra-intestinal manifestations, pregnancy, cancer surveillance, surgery, and ileo-anal pouch disorders. *J Crohn's Colitis.* 2017;11(6):649–670. doi:10.1093/ecco-jcc/jjx008
4. Brandt LJ, Feuerstadt P, Longstreth GF, Boley SJ. ACG clinical guideline: epidemiology, risk factors, patterns of presentation, diagnosis, and management of colon ischemia (CI). *Am J Gastroenterol.* 2015;110(1):18–44. doi:10.1038/ajg.2014.395

5. Muto M, Matsufuji H, Taguchi T, et al. Japanese clinical practice guidelines for allied disorders of Hirschsprung's disease, 2017. *Pediatr Int*. 2018;60(5):400–410. doi:10.1111/ped.13559
6. Jiang S, Song C-Y, Feng M-X, Lu Y-Q. Adult patients with allied disorders of Hirschsprung's disease in emergency department: an 11-year retrospective study. *World J Gastrointest Surg*. 2022;14(7):656–669. doi:10.4240/wjgs.v14.i7.656
7. Yoshimaru K, Taguchi T, Obata S, et al. Immunostaining for Hu C/D and CD56 is useful for a definitive histopathological diagnosis of congenital and acquired isolated hypoganglionosis. *Virchows Arch*. 2017;470(6):679–685. doi:10.1007/s00428-017-2128-9
8. Tang CS-M, Li P, Lai FP-L, et al. Identification of genes associated with Hirschsprung disease, based on whole-genome sequence analysis, and potential effects on enteric nervous system development. *Gastroenterology*. 2018;155(6):1908–1922.e5. doi:10.1053/j.gastro.2018.09.012
9. Wechalekar AD, Gillmore JD, Hawkins PN. Systemic amyloidosis. *Lancet*. 2016;387(10038):2641–2654. doi:10.1016/S0140-6736(15)01274-X
10. Leong RY, Nio K, Plumley L, Molmenti E, Klein JDS. Systemic amyloidosis causing intestinal hemorrhage and pseudo-obstruction. *J Surg Case Rep*. 2014;2014(9). doi:10.1093/jscr/rju087
11. Meira T, Sousa R, Cordeiro A, Ilgenfritz R, Borralho P. Intestinal amyloidosis in common variable immunodeficiency and rheumatoid arthritis. *Case Rep Gastrointest Med*. 2015;2015:405695. doi:10.1155/2015/405695

Journal of Inflammation Research

Dovepress

Publish your work in this journal

The Journal of Inflammation Research is an international, peer-reviewed open-access journal that welcomes laboratory and clinical findings on the molecular basis, cell biology and pharmacology of inflammation including original research, reviews, symposium reports, hypothesis formation and commentaries on: acute/chronic inflammation; mediators of inflammation; cellular processes; molecular mechanisms; pharmacology and novel anti-inflammatory drugs; clinical conditions involving inflammation. The manuscript management system is completely online and includes a very quick and fair peer-review system. Visit <http://www.dovepress.com/testimonials.php> to read real quotes from published authors.

Submit your manuscript here: <https://www.dovepress.com/journal-of-inflammation-research-journal>