

Systemic Thrombolysis for Isolated Splenic Vein Thrombosis Secondary to Oral Contraceptives: A Case Report

Qianqian Li*, Ran Wang *, Xingshun Qi 

Department of Gastroenterology, General Hospital of Northern Theater Command, Shenyang, People's Republic of China

*These authors contributed equally to this work

Correspondence: Xingshun Qi, Department of Gastroenterology, General Hospital of Northern Theater Command, No. 83 Wenhua Road, Shenyang, Liaoning Province, 110840, People's Republic of China, Tel +86-24-28897603, Fax +86-24-28851113, Email xingshunqi@126.com

Abstract: Isolated splenic vein thrombosis (ISVT) is a very rare venous thromboembolism in the absence of pancreatic diseases, which can cause acute abdominal pain and chronic left-side portal hypertension. Herein, we reported a 40-year-old female patient who developed ISVT after taking oral contraceptives. Anticoagulation with oral rivaroxaban was the first-line choice of therapy in this case. Since then, abdominal pain alleviated, but she did not achieve vessel recanalization. Thus, a 7-day systemic thrombolysis with urokinase was given. Abdominal pain disappeared, but ISVT was not significantly improved. During follow-up period, long-term anticoagulation with oral rivaroxaban was given. Collectively, this case indicates the possibility of oral contraceptives as a risk factor of ISVT as well as anticoagulation combined with systemic thrombolysis as a choice of treatment for ISVT. Certainly, long-term follow-up is necessary in this case.

Keywords: splenic vein thrombosis, oral contraceptives, anticoagulation, rivaroxaban, thrombolysis

Introduction

Portal vein system thrombosis, which refers to complete or partial thrombotic obstruction of the main portal vein and/or its branches with or without extension to splenic and superior mesenteric veins, has been increasingly recognized in clinical practice, due to its negative impact on the outcomes of patients.^{1,2} It is often associated with liver cirrhosis and abdominal malignancy.³ By comparison, isolated splenic vein thrombosis (ISVT) without involvement of portal vein and superior mesenteric vein is usually observed in patients with pancreatic diseases, especially pancreatitis and pancreatic cancer.^{4,5} This is because the splenic vein lies posterior to the pancreas and extends along the tail and neck. More than half of the patients with ISVT present with abdominal pain, followed by gastric variceal bleeding.¹ Splenectomy is often performed in the majority of ISVT patients.⁶ Notably, ISVT in the absence of pancreatic diseases has been rarely reported yet. Herein, we report a case of ISVT secondary to oral contraceptives (OCs) without a history of pancreatic diseases who received anticoagulation combined with systemic thrombolysis.

Case Presentation

A 40-year-old female patient presented with left abdominal pain accompanied by diarrhea for one week at our department on August 9, 2023. She did not have hematochezia. She had no history of serious comorbidities or pancreatic diseases but took oral contraceptives (drospirenone 3mg and ethinylestradiol 0.03mg) daily during the past three months. She has no history of smoking. Contrast-enhanced computer tomography (CECT) scans showed unenhanced lesions in the splenic vein, suggesting a diagnosis of ISVT (Figure 1A). Laboratory tests showed that D-dimer level was 2.02mg/L (reference range: 0.00–0.55mg/L). She had consulted with a vascular interventionalist before our admission, and was given oral rivaroxaban. After our admission, antithrombin III, plasma protein C activity, plasma protein S activity, kappa

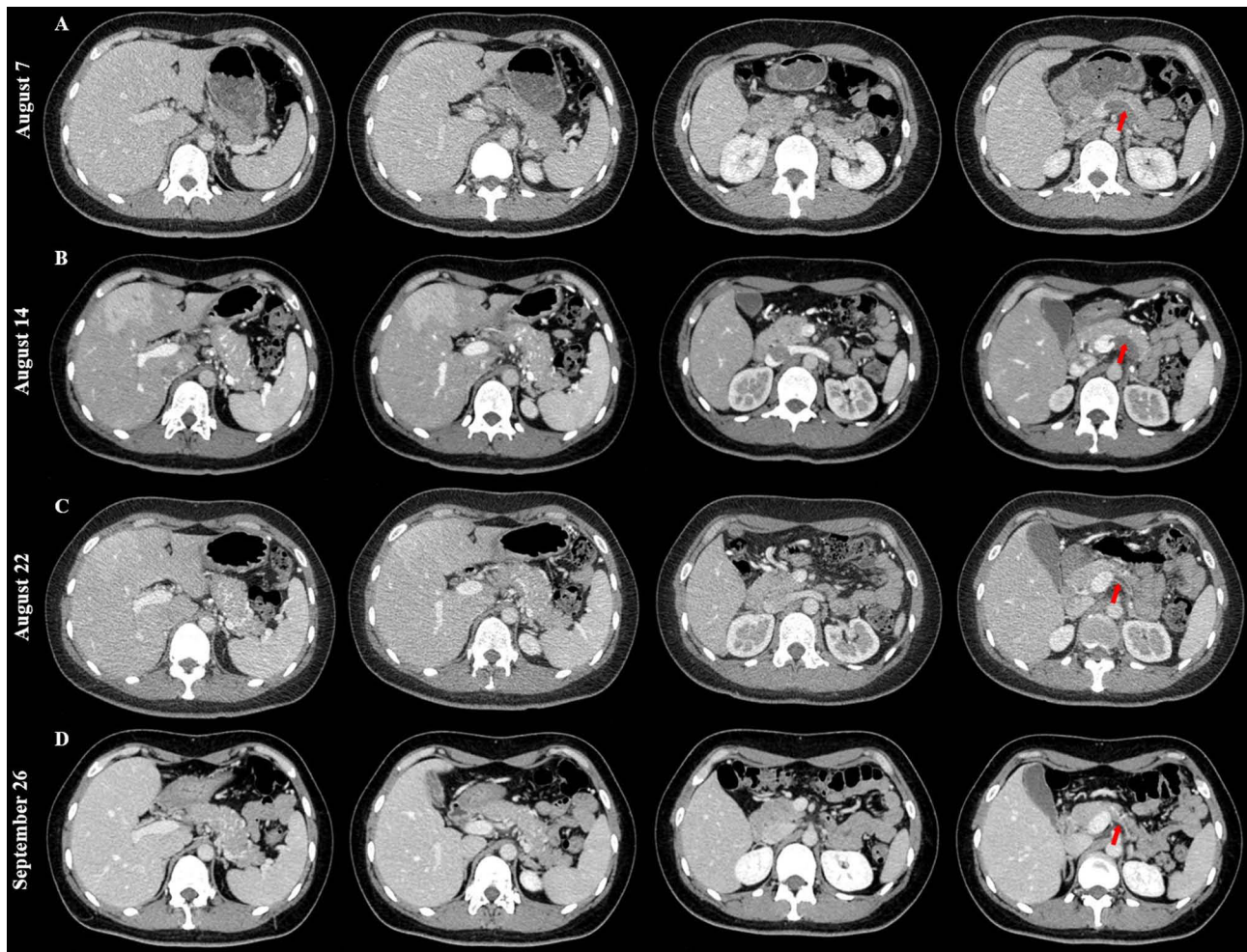


Figure 1 Contrast-enhanced CT images performed on August 7 (A), August 14 (B), August 22 (C), and September 26 (D) showing change of isolated splenic vein thrombosis (red arrow).

chain, lambda chain, antiphospholipid syndrome antibody, and thrombelastography (TEG) profile were within their reference ranges. Meanwhile, she continued to receive oral rivaroxaban. On August 11, 2023, she underwent upper gastrointestinal endoscopy showing superficial gastritis without gastroesophageal varices (Figure 2A and B). On

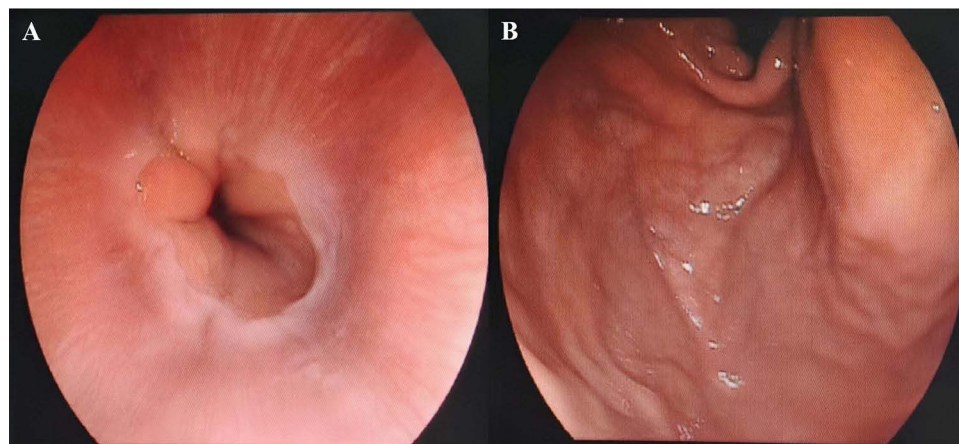


Figure 2 Upper gastrointestinal endoscopic images. There were no varices in the esophagus (A) or gastric fundus (B).

August 14, 2023, CECT scans were performed again, still showing low-density lesions in the proximal splenic vein (Figure 1B). Laboratory tests showed that D-dimer level was 1.06mg/L and R value was 4.6min (reference range: 5–10min). Plasminogen activator inhibitor type 1 gene test showed 4G/4G homozygous mutation. At this time, abdominal pain alleviated, but ISVT remained. Thus, she was informed about the efficacy and safety of thrombolysis. After that, she agreed to receive systemic thrombolysis with continuous intravenous injection of urokinase 500000u every 12 hours for a duration of 7 days. During the period of systemic thrombolysis, she did not develop any bleeding event. On August 22, 2023, abdominal pain disappeared, and CECT scans were repeated, showing a slight decrease in thrombus extension (Figure 1C). She was discharged with long-term use of oral rivaroxaban. On September 26, 2023, D-dimer level was 0.19mg/L, and CECT scans showed that the splenic vein became fibrotic cord (Figure 1D).

Discussion

At present, the data on ISVT are very scant. Thus, we have reviewed cases of ISVT or splenic vein occlusion in Table 1.^{5,7–44} Pancreatic diseases should be the most common risk factors associated with ISVT, followed by tumors, infections, and hematological diseases. A potential mechanism of ISVT is that inflammatory reaction and extravascular

Table 1 Reported Cases of Isolated Splenic Vein Thrombosis or Occlusion: An Overview

First Author (Country, Year)	Patient Age/Sex	Etiology	Symptoms	Diagnostic Method	Therapy
Sutton (USA, 1970) ⁷	40/M	Pancreatic pseudocyst, trauma	GIB	Splenic venogram	Splenectomy
Khan (USA, 1977) ⁸	39/M	Chronic pancreatitis	GIB	Angiography	Splenectomy
Bunt (USA, 1983) ⁹	45/M	Pancreatitis	GIB	Angiography	Splenectomy
Röder (NA, 1984) ¹⁰	51/NA	Pancreatic pseudocyst	GIB	Angiography	Splenectomy
	50/NA	Previous gastric surgery			
Madsen (NA, 1986) ¹¹	NA	NA	GIB	NA	Splenectomy
Singh (India, 1990) ¹²	NA	Tuberculosis	GIB, bowel obstruction	NA	Splenectomy, jejunal resection, antituberculous
Perišić-Savić (Yugoslavia, 1991) ¹³	31/F	Pregnant	Asymptomatic	Ultrasonography	Splenectomy
Møller (Denmark, 1997) ¹⁴	33/M	Pancreatic abscess	GIB	NA	Splenectomy
Tsuchida (Japan, 2003) ¹⁵	46/F	Distal pancreatectomy	Asymptomatic	Ultrasonography, angiography	Splenectomy
Köklü (Turkey, 2004) ¹⁶	26/F	Renal abscess	GIB, abdominal pain, fever, dyspnea	Ultrasonography, CECT	Splenectomy, nephrectomy
Joya Seijo (Spain, 2004) ¹⁷	46/NA	Renal-cell carcinoma	GIB	CECT	Splenectomy
Bilski (Poland, 2004) ¹⁸	61/F	Chronic pancreatitis	NA	NA	Splenectomy
Yamaguchi (Japan, 2005) ¹⁹	53/M	Pancreatic neuroendocrine tumor	GIB	CECT	Splenectomy, distal pancreatectomy, partial resection of gastric fundus, lymph node dissection
Hiraiwa (Japan, 2006) ²⁰	49/F	Colon cancer	Abdominal pain	CECT	Splenectomy, hemicolectomy, distal pancreatectomy
Liu (China, 2006) ²¹	42/M	Embolization of varices	Fever	Ultrasonography, CECT	Antibiotic
Hariharan (UK, 2006) ²²	64/M	Trauma	GIB	CECT	Refused any treatment
Allen (USA, 2007) ²³	49/F	Chronic pancreatitis	GIB	Angiography	Splenic artery embolization
Guler (Turkey, 2008) ²⁴	23/F	MTHFR C677T mutation	Abdominal pain	Ultrasonography	Low-molecular weight heparin, splenectomy, warfarin

(Continued)

Table I (Continued).

First Author (Country, Year)	Patient Age/Sex	Etiology	Symptoms	Diagnostic Method	Therapy
Tzur (Israel, 2008) ²⁵	46/M	Trauma, hyperhomocysteinemia	Chest pain	Magnetic resonance venography	Low-molecular weight heparin
Numora (Japan, 2009) ²⁶	39/F	Idiopathic	Abdominal pain	Autopsy	Transfusion without reporting other treatments
Karagiannis (Greece, 2012) ²⁷	70/F	Autoimmune hemolytic anemia	Abdominal pain, vomiting, nausea, constipation	CECT	Splenectomy
Chen (China, 2013) ²⁸	77/F	Lymphoma	GIB	CECT	Chemotherapy
Jain (India, 2014) ²⁹	16/F	Tuberculosis	Fever, dry cough, jaundice, vomiting	CECT	Low-molecular weight heparin, antituberculous
Köksal (Turkey, 2014) ³⁰	54/M	External compression	Fatigue, weight loss	CECT	Chemotherapy
Kiani (Iran, 2015) ³¹	8/M	Idiopathic	GIB	CECT	Splenectomy
Parekh (USA, 2015) ³²	47/M	Lymphoma	GIB, lightheadedness, dyspnea, weakness	CECT	Splenectomy, chemotherapy
Lenhart (USA, 2016) ³³	73/M	Lymphoma	GIB	MRI	Splenic artery embolization
Franco-Avilés (Spain, 2017) ³⁴	31/M	Pancreatic pseudocyst	GIB	Angiography	Splenectomy
Lupascu-Ursulescu (Romania, 2017) ³⁵	37/F	Pancreatic cyst	GIB	Ultrasonography, CECT	Splenectomy, pancreatectomy
Salazar-Mejía (Mexico, 2017) ³⁶	26/M	Testicular cancer	GIB	CECT	Chemotherapy
Patel (USA, 2019) ³⁷	65/M	Essential thrombocytosis	GIB	Splenic venogram	Splenic artery embolization
Hayashi (Japan, 2020) ³⁸	70/M	Idiopathic	Epigastric discomfort	CECT	Splenectomy
Park (Korea, 2021) ³⁹	23/F	Pancreatic desmoid type fibromatosis	Abdominal pain	CECT, MRI	Splenectomy, distal pancreatectomy
Zafar (UK, 2022) ⁵	64/M	Chronic pancreatitis	Chest pain	CECT	Heparin, apixaban
	71/M	Polycythemia rubra vera	Abdominal pain	CECT	Enoxaparin, rivaroxaban
Sikana (Indonesia, 2022) ⁴⁰	28/M	Liver cirrhosis, chronic pancreatitis	GIB Abdominal pain Ascites	CECT	Proton pump inhibitors, diuretics, octreotide, antibiotic
Capraro (USA, 2022) ⁴¹	13/F	Acute pancreatitis	Abdominal pain	CECT	Low-molecular weight heparin, rivaroxaban
Füssel (Austria, 2023) ⁴²	45/F	Chronic pancreatitis	GIB	Angiography	Balloon dilatation and stenting
Pak (Korea, 2023) ⁴³	69/M	NA	GIB	CECT, angiography	Splenectomy
	57/M	Chronic pancreatitis	GIB	CECT, angiography	Splenic artery embolization
García Soria (Spain, 2023) ⁴⁴	42/M	Pancreatic neuroendocrine tumor	GIB	CECT, endoscopic ultrasonography	Anticoagulation, splenectomy

Abbreviations: GIB, gastrointestinal bleeding; CECT, contrast-enhanced computed tomography; MRI, magnetic resonance imaging; NA, not available.

compression induce the injury of vascular endothelium, blood stasis, and hypercoagulability.^{4,42} Our case had no significant risk factors other than a history of OCs. OCs can produce von Willebrand factor, which plays an important role in platelet adhesion and activation through stimulation of endothelial cells. Besides, OCs also increase the levels of factors II, VII, VIII, and X and fibrinogen, and decrease the factor V level to influence the coagulation cascade. On the other hand, OCs decrease the levels of tissue factor pathway inhibitor, antithrombin, and total and free protein S.^{45,46} The

risk of venous thrombosis with OCs is higher in women who are older than 40 years, and increased from the 4th month of administration, especially in those receiving OCs for the first time.⁴⁷ Drospirenone, a novel contraceptive pill, in combination with ethinylestradiol, leads to an increased risk of venous thrombosis.⁴⁸ Like our case, Zhao et al also reported a young female treated with OCs at the same dosage who developed portal, superior mesenteric, and splenic vein thrombosis.⁴⁹ However, the location of splanchnic vein thrombosis in this case is completely different from ours.

Plasminogen activator inhibitor type 1 (PAI-1) gene mutation is theoretically associated with splanchnic vein thrombosis, since the binding of 4G allele to transcription activator is associated with high levels of PAI-1, which can inhibit the efficacy of tissue-type and urokinase-type plasminogen activator, and promote the development of venous thrombosis.^{50,51} However, the clinical evidence regarding association of PAI-1 gene mutation with splanchnic vein thrombosis is still insufficient and controversial.⁵²⁻⁵⁴ Notably, the thrombogenic effect of hypofibrinolysis status secondary to PAI-1 gene mutation can be synergistically amplified by the use of OCs.^{55,56} On the other hand, unfortunately, we did not screen JAK2V617F mutation which is a major risk factor of splanchnic vein thrombosis, but it should be acknowledged that higher platelet count and splenomegaly, both of which are closely related to JAK2V617F mutation,⁵⁷ were missing in our case.

Elevated D-dimer often indicates the probability of thrombosis.⁵⁸ Certainly, imaging tests are needed to clarify the diagnosis and further identify the location of thrombosis. CECT and angiography are preferred for a definitive diagnosis of ISVT. Splanchnic vein thrombosis often presents as low-density defect in the vascular lumen on the portal vein phase of CECT scans.⁵⁹ Ultrasound is a convenient diagnostic method for splanchnic vein thrombosis. Early stage of thrombosis may be echoless on ultrasound, and the echo gradually increases following fibrosis with or without blood flow.⁶⁰ Both ultrasound and CECT seem to be equally reliable in assessing the presence and severity of ISVT.⁶¹ However, CECT is more helpful to further distinguish the nature of thrombosis, considering that ISVT is a marker of occult cancer.^{62,63}

A few patients with ISVT are asymptomatic, but most patients with chronic ISVT often present with gastroesophageal variceal bleeding. Left-side portal hypertension occurs due to complete splenic vein obstruction.^{6,64} Endoscopic and drug hemostasis are usually ineffective, and splenectomy has to be performed. By comparison, patients with acute ISVT often present with abdominal pain but without varices on endoscopy. Our case should be diagnosed with acute ISVT and treated with anticoagulation and thrombolysis to prevent from portal hypertension-related complications in a timely fashion. However, she did not achieve splenic vein recanalization at the last visit. Accordingly, screening for gastroesophageal varices by endoscopy is very necessary in our case during follow-up period.

Guidelines recommend low molecular weight heparin and vitamin K antagonists as traditional choices for early anticoagulation.^{65,66} Anticoagulation can promote vascular recanalization and prevent thrombotic progression in patients with splanchnic vein thrombosis.^{67,68} Recently, direct-acting oral anticoagulants (DOACs) are increasingly employed.⁶⁶ Compared to traditional anticoagulants, patients' adherence to DOACs was better, because the method of its administration was convenient and close monitoring and dosage adjustment were not required. Besides, Ageno et al demonstrated that oral rivaroxaban was effective in patients with splanchnic vein thrombosis with a complete recanalization rate of 47.3%.⁶⁹ Naymagon et al also demonstrated that rivaroxaban, apixaban, and dabigatran had a higher rate of complete recanalization than warfarin in patients with portal vein thrombosis.⁷⁰ Anticoagulation seems to be promising for the treatment of ISVT but has been insufficiently explored. In our case, oral rivaroxaban did not contribute to complete vascular recanalization, but relieved abdominal discomfort to some extent.

Thrombolysis is recommended in the case of intestinal ischemia, especially if anticoagulation fails. Zhang et al demonstrated that thrombolysis had a higher rate of vascular recanalization and a shorter period of symptomatic improvement than anticoagulation in patients with splanchnic vein thrombosis.⁷¹ A systematic review and meta-analysis suggested that the rates of vascular recanalization and symptomatic improvement after thrombolysis in patients with portal vein thrombosis were 84% and 86%, respectively.⁷² To the best of our knowledge, our case should be the first one of ISVT receiving systemic thrombolysis. In our case, systemic thrombolysis relieved abdominal pain more significantly as compared to the use of anticoagulation alone. Unfortunately, vascular recanalization was not achieved, probably because we did not initiate thrombolysis as the first-line choice of treatment in this case. Additionally, we did not employ local thrombolysis via a catheter in the portal vein system or superior mesenteric artery, which might be more effective than systemic thrombolysis.^{73,74}

In conclusion, for patients who use OCs for the first time and need long-term maintenance, it should be appropriate to screen splanchnic vein thrombosis after the 3-month use of OCs. ISVT secondary to OCs is very rare in clinical practice, but this condition should be recognized. Its related chronic complications, such as left-side portal hypertension, should be closely screened

during follow-up period. Thrombolysis may be a choice of treatment for acute ISVT, but its efficacy and safety should be further validated in a large group of patients with ISVT.

Ethics Approval

Institutional approval for publication of the case details was not required in accordance with local institutional requirements.

Consent to Publish Statement

Written informed consent for publication of the case details was obtained from the patient.

Acknowledgment

Qianqian Li and Ran Wang are co-first authors for this study. The authors would like to acknowledge Professor Nahum Mendez-Sanchez for giving critical comments on this manuscript and Professor Hongyu Li for treating this case and giving critical comments on this manuscript.

Author Contributions

All authors made a significant contribution to the work reported, whether that is in the conception, study design, execution, acquisition of data, analysis and interpretation, or in all these areas; took part in drafting, revising or critically reviewing the article; gave final approval of the version to be published; have agreed on the journal to which the article has been submitted; and agree to be accountable for all aspects of the work.

Funding

This work was partially supported by National Natural Science Foundation of China (8227034094).

Disclosure

The authors report no conflicts of interest in this work.

References

1. Valeriani E, Riva N, Di Nisio M, Ageno W. Splanchnic vein thrombosis: current perspectives. *Vasc Health Risk Manag*. 2019;15:449–461. doi:10.2147/VHRM.S197732
2. Galante A, De Gottardi A. Portal vein thrombosis: an overview of current treatment options. *Acta Gastroenterol Belg*. 2021;84(2):327–332. doi:10.51821/84.2.327
3. Senzolo M, Garcia-Tsao G, Garcia-Pagan JC. Current knowledge and management of portal vein thrombosis in cirrhosis. *J Hepatol*. 2021;75(2):442–453. doi:10.1016/j.jhep.2021.04.029
4. Moossa AR, Gadd MA. Isolated splenic vein thrombosis. *World J Surg*. 1985;9(3):384–390. doi:10.1007/BF01655272
5. Zafar M, Heslop-Harrison W, Loterh L, Ofuafor K. Splenic vein thrombosis: a case series of consequential chronic pancreatitis and sequential myeloproliferative disorder. *Cureus*. 2022;14(6):e25924. doi:10.7759/cureus.25924
6. Akhondi H, Ganjali S, Nagalli S. Splanchnic venous thrombosis. *StatPearls*; 2023.
7. Sutton JP, Yarborough DY, Richards JT. Isolated splenic vein occlusion. Review of literature and report of an additional case. *Arch Surg*. 1970;100(5):623–626. doi:10.1001/archsurg.1970.01340230089024
8. Khan AH, O'Reilly CJ, Avakian VA, Lucina PA. Splenic vein thrombosis: an unusual case of gastric bleeding. *Angiology*. 1977;28(10):725–727. doi:10.1177/000331977702801010
9. Bunt TJ, Hackler MT, Greene FL. Isolated splenic vein thrombosis: the curable variceal hemorrhage. *South Med J*. 1983;76(7):936–938. doi:10.1097/00007611-198307000-00036
10. Roder OC. Splenic vein thrombosis with bleeding gastroesophageal varices. Reports of two splenectomized cases and review of the literature. *Acta Chir Scand*. 1984;150(3):265–268.
11. Madsen MS. Splenic vein obstruction: a cause of upper gastrointestinal bleeding. *Acta Chir Scand*. 1986;152:393–395.
12. Singh K, Zargar SA, Bhasin D, Malik AK, Nagi B, Bose SM. Isolated splenic vein thrombosis with natural shunt caused by jejunal tuberculosis. *Trop Gastroenterol*. 1990;11(1):39–43.
13. Perisic-Savic M, Colovic R, Milosavljevic T, Ivanovic L. Splenic vein thrombosis. Diagnosed with Doppler ultrasonography. *Hepatogastroenterology*. 1991;38(6):557–560.
14. Moller S, Bech K, Bendtsen F. Segmental "portal hypertension". A rare cause of severe tractable variceal bleeding. *Ugeskr Laeger*. 1997;159(17):2563–2565.
15. Tsuchida S, Ku Y, Fukumoto T, Tominaga M, Iwasaki T, Kuroda Y. Isolated gastric varices resulting from iatrogenic splenic vein occlusion: report of a case. *Surg Today*. 2003;33(7):542–544. doi:10.1007/s10595-002-2519-7

16. Koklu S, Koksal A, Yolcu OF, et al. Isolated splenic vein thrombosis: an unusual cause and review of the literature. *Can J Gastroenterol.* 2004;18(3):173–174. doi:10.1155/2004/801576
17. Joya Seijo MD, Del Valle Loarte P, Marco Martinez J, Herrera Merino N, Agud Aparicio JL. Sinistral portal hypertension with bleeding gastric varices as initial manifestation of renal-cell carcinoma. *An Med Interna.* 2004;21(6):283–284. doi:10.4321/s0212-71992004000600006
18. Bilski RA, Szczepanik AB. Isolated splenic vein thrombosis. *Wiad Lek.* 2004;57(11–12):697–698.
19. Yamaguchi T, Takahashi H, Kagawa R, et al. Nonfunctioning pancreatic endocrine tumor presenting with hemorrhage from isolated gastric varices. *Am Surg.* 2005;71(12):1027–1030. doi:10.1177/000313480507101208
20. Hiraiwa K, Morozumi K, Miyazaki H, et al. Isolated splenic vein thrombosis secondary to splenic metastasis: a case report. *World J Gastroenterol.* 2006;12(40):6561–6563. doi:10.3748/wjg.v12.i40.6561
21. Liu CH, Tsai FC, Liang PC, Lee CZ, Yang PM. Splenic vein thrombosis and Klebsiella pneumoniae septicemia after endoscopic gastric variceal obturation therapy with N-butyl-2-cyanoacrylate. *Gastrointest Endosc.* 2006;63(2):336–338. doi:10.1016/j.gie.2005.08.025
22. Hariharan D, Singhal R, Kinra S, Chilton A. Post traumatic intra thoracic spleen presenting with upper GI bleed!--a case report. *BMC Gastroenterol.* 2006;6(1):38. doi:10.1186/1471-230X-6-38
23. Allen LM, Behrens G, Patel NH, Ferral H. Splenic artery embolization and balloon occlusion retrograde alcohol embolization in a patient with bleeding gastric varices. *Semin Intervent Radiol.* 2007;24(1):53–57. doi:10.1055/s-2007-971186
24. Guler N, Yapici O, Erdem D, Ogur G, Ozatli D, Bakir T. Acute complete splenic infarction in a patient with Hirschsprung's disease and literature review of complete splenic infarction. *Pathophysiol Haemost Thromb.* 2008;36(2):102–104. doi:10.1159/000173730
25. Tzur I, Almozni-Sarafian D, Dotan E, et al. Splenic vein thrombosis following abdominal compression and vibration: a case report. *Angiology.* 2008;59(4):514–516. doi:10.1177/0003319707305403
26. Nomura T, Keira N, Urakabe Y, et al. Fatal splenic laceration in a young woman caused by idiopathic isolated splenic vein thrombosis. *Intern Med.* 2009;48(11):907–910. doi:10.2169/internalmedicine.48.1843
27. Karagiannis G, Anagnostara A, Samaras V, Mylona S. Isolated splenic vein thrombosis. *JBR-BTR.* 2012;95(2):105. doi:10.5334/jbr-btr.192
28. Chen BC, Wang HH, Lin YC, Shih YL, Chang WK, Hsieh TY. Isolated gastric variceal bleeding caused by splenic lymphoma-associated splenic vein occlusion. *World J Gastroenterol.* 2013;19(40):6939–6942. doi:10.3748/wjg.v19.i40.6939
29. Jain D, Verma K, Jain P. Disseminated tuberculosis causing isolated splenic vein thrombosis and multiple splenic abscesses. *Oxf Med Case Rep.* 2014;2014(6):107–109. doi:10.1093/omcr/omu042
30. Koksall AS, Kalkan IH, Torun S, Yuksel M, Okten RS, Kayacetin E. Isolated splenic vein thrombosis and splenic infarct due to external compression of enlarged lymph nodes in a patient with lymphoma. *Indian J Cancer.* 2014;51(4):586. doi:10.4103/0019-509X.175293
31. Kiani MA, Forouzan A, Masoumi K, et al. Isolated splenic vein thrombosis: 8-year-old boy with massive upper gastrointestinal bleeding and hypersplenism. *Case Rep Pediatr.* 2015;2015:480507. doi:10.1155/2015/480507
32. Parekh R, Walia S, Zalawadia A, Siddiqui Y. A rare case of splenic lymphoma in a patient with polymyositis manifesting as gastric variceal bleeding. *Clin J Gastroenterol.* 2015;8(2):92–96. doi:10.1007/s12328-015-0561-3
33. Lenhart A, Fernandez-Castillo J, Mullins K, Salgia R. A rare case of gastric variceal hemorrhage secondary to infiltrative B-cell lymphoma. *Case Rep Gastroenterol.* 2016;10(3):518–524. doi:10.1159/000445184
34. Franco-Aviles L, Hernandez-Rocha FI, Mercado U, Malvido-Torres CG. Segmental portal hypertension with splenic vein thrombosis caused by pancreatitis. *Rev Med Inst Mex Seguro Soc.* 2017;55(6):788–790.
35. Lupascu-Ursulescu C, Trofin AM, Zabara M, et al. Bleeding from isolated gastric varices as complication of a mucinous cystic neoplasm of the pancreas: a case report. *Medicine.* 2017;96(47):e8775. doi:10.1097/MD.00000000000008775
36. Salazar-Mejia CE, Hernandez-Barajas D, Llerena-Hernandez E, et al. Testicular cancer presenting as gastric variceal hemorrhage. *Case Rep Gastrointest Med.* 2017;2017:4510387. doi:10.1155/2017/4510387
37. Patel H, Bhandari P, Kumar K, Makker J, Chandrala C. Isolated gastric varices due to essential thrombocytosis related to splenic vein thrombosis: a challenge to uncover the concealed diagnosis. *Cureus.* 2019;11(11):e6068. doi:10.7759/cureus.6068
38. Hayashi H, Shimizu A, Motoyama H, et al. Left-sided portal hypertension caused by idiopathic splenic vein stenosis improved by splenectomy: a case report. *Surg Case Rep.* 2020;6(1):148. doi:10.1186/s40792-020-00912-y
39. Park CG, Lee YN, Kim WY. Desmoid type fibromatosis of the distal pancreas: a case report. *Ann Hepatobiliary Pancreat Surg.* 2021;25(2):276–282. doi:10.14701/ahbps.2021.25.2.276
40. Sikana AM, Thamrin H. Splenic vein thrombosis in cirrhosis of the liver: a rare case. *Ann Med Surg.* 2022;81:104439. doi:10.1016/j.amsu.2022.104439
41. Capraro S, Acquazzino M, Drake M, Dike CR. Successful treatment of splenic vein thrombosis secondary to acute pancreatitis with oral anticoagulants: a pediatric case series. *Am J Case Rep.* 2022;23:e937599. doi:10.12659/AJCR.937599
42. Fussel LM, Muller-Wille R, Dinkhauser P, Schauer W, Hofer H. Treatment of colonic varices and gastrointestinal bleeding by recanalization and stenting of splenic-vein-thrombosis: a case report and literature review. *World J Gastroenterol.* 2023;29(24):3922–3931. doi:10.3748/wjg.v29.i24.3922
43. Pak J, Lee S, Lee HN, Hyun D, Park SJ, Cho Y. Isolated gastric varix bleeding caused by splenic vein obstruction: two case reports. *J Korean Soc Radiol.* 2023;84(1):291–297. doi:10.3348/jksr.2022.0059
44. Garcia Soria A, Brotons Brotons A, Girona Torres E, et al. Gastric variceal bleeding as a form of presentation of pancreatic neuroendocrine tumor. *Rev Esp Enferm Dig.* 2023. doi:10.17235/reed.2023.9757/2023
45. Khialani D, Rosendaal F, Vlieg AVH. Hormonal contraceptives and the risk of venous thrombosis. *Semin Thromb Hemost.* 2020;46(8):865–871. doi:10.1055/s-0040-1715793
46. Abou-Ismaïl MY, Citla Sridhar D, Nayak L. Estrogen and thrombosis: a bench to bedside review. *Thromb Res.* 2020;192:40–51. doi:10.1016/j.thromres.2020.05.008
47. Gialeraki A, Valsami S, Pittaras T, Panayiotakopoulos G, Politou M. Oral contraceptives and HRT risk of thrombosis. *Clin Appl Thromb Hemost.* 2018;24(2):217–225. doi:10.1177/1076029616683802
48. Morimont L, Haguët H, Dogné JM, Gaspard U, Douxfils J. Combined oral contraceptives and venous thromboembolism: review and perspective to mitigate the risk. *Front Endocrinol.* 2021;12:769187. doi:10.3389/fendo.2021.769187
49. Zhao JW, Cui XH, Zhao WY, et al. Acute mesenteric ischemia secondary to oral contraceptive-induced portomesenteric and splenic vein thrombosis: a case report. *World J Clin Cases.* 2022;10(29):10629–10637. doi:10.12998/wjcc.v10.i29.10629

50. Zhang Q, Jin Y, Li X, et al. Plasminogen activator inhibitor-1 (PAI-1) 4G/5G promoter polymorphisms and risk of venous thromboembolism - a meta-analysis and systematic review. *Vasa*. 2020;49(2):141–146. doi:10.1024/0301-1526/a000839
51. Grubic N, Stegnar M, Peternel P, Kaider A, Binder BR. A novel G/A and the 4G/5G polymorphism within the promoter of the plasminogen activator inhibitor-1 gene in patients with deep vein thrombosis. *Thromb Res*. 1996;84(6):431–443. doi:10.1016/S0049-3848(96)00211-3
52. Prabhudesai A, Shetty S, Ghosh K, Kulkarni B. Investigation of Plasminogen Activator Inhibitor-1 (PAI-1) 4G/5G promoter polymorphism in Indian venous thrombosis patients: a case-control study. *Eur J Haematol*. 2017;99(3):249–254. doi:10.1111/ejh.12912
53. Kollabathula A, Sharma S, Kumar N, et al. Plasminogen activator inhibitor-1 4G/5G promoter polymorphism in adults with splanchnic vein thrombosis: a case-control study. *Indian J Hematol Blood Transfus*. 2022;38(1):169–172. doi:10.1007/s12288-021-01454-5
54. Balta G, Altay C, Gurgey A. PAI-1 gene 4G/5G genotype: a risk factor for thrombosis in vessels of internal organs. *Am J Hematol*. 2002;71(2):89–93. doi:10.1002/ajh.10192
55. Meltzer ME, Lisman T, Doggen CJ, de Groot PG, Rosendaal FR, Bounameaux H. Synergistic effects of hypofibrinolysis and genetic and acquired risk factors on the risk of a first venous thrombosis. *PLoS Med*. 2008;5(5):e97. doi:10.1371/journal.pmed.0050097
56. Lenicek Krleza J, Jakovljevic G, Bronic A, et al. Contraception-related deep venous thrombosis and pulmonary embolism in a 17-Year-old girl heterozygous for factor V Leiden, prothrombin G20210A mutation, MTHFR C677T and homozygous for PAI-1 mutation: report of a family with multiple genetic risk factors and review of the literature. *Pathophysiol Haemost Thromb*. 2010;37(1):24–29. doi:10.1159/000319051
57. Qi X, Zhang C, Han G, et al. Prevalence of the JAK2V617F mutation in Chinese patients with Budd-Chiari syndrome and portal vein thrombosis: a prospective study. *J Gastroenterol Hepatol*. 2012;27(6):1036–1043. doi:10.1111/j.1440-1746.2011.07040.x
58. Zheng J, Han M, Chen J, Deng MM, Luo G. Predictive value of D-dimer and fibrinogen degradation product for splanchnic vein thrombosis in patients with severe acute pancreatitis: a single-center retrospective study. *Scand J Gastroenterol*. 2023;58(10):1–7.
59. Lee HK, Park SJ, Yi BH, Yeon EK, Kim JH, Hong HS. Portal vein thrombosis: CT features. *Abdom Imaging*. 2008;33(1):72–79. doi:10.1007/s00261-007-9200-x
60. Abbitt PL. Portal vein thrombosis: imaging features and associated etiologies. *Curr Probl Diagn Radiol*. 1992;21(4):115–147. doi:10.1016/0363-0188(92)90036-F
61. Sturm L, Bettinger D, Klinger C, et al. Validation of color Doppler ultrasound and computed tomography in the radiologic assessment of non-malignant acute splanchnic vein thrombosis. *PLoS One*. 2021;16(12):e0261499. doi:10.1371/journal.pone.0261499
62. Sherman CB, Behr S, Dodge JL, Roberts JP, Yao FY, Mehta N. Distinguishing tumor from bland portal vein thrombus in liver transplant candidates with hepatocellular carcinoma: the A-VENA criteria. *Liver Transpl*. 2019;25(2):207–216. doi:10.1002/lt.25345
63. Sogaard KK, Farkas DK, Pedersen L, Sorensen HT. Splanchnic venous thrombosis is a marker of cancer and a prognostic factor for cancer survival. *Blood*. 2015;126(8):957–963. doi:10.1182/blood-2015-03-631119
64. Thatipelli MR, McBane RD, Hodge DO, Wysokinski WE. Survival and recurrence in patients with splanchnic vein thromboses. *Clin Gastroenterol Hepatol*. 2010;8(2):200–205. doi:10.1016/j.cgh.2009.09.019
65. de Franchis R, Bosch J, Garcia-Tsao G, Reiberger T, Ripoll C. Baveno VIII. baveno VII - renewing consensus in portal hypertension. *J Hepatol*. 2022;76(4):959–974. doi:10.1016/j.jhep.2021.12.022
66. Northup PG, Garcia-Pagan JC, Garcia-Tsao G, et al. Vascular liver disorders, portal vein thrombosis, and procedural bleeding in patients with liver disease: 2020 practice guidance by the American Association for the study of liver diseases. *Hepatology*. 2021;73(1):366–413. doi:10.1002/hep.31646
67. Valeriani E, Di Nisio M, Riva N, et al. Anticoagulant therapy for splanchnic vein thrombosis: a systematic review and meta-analysis. *Blood*. 2021;137(9):1233–1240. doi:10.1182/blood.2020006827
68. Wang L, Guo X, Xu X, et al. Anticoagulation favors thrombus recanalization and survival in patients with liver cirrhosis and portal vein thrombosis: results of a meta-analysis. *Adv Ther*. 2021;38(1):495–520. doi:10.1007/s12325-020-01550-4
69. Ageno W, Beyer Westendorf J, Contino L, et al. Rivaroxaban for the treatment of noncirrhotic splanchnic vein thrombosis: an interventional prospective cohort study. *Blood Adv*. 2022;6(12):3569–3578. doi:10.1182/bloodadvances.2022007397
70. Naymagon L, Tremblay D, Zubizarreta N, et al. The efficacy and safety of direct oral anticoagulants in noncirrhotic portal vein thrombosis. *Blood Adv*. 2020;4(4):655–666. doi:10.1182/bloodadvances.2019001310
71. Zhang Z, Gao L, Liu Z, et al. Catheter-directed thrombolysis versus systemic anticoagulation in the treatment of symptomatic splanchnic venous thrombosis secondary to acute pancreatitis: a retrospective cohort study. *BMC Surg*. 2023;23(1):199. doi:10.1186/s12893-023-02046-y
72. Cheng Q, Tree K. Systematic review of thrombolysis therapy in the management of non-cirrhosis-related portal vein thrombosis. *J Gastrointest Surg*. 2021;25(6):1579–1590. doi:10.1007/s11605-020-04624-4
73. Liu K, Li WD, Du XL, Li CL, Li XQ. Comparison of systemic thrombolysis versus indirect thrombolysis via the superior mesenteric artery in patients with acute portal vein thrombosis. *Ann Vasc Surg*. 2017;39:264–269. doi:10.1016/j.avsg.2016.06.029
74. Gao F, Wang L, Pan J, et al. Efficacy and safety of thrombolytic therapy for portal venous system thrombosis: a systematic review and meta-analysis. *J Intern Med*. 2023;293(2):212–227. doi:10.1111/joim.13575