


Correlation Analysis of Digital Mammography, Ultrasonography, and Pathologic Features in Pure Invasive Micropapillary Carcinoma of the Breast (PIMPC)

Xulei Sui¹, Peipei Feng¹, Xiaoyuan Sun¹, Peng Liang¹, Ying Liu², Guowei Zhang³

¹Department of Radiology, Yantaishan Hospital, Yantai City, 264001, People's Republic of China; ²Department of Pathology, Yantaishan Hospital (East Courtyard), Yantai City, 264003, People's Republic of China; ³Department of Radiology, Yantaishan Hospital (East Courtyard), Yantai City, 264003, People's Republic of China

Correspondence: Guowei Zhang, Department of Radiology, Yantaishan Hospital (East Courtyard), No. 10087 Keji Avenue, Laishan District, Yantai City, 264003, People's Republic of China, Tel +86-0535-6602048, Email zhangguoweiyt@163.com

Purpose: This study determined the digital mammography and ultrasonography imaging features of pure invasive micropapillary carcinoma of the breast (PIMPC) and the correlation with pathologic features.

Patients Methods: Nineteen patients diagnosed with PIMPC at Yantaishan Hospital from October 2015 to February 2022 were included in the study group. Forty patients with breast masses diagnosed as nonspecific invasive ductal carcinoma of the breast (NIDC) from July to December 2021 were included in the control group. Digital mammography and ultrasonography features were compared between the two groups.

Results: Patients with PIMPC had a younger age profile compared to patients with NIDC ($P=0.017$). Moreover, PIMPC masses were smaller than NIDC masses ($P=0.040$). Imaging features analysis revealed significant differences in age groups (<45 years: $\chi^2=5.971$, $P=0.044$) and the presence of spiculations or the crab claw sign ($\chi^2=8.583$, $P=0.004$) between patients with PIMPC and NIDC. However, there were no statistically significant differences in the presence of calcifications, blood flow grading, pathologic molecular subtypes between the study and control groups. The Ki-67 proliferative index ($\chi^2=1.052$, $P=0.389$), vascular invasion ($\chi^2=2.263$, $P=0.197$), and lymph node metastasis ($\chi^2=1.968$, $P=0.386$) showed no significant differences between PIMPC and NIDC patients.

Conclusion: PIMPC imaging features show specificity, such as tiny breast masses, spiculated edges, or crab claw-like patterns, and malignant signs appeared when the lesion was <2 cm in diameter. PIMPC mainly occurs in middle-aged women 45–59 y of age. Patients with PIMPC and NIDC of the breast are frequently associated with lymph node metastases and greater than one-half of the cases (74%) were shown to have a Ki-67 index >30%, suggesting a significant risk of recurrence and metastasis. Early therapeutic care for these patients is crucial. These results warrant further validation with additional samples from several centers due to the limited single-center sample size in the current study.

Keywords: pure invasive micropapillary breast carcinoma, digital mammography, ultrasonography, breast cancer, pathologic features

Background

Invasive micropapillary carcinoma (IMPC) is a unique subtype of invasive breast cancer (IDC). IMPC is characterized by a focal micropapillary growth pattern and accounts for 3–6% of IDCs.¹ Pure invasive micropapillary carcinoma of the breast (PIMPC) is a more specific form of IMPC. The term “pure” is used because >90% of the carcinoma consists of clusters of mulberry-like or glandular ductal or alveolar-like carcinoma cells. The incidence of PIMPC accounts for <2% of IDCs.^{2,3} The literature suggests that IMPC has aggressive biological behavior and a poor prognosis.⁴

IMPCs, which include the PIMPC subtype, exhibits distinct clinical imaging and pathologic features that can be detected using various imaging modalities. Mammography typically reveals irregular spiculated masses, microcalcifications,

and architectural distortion.⁵ Sonographic images frequently exhibit irregular shapes, hypoechoic structures, angular or spiculated margins, echogenic halos, and abnormal vascularity.⁶ Magnetic resonance imaging (MRI) frequently reveals masses with angular or spiculated borders, irregular or lobulated forms, heterogeneous interior enhancement, and type II or III washout kinetic curves. Molecular imaging approaches have shown that radiotracer uptake is mild-to-moderate in localized regions of IMPC lesions.⁵

The pathologic features of IMPCs include clusters of mulberry-like or glandular ductal/alveolar-like carcinoma cells. Immunohistochemistry analysis of IMPCs typically reveals high estrogen receptor positivity (90.5%), high progesterone receptor positivity (71.6%), and low HER-2 positivity (26.4%).⁵ These distinctive features, when detected through a combination of mammography, sonography, MRI, and molecular imaging, contribute to the accurate diagnosis and understanding of IMPCs and its subtypes.⁵

Based on mammographic studies, IMPCs tend to consist of high-density irregular or round solid masses.⁷ The most common sonographic finding in IMPCs is an irregular hypoechoic mass with spiculated margins and posterior acoustic shadowing.⁸ The most common MRI finding in IMPCs is an irregular mass with washout kinetics but diffuse heterogeneous non-mass-like enhancement throughout the breast has also been reported. Molecular breast imaging shows multicentric radiotracer uptake.⁸ Analysis of pathologic specimens shows angiolymphatic invasion in a significant number of cases. Axillary nodal metastases are present in the majority of patients, some of which have extranodal extension.⁸

Non-specific invasive ductal carcinoma of the breast (NIDC) refers to common subtype of IDC, including invasive ductal and lobular carcinomas. PIMPCs and NIDCs are subtypes of IDCs that exhibit similar image signs and symptoms.^{9,10}

In the current study the imaging and pathologic features of PIMPC and NIDCs were retrospectively analyzed.

Materials and Methods

Patient Data

A retrospective analysis of 19 patients diagnosed with PIMPCs based on pathologic examination at the Breast Surgery Department of Yantaishan Hospital from October 2015 to February 2022 was performed. The average age of patients with PIMPCs was 54.47±9.94 y, with a median age of 56 y (range, 36–71 y). The control group was comprised of 40 patients with NIDCs who presented with breast masses from July to December 2021. The average age for the control group was 60.80±8.86 y, with a median age of 61.5 y (range, 40–78 y). All patients were females with primary breast lesions and no distant metastases at the initial consultation. Among the 19 patients with PIMPCs, 1 had bilateral lesions, all of which were PIMPCs. Among the 40 patients with NIDCs, 1 had bilateral lesions, all of which were NIDCs. This study complied with the principles of the Declaration of Helsinki and was approved by the Ethics Medical Committee of Yantaishan Hospital on 18 October 2023 (No. LL-2023-126-L).

Instruments and Methods

Digital X-ray Imaging

A Siemens Mammomat Inspiration was used with a focus-film distance of 40 cm. The exposure conditions were automatically generated, ranging from a tube voltage of 26–35kVp and exposure dose of 75–160 mAs.

Color Doppler Ultrasonography

A Philips IU22 and ATL-5000 color ultrasound diagnostic instruments were used with a probe frequency of 7–12 MHz.

MRI Examination

A Siemens 3.0T Skyra magnetic resonance imaging system was used. A specialized breast coil was used. The sequences included axial TSET2WI-FS, 2D EPI-DWI, and 3D Flash-T1WI. Gadolinium-DTPA (Gd-DT) was injected at a dose of 0.2 mmol/kg and a rate of 2.0 mL/s, followed by an equal amount of normal saline. Dynamic contrast-enhanced scanning was performed at an interval of 90s and repeated 3–5 times. After scanning, automatic reconstruction was done and uploaded to the diagnostic workstation. The post-processing techniques included the maximum intensity projection (MIP), multi-planar reconstruction (MPR), and time-intensity curve (TIC).

Image Analysis

Breast X-ray and ultrasound images were jointly analyzed by two experienced radiologists with > 10 y of experience in breast imaging. The radiologists were blinded to the pathologic findings. Unanimous consensus was reached and detailed records were made following the 2013 version of BI-RADS,¹¹ as follows: tumor size was recorded for cases with lesions on the same side and the sum of the longest diameters was recorded; presence of calcifications; tumor margins (presence of spicules or crab claw-like patterns); and blood flow grading.

Ultrasound blood flow was graded according to Adler, as follows:¹² grade 0 indicated no blood flow signals within the mass; grade I indicated minimal blood flow, with 1–2 dot-like or fine rod-like tumor vessels visible; grade II indicated relatively abundant blood flow, with 3–4 dot-like vessels or 1 longer vessel penetrating the lesion, the length of which approached or exceeded one-half the radius of the mass; and grade III indicated rich blood flow. Grades 0–I were negative, whereas grades II–III were positive.

Pathologic Diagnosis Criteria

Based on the 2021 edition of the Chinese Anti-Cancer Association Breast Cancer Diagnosis and Treatment Guidelines,¹³ the study was conducted while considering the following factors: breast cancer molecular subtypes were categorized into four types (luminal A, luminal B, human epidermal growth factor receptor 2-positive [ERBB 2+], and triple-negative breast cancer [TNBC]); regional lymph node metastasis was classified as negative (0 nodes), 1–3 nodes, or ≥ 4 nodes; the Ki-67 proliferative index was classified as <30% and $\geq 30\%$ based on guideline-defined thresholds; and the presence or absence of vascular invasion.

Statistical Analysis

Statistical analysis was performed using SPSS 22.0 software. Age and tumor size were designated as continuous variables. Levene's test confirmed the homogeneity of variances and the data were normally distributed. The results are expressed as the mean \pm standard deviation (SD). Group comparisons were performed using t-tests. Age was further categorized into three groups for comparison. Categorical variables, including the presence or absence of calcifications, the presence or absence of spicules or a crab claw-like pattern at the tumor edge, ultrasound blood flow characteristics (negative or positive), pathologic molecular subtypes, the Ki-67 proliferation index, regional lymph node metastasis, and vascular invasion, were compared using a chi-square (χ^2) test or Fisher's exact probability test. A $P < 0.05$ was considered statistically significant for all analyses.

Results

Radiologic Findings

Age and Tumor Size

The age of onset and tumor size were compared between patients with PIMPCs and NIDCs using Levene's test. The F-values were 0.105 and 0.197, respectively, with corresponding P values of 0.747 and 0.659, indicating homogeneity of variances ($P > 0.05$) and a normal distribution. Among the 19 individuals in the PIMPC group, the average age was 54.47 years (± 9.94 y), while the 40 patients in the NIDC group had an average age of 60.80 years (± 8.86 y). The t -test demonstrated a significant age difference between the groups ($t = -2.46$, $P = 0.017$), indicating younger age in the PIMPC patients. The PIMPC masses averaged 2.09 cm (± 0.98 cm), whereas the NIDC masses averaged 2.62 cm (± 0.84 cm). The difference between the PIMPC and NIDC masses was significant ($t = -2.11$, $P = 0.040$), indicating smaller masses in the PIMPC group. These results underscore distinctions in both age and mass size between patients with PIMPC and NIDC (Table 1).

Age Group Comparison

Patients were grouped as follows: <45 y (young group); 45–59 y (middle-aged group); and ≥ 60 y (elderly group; Table 2). Significant differences were observed between the age groups ($\chi^2 = 5.971$, $P = 0.044$). In the PIMPC group, 3 patients were <45 y of age, 12 patients were between 45 and 59 y of age, and 4 patients were >60 y of age. In contrast, the NIDC group was comprised of 2 patients <45 y of age, 17 patients were between 45 and 59 y of age, and 21 patients were >60 y of age.

Table 1 Comparative Analysis of Age and Mass Size Between PIMPC and NIDC

Variables	PIMPC (N=19)	NIDC (N=40)	t	P
Age (y)	54.47±9.94	60.80±8.86	-2.46	0.017
Size of mass (cm)	2.09±0.98	2.62±0.84	-2.11	0.040

Abbreviations: PIMPC, pure invasive micropapillary carcinoma of the breast; NIDC, nonspecific invasive ductal carcinoma of the breast.

Table 2 Comparative Analysis of PIMPC and NIDC Imaging Manifestations

Imaging Features	PIMPC (N=19)	NIDC (N=40)	χ^2	P
Age (y)				
<45	3	2	5.971	0.044
45–59	12	17		
≥60	4	21		
Pure mass	13	26	0.067	0.797
Mass with calcifications	6	14		
With spiculations or the crab claw sign	17	20	8.583	0.004
Without spiculations	2	20		
No blood flow (score=0–1)	10	27	1.218	0.388
Blood flow present (score=2–3)	9	13		

Abbreviations: PIMPC, pure invasive micropapillary carcinoma of the breast; NIDC, nonspecific invasive ductal carcinoma of the breast.

Analysis of tumor characteristics revealed no significant differences in the presence of pure masses ($\chi^2 = 0.067$, $P=0.797$) or masses with calcifications. However, notable disparities were demonstrated in imaging features, such as spiculation or crab claw sign ($\chi^2 = 8.583$, $P=0.004$). Specifically, 17 patients in the PIMPC group exhibited these features, whereas 20 patients in the NIDC group showed similar manifestations. Furthermore, Doppler ultrasound assessment of blood flow was not significantly different between the groups. Ten PIMPC patients had no blood flow (score=0–1) compared to 27 NIDC patients. Nine PIMPC patients had blood flow (score=2–3) in contrast to 13 NIDC patients.

X-ray images of PIMPCs were significant for irregular tumor margins with spicules (Figure 1A) and ultrasound examinations revealed a crab claw-like pattern (Figure 1B), which were more common in PIMPCs ($P<0.05$, Table 2). No marginal infiltration, burr sign, or crab claw-like patterns were noted in the NIDC images (Figure 2A and B).

Pathologic Characteristics

The 19 PIMPC and 40 NIDC patients were pathologically classified into 4 molecular subtypes without a statistically significant difference ($\chi^2 = 3.887$, $P=0.272$): luminal A (PIMPC [n=4] vs NIDC [n=18]); luminal B (PIMPC [n=9] vs NIDC [n=1]); ERBB 2+ (PIMPC [n=5] vs NIDC [n=8]); and TNBC (PIMPC [n=1] vs NIDC [n=3]). The essential marker for cancer aggressiveness, the Ki-67 proliferative index, was not significantly different between the groups ($\chi^2 = 1.052$, $P=0.389$) for Ki-67 < 30% (PIMPC [n=5] vs NIDC [n=1]) or Ki-67 ≥ 30% (PIMPC [n=16] vs NIDC [n=24]). Additionally, 4 and 15 PIMPC patients presented with and without vascular invasion, respectively; 3 and 37 NIDC patients presented with and without vascular invasion, respectively ($\chi^2 = 2.263$, $p = 0.197$). The extent of regional lymph node metastasis in the PIMPC group (0, n=8; 1–3, n=9; ≥4, n=2) did not differ from the NIDC group (0, n=21; 1–3, n=18; ≥4, n=1; $\chi^2 = 1.968$, $P=0.386$). Therefore, the key pathologic features were similar between PIMPCs and NIDCs, underscoring the complexity of differentiating these breast cancer subtypes based on these parameters alone, which warrants further research for a comprehensive understanding of the unique pathologic profiles.

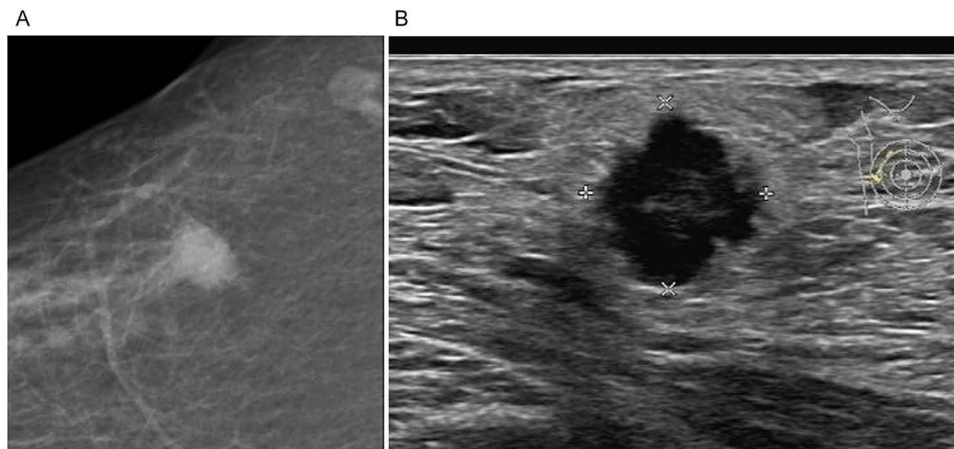


Figure 1 Image of a 65-year-old female patient in the PIMPC group. **(A)** The X-ray shows a high-density oval mass in the upper outer quadrant of the right breast with infiltrative margins and the burr sign. **(B)** The ultrasound shows a hypoechoic mass with uneven internal echoes and slightly reduced posterior echoes. The margin exhibits a crab claw-like pattern. The pathologic diagnosis was invasive micropapillary carcinoma of the right breast, 1.8 cm×1.5 cm×1.2 cm in size.

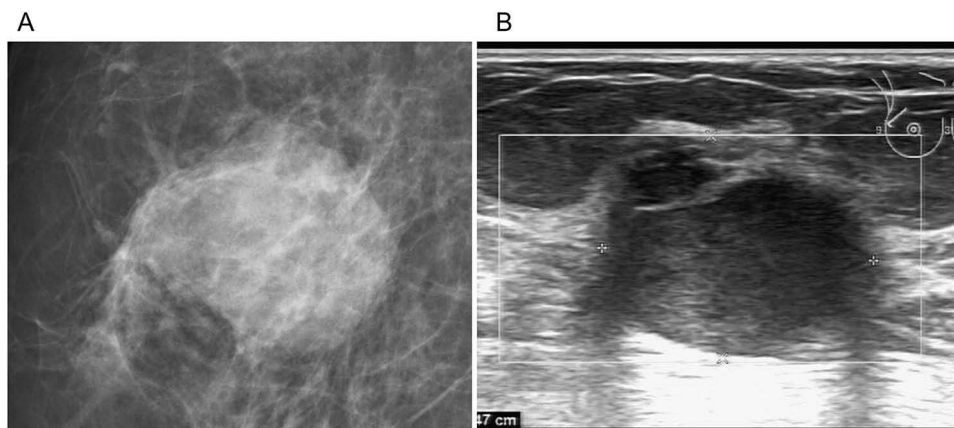


Figure 2 Image of a 72-year-old female patient. **(A)** The X-ray shows a high-density oval mass in the upper outer quadrant of the right breast with infiltrative margins and no burr sign. **(B)** The ultrasound shows a hypoechoic mass with uneven internal echoes and slightly reduced posterior echoes. The pathologic diagnosis was a non-specific invasive ductal carcinoma of the right breast (grade II), 2.8 cm×2.5 cm×2 cm in size.

Discussion

IMPCs were first identified and defined by Siriaunkgul in 1993.¹⁴ IMPCs represent a rare and distinct subtype of invasive breast cancer that are characterized by tumor cell cluster infiltration with micropapillary structures. When these structures account for > 90% of the tumor tissue upon microscopic examination, the tumor is diagnosed as a PIMPC. Recent studies have shown that IMPCs often co-exist with other types of invasive breast cancer. However, the literature pertaining to the imaging and pathologic characteristics of PIMPCs are limited. Therefore, PIMPCs and NIDCs were compared in the current study and the imaging and pathologic features of PIMPCs were summarized.

General Characteristics of PIMPCs

Patients with PIMPCs had a significantly lower age of onset compared to patients with NIDCs and were mainly concentrated in the middle-age group (40–59 y of age), which accounted for approximately 63.2% of all PIMPC patients. The tumor size in PIMPC patients was notably smaller than the tumor size in NIDC patients with an average size of 2.09 ±0.98 cm. This study emphasizes that when a breast lump is detected, benign signs might not be prominent. If the patient is relatively young and the tumor size is small, follow-up evaluations should be continued and the possibility of PIMPC should be considered.

X-Ray and Ultrasound Imaging Characteristics of PIMPCs

We showed that the imaging features of PIMPCs and NIDCs were similar. Specifically, the imaging features primarily manifested as lumps, occasionally accompanied by suspicious calcifications inside or outside the lump. The edges of the masses were often irregular, presenting as spiculated or blurred margins on X-ray and a crab claw-like pattern on ultrasound. This ultrasound feature was significantly more common in PIMPC patients than NIDC patient and was statistically significant. However, due to the influence of breast tissue overlap, observing the edges of the masses solely through mammography could lead to missed diagnoses or misdiagnoses. Therefore, it is advisable to combine ultrasound or digital breast tomosynthesis, and if available, consider breast MRI for an enhanced examination. The blood supply to the masses exhibited various patterns but no significant specificity.¹⁵ The blood supply to the masses exhibited four different patterns but there was no significant specificity.

Pathologic Features of PIMPCs

Our study showed that the pathologic manifestations of PIMPCs and NIDCs were consistent. There was no statistical difference in pathologic molecular typing, Ki-The Ki-67 proliferation index, the presence or absence of vascular invasion, and regional lymph node metastases. These findings are in contrast to some studies that concluded IMPCs have a poor prognosis, and high lymphatic invasion, high lymph node metastases, high recurrence, and high distant metastases rates.^{3,4,16} Based on our study we are of the opinion that in pure micropapillary breast carcinoma, because tumor cell clusters are surrounded by an empty matrix space, the range is limited, and vascular invasion is rare, the pathologic malignancy is close to non-specific breast cancer. However, as the proportion of micropapillary breast carcinomas decrease and the components of other invasive breast cancers increase, the destruction of the surrounding fibrous matrix leads to an expansion of the infiltration range of the tumor into adjacent tissues and the degree of malignancy increases accordingly. The occurrence of lymph node metastases in patients with PIMPCs is related to the following factors:^{17,18} ① PIMPC cells have microvilli structures on the surface, microvilli face the lesion interstitial side, and there are abundant filamentous structures inside the cancer cells, indicating that PIMPC cells have strong invasive ability. ② The binding ability of PIMPC cell surface microvilli to lesion stroma is weak and cancer cells detach easily. ③ There are a large number of vascular structures in PIMPC lesions, which makes it easy for cancer cells to metastasize through blood vessels. As a result, traits, including a poor prognosis, and high lymphatic invasion, high lymph node metastases, high recurrence, and high distant metastases rates are manifest. This finding is consistent with Chen et al who conducted matched control studies on breast IMPCs and reported that although the axillary lymph node metastasis rate of breast IMPCs is higher, the 5-year disease-free and 5-year overall survival periods are equivalent to NIDCs.¹⁹

We consider the Ki-67 index to be a risk factor for PIMPCs. The proportion of patients with a Ki-67 index $\geq 30\%$ was 14/19 (73.7%). The 2021 edition of the Chinese Anti-Cancer Association Breast Cancer Diagnosis and Treatment Guidelines and Standards¹³ concluded that compared to patients with a Ki-67 < 20%, as the level of Ki-67 expression increases, the risk ratio of early recurrence and metastasis increases.²⁰ This finding suggests that PIMPCs exhibit highly invasive biological behavior, which is related to the short recurrence-free period of IMPCs. However, because the tumor is relatively small, self-detection is unlikely, which delays the optimal treatment opportunity. Therefore, the primary tumor is only discovered when metastatic signs appear. Early detection and diagnosis of PIMPCs are of great significance to the treatment and prognosis of patients.

The treatment for PIMPCs typically includes surgery (lumpectomy or mastectomy) to remove the tumor, radiation therapy to kill remaining cancer cells, chemotherapy to destroy cancer cells, and hormone therapy if the cancer is hormone receptor-positive. Lymph nodes may also be removed. Targeted therapy specifically targets cancer cells and immunotherapy boosts the immune system against cancer. The treatment plan varies based on cancer stage, patient health status, and preferences.²¹

The survival rate for PIMPCs varies based on several factors. Early diagnosis generally leads to better outcomes and patients in good overall health tend to respond better to treatment. The type and effectiveness of treatments, including surgery, radiation, chemotherapy, hormone therapy, targeted therapy, and immunotherapy, have a crucial role in prognosis. Tumor characteristics, such as size and spread, as well as biological and genetic factors (hormone receptor or

HER2 status) impact prognosis. Additionally, patient age is a factor, with younger patients often having a better outlook. These elements collectively influence the survival rate for PIMPC patients.²²

There were a few limitations in this study. First, the study was a retrospective analysis with a small sample size in a single center without a lengthy follow-up period. Second, the definition of PIMPC varies among different research institutions, which may result in discrepancies in the research results. Finally, earlier cases lack imaging data, such as breast magnetic resonance enhancement examinations. We look forward to collecting more cases from different centers and discussing these issues with our peers in the future.

Conclusion

PIMPCs of the breast exhibit specific imaging characteristics. Digital X-ray and ultrasound imaging of PIMPCs show distinct features, mainly observed in middle-aged women (45–59 years old) with small breast lumps, irregular margins, or a crab claw-like pattern. Most cases are associated with lymph node metastases and greater than one-half of the patients have a Ki-67 index $\geq 30\%$, indicating a higher risk of recurrence and metastasis. These results need further validation with additional samples in multiple centers due to the limited single-center sample size in the current study.

Data Sharing Statement

The dataset analyzed during the current study is not publicly available but is available from the corresponding author upon reasonable request.

Ethics Approval and Consent to Participate

This study was conducted in accordance with the principles of the Declaration of Helsinki and was approved by the Ethics Medical Committee of Yantaishan Hospital on 18 October 2023 (No. LL-2023-126-L). Informed consent was obtained from all participants.

Funding

This study was supported by the Science and Technology Plan Projects of Yantai City (No. 2021YD036).

Disclosure

The authors declare no competing interests in this work.

References

1. Wedie AB, Tse Yang W. *DIAGNOSTIC Imaging: breast*. Beijing: People's Health Publishing House; 2018:733.
2. Tan PH, Ellis I, Allison K, et al. The 2019 World Health Organization classification of tumours of the breast. *Histopathology*. 2020;77(2):181–185. doi:10.1111/his.14091
3. Lewis GD, Xing Y, Haque W, et al. Prognosis of lymphotropic invasive micropapillary breast carcinoma analyzed by using data from the national cancer database. *Cancer Commun*. 2019;39(1):60. doi:10.1186/s40880-019-0406-4
4. Yang YL, Liu BB, Zhang X, Fu L. Invasive micropapillary carcinoma of the breast: an update. *Arch Pathol Lab Med*. 2016;140(8):799–805. doi:10.5858/arpa.2016-0040-RA
5. Nangong J, Cheng Z, Yu L, Zheng X, Ding G. Invasive micropapillary breast carcinoma: a retrospective study on the clinical imaging features and pathologic findings. *Front Surg*. 2022;9:1011773. doi:10.3389/fsurg.2022.1011773
6. Kim YR, Kim HS, Kim HW. Are irregular hypoechoic breast masses on ultrasound always malignancies?: A pictorial essay. *Korean J Radiol*. 2015;16(6):1266–1275. doi:10.3348/kjr.2015.16.6.1266
7. Verras GI, Tchabashvili L, Mulita F, et al. Micropapillary breast carcinoma: from molecular pathogenesis to prognosis. *Breast Cancer*. 2022;14:41–61. doi:10.2147/BCTT.S346301
8. Rones KN, Guimaraes LS, Reynolds CA, Ghosh K, Degnim AC, Glazebrook KN. Invasive micropapillary carcinoma of the breast: imaging features with clinical and pathologic correlation. *AJR Am J Roentgenol*. 2013;200(3):689–695. doi:10.2214/AJR.12.8512
9. Liu Y, Huang X, Bi R, Yang W, Shao Z. Similar prognoses for invasive micropapillary breast carcinoma and pure invasive ductal carcinoma: a retrospectively matched cohort study in China. *PLoS One*. 2014;9:9.
10. Abdel Hadi M, Al Muhanna A, Alratroot J, Shawarby MA. Angiocentric invasive ductal carcinoma: breast images. *Breast J*. 2020;26(2):295–296. doi:10.1111/tbj.13553
11. Magny SJ, Shikhman R, Keppke AL. Breast Imaging Reporting and Data System. In: *StatPearls*. Treasure Island (FL): StatPearls Publishing; 2023. Available from <https://www.ncbi.nlm.nih.gov/books/NBK459169/>. Accessed October 10, 2023.
12. Adler DD, Carson PL, Rubin JM, Quinn-Reid D. Doppler ultrasound color flow imaging in the study of breast cancer: preliminary findings. *Ultrasound Med Biol*. 1990;16(6):553–559. doi:10.1016/0301-5629(90)90020-D

13. Breast Cancer Specialized Committee of the Chinese Anti-Cancer Association. Chinese anti-cancer association breast cancer diagnosis and treatment guidelines and norms (2021 edition). *Chinese j Cancer*. 2021;31(10):954–1040.
14. Siriaunkgul S, Tavassoli FA. Invasive micropapillary carcinoma of the breast. *Mod Pathol*. 1993;6(6):660–662.
15. You X, Zheng H, Xu T. Analysis of the clinical value of ultrasonography and MRI in the diagnosis of invasive micropapillary carcinoma of the breast. *J Medical Imaging*. 2021;31(01):135–138.
16. Guo X, Chen L, Lang R, Fan Y, Zhang X, Fu L. Invasive micropapillary carcinoma of the breast: association of pathologic features with lymph node metastasis. *Am J Clin Pathol*. 2006;126(5):740–746. doi:10.1309/AXYY4AJTMNW6FRMW
17. Zhang XW, Wu AJ, Chen Y, et al. Clinicopathologic analysis of 16 cases of invasive micropapillary carcinoma of the breast. *Chin J Endoc Surg*. 2019;2019:(06):946–949.
18. Zhang SC, Lu S, Zhao ZW. Clinicopathologic features and prognostic analysis of invasive micropapillary carcinoma of the breast. *Chinese Cancer Clin*. 2020;47(02):77–81.
19. Chen L, Fan Y, Lang RG, et al. Breast carcinoma with micropapillary features: clinicopathologic study and long-term follow-up of 100 cases. *Int J Surg Pathol*. 2008;16:155–163. doi:10.1177/1066896907307047
20. Liu YP. Interpretation of the main content of the Ki-67 assessment update of the international breast cancer Ki-67 working group. *Chin J Pathol*. 2021;50(07):704–709.
21. Moo TA, Sanford R, Dang C, Morrow M. Overview of breast cancer therapy. *PET Clin*. 2018;13(3):339–354. doi:10.1016/j.cpet.2018.02.006
22. Mirhosseini SM, Fakhri M, Mozaffary A, et al. Risk factors affecting the survival rate in patients with symptomatic pericardial effusion undergoing surgical intervention. *Interact Cardiovasc Thorac Surg*. 2013;16(4):495–500. doi:10.1093/icvts/ivs491

Breast Cancer: Targets and Therapy

Dovepress

Publish your work in this journal

Breast Cancer - Targets and Therapy is an international, peer-reviewed open access journal focusing on breast cancer research, identification of therapeutic targets and the optimal use of preventative and integrated treatment interventions to achieve improved outcomes, enhanced survival and quality of life for the cancer patient. The manuscript management system is completely online and includes a very quick and fair peer-review system, which is all easy to use. Visit <http://www.dovepress.com/testimonials.php> to read real quotes from published authors.

Submit your manuscript here: <https://www.dovepress.com/breast-cancer—targets-and-therapy-journal>