

Lessons from Multiple Infections Such as Lymphoma Complicated with Pneumocystis Infection: A Case Report

Huaichong Wang¹, Yuying Lang¹, Xinjun Cai¹, Liuji Gao², Shengya Yang³, Jie Jin¹

¹Department of Pharmacy, Hangzhou Red Cross Hospital, Hangzhou, Zhejiang Province, People's Republic of China; ²Department of Oncology, Hangzhou Red Cross Hospital, Hangzhou, Zhejiang Province, People's Republic of China; ³Tuberculosis Diagnosis and Treatment Center, Hangzhou Red Cross Hospital, Hangzhou, Zhejiang Province, People's Republic of China

Correspondence: Jie Jin, Department of Pharmacy, Hangzhou Red Cross Hospital, East Huancheng Road No. 208, Hangzhou, Zhejiang Province, People's Republic of China, Email jinjie0916@163.com

Background: Lymphoma is complicated by intricate infections, notably *Pneumocystis jirovecii* pneumonia (PJP), marked by rapid progression, respiratory failure, and high mortality. Rapid diagnosis of PJP and effective administration of the first-line treatment trimethoprim-sulfamethoxazole (TMP-SMX) are important. For patients intolerant to TMP-SMX, selecting appropriate alternatives is challenging, necessitating careful decisions to optimize diagnosis and treatment. We present a lymphoma case complicated by PJP, illustrating medication adjustment until a positive response was observed.

Case Description: A 41-year-old male patient with lymphoma presented with a week-long history of fever, fatigue, cough, sputum, chest tightness, and exertional dyspnea, unresponsive to treatment. Routine laboratory examinations revealed no pathogenic bacteria. PJ and *Mycobacterium tuberculosis* (MTB) were detected in bronchoalveolar lavage fluid (BALF) using metagenomic next-generation sequencing (mNGS). On Day 1 of admission, meropenem, TMP-SMX, and rifampicin+isoniazid+levofloxacin were administered. However, the patient developed drug-induced hepatotoxicity and gastrointestinal adverse reactions after six days of treatment. After a multidisciplinary team discussion, anti-tuberculosis therapy was stopped because of insufficient evidence of tuberculosis infection. A reduced dose of TMP-SMX with micafungin was used for PJP; however, symptoms persisted and repeated computed tomography showed extensive deterioration of bilateral pulmonary plaques. The PJP regimen was modified to include a combination of TMP-SMX and caspofungin. Due to the high fever and elevated infection indices, the patient was treated with teicoplanin to enhance the anti-infection effects. By Day 13, the patient's temperature had normalized, and infection control was achieved by Day 30. CT revealed that the infection in both lung lobes fully resolved. Subsequently, lymphoma treatment commenced.

Conclusion: BALF-NGS facilitates early and rapid diagnosis of PJP. mNGS reads of MTB bacillus <5 may indicate a bacterial carrier state, warranting other detection techniques to support it. There is insufficient evidence for using TMP-SMX with micafungin to treat PJP; however, TMP-SMX combined with caspofungin is suitable.

Keywords: bronchoalveolar lavage fluid, metagenomic next-generation sequencing, *Pneumocystis jirovecii* pneumonia, *Mycobacterium tuberculosis*, trimethoprim-sulfamethoxazole

Introduction

Infectious diseases have a rapid onset and progression, and the causative agents in severe cases are complex, difficult to diagnose and treat, and can endanger lives. *Pneumocystis jirovecii* pneumonia (PJP) is caused by *Pneumocystis jirovecii* (PJ) infection, a life-threatening pulmonary infectious disease. When host immune function is low, especially when cellular immunity is impaired, PJ infection easily develops. High-risk populations include patients with human immunodeficiency virus (HIV) infection, hematopoietic malignancies (including leukemia, lymphoma, and multiple myeloma), solid tumors, inflammatory diseases, long-term glucocorticoid use, immunosuppression, and those who have undergone organ transplantation.^{1,2}

The accurate identification of PJ is critical,³ microscopic examination remains the gold standard for diagnosing PJP. However, immunofluorescence staining for PJ is not widely used in hospitals, and its diagnostic sensitivity is low. Newly developed technologies for molecular testing complement clinical diagnoses. Metagenomic next-generation sequencing (mNGS) detection technology does not rely on traditional microbial culture and directly conducts high-throughput sequencing of nucleic acids in clinical samples, promptly and objectively detecting various pathogenic microorganisms, significantly improving pathogen detection sensitivity, and has advantages in identifying the rare manifestations of common pathogen infections and diagnosing rare pathogen infections.⁴

Trimethoprim-sulfamethoxazole (TMP-SMX) is the first-line effective treatment for PJP. However, many patients cannot tolerate high doses due to adverse reactions affecting the digestive tract, kidneys, and liver. Additionally, the second-line treatment regimen cannot be effectively implemented due to the limited accessibility of drugs like primaquine, atovaquone, and pentamidine.

Therefore, the timely and accurate identification of PJ pathogens is crucial for diagnosing infection. Furthermore, selecting an appropriate alternative therapy is instrumental in improving the prognosis of PJP. Here, we report a case of severe PJP where the patient achieved eventual recovery after timely detection of the pathogen using bronchoalveolar lavage fluid (BALF)-NGS and subsequent adjustment of the treatment regimen in response to suboptimal initial therapy.

Case Presentation

A 41-year-old male patient with lymphoma had previously visited a local hospital and underwent bronchoscopy to examine the BALF. The routine microbiological examination did not detect any pathogenic bacteria; Gram staining did not show any bacteria; the culture did not show fungal growth; Grocott's methenamine (hexamine) silver technique did not show PJP cysts, and tuberculosis smears did not detect acid-fast bacteria. However, BALF-NGS found 5225 PJP reads and four *Mycobacterium tuberculosis* (MTB) reads. Due to the uncertainty regarding tuberculosis infection, he was transferred to our designated tuberculosis hospital for continued treatment.

The patient presented with relapsed refractory diffuse large B-cell lymphoma (R/RDLBCL) with MYC, BCL-2, and BCL-6 expression. After treatment with R-CHOP (rituximab, cyclophosphamide, doxorubicin, vincristine, and prednisone), R-GDP (rituximab, cisplatin, gemcitabine, and dexamethasone), venetoclax, obutinib, and immune checkpoint inhibitors were administered. The patient developed acute type 1 respiratory failure, severe pneumonia, PJP, cytomegalovirus retinitis, secondary immune deficiency, and secondary pulmonary tuberculosis.

The patient underwent a computed tomography (CT) examination after admission (Figure 1A), which indicated that two lung infections should be considered first. In addition, the immune response to MTB by T-cell receptor clustering was negative, and MTB complex from sputum samples, non-tuberculous mycobacterial DNA, and tuberculosis DNA and RNA were negative. Meropenem (1 g q8h) was administered for infection, TMP-SMX 1.44 g q6h for PJP, and rifampicin, isoniazid, and levofloxacin for tuberculosis. Simultaneously, methylprednisolone 40 mg q12h was administered to control inflammation. Ganciclovir was used as a prophylactic treatment for cytomegalovirus retinitis, and tiopronin was used for liver protection.

Unfortunately, the patient developed drug-induced liver injury after six days of treatment, with alanine transaminase (ALT) levels up to 269 U/L and aspartate aminotransferase (AST) levels up to 299 U/L. Due to the gastrointestinal reaction of nausea and vomiting combined with drug-induced liver injury, the patient could not tolerate high-intensity treatment, so the dose of TMP-SMX was reduced to 0.96 g q8h, combined with micafungin 0.2 g qd for PJP treatment. However, after four days of continued treatment, a reexamination CT scan indicated the progression of the infection (Figure 1B). The patient's high fever remained unrelieved, with a temperature as high as 40.4°C (see Figure 2 for the temperature trend chart) accompanied by shortness of breath and chest tightness. Blood gas analysis indicated type 2 respiratory failure and the arterial oxygen tension (PaO₂) decreased to 57 mmHg. Indicators of particularly abnormal laboratory tests, including levels of procalcitonin (PCT) 5.32 ng/mL, C-reactive protein (CRP) 167.53 mg/L, lactate dehydrogenase (LDH) 564 U/L, and white blood cell (WBC) count 2.7*10⁹/L, are shown in Table 1.

Based on the persistent fever, tachypnoea, PaO₂ of 57 mmHg, arterial oxygen saturation (SaO₂) of 89% at rest, and extensive interstitial shadowing on chest CT, the patient was classified as having severe PJP according to the PJP grade.⁵

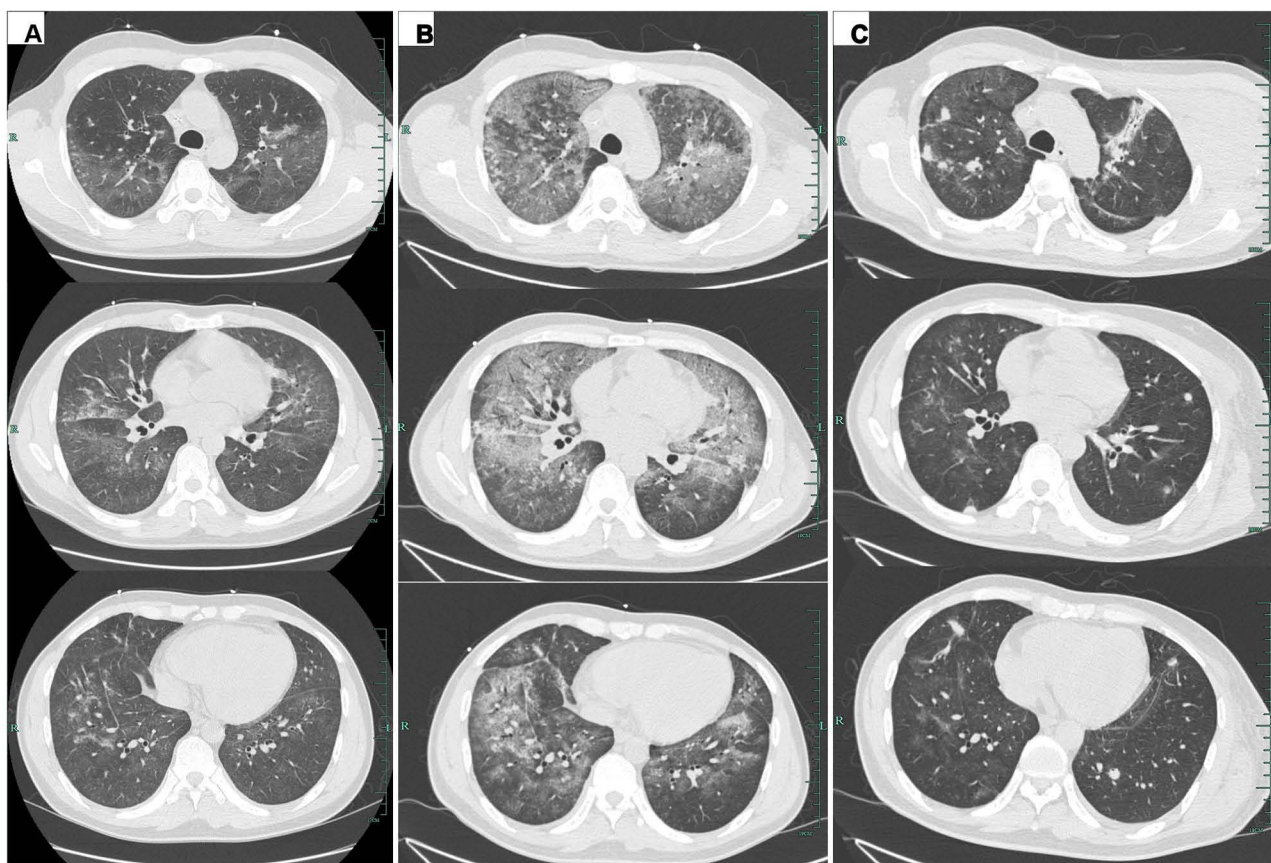


Figure 1 Serial chest CT scans at D1, D10, and D30 during the anti-infection period: **(A)** the initial CT scan at D1 showed an increased texture of both lungs increased, with multiple slight exudations and a small pleural effusion; **(B)** CT scan on D10 after admission revealed multiple progressive patchy shadows on both lungs, with ground-glass opacities and inflammatory exudates; **(C)** the follow-up CT scan on D30 after admission showed resolution of the bilateral diffuse patchy shadows, and increased multiple nodules increased in both lungs, with no pleural effusion. CT, computed tomography.

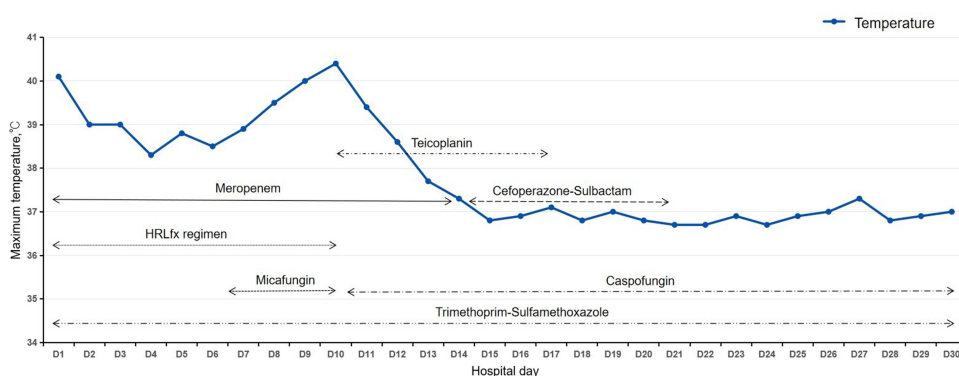


Figure 2 Temperature trend chart and anti-infection summary during the hospital stay. Trimethoprim-sulfamethoxazole (TMP-SMX) 1.44 g qid (D1–D6) and 0.96 g qid (D7–D30), micafungin 0.2 g qd (D7–D10), caspofungin 50 mg qd (D11–D30), HRLfx (D1–D10) [R(rifampicin) 0.6 g qd, H(isoniazid) 0.3 g qd and Lfx(levofloxacin) 0.5 g qd], meropenem 1 g q8h (D1–D14), cefoperazone-sulbactam 2 g q8h (D15–D21) and teicoplanin 400 mg qd (D10–D17).

Therefore, the treatment regimen for PJP was adjusted to TMP-SMX 0.96 g q6h + caspofungin 50 mg qd, while teicoplanin 0.4 g q12h was added to enhance the anti-infection effect.

After a multidisciplinary team discussion, the anti-tuberculosis drugs were discontinued because MTB was considered a non-pathogenic bacterium. Leukocyte and platelet-ascending drugs were used, human immunoglobulin was added, and nutrition was improved.

Table 1 Changes in the Main Indices During the Anti-Infection Period

Date	CRP mg/L	PCT ng/mL	WBC 10 ⁹ /L	LDH U/L	ALT U/L
D1	30.46	0.28	3.6	860	38
D3			3.3		
D4	63.34			546	78
D5			3.4		
D6	117.51	0.39		474	269
D8			3.0		
D10	167.53	5.32	2.7	564	139
D12	121.6	1.8	3.1	463	88
D15	30.3	0.39		487	52

Abbreviations: CRP, C-reactive protein; PCT, procalcitonin; WBC, white blood cell; LDH, lactate dehydrogenase; ALT, alanine aminotransferase.

After four days of treatment for multiple infections, the patient's temperature decreased to 37°C, and acute infection indicators improved (PCT 0.39 ng/mL, CRP 30.30 mg/L). Anti-infection de-escalation therapy consisted of cefoperazone and sulbactam 3 g q8h. PJP treatment continued for 30 days, and pulmonary infection lesions were completely relieved (Figure 1C). TMP-SMX 0.96 g qd was continuously administered as a PJP prophylactic therapy. The patient then began treatment for the lymphoma.

Discussion

PJP progresses rapidly, is often complicated by respiratory failure, and has a high fatality rate, posing challenges for clinical diagnosis and treatment. It is crucial to identify pathogenic microorganisms as soon as possible to detect an infection. The mNGS detection technology does not rely on traditional microbial culture. It performs high-throughput sequencing of nucleic acids directly in clinical samples, which can quickly and objectively detect various pathogenic microorganisms, significantly enhancing sensitivity. It has advantages in terms of rare manifestations and the ability to diagnose common pathogenic bacterial infections. PJ was not found in the patient's routine examination, and PJ reads of 5225 were found via BALF-NGS, which provided a basis for accurate treatment.

Jiang et al⁶ found that among the diagnostic methods for PJP, the sensitivity of mNGS was 100%, whereas the sensitivities of Grocott's methenamine silver staining and serum (1,3)-beta-D-glucan were 25.0% and 67.4%, respectively, showing obvious advantages. An mNGS-positive case accompanied by two of the following four clinical manifestations (dyspnea, fever, dry cough, and hypoxemia) and typical imaging features confirmed the clinical diagnosis of PJP.^{2,7} The patient met all these conditions, and the clinical diagnosis of PJP was clear.

Although the detection sensitivity of mNGS is high, pathogens are usually diverse and complex, and it remains challenging to distinguish colonization from infection using mNGS. If the detection threshold for mNGS can be determined, more accurate information can be provided to clinicians.

Four MTB reads were identified in the patient, complicating the distinction between latent and infected reads and making treatment challenging. Due to the abundant lipids in the cell walls of mycobacteria, the efficiency of nucleic acid extraction is low, which may lead to a reduced number of MTB reads, and mNGS positivity is usually of clinical significance. The Clinical Microbiology Group of the Chinese Society of Laboratory Medicine suggests that other TB detection techniques should be supported if the BALF sequence number is less than five.⁸ With 5–10 sequences, the diagnosis of tuberculosis can be supported by evaluating the patient's symptoms, disease course, and other clinical manifestations. The patient's condition progressed rapidly and combining imaging examination and clinical manifestations could not completely rule out the possibility of tuberculosis infection; therefore, we administered anti-tuberculosis treatment at an early stage. The multidisciplinary team considered that the mNGS reads were only four, and other evidence of tuberculosis bacteria detection was negative, combined with the lack of improvement in lung imaging and the patient's clinical symptoms. Hence, it was concluded that tuberculosis bacteria were not the patient's pathogen. Therefore, anti-tuberculosis therapy was promptly discontinued.

The first-line treatment for PJP is TMP-SMX, with standard dosages of TMP 15–20 mg/kg/d, q6h or q8h. However, it cannot be used in sufficient amounts due to drug-induced liver injury and gastrointestinal reactions. Alternative drugs like pentamidine, primaquine + clindamycin, dapsone + TMP, and atovaquone are either unavailable or have a high recurrence rate. A reduced dose of TMP/SMX + micafungin was administered. However, the symptoms did not improve after four days of treatment, which may be related to the absence of other pathogens, insufficient clinical evidence for micafungin in PJP treatment, and reduced doses of TMP-SMX.⁵ Therefore, we adjusted the treatment plan to TMP/SMX + caspofungin, enhanced the treatment of positive bacteria, and achieved positive outcomes.

TMP-SMX, combined with a synthetic anti-infective preparation, acts by inhibiting dihydrofolate synthetase and reductase and is the drug of choice for the treatment and prevention of PJ infection. The oral bioavailability of TMP-SMX exceeds 90%, but gastrointestinal intolerance and other factors may lead to ineffectiveness due to the inability to absorb appropriate drug doses. For higher C(max) and drug exposure,⁹ TMP-SMX injection is recommended for moderate to severe PJP, especially when the PaO₂ is <70 mmHg. However, it is difficult to purchase TMP-SMX injections in China.

Echinocandins offer significant benefits by reducing the inflammatory response associated with β -1, 3-glucan, and accelerating pathogen clearance, as they act more rapidly than TMP-SMX. Echinocandins inhibit the synthesis of 1, 3-glucan by acting on 1, 3-glucan synthetase, promoting cyst lysis and inhibiting new cyst formation. However, echinocandins are ineffective against PJ trophozoites. Therefore, echinocandins cannot be used alone for the treatment of PJP and must be combined with TMP-SMX. In addition, Melanie et al¹⁰ found that there were differences in the efficacy of echinocandins on PJP and that caspofungin and anidulafungin were significantly better than micafungin in reducing cysts, which may be the reason for the poor effect of micafungin. Therefore, we recommend caspofungin over micafungin for PJP treatment when echinocandins are combined with TMP-SMX.

Unfortunately, due to the rapid progression of infection and the poor physical condition of the patient, we did not conduct an etiological examination including NGS again when the initial treatment was ineffective. Regarding the treatment of PJP, there are currently no recommendations on whether caspofungin can be replaced by micafungin in the combination regimen including TMP-SMX. This aspect needs to be verified by further studies.

Conclusions

In patients with lymphoma with unexplained infections, BALF-NGS can be used to rapidly identify atypical pathogens and promote precise treatment with anti-infective medications. For various pathogens tested using mNGS, the breakpoint of the sequence number, combined with other examinations, helps determine colonization, latency, or infection. This case emphasizes the importance of timely diagnosis and accurate treatment for severe PJ infections, which can ensure optimal management of tumor progression.

Data Sharing Statement

Data will be provided by the corresponding author upon reasonable request.

Ethics Approval and Consent to Participate

This study was supported by the Ethics Committee of Hangzhou Red Cross Hospital (No.: 2023YS018) and was carried out in accordance with the ethical standards of the Declaration of Helsinki.

Consent Statement

Written informed consent was obtained from the patient and his immediate family members for the publication of any potentially identifiable images or data included in this case report prior to inclusion.

Acknowledgments

The authors thank all the clinical staff who contributed to the study.

Author Contributions

All authors made a significant contribution to the work reported, whether that is in the conception, study design, execution, acquisition of data, analysis and interpretation, or in all these areas; took part in drafting, revising or critically reviewing the article; gave final approval of the version to be published; have agreed on the journal to which the article has been submitted; and agree to be accountable for all aspects of the work.

Funding

This research was supported by the Hangzhou Biomedicine and Health Industry Development Project (No. 2022WJC210), and the Zhejiang Province Traditional Chinese Medicine Science and Technology Plan Project (No. 2021ZB214).

Disclosure

All authors declare that the research is conducted in the absence of any commercial relations or financial relationships of interest that might be a constant source of interest.

References

1. Azoulay E, Roux A, Vincent F, et al. A multivariable prediction model for *Pneumocystis jirovecii* pneumonia in hematology patients with acute respiratory failure. *Am J Respir Crit Care Med*. 2018;198(12):1519–1526. doi:10.1164/rccm.201712-2452OC
2. Donnelly JP, Chen SC, Kauffman CA, et al. Revision and update of the consensus definitions of invasive fungal disease from the European Organization for Research and Treatment of Cancer and the Mycoses Study Group Education and Research Consortium. *Clin Infect Dis*. 2020;71(6):1367–1376. doi:10.1093/cid/ciz1008
3. Giacobbe DR, Dettori S, Di Pilato V, et al. *Pneumocystis jirovecii* pneumonia in intensive care units: a multicenter study by ESGCIP and EFISG. *Crit Care*. 2023;27(1):323. doi:10.1186/s13054-023-04608-1
4. Li N, Cai Q, Miao Q, et al. High-throughput metagenomics for identification of pathogens in the clinical settings. *Small Methods*. 2021;5(1):2000792. doi:10.1002/smt.202000792
5. Maschmeyer G, Helweg-Larsen J, Pagano L, et al. ECIL guidelines for treatment of *Pneumocystis jirovecii* pneumonia in non-HIV-infected haematology patients. *J Antimicrob Chemother*. 2016;71(9):2405–2413. doi:10.1093/jac/dkw158
6. Jiang J, Bai L, Yang W, et al. Metagenomic next-generation sequencing for the diagnosis of *pneumocystis jirovecii* pneumonia in non-HIV-infected patients: a retrospective study. *Infect Dis Ther*. 2021;10(3):1733–1745. doi:10.1007/s40121-021-00482-y
7. Bassetti M, Azoulay E, Kullberg BJ, et al. EORTC/MSGERC definitions of invasive fungal diseases: summary of activities of the Intensive Care Unit working group. *Clin Infect Dis*. 2021;72(suppl 2):S121–S127. doi:10.1093/cid/ciaa1751
8. Clinical microbiology group of Chinese society of laboratory medicine, clinical microbiology group of Chinese Society of Microbiology and Immunology, society of clinical microbiology and infection of China international exchange and promotion association for medical and healthcare. Chinese expert consensus on metagenomics next-generation sequencing application on pathogen detection of infectious diseases. *Chin J Lab Med*. 2021;44(2):107–120. doi:10.3760/cma.j.cn114452-20201026-00794
9. Grose WE, Bodey GP, Loo TL. Clinical pharmacology of intravenously administered trimethoprim-sulfamethoxazole. *Antimicrob Agents Chemother*. 1979;15(3):447–451. doi:10.1128/AAC.15.3.447
10. Cushion MT, Linke MJ, Ashbaugh A, et al. Echinocandin treatment of *pneumocystis* pneumonia in rodent models depletes cysts leaving trophic burdens that cannot transmit the infection. *PLoS One*. 2010;5(1):e8524. doi:10.1371/journal.pone.0008524

Infection and Drug Resistance

Dovepress

Publish your work in this journal

Infection and Drug Resistance is an international, peer-reviewed open-access journal that focuses on the optimal treatment of infection (bacterial, fungal and viral) and the development and institution of preventive strategies to minimize the development and spread of resistance. The journal is specifically concerned with the epidemiology of antibiotic resistance and the mechanisms of resistance development and diffusion in both hospitals and the community. The manuscript management system is completely online and includes a very quick and fair peer-review system, which is all easy to use. Visit <http://www.dovepress.com/testimonials.php> to read real quotes from published authors.

Submit your manuscript here: <https://www.dovepress.com/infection-and-drug-resistance-journal>