


Multi-Organ Dysfunction Due to Envenoming Syndrome Following a Massive Bee Attack: A Fatal Case Study and Comprehensive Literature Review

Ubah Mumin Ali Osman¹, Selim Turfan¹, Mohamed Farah Yusuf Mohamud ¹⁻⁴

¹Emergency Department, Mogadishu Somali Turkey Training and Research Hospital, Mogadishu, Somalia; ²Somalia Society for Emergency Medicine (SOSEM), Mogadishu, Somalia; ³Tayo Institute for Health, Research, and Development, Mogadishu, Somalia; ⁴Faculty of Medicine, Mogadishu University, Mogadishu, Somalia

Correspondence: Mohamed Farah Yusuf Mohamud, Emergency Department, Mogadishu Somali Turkey Training and Research Hospital, Hawa-Abdi Street, Hodan District, Mogadishu, Somalia, Tel +252615591689, Email m.qadar59@gmail.com

Abstract: Honeybee bites are a common public health hazard, the incidence of which is gradually increasing. A bee sting incident involving more than fifty stings is categorized as massive envenomation. The clinical manifestations of honey bee stings can range from localized symptoms to severe allergic and systemic reactions. This case study presents a 60-year-old male who experienced multi-organ failure following a severe bee sting incident. According to our research, this is the first documented instance in Somalia of multi-organ failure resulting from a sting by a giant honey bee. The case highlights the potential severity of bee stings, which, while often considered minor, can lead to serious medical complications. Interestingly, despite the patient suffering numerous stings and receiving a substantial amount of venom, an immediate anaphylactic reaction did not occur. Instead, a delayed severe response leading to multi-organ failure emerged within 48 hours of the incident.

Keywords: Honey bee, multi-organ failure, acute kidney injury, acute liver injury, pancreatitis, pulmonary odema

Introduction

Bites and stings from arthropods have the potential to cause harm, trigger allergic reactions, and spread infectious diseases.¹ Hymenoptera order members are particularly important because of being nearly ubiquitous in the nature. Apidae (honeybees and bumblebees), Vespidae (hornets, wasps, and yellow jackets), and Formicidae (ants) are the three families into which hymenopterans are often divided.² Honeybee bites are a common public health hazard, the incidence of which is gradually increasing. The species of bees primarily responsible for human stinging incidents include *Apis mellifera mellifera* (*A. m. mellifera*), *A. m. ligustica*, and *A. m. Scutellata*.³ A bee sting incident involving more than fifty stings is categorized as massive envenomation.⁴ The clinical manifestations of honey bee stings can range from localized symptoms to severe allergic and systemic reactions.⁵ Localized reactions typically include redness, swelling, and pain, while allergic reactions triggered by IgE can lead to urticaria, angioedema, breathing difficulties, acute kidney injury (AKI), and potentially life-threatening anaphylactic shock.⁵

Here we report, a patient, who had no known allergies, experienced a severe systemic reaction after being stung by a swarm of bees. This led to the development of multiorgan dysfunction, a complex and life-threatening condition. The case highlights the potential severity of bee stings, which, while often considered minor, can lead to serious medical complications. It also sheds light on the challenges of managing such cases in Somalia, a region with limited medical resources and data.

Case Report

A 50-year-old male from southern rural area of Somalia came to emergency room with no chronic disease complaining oliguria and shortness of breath for six days. The patient had suffered a severe honeybee sting a week earlier during honey harvesting, leading to a generalized body edema, puffy eyes, respiratory distress, altered mental status. Due to a lack of immediate healthcare facilities in his local area, it took a week for him to be transferred to the hospital in Mogadishu for further treatment. At the time of his arrival at the emergency department of Mogadishu Somali Turkey Training and Research Hospital, the patient was conscious and oriented but was noted to have multiple erythematous skin lesions across his body (Figure 1). Her vital sign; the blood pressure was 160/90, pulse was 98, temperature was 36.5c, and rapid blood sugar test was 108mg/dl. This presentation necessitated an immediate and thorough medical assessment to address the complications arising from the honeybee sting and his subsequent symptoms. Due to the patient's delayed presentation at the hospital, immediate and comprehensive laboratory investigations were essential. The lab results revealed several critical conditions included: markedly elevated levels of creatinine (13.8 mg/dl) and urea (343 mg/dl) with moderate metabolic acidosis pointed towards acute kidney injury, significantly high levels of AST (540 U/L) and ALT (692 U/L) indicated acute liver injury, and elevated amylase (284 U/L) and lipase (201 U/L) levels were suggestive of acute pancreatic injury. Additionally, screenings for viral infections, including hepatitis B, C, A, and HIV, all returned negative results. These findings were integral to forming a comprehensive clinical picture and guiding the subsequent treatment approach for the patient. A chest X-ray showed bilateral pulmonary edema (Figure 2). However, echocardiography results were normal, and an electrocardiography (ECG) indicated sinus tachycardia (Figure 3). Additionally, abdominal ultrasound and renal Doppler ultrasound did not reveal any significant abnormalities. The patient was admitted for in-patient care. Upon admission for in-patient care, the patient was immediately started on a comprehensive treatment regimen. This included Cetirizine hydrochloride 10mg for allergic reactions, Hydrocortisone 100mg administered twice daily as an anti-inflammatory, Ceftriaxone 1 gram twice daily, and intravenous fluids for hydration. In addition to these medications, the patient also underwent five sessions of hemodialysis. This treatment was crucial in addressing his acute kidney injury and led to a significant improvement in his urine output. The patient responded positively to the treatment and showed significant improvement. As a result, he was able to be discharged on the 7th day of his admission. During follow-up consultations, he continued to do well, indicating a successful recovery from the acute complications that arose following the honeybee sting.

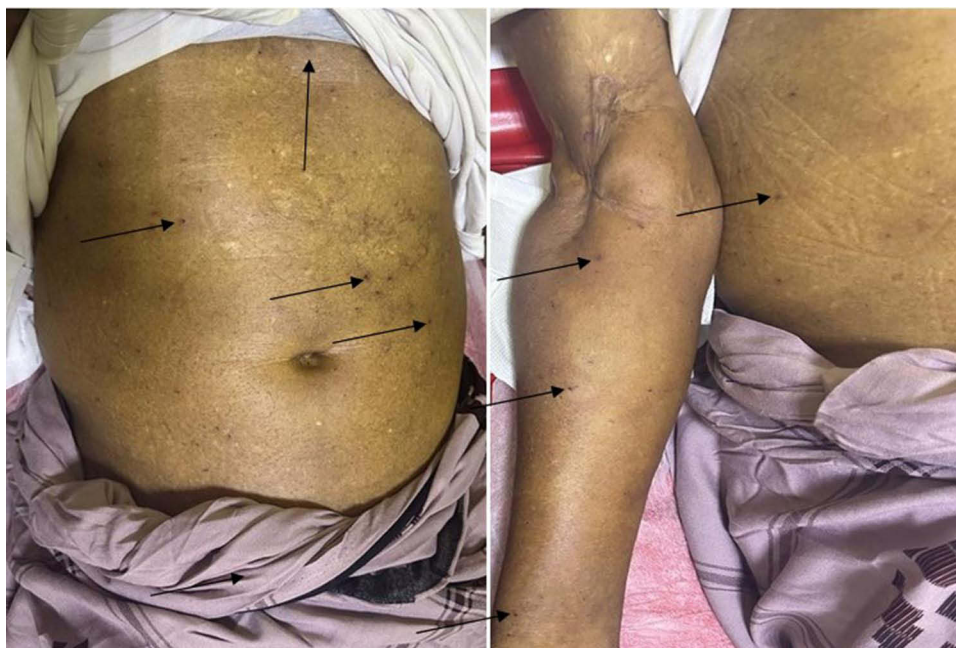

Figure 1 Demonstrates multiple red raised dermal papules (bee stings) on the anterior abdominal wall and right upper extremity.

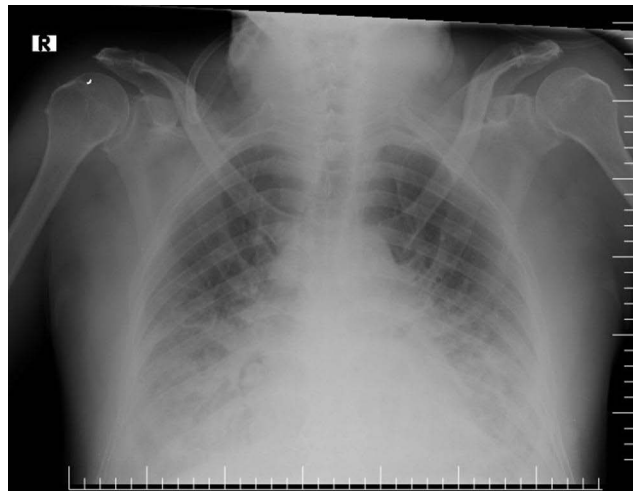


Figure 2 A chest X-ray showed bilateral pulmonary edema.

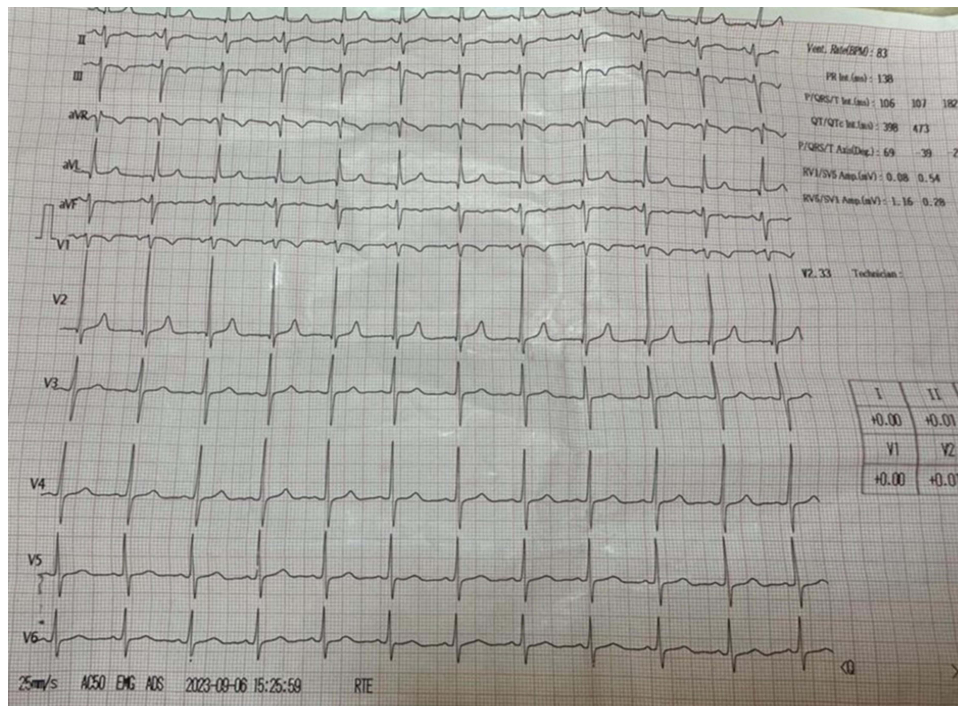


Figure 3 Electrocardiography (ECG) revealed sinus tachycardia.

Discussion

Bee stings are frequently experienced in Africa, yet there is a scarcity of medical literature specifically focusing on bee stings and their association with multi-organ failure. Venom released by bee stings can range from 50 to 140 μg each sting, which is a significant enough dosage to cause systemic damage.⁶ The clinical manifestations of honey bee stings can range from localized symptoms to severe allergic and systemic reactions.⁵ Several complications of massive honey bee stings were found in our case, including AKI, acute liver injury, coagulopathy, and acute pancreatitis. Very few such cases have been reported in literature. A similar case of multiorgan involvement was reported by Prasad et al from India, involving a 23-year-old boy who had bitten by a honeybee and suffered acute kidney injury (AKI), acute myocardial infarction, stroke, and immunological

thrombocytopenia.⁷ According to a study by Chen et al, a 67-year-old man who suffered from severe bee stings developed rhabdomyolysis, acute kidney damage (AKI), intravascular hemolysis, and acute respiratory distress syndrome (ARDS).⁴ Our patient also had raised creatinine, urea, ALT, AST, amylase, and lipase level. Acute kidney injury (AKI) from bee stings is due to multiple factors, such as intravascular hemolysis, rhabdomyolysis, hypotension, and direct toxicity of the venom components (melittin and apamin) to the renal tubules. The amount of venom injected directly correlates with the degree of liver damage caused by a bee bite, and hepatotoxicity may result from the toxin's direct effects or via immune-mediated mechanisms. Ramlackhansingh et al, documented a case where a 70-year-old man suffered an ischemic stroke, verified through neuroimaging, within 24 hours of being stung multiple times by Africanized honey bees.⁸ In a Sri Lankan case report, a 65-year-old male with hypertension and hyperlipidemia suffered envenomation after being attacked by *A. dorsata* bees, leading to acute limb ischemia.⁹ He fully recovered following treatment with anticoagulants and a surgical embolectomy. Our case had no any vascular complication ocular stings, which which either ischemic stroke or limb ischemia.

The case highlights the potential severity of bee stings, which, while often considered minor, can lead to serious medical complications. It also sheds light on the challenges of managing such cases in Somalia, a region with limited medical resources and data. This report aims to raise awareness about the risks associated with bee stings and the importance of prompt medical intervention, as well as to contribute to the limited body of literature on such cases in data-scarce regions like Somalia.

Data Sharing Statement

We declared that we had full access to all of the data in this study, and we take complete responsibility for the integrity of the data. All original data are available in the Mogadishu Somali Turkey Training and Research Hospital, Mogadishu, Somalia. Data used to support the findings of this study are available from the corresponding author upon request.

Ethics Approval

Based on the regulations of the review board of the Mogadishu Somali Turkish Training and Research Hospital, institutional review board approval is not required for case reports.

Consent for Publication

Written informed consent had obtained by the patient and his son to have the case details and any accompanying images published.

Author Contributions

All authors made a significant contribution to the work reported, whether that is in the conception, case presentation, or in all these areas; took part in drafting, revising or critically reviewing the case; gave final approval of the version to be published; have agreed on the journal to which the article has been submitted; and agree to be accountable for all aspects of the work.

Funding

We declare that we have not received any financial support.

Disclosure

The authors report no conflicts of interest in this work.

References

1. Steen CJ, Janniger CK, Schutzer SE, Schwartz RA. Insect sting reactions to bees, wasps, and ants. *Int J Dermatol*. 2005;44(2):91–94. doi:10.1111/j.1365-4632.2005.02391.x
2. Witharana EW, Wijesinghe SK, Pradeepa KS, Karunaratne WA, Jayasinghe S. Bee and wasp stings in Deniyaya; a series of 322 cases. *Ceylon Med J*. 2015;60(1):5. doi:10.4038/cmj.v60i1.7406

3. Schmidt JO. Clinical consequences of toxic envenomations by Hymenoptera. *Toxicon*. 2018;150:96–104. doi:10.1016/j.toxicon.2018.05.013
4. Chen TH, Liao WT, Chen CS, Lin PC, Wu MY. An envenoming syndrome from massive vespa stings induces multiple organ failure. *Insects*. 2020;11(4):219. doi:10.3390/insects11040219
5. Ryakitimbo A, Kennedy M, Shao E, et al. Acute kidney injury in a Tanzanian boy following multiple bee stings in resource-limited setting: a case report. *Oxford Med Case Rep*. 2018;2018(10):omy070. doi:10.1093/omcr/omy070
6. Jimoh AO, Akuse RM, Bugaje MA, Mayaki S. A call for sting treatment protocol: case report of a 3 year old with massive bee sting resulting in acute kidney injury. *Niger J Paediatr*. 2016;43(3):231–233. doi:10.4314/njp.v43i3.14
7. Prasad SK, Mehta SK, Satyanarayan B, Panda SK. Multi-organ dysfunction following honeybee bite—A rare entity. *J Fam Med Prim Care*. 2020;9(9):5052. doi:10.4103/jfmpe.jfmpe_629_20
8. Ramlackhansingh AF, Seecheran N. Case report: africanised honey bee sting-induced ischaemic stroke. *BMJ Case Rep*. 2020;13(5):e234877. doi:10.1136/bcr-2020-234877
9. Ratnayake GM, Weerathunga PN, Dilrukshi MS, Amara Witharana EW, Jayasinghe S. Giant honey bee (*Apis dorsata*) sting and acute limb ischemia: a case report and review of the literature. *BMC Res Notes*. 2018;11(1):1–3. doi:10.1186/s13104-018-3422-6
10. Silva Junior GB, Vasconcelos Junior AG, Rocha AM, et al. Acute kidney injury complicating bee stings—a review. *Rev Inst Med Trop Sao Paulo*. 2017;59(e25). doi:10.1590/s1678-9946201759025

International Medical Case Reports Journal

Dovepress

Publish your work in this journal

The International Medical Case Reports Journal is an international, peer-reviewed open-access journal publishing original case reports from all medical specialties. Previously unpublished medical posters are also accepted relating to any area of clinical or preclinical science. Submissions should not normally exceed 2,000 words or 4 published pages including figures, diagrams and references. The manuscript management system is completely online and includes a very quick and fair peer-review system, which is all easy to use. Visit <http://www.dovepress.com/testimonials.php> to read real quotes from published authors.

Submit your manuscript here: <https://www.dovepress.com/international-medical-case-reports-journal-journal>