




Exceptional Survival of a Buried Alive Newborn: A Case Report

Gabriel Kakuru Shamavu ¹, Kumbowi Kumbakulu Patrick¹, Franck Katembo Sikakulya ²,
Odong Richard Justin¹, Everest Tukamushaba³, Simon Odoch ^{1,3}, Baanitse Munihire Jeannot²,
Juliet Adongo Ocol^{1,3}

¹Department of Pediatrics, Faculty of Clinical Medicine and Dentistry, Kampala International University Western Campus, Ishaka-Bushenyi, Uganda;

²Department of Surgery, Faculty of Clinical Medicine and Dentistry, Kampala International University Western Campus, Ishaka-Bushenyi, Uganda;

³Department of Pediatrics, Lira Regional Referral Hospital, Lira, Uganda

Correspondence: Gabriel Kakuru Shamavu, Faculty of Clinical Medicine and Dentistry, Department of Pediatrics, Kampala International University Western Campus, PO.Box 70, Ishaka-Bushenyi, Uganda, Email gabrielshamavu@gmail.com; shamavu.kakuru@studwc.kiu.ac.ug

Introduction: This report details the exceptional survival of a female newborn buried alive by her own mother after a clandestine and unassisted birth. Despite spending over six hours underground, the newborn remarkably survived without exhibiting signs of perinatal asphyxia or major complications, and did not require advanced resuscitation measures.

Case Presentation: Rescued following a shocking discovery in a garden and rushed to the hospital, this newborn experienced transient hypothermia, mild to moderate respiratory distress, and scattered skin bruises. After five days of hospital care, she was discharged in clinically stable condition with no infectious complications, displaying age-appropriate normal neurological examination findings and excellent feeding.

Conclusion: This case not only defies established expectations but also illuminates perinatal physiological adaptation complexities. It highlights a fortunate and exceptional outcome in dire circumstances, presenting a captivating enigma within scientific realms. This report sheds light on the critical importance of early intervention and timely rescue efforts in cases of neonaticide, emphasizing the significance of raising awareness and implementing prompt measures to safeguard newborns in vulnerable situations and collectively contribute to our understanding of handling similar distressing cases.

Keywords: buried alive, survival, newborn, Uganda, case report

Introduction

The human organism, like most mammals, is fundamentally reliant on oxygen for its growth, development, and metabolic processes, both during its intra-uterine (embryologic and fetal life) and extra-uterine life.¹ During intrauterine life, the fetus draws its vital oxygen supply from the mother through the placental circulation. However, immediately after birth, a momentous transition occurs. The newborn must initiate breathing and derive oxygen from the surrounding air through its lungs. This transition necessitates not only physiological adaptative processes but also patent airways, fully developed lungs, and the presence of an oxygen-rich environment^{2,3}

Asphyxia, characterized by generalized cellular metabolic disorders resulting from oxygen deprivation, may stem from the impairment or interruption of placental oxygen supply in the intrauterine phase or the failure to establish successful pulmonary respiration upon birth. The perinatal period, encompassing the moments following birth, is a critical juncture where the newborn must seamlessly shift from the intrauterine to extrauterine life, contingent upon the availability of an oxygenated, aerobic environment.^{2,3}

While contemporary knowledge highlights the normative transition process, most neonates make this shift effortlessly, without the need for special intervention.^{3,4} Nevertheless, international guidelines uniformly emphasize that hospitals and accredited birth centers offer the safest settings for childbirth.⁵ Although human birth shares its roots with other mammals, our species demands routine care, even in the absence of complications.^{3,4}

Oxygen, a vital element for the survival of most life systems on Earth, is primarily sourced from the air. However, oxygen content varies due to environmental factors such as temperature, humidity, atmospheric pressure, and altitude. An underground environment, beneath the soil, is a classic example of a hypoxic (low-oxygen) setting. Human beings, like most mammals, exhibit a low tolerance to hypoxic conditions and cannot respire efficiently when buried underground.¹ Consequently, the survival of a human after spending many hours buried in the soil, isolated from the ambient air, is an extraordinary event.

We present a remarkable case of a newborn who defied the odds by surviving being buried alive for over six hours without exhibiting signs of perinatal asphyxia or any other complications. This newborn required no advanced resuscitation measures. The neonate received immediate oxygen supplementation, essential vaccines, and intravenous antibiotics upon admission. Subsequently, the newborn underwent five days of standard medical care and was ultimately discharged in a clinically stable condition, displaying excellent feeding and no apparent distress. This case not only defies established expectations but also illuminates the complexities of perinatal physiological adaptation. The exceptional survival of this newborn challenges conventional knowledge and calls for deeper exploration into the remarkable resilience it demonstrates, offering a unique perspective on the marvels of perinatal physiology and adaptation process. Additionally, we present this case as a poignant instance of attempted maternal neonaticide. Neonaticide, infanticide, and filicide are distressing societal issues that encompass the tragic acts of parents taking the lives of their newborns, infants, and children.^{6–12} This manuscript was prepared following the CARE guidelines (<https://www.care-statement.org>)

Case Presentation

Patient Description and Case History

We present the case of a newborn female that we received in emergency, brought by a team of rescuers. The baby was reportedly found buried underground in a garden. She would have been buried alive during the night by her own mother immediately after birth. It appears that the mother gave birth on her own, without assistance and buried her own daughter alive shortly after delivery. The newborn was not discovered until 11 a.m the following morning when the mother's family members discovered traces of blood in the garden near their home, leading them to the scene where the baby was buried. She was found still attached to the placenta and exhibited reactive limb movements in response to tactile stimuli, with a shallow breathing. The baby was covered in soil and had scattered small abrasions and bruises on her skin (image 1–4). This shocking discovery necessitated an urgent intervention by the rescuers who promptly cleaned the baby, separated her from the placenta by clamping, cutting, and ligating the cord. After a few minutes, she began to emit a weak cry exhibiting a labored and irregular breathing. Additionally, upon touch, the baby started to feel cool, and her extremities turned bluish. The rescuers wrapped her in towels and rushed her to the hospital. The mother is 23 years old and is a single mother living in her parents' house. She already had another child from an unplanned pregnancy. She did not attend any antenatal visits and did not receive routine antenatal care, including tetanus toxoid vaccines. There is no information available regarding her serological status for Human Immunodeficiency Virus (HIV) and other pathogens with the potential for congenital infections, such as Toxoplasmosis, Hepatitis B, Syphilis, Parvovirus, Varicella-Zoster Virus, Rubella, Cytomegalovirus or Herpes simplex virus. However, she reportedly does not have any known chronic diseases or mental disorders according to her family members. The age of the pregnancy was unknown.

Physical Examination Results

Upon admission, the neonate was alert, reactive with a progressively vigorous cry. She exhibited a normal global tone with presence of strong primitive reflexes, had neither abnormal posture nor abnormal movements. She weighed 3100 g (3.1 kg) and had no feature of prematurity or obvious dysmorphism with an estimated gestational age of approximately at 38 weeks using the Ballard maturational assessment Scale (35/50). She appeared mildly pale but no jaundice. The skin was already clean of soil but had disseminated small abrasions and bruises some of which were bleeding (Figures 1–4). She presented also a transient period of hypothermia with a rectal temperature 35.0°C (95°F) associated with acrocyanosis, which resolve after been putted under a radiant warmer. The neonate was in moderate Respiratory distress (Silverman-Andersen Score of 6), including mild nasal flaring, intercostal and subcostal retraction, and chest indrawing but neither grunting nor central cyanosis. She had bradypnea of 28 breaths per minute and oxygen saturation levels were measured at 82 to 85% in room air. The auscultation of lungs reveals diffused “Velcro-like fine crackles” were heard bilaterally but no inspiratory

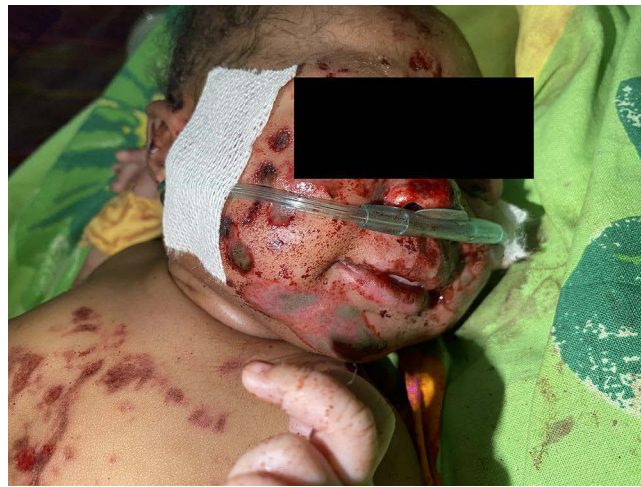

Figure 1 Newborn miraculously surviving being buried alive, displays scattered abrasions and bruises, picture taken in the emergency department post-cleaning from soil and while receiving Oxygen supplementation via Nasal Prongs.

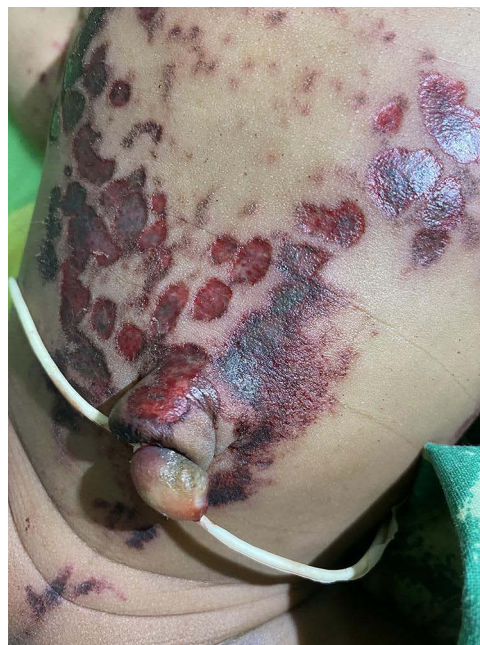

Figure 2 The newborn, miraculously surviving being buried alive, exhibits scattered abrasions and bruises. Photographed in the emergency department post-cleaning to remove soil, with the umbilical cord already cut and securely ligated.

stridor or expiratory wheezes. Other Notable findings on examination included, on the cardiovascular examination, the newborn has cold extremities, delayed capillary refill time for more than 2 seconds, but normal pulse volume and rate of 153 beats per minutes. The heart examination reveals normal findings. The abdominal and gastrointestinal system examination reveals no abnormal findings. The nasogastric placed, the aspiration reveals an empty stomach, no abnormal gastric aspirates.

Results and Interpretations of Investigations

Initial relevant laboratory investigations, including a baseline Complete Blood Count (CBC), Renal Function Tests, serum electrolyte levels, and Liver Function Tests, were conducted, and all results were normal. The sample for blood culture and antibiotics sensitivity tests was drawn. Chest standard plain radiography was not performed on admission and following the rapid clinical resolving of respiratory signs and symptoms, it was not requested after.

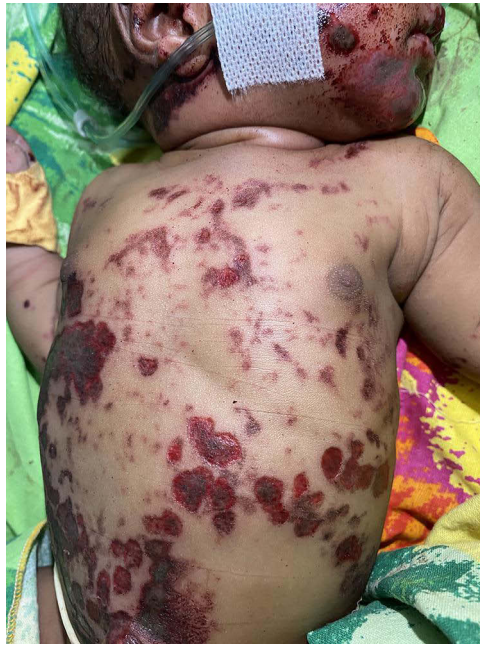

Figure 3 The newborn, miraculously surviving being buried alive, displays scattered abrasions and bruises. Photographed in the emergency department after thorough soil removal, the infant was placed under a radiant warmer to prevent hypothermia.

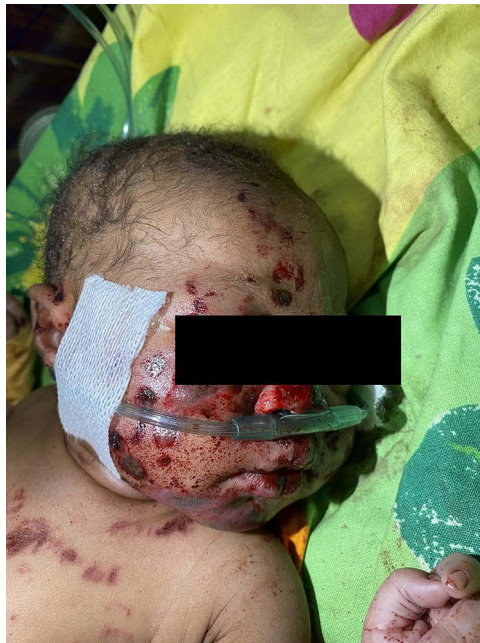

Figure 4 Photograph taken in the emergency department of a newborn miraculously surviving being buried alive, showing scattered abrasions and bruises. The image was captured after meticulous cleaning to remove soil from the skin, with the infant under a radiant warmer and receiving oxygen supplementation via nasal prongs.

Treatment Plan

Upon admission, the neonate was putted under a radiant warmer table and continuous monitoring of vital signs, received immediately Oxygen supplementation with initial standard flow via nasal prongs of 1 liter per minute. She received also Vitamin K1 1 mg in intramuscular (IM), Tetanus toxoid vaccine IM, BCG vaccine in subcutaneous (SC), Oral Polio vaccine, Tetracycline eye ointment, and routine Cord care. Intravenous (IV) antibiotics were prescribed: Ampicillin 150mg (50 mg/kg) every 6 hours for 5 days, Iv gentamicin 15 mg (5 mg/kg) per day for 5 days and Iv metronidazole starting dose

of 45 mg (15 mg/kg) then maintenance of 23 mg(7.5 mg/kg) every 8 hours. Received Dextrose 10% 15mL (5mL/kg) bolus at admission, and maintenance of 180 mL/24 h (60 mL/kg/24 h) the first day and 240 mL/24 h (80m L/kg/24 h) the second day. From the third day of life, the baby started to be fed orally by infant formula milk, with an initial quantity of 25 mL every 2 hours (300 mL/24 h = 100 mL/kg/24 h), increasing progressively over days. The skin was cleaned daily with 0.9% Saline solution, dried with sterile gauzes then the Mupirocin 2% topic were applied every 12 hours.

Outcome

The neonate presented a marked and drastic improvement over few days from admission, and was discharged 6 days. The baby received oxygen supplementation for 24 hours. She was weaned off the second day of admission, she was now breathing well with no sign of respiratory distress. Lungs' auscultatory adventitious sounds (crackles) subsided progressively. Attendants were counseled and educated about the nutrition, hygiene, and the importance of respecting the recommended, routine age-appropriate immunization visits. Subsequent routine follow-up visits revealed no late complications, with the patient exhibiting normal growth and development. At the 6-month follow-up (referenced in [Figures 5 and 6](#)), the infant demonstrated excellent overall health, normal neurological status, met age-appropriate developmental milestones across all domains, and maintained normal growth and nutritional status. It's notable that the

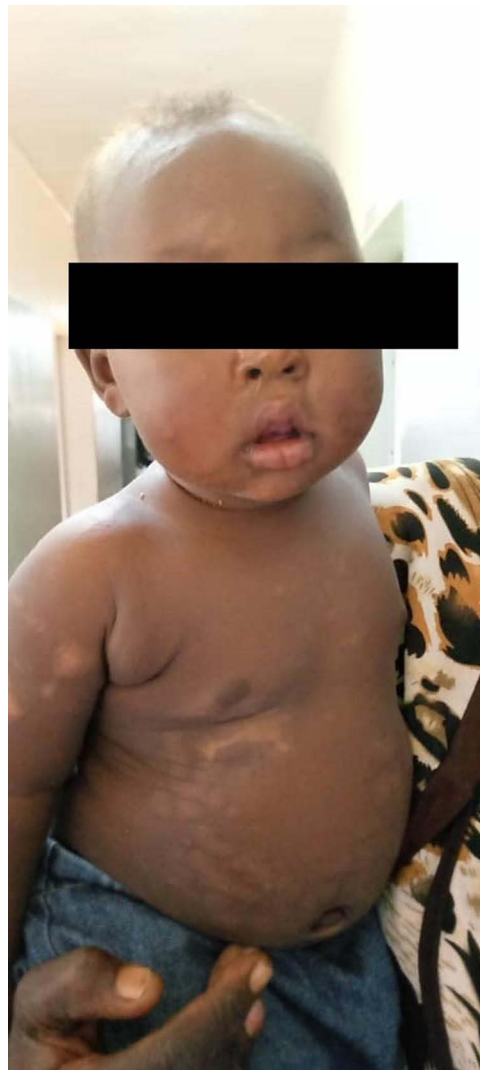


Figure 5 Infant's Progress at 6 Months: Image displaying the resilient survivor of a burial immediately after birth. Captured during the routine 6-month visit, showcasing normal growth, good nutritional status, attainment of age-appropriate developmental milestones, and visible skin lesion scars.

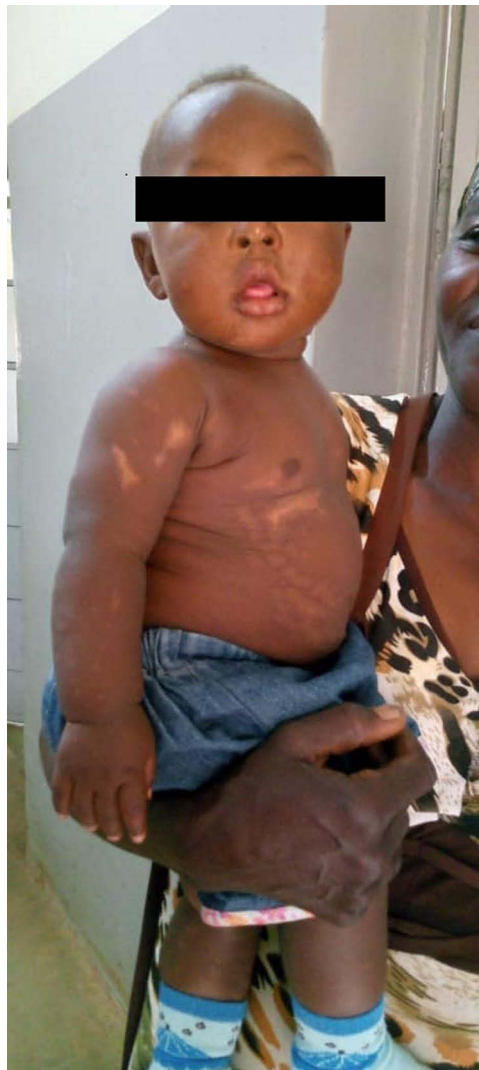

Figure 6 6-Month Follow-up Image: Depicting the thriving infant who survived being buried alive post-birth. Taken during the routine 6-month visit, highlighting normal growth, positive nutritional status, accomplishment of age-appropriate developmental milestones, and visible skin lesion scars.

baby is being raised by their grandmother. Unfortunately, the mother's situation led to her being taken into custody by the justice authorities and subsequently placed in a correctional center, followed by a psychiatric clinic.

Discussion

The remarkable survival of a newborn buried underground for over six hours presents a compelling enigma within the realm of neonatal physiology and adaptation. This unprecedented case provokes profound exploration into the intricate mechanisms orchestrating the transition from intrauterine to extra-uterine existence. While modern insights into neonatal resuscitation and transitional physiology have greatly progressed, elucidating the intricate choreography of cardiopulmonary adaptation, the survival of this buried newborn remains a tantalizing puzzle.

Contemporary understanding of the physiological changes during birth underscores the normative transition process, wherein most neonates seamlessly adapt. However, a subset necessitates interventions, and a minority requires extensive resuscitative measures.²⁻⁴

A fundamental cardiopulmonary transition occurs at birth, predicated on the closure of fetal circulatory shunts. This transition is integral to adapting to extrauterine life. Central to this process is the decrease in pulmonary vascular resistance,

triggered by the introduction of air into the alveoli during the first breaths, which replaces fluid. Concurrently, systemic vascular resistance increases due to the cessation of the low-pressure, low-resistance placental circulation.^{2-4,13-16}

In light of our current understanding of perinatal physiological adaptation, standardized guidelines have been established to govern systematic routine care for all newborns, facilitating a successful transition, as well as resuscitation protocols for distressed newborns. These guidelines include the American Heart Association (AHA) 2020 Neonatal Resuscitation Guidelines, the Helping Babies Breathe (HBB) Neonatal Resuscitation Global Curriculum by the American Academy of Pediatrics (AAP), and the World Health Organization (WHO) Basic Newborn Resuscitation Guidelines.²⁻⁴

A significant question arises: how did this newborn achieve a successful transition from intrauterine to extrauterine life despite the umbilical cord remaining uncut for more than six hours? Current perinatal physiology principles emphasize the importance of cord clamping in initiating vital physiological changes essential for a successful transition.¹³ Upon clamping, removal of the placenta with its low vascular resistance causes neonatal systemic blood pressure to rise, coinciding with reduced pulmonary vascular resistance and pulmonary artery pressure due to lung expansion.^{2-4,13-16}

Our clinical evaluation of the newborn indicated features consistent with successful transition. Unfortunately, we could not conduct further investigations to confirm the integrity of postnatal cardiovascular changes, such as the closure of foetal circulation shunts. A cardiac echocardiogram could have validated these changes.

Another perplexing aspect is the newborn's survival and tolerance of oxygen deprivation while underground for over six hours. Foetal oxygen tension is naturally low, and oxygen saturation decreases as blood returns to the placenta. Adequate tissue oxygenation results from foetal haemoglobin's higher oxygen affinity, reduced foetal oxygen consumption due to diminished physiological functions, and differential blood flow favouring vital organs.^{2-4,13-16}

The hypothesis arises that burial immediately after birth might have offered benefits. The soil's warmth could have mirrored the intrauterine thermal environment, reducing thermoregulatory demands. Additionally, the newborn's relative reduction in oxygen consumption and tolerance of lower oxygen environments might have contributed to her survival. However, it's important to note that this hypothesis lacks empirical support.

When found, the newborn exhibited scattered skin abrasions, the origin of which remains uncertain. The underground environment contained various insect species and microorganisms, raising questions about potential post-burial interactions. Notably, since the newborn's body seemingly remained alive during her underground dwell time, the typical decomposition process would not have occurred.

The mother, responsible for the attempted infanticide, was apprehended by the authorities; however, limited access to legal and psychiatric records restricts our discussion to the remarkable survival amidst these dire circumstances. Neonaticide, infanticide, and filicide are distressing societal concerns encompassing the killing of newborns, infants, and children by parents.⁶⁻¹¹ Phillip Resnick's 1969 classification reveals motives behind these acts, including altruism, psychosis, unwantedness, accidents, and revenge. Maternal distress, mental illness, and environmental stress (economic factors, domestic violence) contribute to these actions.⁷ Prevention strategies involve improved sex education, contraceptive access, psychiatric screening, and support.¹² Notably, neonaticide, often driven by pregnancy denial, highlights the urgency of awareness and intervention, given the irreversible consequences for all involved.^{7,17} Across cultures and ages, infanticide has manifested through diverse forms, from child sacrifice to abandonment. The prevalence of infanticide and neonaticide, driven by factors like gender preference and socio-economic pressures, underscores the gravity of these acts. While societies have witnessed shifts in attitudes and legal frameworks, the haunting reality of filicide persists. Psychiatric conditions, socio-economic stressors, and marital conflicts contribute to such tragic events.^{11,12,17-21}

Upon the exploration of this case, it is crucial to underscore the extraordinary survival of the newborn and the exhaustive therapeutic efforts employed. The family's experience in this case highlights the intricate dynamics and challenges they faced, shedding light on the complexities that contribute to such incidents. Notably, the separation of the newborn from the mother created a poignant and challenging situation for the family. Moreover, the paramount lesson from this case lies in prioritizing prevention as the primary strategy against neonaticide. It calls for a dedicated focus on identifying and providing personalized follow-up for psychologically and socially unstable pregnant women. While time-sensitive interventions are undeniably vital, investing in proactive measures directed at at-risk individuals holds the key to averting such distressing incidents in the future. Understanding the nuanced factors that lead to neonaticide is essential for developing effective preventive measures and support systems.

Conclusion

In conclusion, the exceptional survival of a newborn buried alive for more than six hours presents a remarkable case that challenges our current understanding of neonatal physiology and adaptation. This singular occurrence underscores the importance of further research to unravel the intricate mechanisms underlying such exceptional resilience. Additionally, this report underscores the urgency of early intervention and awareness in cases of neonaticide, emphasizing the need to safeguard vulnerable newborns and enhance our approach to similar distressing cases.

Abbreviations

SC, Subcutaneous; IM, Intramuscular; IV, Intravenous; CBC, Complete Blood Cells Count; BCG, Bacillus Calmette-Guérin; °C, degrees Celsius; °F, degrees Fahrenheit; Kg, kilogram; mL, milligram; HIV, Human Immunodeficiency Virus; g, gram; mg, milligram; PCR, Polymerase Chain Reaction.

Data Sharing Statement

All data generated or analyzed during this study are included in this case report.

Ethical Approval

Not applicable. The institutional approval was not required.

Informed Consent and Right of Anonymity

The informed consent for publication, including permission for the use of images, was obtained from the guardian.

Disclosure

The authors declare no conflicts of interest in this work.

References

- Li M, Pan D, Sun H, et al. The hypoxia adaptation of small mammals to plateau and underground burrow conditions. *Animal Model Exp Med*. 2021;4(4):319–328.
- Aziz K, Lee HC, Escobedo MB, et al. Part 5: neonatal resuscitation: 2020 American heart association guidelines for cardiopulmonary resuscitation and emergency cardiovascular care. *Circulation*. 2020;142(16_suppl_2):S524–50. doi:10.1161/CIR.0000000000000902
- Berg KM, Bray JE, Ng KC, et al. 2023 international consensus on cardiopulmonary resuscitation and emergency cardiovascular care science with treatment recommendations: summary from the basic life support; advanced life support; pediatric life support; neonatal life support; education, I. *Circulation*. 2023;1:1.
- Kamath-Rayne BD, Thukral A, Visick MK, et al. Helping babies breathe, second edition: a model for strengthening educational programs to increase global newborn survival. *Glob Health Sci Pract*. 2018;6(3):538–551. doi:10.9745/GHSP-D-18-00147
- Watterberg K, Cummings JJ, Adams-Chapman IS. Providing care for infants born at home. *Pediatrics*. 2020;145(5). doi:10.1542/peds.2020-0626
- Bourget D, Grace J, Whitehurst L. A review of maternal and paternal filicide. *J Am Acad Psychiatry Law*. 2007;35(1):74–82.
- Resnick PJ. Child murder by parents: a psychiatric review of filicide. *Am J Psychiatry*. 1969;126(3):325–334. doi:10.1176/ajp.126.3.325
- Schöne M, Peter E, Dobrowolny H, Bogerts B. Neonaticide: a classification of female perpetrators in an east-west comparison. *Nervenarzt*. 2015;86(5):595–602. doi:10.1007/s00115-014-4205-5
- Kohl M. *Infanticide and the Value of Life*. Buffalo, New York SE: Prometheus Books Buffalo, New York; 1978.
- Guileyardo JM, Prahlow JA, Barnard JJ. Familial filicide and filicide classification. *Am J Forensic Med Pathol*. 1999;20(3):286–292. doi:10.1097/0000433-199909000-00014
- West SG. An overview of filicide. *Psychiatry*. 2007;4(2):48–57.
- Jason J. Child homicide spectrum. *Am J Dis Child*. 1983;137(6):578–581.
- Jain A, Mohamed A, Kavanagh B, et al. Cardiopulmonary adaptation during first day of life in human neonates. *J Pediatr*. 2018;200:50–57.e2. doi:10.1016/j.jpeds.2018.04.051
- van Vonderen JJ, te Pas AB, Kolster-Bijdevaate C, et al. Non-invasive measurements of ductus arteriosus flow directly after birth. *Arch Dis Child Fetal Neonatal Ed*. 2014;99(5):F408–12. doi:10.1136/archdischild-2014-306033
- Tan CMJ, Lewandowski AJ. The transitional heart: from early embryonic and fetal development to neonatal life. *Fetal Diagn Ther*. 2019;47(5):373–386. doi:10.1159/000501906
- Noori S, Wlodaver A, Gottipati V, McCoy M, Schultz D, Escobedo M. Transitional changes in cardiac and cerebral hemodynamics in term neonates at birth. *J Pediatr*. 2012;160(6):943–948. doi:10.1016/j.jpeds.2011.12.008
- Milner L. *Hardness of Heart/Hardness of Life: The Stain of Human Infanticide*. Lanham/New York/Oxford: University Press of America; 2000:1–29.
- Amon S, Putkonen H, Weizmann-Henelius G, et al. Potential predictors in neonaticide: the impact of the circumstances of pregnancy. *Arch Womens Ment Health*. 2012;15(3):167–174. doi:10.1007/s00737-012-0268-0

19. Asch SS. Crib deaths: their possible relationship to post-partum depression and infanticide. *J Mt Sinai Hosp N Y*. 1968;35(3):214–220.
20. Asch SS, Rubin LJ. Postpartum reactions: some unrecognized variations. *Am J Psychiatry*. 1974;131(8):870–874. doi:10.1176/ajp.131.8.870
21. Spinelli MG. A systematic investigation of 16 cases of neonaticide. *Am J Psychiatry*. 2001;158(5):811–813. doi:10.1176/appi.ajp.158.5.811

International Medical Case Reports Journal

Dovepress

Publish your work in this journal

The International Medical Case Reports Journal is an international, peer-reviewed open-access journal publishing original case reports from all medical specialties. Previously unpublished medical posters are also accepted relating to any area of clinical or preclinical science. Submissions should not normally exceed 2,000 words or 4 published pages including figures, diagrams and references. The manuscript management system is completely online and includes a very quick and fair peer-review system, which is all easy to use. Visit <http://www.dovepress.com/testimonials.php> to read real quotes from published authors.

Submit your manuscript here: <https://www.dovepress.com/international-medical-case-reports-journal-journal>