

The role of ^{123}I -ioflupane SPECT dopamine transporter imaging in the diagnosis and treatment of patients with dementia with Lewy bodies

Angelo Antonini

Parkinson Institute, Istituti Clinici di Perfezionamento, Milan, Italy

Abstract: The diagnosis of dementia with Lewy bodies (DLB) is difficult if one relies solely on clinical features. Current International Consensus Criteria for DLB have high specificity but a significant percentage of patients might be misdiagnosed. Reasons for clinical uncertainty regard the presence of concomitant motor signs in patients with Alzheimer's disease as well as the observation that cognitive abnormalities in DLB might develop with memory impairment without significant parkinsonism. This has clinical relevance as DLB patients may be particularly sensitive to anti-psychotics and even the effectiveness of atypical neuroleptics such as quetiapine for the treatment of agitation and hallucinations has been questioned by double-blind, placebo-controlled, randomized studies. By contrast, acetyl-cholinesterase inhibitors such as rivastigmine have shown benefit not only on cognitive but also on psychiatric symptoms. Recent evidence shows that striatal dopamine transporter binding of ^{123}I -ioflupane SPECT is reduced in DLB and this is consistent with a significant loss of nigral dopamine neurons in this disorder. Several studies have demonstrated the diagnostic accuracy of ^{123}I -ioflupane in the differential diagnosis of parkinsonism. Given the availability of SPECT, this investigation represents a useful marker to support clinical diagnosis and can help establishing appropriate treatment for this disorder.

Keywords: dementia with Lewy bodies, ^{123}I -ioflupane-SPECT, dopamine transporter, parkinsonism, Alzheimer's disease

Introduction

Clinical diagnosis of patients presenting with extrapyramidal features is often problematic as signs and symptoms suggestive of Parkinson's disease may be present in several parkinsonian syndromes. The diagnostic algorithm can be even more complex if additional cognitive deficits are present. These cases, particularly when dementia precedes parkinsonism, might be difficult to ascertain and a differential diagnosis with Alzheimer's disease (AD) should be considered. This has clinical consequences since treatment strategies differ among disorders with dementia. Neuroimaging is helpful particularly when demonstration of abnormalities in the dopamine system is required. Tracers binding to the dopamine transporter (DAT) in the striatum have now reached widespread application and can be used, in addition to neurological examination, in those patients presenting clinical uncertainty (Tolosa et al 2006).

Clinical diagnostic issues in patients with dementia with Lewy bodies

Current International Consensus diagnostic criteria define patients with Parkinson's disease dementia (PDD) as those presenting with parkinsonism prior to the onset

Correspondence: Angelo Antonini
Parkinson Institute, Istituti Clinici di Perfezionamento, 20126 Milano, Italy
Tel +39 0257 993222
Fax +39 0257 93319
Email angelo3000@yahoo.com

of dementia, while if parkinsonism and dementia develop concurrently they are classified as dementia with Lewy bodies (DLB) (McKeith et al 2005). However, data on neuropathology of these disorders are scarce and inconclusive about the possibility of distinguishing between patients with and without dementia (Aarsland et al 2004). In PD, the Lewy bodies are found mainly in the substantia nigra and other brainstem nuclei such as the locus ceruleus and raphe, whereas in DLB Lewy bodies are also present in a number of neocortical and archicortical areas (Apaydin et al 2002). Overall the 1-year rule described in the McKeith criteria, where patients presenting with less than 1 year of parkinsonism prior to dementia are diagnosed with DLB and patients with a longer duration of parkinsonism before the onset of dementia are diagnosed with PDD, is still commonly used for clinical and research purposes. This has been further reaffirmed in a recent consensus article where it is concluded that the different course of cognitive and motor symptoms in PDD and DLB justify a distinction between the two disorders (Lippa et al 2007). However, the same authors suggested that for research purposes it is currently more convenient to use a "Lewy body disorder model" in view of the presence of abnormal alpha-synuclein inclusions in both diseases (Lippa et al 2007).

Clinically, patients with DLB develop postural instability and gait difficulties more frequently than in PD without dementia (Burn et al 2003). The response to levodopa is often unsatisfactory, suggesting that many extrapyramidal symptoms may have non-dopaminergic origin. In a recent study in 14 DLB patients, acute levodopa challenge yielded a 13.8% improvement in UPDRS-III compared with 23% and 21% in PD patients with and without cognitive dysfunction (Molloy et al 2005).

The environment is further complicated by the fact that DLB patients might be difficult to separate from AD patients. Concurrent senile plaques and neurofibrillary tangles are common in both PDD and DLB possibly contributing to cognitive decline in these disorders (Aarsland et al 2005a, b). Moreover, cholinergic dysfunction has been reported also in DLB patients, making the differential diagnosis challenging in some cases (Tiraboschi et al 2000).

Difficulties in the differential diagnosis between DLB and AD have been highlighted by many studies that have reassessed "in life" diagnosis of dementia at neuropathology. In a series of 10 patients with a diagnosis of DLB who came to autopsy this could be confirmed only in 5. Of the five misdiagnosed cases, 4 had AD and 1 progressive supranuclear palsy. The misdiagnosed DLB cases who had AD

presented in life with fewer hallucinations but interestingly an equal amount of spontaneous extrapyramidal signs, even in the absence of neuroleptic treatment, further highlighting the limit of current diagnostic criteria (Hohl et al 2000). Similar results were found in a later study aimed at determining what clinical features, among visual hallucinations, extrapyramidal signs, and visuospatial impairment, might best predict at early disease stage a diagnosis of DLB at neuropathology compared with AD. In a cohort of 23 pathologically proven DLB patients vs 94 AD the authors found that among several clinical variables, visual hallucination was the most specific to DLB and visuospatial impairment the most sensitive. The best model for differentiating DLB from AD did not include extrapyramidal symptoms (Tiraboschi et al 2006). In another cohort of 44 DLB patients identified among 788 cases with parkinsonism archived at the Queen Square Brain Bank in London, frequency of visual hallucinations was 50% of PD, 73% of DLB, and only 7% of non-degenerative parkinsonism. Visual hallucinations were associated with cognitive impairment, autonomic dysfunction, and axial rigidity within the first 2 years of disease (Williams and Lees 2005). This is in line with the observation that patients who at neuropathology present significant Alzheimer abnormalities in addition to Lewy bodies have predominantly memory impairment in life (Merdes et al 2003).

Conversely, the frequency of motor signs in AD is often underestimated, as suggested by a recent prospective evaluation of 474 AD patients for an average period of 13 years where motor signs were observed in 13% of patients at first examination rising to 36% of patients at the end of the follow-up period. The main symptoms contributing to worsening mobility were gait and bradykinesia which significantly predicted institutionalization and mortality (Scarmeas et al 2004; Scarmeas et al 2005).

In view of these difficulties the recently revised consensus criteria have suggested adding new features to improve DLB diagnosis. In particular, imaging of the dopamine system has been proposed as the main instrumental investigation to help in the differential diagnosis among disorders with dementia (McKeith et al 2005).

Because DLB, unlike AD, is characterized by degeneration of nigral dopaminergic neurons, in vivo demonstration of dopaminergic loss can be considered an accurate diagnostic marker (Walker et al 1999).

Dopamine transporter imaging

SPECT imaging tracers binding to the dopamine transporters are sensitive tools aimed at demonstrating the presence

of dopamine nerve terminal loss in the striatum (Antonini and De Notaris 2004; Scherfler et al 2007). There are two radiopharmaceuticals available for SPECT imaging, [^{123}I]β-CIT or [^{123}I]2β-carboxymethoxy-3β-(4-iodophenyl)tropane) and ^{123}I -ioflupane or [^{123}I]N-w-fluoropropyl-2β-carbomethoxy-3β-(4-iodophenyl)nortropane.

^{123}I -ioflupane is a radioligand that binds to the dopamine transporter located in the presynaptic membrane of dopamine nerve terminals. The main advantage of ^{123}I -ioflupane is that a steady state allowing SPECT imaging is reached at 3 hours after a single bolus injection of the radioligand, compared with the 18–24 hours required for [^{123}I]β-CIT. Therefore image acquisition can be completed the same day.

^{123}I -ioflupane has been studied in a large number of trials using SPECT to identify in vivo loss of dopamine transporters in the striatum, especially the putamen, in patients with pre-synaptic parkinsonism (Benamer et al 2000a; Booij et al 2001). A European study conducted in 158 patients with a clinical diagnosis of parkinsonism compared their ^{123}I -ioflupane SPECT imaging with the visual assessment of 27 subjects affected by ET and 35 healthy volunteers. The “institutional read” was the primary end-point of the study: it consisted of the visual assessment of ^{123}I -ioflupane SPECT striatal uptake, and was conducted on scans reconstructed with the highest resolution in each participating center by an investigator blinded to clinical data. The “consensus blinded” read was the secondary end-point of the study and was reconstructed with raw data performed in each center: the resultant images were randomly evaluated by a blinded read panel of neurologists until an agreement was reached. Sensitivity for the clinical diagnosis of parkinsonism was 97% and specificity for ET was 100% for the institutional read, whereas sensitivity was 95% and specificity 93% for the consensus blinded (Benamer et al 2000b).

There is good consistency between visual and semi-quantitative assessment, making ^{123}I -ioflupane imaging easy to use also in a clinical routine setting (Ottaviani et al 2006). Because DLB, PD with dementia, and PD are characterized by involvement of dopamine nigral neurons, imaging of striatal DAT helps in identifying these patients. Degeneration might be more widespread in DLB and might also involve projections to the caudate nucleus possibly contributing to cognitive impairment (Figure 1) (Lucignani et al 2002; Walker et al 2004).

Conversely, AD patients generally show normal striatal DAT binding (Walker et al 2002), making this pattern a specific and helpful disease marker (Figure 1). In addition to changes in the dopamine system, additional cortical

abnormalities have been described in DLB. More specifically, a pattern of reduced perfusion or metabolism in the occipital lobe may occur in DLB but this does not help in single case assessment. Reduced temporoparietal function is instead common to both AD and DLB (Mito et al 2005). Striatal dopamine D2 receptor binding of ^{123}I -IBZM SPECT may also be reduced in DLB but the overlap with AD is considerable (Walker et al 1997).

The rate of decline of striatal dopamine loss in DLB is similar to that in PD and PD dementia (Colloby et al 2005). However in DLB, dementia severity and motor impairment correlated with striatal tracer decline, suggesting that dopaminergic loss plays an important role both in cognitive and motor features.

Additional confirmation about the relevance of DAT imaging in the differential diagnosis between DLB from AD comes from a study that compared in-life diagnosis, imaging, and neuropathology in 14 demented patients (Costa et al 2003). Seven patients had in-life abnormal DAT imaging and were diagnosed as DLB: 6 had their in-life diagnoses confirmed at neuropathology, while 1 showed coexistent striatal vascular infarction. By contrast, the five individuals with in-life diagnosis of DLB but normal striatal binding had a post-mortem diagnosis of AD. This study confirms that imaging of the dopamine system helps in the diagnostic work-up of DLB and further highlights the complexity of clinical examination in the differential diagnosis among disorders with dementia.

Finally, a recently published phase III study used ^{123}I -ioflupane SPECT to assess DAT binding in 326 patients with clinical diagnoses of probable or possible DLB vs non-DLB dementia. The authors found that abnormal uptake had a 77.7% probability for detecting DLB with a 90.4% specificity to exclude other forms of dementia, mostly AD. Diagnosis of dementia was established on clinical criteria rather than neuropathology. The authors concluded that DAT imaging improves diagnostic accuracy of DLB, particularly in cases presenting clinical uncertainty (McKeith et al 2007).

Relevance of a correct diagnosis for DLB treatment

Treatment of DLB patients requires control of motor symptoms as well as cognitive dysfunction, including deficits in attention, apathy, fluctuating cognition, behavioral abnormalities, confusion, delusions, hallucinations, and psychosis. Psychiatric symptoms often need treatment with neuroleptics but this occasionally causes adverse events in these patients.

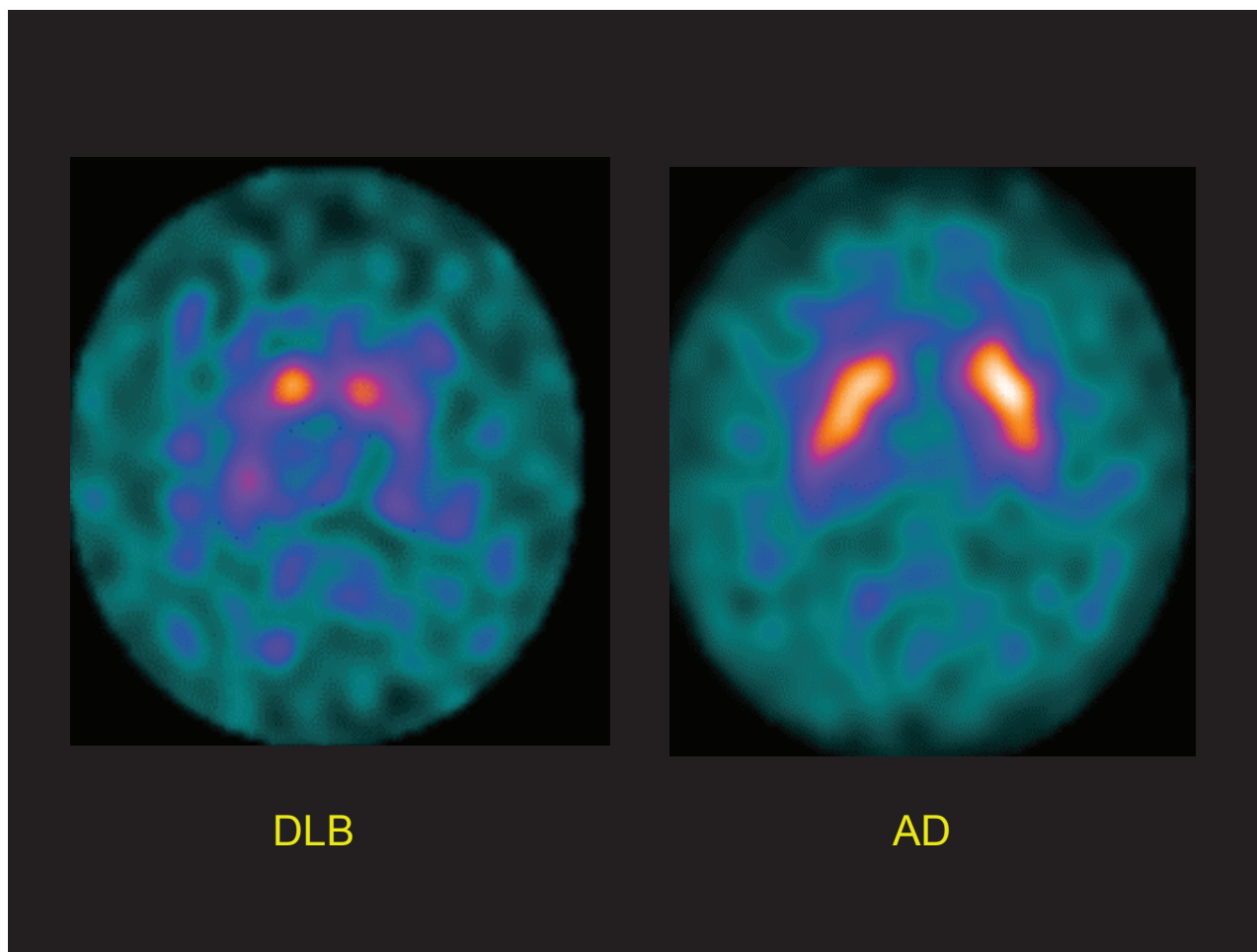


Figure 1 The images depict striatal dopamine transporter binding of with ^{123}I -ioflupane – SPECT in one patient with dementia with Lewy bodies (DLB) (right panel) and in one with Alzheimer's disease (AD) (left panel). It can be appreciated that ^{123}I -ioflupane uptake in the basal ganglia is normal in AD but markedly reduced in the DLB patient, consistent with significant impairment of striatal dopamine nerve terminals.

In a recent survey severe reactions to neuroleptics have been reported in 53% of DLB patients but not in AD (Aarsland et al 2005a, b). In the first report on this topic, McKeith et al (1992) described severe adverse reaction to neuroleptics in 13 of 20 neuropathologically confirmed cases of DLB. These patients were exposed to phenothiazines or haloperidol and presented, in addition to worsening parkinsonism, confusion, and agitation, and in 2 cases developed neuroleptic malignant-like syndrome.

There is agreement that clozapine and quetiapine should be preferred in the treatment of psychiatric symptoms in DLB (Klein et al 2003; Poewe 2005). The effectiveness of clozapine has been proven in a controlled trial in PD patients with hallucinations and does not interfere with cognitive function, except for sedation (Parkinson Study Group 1999). Quetiapine has similar properties to clozapine and can be used safely in these patients. A retrospective evaluation found complete or partial remission of psychosis with low

doses in almost 90% of DLB patients (Fernandez et al 2002). Two recent double-blind, placebo-controlled, studies have challenged quetiapine's benefit on psychiatric symptoms in DLB, PDD, and PD patients (Kurlan et al 2007; Rabey et al 2007). In both studies the authors found no improvement in agitation or psychosis in patients with dementia and parkinsonism even though motor symptoms were unaffected by quetiapine treatment.

By contrast treatment strategies in AD differ and neuroleptics with more potent anti-dopaminergic activity such as haloperidol or risperidone might help in the management of behavioral symptoms (De Deyn et al 1999; Mayeux et al 1999).

Similarly to AD, recent studies have assessed the effectiveness and safety of acetyl-cholinesterase inhibitors, such as rivastigmine and donepezil in DLB. In a large, randomized, placebo-controlled trial, rivastigmine treatment significantly improved cognitive scales as well as secondary measures on fluency and attention (McKeith et al 2000). The

magnitude of improvement is possibly even greater than AD, and some authors have suggested this treatment also as first-line management of psychiatric symptoms in DLB (McKeith et al 2004).

Additional studies have looked at the effect of rivastigmine in patients with PD and dementia and found similar results (Werber et al 2001; Emre et al 2004). Current evidence favors further research on the use of rivastigmine and acetyl-cholinesterase inhibitors in general, for the treatment of hallucinations and psychiatric symptoms in PD with dementia (Reading et al 2001; Bullock et al 2002).

Conclusions

The differential diagnosis between DLB and AD is complex and neuropathology studies demonstrate a high rate of misdiagnosis. This has clinical consequences particularly in view of the risk of severe adverse reactions to antipsychotics as well as of the potential benefit of acetyl-cholinesterase inhibitors such as rivastigmine on cognitive and psychiatric disturbances of DLB patients. Considering that in DLB there is significant loss of nigral neurons, imaging of the dopamine system is an appropriate and effective biological marker for this disorder. ¹²³I-ioflupane is a SPECT tracer that is now commonly used in clinical routine for the differential diagnosis between PD and ET because of its high specificity and sensitivity. Recent studies in DLB have shown that imaging with ¹²³I-ioflupane helps in identifying these patients and this is consistent with post-mortem assessment. Overall, current evidence favors the use of this imaging test in the diagnostic work-up of DLB.

References

- Aarsland D, Ballard CG, Halliday G. 2004. Are Parkinson's disease with dementia and dementia with Lewy bodies the same entity? *J Geriatr Psychiatry Neurol*, 17:137–45.
- Antonini A, DeNotaris R. 2004. PET and SPECT functional imaging in Parkinson's disease. *Sleep Med*, 5:201–6.
- Aarsland D, Perry R, Brown A, et al. 2005a. Neuropathology of dementia in Parkinson's disease: a prospective, community-based study. *Ann Neurol*, 58:773–6.
- Aarsland D, Perry R, Larsen JP, et al. 2005b. Neuroleptic sensitivity in Parkinson's disease and parkinsonian dementias. *J Clin Psychiatry*, 66:633–7.
- Apaydin H, Ahlskog JE, Parisi JE, et al. 2002. Parkinson's disease neuropathology: later developing dementia and loss of the levodopa response. *Arch Neurol*, 59:102–12.
- Benamer HT, Patterson J, Grosset DG, and the 123I-FP-CIT Study Group. 2000a. Accurate differentiation of parkinsonism and essential tremor using visual assessment of 123I-FP-CIT SPECT imaging: the FP-CIT study group. *Mov Disord*, 15:503–10.
- Benamer HT, Patterson J, Wyper DJ, et al. 2000b. Correlation of Parkinson's disease severity and duration with 123I-FP-CIT SPECT striatal uptake. *Mov Disord*, 15:692–8.
- Booij J, Speelman JD, Horstink MWIM, et al. 2001. The clinical benefit of imaging striatal dopamine transporters with [123I]FP-CIT SPECT on differentiating patients with presynaptic Parkinsonism from those with other forms of Parkinsonism. *Eur J Nucl Med*, 28:266–72.
- Burn DJ, Rowan EN, Minett T, et al. 2003. Extrapyramidal features in Parkinson's disease with and without dementia and dementia with Lewy bodies: a cross-sectional comparative study. *Mov Disord*, 18:884–9.
- Bullock R, Cameron A. 2002. Rivastigmine for the treatment of dementia and visual hallucinations associated with Parkinson's disease: a case series. *Curr Med Res Opin*, 18:258–64.
- Colloby SJ, Williams ED, Burn DJ, et al. 2005. Progression of dopaminergic degeneration in dementia with Lewy bodies and Parkinson's disease with and without dementia assessed using 123I-FP-CIT SPECT. *Eur J Nucl Med Mol Imaging*, 32:1176–85.
- Costa DC, Walker Z, Walker RW, et al. 2003. Dementia with Lewy bodies versus Alzheimer's disease: role of dopamine transporter imaging. *Mov Disord*, 18(Suppl 7):34–8.
- De Deyn PP, Rabheru K, Rasmussen A, et al. 1999. A randomized trial of risperidone, placebo and haloperidol for behavioral symptoms of dementia. *Neurology*, 53:946–55.
- Emre M, Aarsland D, Albanese A, et al. 2004. Rivastigmine in Parkinson's disease patients with dementia: a randomized, double-blind, placebo-controlled study. *N Engl J Med*, 351:2509–18.
- Fernandez H, Trieschmann ME, Burke MA, et al. 2002. Quetiapine for psychosis in Parkinson's disease versus dementia with Lewy bodies. *J Clin Psychiatry*, 63:513–15.
- Hohl U, Tiraboschi P, Hansen LA, et al. 2000. Diagnostic accuracy of dementia with Lewy bodies. *Arch Neurol*, 57:347–51.
- Klein C, Gordon J, Pollak L, et al. 2003. Clozapine in Parkinson's disease psychosis: 5-year follow-up review. *Clin Neuropharmacol*, 26:8–11.
- Kurlan R, Cummings J, Raman R, et al. 2007. Alzheimer's Disease Cooperative Study Group. Quetiapine for agitation or psychosis in patients with dementia and parkinsonism. *Neurology*, 68:1356–63.
- Lippa CF, Duda JE, Grossman M, et al. 2007. DLB and PDD boundary issues: diagnosis, treatment, molecular pathology, and biomarkers. *Neurology*, 68:812–19.
- Lucignani G, Gobbo C, Moresco RM, et al. 2002. The feasibility of statistical parametric mapping for the analysis of positron emission tomography studies using 11C-2-beta-carbomethoxy-3-beta-(4-fluorophenyl)-tropane in patients with movement disorders. *Nucl Med Commun*, 23:1047–55.
- McKeith I, Fairbairn A, Perry R, et al. 1992. Neuroleptic sensitivity in patients with senile dementia of Lewy body type. *BMJ*, 305:673–8.
- McKeith I, Del-Ser T, Spano PF, et al. 2000. Efficacy of rivastigmine in dementia with Lewy bodies: a randomised, double-blind, placebo-controlled international study. *Lancet*, 356:2031–6.
- McKeith I, Mintzer J, Aarsland D, et al, on behalf of the International Psychogeriatric Association Expert Meeting on DLB. 2004. Dementia with Lewy bodies. *Lancet Neurol*, 3:19–28.
- McKeith IG, Dickson DW, Lowe J, et al. 2005. Diagnosis and management of dementia with Lewy bodies. Third report of the DLB consortium. *Neurology*, 65:1863–72.
- McKeith I, O'Brien J, Walker Z, et al. 2007. Sensitivity and specificity of dopamine transporter imaging with 123I-FP-CIT SPECT in dementia with Lewy bodies: a phase III, multicentre study. *Lancet Neurol*, 6:305–13.
- Mayeux R, Sano M. 1999. Treatment of Alzheimer's disease. *N Engl J Med*, 341:1670–9.
- Merdes AR, Hansen LA, Jeste DV, et al. 2003. Influence of Alzheimer pathology on clinical diagnostic accuracy in dementia with Lewy bodies. *Neurology*, 60:1586–90.
- Mito Y, Yoshida K, Yabe I, et al. 2005. Brain 3D-SSP SPECT analysis in dementia with Lewy bodies, Parkinson's disease with and without dementia, and Alzheimer's disease. *Clin Neurol Neurosurg*, 107:396–400.
- Molloy S, McKeith IG, O'Brien JT, et al. 2005. The role of levodopa in the management of dementia with Lewy bodies. *J Neurol Neurosurg Psychiatry*, 76:1200–3.
- Ottaviani S, Tinazzi M, Pasquin I, et al. 2006. Comparative analysis of visual and semi-quantitative assessment of striatal [123I]FP-CIT-SPECT binding in Parkinson's disease. *Neurol Sci*, 27:397–401.

- Parkinson Study Group. 1999. Low-dose clozapine for the treatment of drug-induced psychosis in Parkinson's disease. *N Engl J Med*, 340:757-63.
- Poewe W. 2005. Treatment of dementia with Lewy bodies and Parkinson's disease dementia. *Mov Disord*, 20(Suppl 12):S77-82.
- Rabey JM, Prokhorov T, Miniovitz A, et al. 2007. Effect of quetiapine in psychotic Parkinson's disease patients: a double-blind labeled study of 3 months' duration. *Mov Disord*, 22:313-8.
- Reading P, Luce A, McKeith I. 2001. Rivastigmine in the treatment of parkinsonian psychosis and cognitive impairment. *Mov Disord*, 16:1171-4.
- Scarmeas N, Hadjigeorgiou GM, Papadimitriou A, et al. 2004. Motor signs during the course of Alzheimer disease. *Neurology*, 28; 63:975-82.
- Scarmeas N, Albert M, Brandt J, et al. 2005. Motor signs predict poor outcomes in Alzheimer disease. *Neurology*, 64:1696-703.
- Scherfler C, Schwarz J, Antonini A, et al. 2007. Role of DAT-SPECT in the diagnostic work-up of parkinsonism. *Mov Disord*, May 7 [Epub ahead of print].
- Tiraboschi P, Hansen LA, Alford M, et al. 2000. Cholinergic dysfunction in diseases with Lewy bodies. *Neurology*, 54:407-11.
- Tiraboschi P, Salmon DP, Hansen LA, et al. 2006. What best differentiates Lewy body from Alzheimer's disease in early-stage dementia? *Brain*, 129:729-35.
- Tolosa E, Wenning G, Poewe W. 2006. The diagnosis of Parkinson's disease. *Lancet Neurol*, 5:75-86.
- Walker Z, Costa DC, Janssen AG, et al. 1997. Dementia with Lewy bodies: a study of post-synaptic dopaminergic receptors with iodine-123 iodobenzamide single-photon emission tomography. *Eur J Nucl Med*, 24:609-14.
- Walker Z, Costa DC, Ince P, et al. 1999. In-vivo demonstration of dopaminergic degeneration in dementia with Lewy bodies. *Lancet*, 354:646-7.
- Walker Z, Costa DC, Walker RWH, et al. 2002. Differentiation of dementia with Lewy bodies from Alzheimer's disease using a dopaminergic presynaptic ligand. *J Neurol Neurosurg Psychiatry*, 73:134-40.
- Walker Z, Costa DC, Walker RW, et al. 2004. Striatal dopamine transporter in dementia with Lewy bodies and Parkinson disease: a comparison. *Neurology*, 62:1568-72.
- Werber E, Rabey J. 2001. The beneficial effect of cholinesterase inhibitors on patients suffering from Parkinson's disease and dementia. *J Neural Transm*, 108:1319-25.
- Williams DR, Lees AJ. 2005. Visual hallucinations in the diagnosis of idiopathic Parkinson's disease: a retrospective autopsy study. *Lancet Neurol*, 4:605-10.