


# Incidence of Systemic Vasculitis and Clinical Outcomes in Systemic Sclerosis: 2-Years Follow-Up of Asymptomatic Positive for Anti-Neutrophilic Cytoplasmic Antibody

Raiwin Suwannamajo, Ajanee Mahakkanukrauh, Siraphop Suwannaroj, Chingching Foocharoen 

Department of Medicine, Faculty of Medicine, Khon Kaen University, Khon Kaen, 40002, Thailand

Correspondence: Chingching Foocharoen, Department of Medicine, Faculty of Medicine, Khon Kaen University, Khon Kaen, 40002, Thailand, Tel +6643363746, Email fching@kku.ac.th

**Purpose:** Anti-neutrophilic cytoplasmic antibody (ANCA)-associated vasculitis (AAV) overlap with systemic sclerosis (SSc) is uncommon. We aimed to determine the incidence of AAV and define clinical outcomes relevant to asymptomatic screening positive for ANCA in SSc after 2 years of follow-up.

**Patients and Methods:** The study was a cohort study of 185 Thai adult SSc patients testing for ANCA and having a 2-year follow-up at the Scleroderma Clinic, Khon Kaen University, Thailand. The incidence of AAV and outcomes of those who tested positive for ANCA were evaluated.

**Results:** A total of 185 SSc patients were tested for ANCA, of whom 21.6% were positive for either cytoplasmic ANCA, perinuclear ANCA (p-ANCA), anti-myeloperoxidase (anti-MPO), or anti-proteinase3 antibody. Only one 52-year-old female patient with dcSSc, negative for initial ANCA test, developed AAV (microscopic polyangiitis) 7 months after the first ANCA test for an incidence of AAV of 0.27 per 100-person-years (95% CI 0.01–1.5). She was positive for p-ANCA and anti-MPO. Eight of those who had an initial test were positive for ANCA and underwent a repeated test. Only two cases persisted as positive for ANCA (1 anti-MPO and 1 anti-PR3) and had no clinicals suspicious of vasculitis. Four cases that had ANCA turned to a negative result.

**Conclusion:** AAV is a rare complication in SSc, so ANCA may not have any role as a screening test for AAV as it cannot predict the development of AAV in SSc. We suggest testing for ANCA only in SSc patients with clinicals suspicious of AAV.

**Keywords:** systemic sclerosis, scleroderma, anti-neutrophilic cytoplasmic antibody, ANCA- associated vasculitis, vasculitis

## Introduction

Anti-neutrophil cytoplasmic antibodies (ANCA) are autoantibodies directed against the enzymes found within the primary granules of neutrophils and lysosomes in monocytes. These antibodies are involved in the pathogenesis of ANCA-associated vasculitis (AAV).<sup>1</sup> In a retrospective study in Mexico between March 2003 and March 2018, Martin-Nares et al<sup>2</sup> reported the prevalence of overlap between AAV and systemic autoimmune disease was 11.3%. The predominant AAV type was renal-limited vasculitis (39%), followed by granulomatosis with polyangiitis (GPA) (29%), microscopic polyangiitis (MPA) (25%), and eosinophilic granulomatosis with polyangiitis (EGPA) (7%). The main clinical manifestations were renal (79%), otorhinolaryngologic (43%), and pulmonary and peripheral neuropathy (32%). The overlap between AAV and systemic sclerosis (SSc) was 14%.

Previous studies estimated the prevalence of ANCA in SSc patients between 0% and 18%, but only a few cases develop clinical overlap syndrome with AAV.<sup>3–6</sup> ANCA was reported to be associated with an increased prevalence of interstitial lung disease and pulmonary embolism in SSc, especially in anti-proteinase 3 (anti-PR3) positive patients. It was also associated with an increased risk of mortality.<sup>7</sup> These findings suggest that ANCA should be tested at baseline in

SSc patients as it is associated with a worse prognosis, so those patients need close monitoring and follow-up for adverse outcomes. Many researchers recommend routine testing for ANCA of patients with SSc with a suspected renal crisis or evidence of glomerular disease by urinalysis. If positive, a renal biopsy should be considered. Such an approach will help to define the underlying pathophysiologic process and guide subsequent therapy. Some researchers suggest that a positive ANCA in a patient with SSc warrants close observation for renal disease in anticipation of acute renal failure.<sup>8,9</sup>

The prevalence of asymptomatic positive for ANCA in SSc is around 22%.<sup>10</sup> Notwithstanding, the clinical relevance and outcomes of patients that are asymptomatic positive for ANCA are uncertain. We thus aimed to evaluate the incidence of AAV and the clinical outcomes after 2 years of follow-up in SSc patients who were asymptomatic positive for ANCA after screening. If any clinical relevance or its related outcomes are demonstrated, ANCA testing could be a predictor of AAV in SSc patients. On the other hand, if no clinical relevance is detected in those who are asymptomatic positive for ANCA, the antibody could be nonspecific in SSc, and it need not be screened in patients with no clinicals suspicious of SSc overlap AAV.

## Materials and Methods

A historical cohort was conducted in 185 adults Thai SSc who were followed up for 2 years from the date of ANCA testing at the Scleroderma Clinic, Khon Kaen University, Khon Kaen, Thailand. We included patients  $\geq 18$  years of age, diagnosed as SSc, and all of them participated in a previous cross-sectional study on the “Prevalence and clinical association of the presence of anti-neutrophilic cytoplasmic antibody in systemic sclerosis”.<sup>10</sup>

The data included SSc clinical features, clinical features of vasculitis, routine laboratory tests for SSc, related laboratory tests for AAV, medical treatment, and outcomes. Data collection started 2 years and later from the date of initial ANCA testing. In case of loss to follow-up, patient health status was requested by mail and/or retrieved from the Civil Registration Office. If the patient had clinicals for AAV, the Birmingham vasculitis activity score version 3 was applied to evaluate the severity of AAV.

## Operational Definition

Diagnosis of SSc is based on the 2013 ACR/EULAR Classification Criteria for Systemic Sclerosis<sup>11</sup> and classified into limited cutaneous SSc (lcSSc) and diffuse cutaneous SSc (dcSSc), according to LeRoy et al.<sup>12</sup> Onset of SSc is defined as the time of the first non-Raynaud SSc symptom, as reported by the patient. Disease duration is calculated as the interval between disease onset and the time of the last data collection.

Diagnosis of AAV is based on the 2022 AAV EULAR classification criteria.<sup>13–15</sup> The definition of ANCA-positive is confirmed by either indirect immunofluorescence (IIF) or enzyme-linked immunosorbent assay (ELISA). Anti-myeloperoxidase (anti-MPO) and anti-PR3 were tested using the EUROIMMUN AG (Lübeck, Germany) using the Euroline immunoblot immunoglobulin G (IgG) technique. ANCA was tested using EUROIMMUN AG (Lübeck, Germany) using indirect immunofluorescence testing and classified into two patterns: perinuclear-ANCA (p-ANCA) and cytoplasmic-ANCA (c-ANCA). Antibodies with borderline and weakly positive signal intensities with a titer  $< 1:10$  were considered negative in the current study.

AAV presents as GPA, MPA, EGPA, and renal-limited vasculitis (RLV). GPA is diagnosed by tissue biopsy compatible with necrotizing granulomatous inflammation (usually involving the upper and lower respiratory tract) and necrotizing vasculitis (affecting predominantly small-to-medium vessels).<sup>16</sup> MPA is diagnosed by tissue biopsy compatible with necrotizing vasculitis, with few or no immune deposits, predominantly affecting small vessels (ie, capillaries, venules, or arterioles). Necrotizing arteritis involving small and medium arteries may be present, while granulomatous inflammation is absent.<sup>16</sup> EGPA is diagnosed by tissue biopsy compatible with eosinophil-rich and necrotizing granulomatous inflammation often involving the respiratory tract, and necrotizing vasculitis, predominantly affecting small-to-medium vessels and associated with asthma and eosinophilia.<sup>16</sup> RLV is diagnosed with isolated renal-limited vasculitis with pauci-immune necrotizing glomerulonephritis alone with no evidence of systemic vasculitis.<sup>17</sup>

Functional classification is defined according to the New York Heart Association (NYHA).<sup>18</sup> The skin score is evaluated using the modified Rodnan Skin Score (mRSS). Pulmonary fibrosis is fulfilled when interstitial fibrosis is detected by high-resolution computed tomography (HRCT). Pulmonary arterial hypertension (PAH) is diagnosed by

mean pulmonary arterial pressure > 20 mmHg with pulmonary artery wedge pressure  $\leq$  15 mmHg and pulmonary vascular resistance of  $\geq$  3 wood units, confirmed by right heart catheterization.<sup>19</sup> Scleroderma renal crisis is diagnosed by 1) a new onset of blood pressure >150/85 mmHg obtained at least twice over a 24-h period; 2) a documented decrease in renal function as defined by a decrement of at least 30% in the calculated glomerular filtration rate (eGFR); and, 3) any of the following (microangiopathic hemolytic anemia on the blood smear, retinopathy typical of acute hypertensive crisis, new onset of urinary RBCs (excluding other causes), flash pulmonary oedema, oliguria, or anuria).<sup>20</sup> Esophageal involvement is defined when there is the presence of any esophageal symptoms of SSc (ie, esophageal dysphagia, heartburn, or reflux symptoms). Stomach involvement includes symptoms of dyspepsia, early satiety, constipation, diarrhea, and malabsorption.<sup>21</sup> Anemia is defined when hemoglobin in males is <13 g/dl and in females is <12 g/dl.<sup>22</sup> Eosinophilia is the total eosinophil count more than 500 cell/mm<sup>3</sup>.<sup>23</sup>

## Statistical Analysis

Demographic data are categorized and summarized using descriptive statistics. Categorical data were presented as proportions or percentages. Continuous data were presented as means with standard deviations (SD) or medians with interquartile ranges (IQR) as appropriate. The incidence of AAV was investigated with its 95% confidence interval (95% CI). Clinical outcomes included the presence of AAV, mortality rate, and causes of death of patients testing asymptomatic positive for ANCA. All statistics are analyzed using STATA version 16.0 (Stata Corp. College Station, TX, USA).

The authors designed the study, while it was reviewed and approved by the Khon Kaen University Ethics Committee for Human Research based on the Declaration of Helsinki and the ICH Good Clinical Practice Guidelines (HE631305). The need for informed consent was waived by the Human Research Ethics Committee of Khon Kaen University.

## Results

### Patient Characteristics

A total of 185 cases with asymptomatic for AAV were included and screened for ANCA. At least one serological test positive for ANCA (p-ANCA, c-ANCA, anti-MPO, or anti-PR3) at the initial screening was recorded in 40 cases (21.6%). The demographic data and clinical characteristics of the patients screened for ANCA are presented in Table 1. Most cases were female (64.9%) and dcSSc (71.7%). The mean age on the study date was 59.9 years. Forty-five of the patients were lost to follow-up, of whom eight received treatment for SSc and were followed up at a local hospital; 37 cases died (25 due to SSc-related death and 2 for unknown causes). None had suspected AAV after health status was requested by mail and/or retrieved from the Civil Registration Office.

### Incidence of AAV

Two years after initial ANCA testing with 360.8 person-years, AAV was revealed in only 1 case for an incidence of 0.27 per 100 person-years (95% CI 0.01–1.5). The patient was female with dcSSc. The duration of the disease while having a diagnosis

**Table 1** Demographic Data and Clinical Characteristics of Patients Screened for ANCA

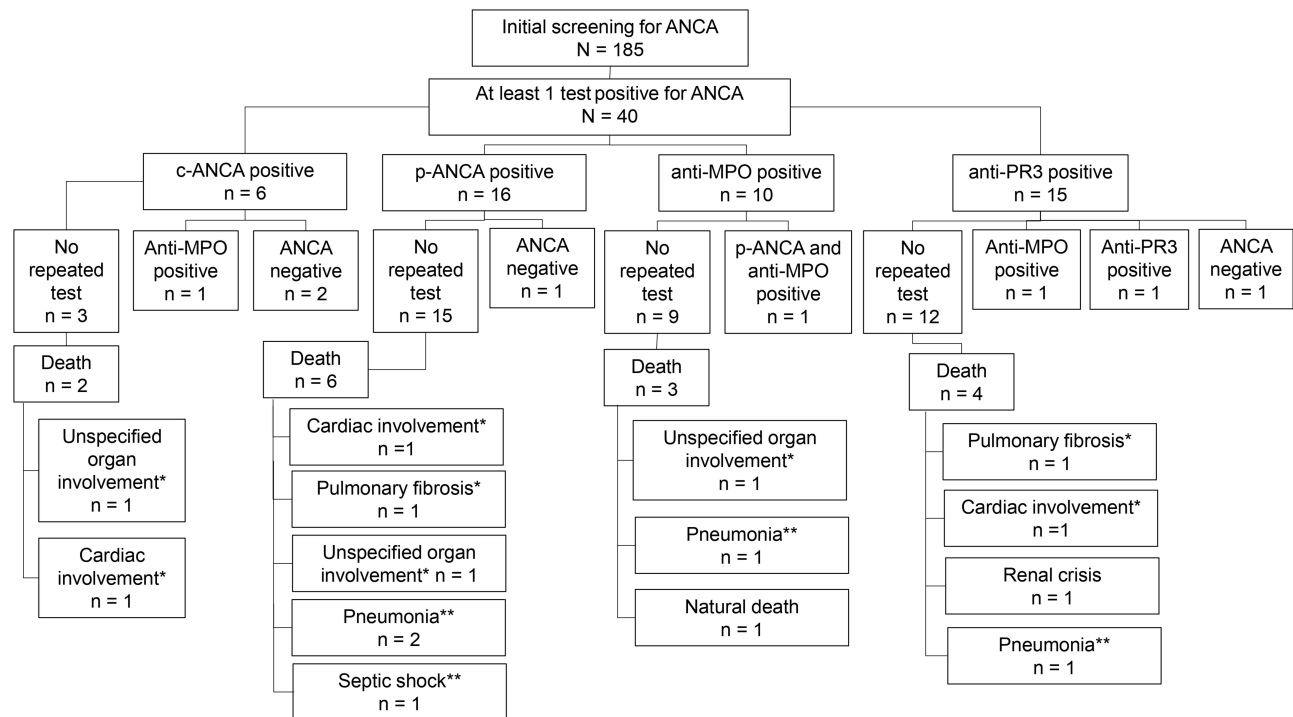
Factor	Value N = 185
Age at onset (years); mean $\pm$ SD	50.9 $\pm$ 10.5
Age on study date (years); mean $\pm$ SD	59.9 $\pm$ 10.1
Sex: female (%)	120 (64.9)
BMI (kg/m <sup>2</sup> ); mean $\pm$ SD	21.0 $\pm$ 3.8
Diffuse cutaneous systemic sclerosis (%)	132 (71.7)

(Continued)

**Table 1** (Continued).

Factor	Value N = 185
Disease duration (years); mean $\pm$ SD	9.0 $\pm$ 5.6
mRSS; median (IQR)	2 (0–4)
Autoantibodies	
Anti-topoisomerase-I antibody positive (%)	137 (76.1)
Anti-CENPA antibody positive (%)	17 (9.8)
Anti-CENPB antibody positive (%)	21 (12.1)
ANCA-IIF method	
c-ANCA positive (%)	6 (3.2)
p-ANCA positive (%)	16 (8.7)
ANCA-ELISA method	
Anti-MPO antibody positive (%)	10 (5.6)
Anti-PR3 antibody positive (%)	15 (8.2)
Positive both P-ANCA and Anti-MPO antibody (%)	2 (1.1)
Positive both C-ANCA and Anti-PR3 antibody (%)	2 (1.1)
ANCA positive either method (%)	40 (21.6)
Clinical manifestation at 2 years after initial ANCA test	N = 138
Raynaud's phenomenon (%)	56 (40.6)
Digital ulcer (%)	18 (13.0)
Salt and pepper skin (%)	48 (35.0)
Hand deformity (%)	51 (37.0)
Dysphagia (%)	27 (19.6)
Dyspepsia (%)	20 (14.5)
Constipation (%)	12 (8.7)
Pulmonary fibrosis (%)	106 (77.4)
Pulmonary hypertension (%)	26 (19.0)
Scleroderma renal crisis (%)	4 (2.9)
Hemoglobin (g/dl); mean $\pm$ SD	11.9 $\pm$ 1.6
Eosinophilia (%)	32 (23.2)
ESR (mm/h); mean $\pm$ SD	41.6 $\pm$ 23.1
Creatinine (mg/dl); mean $\pm$ SD	0.9 $\pm$ 0.6

**Abbreviations:** SD, standard deviation; BMI, body mass index; mRSS, modified Rodnan skin score; ANCA, anti-neutrophilic cytoplasmic antibody; IIF, indirect immunofluorescence; ELISA, Enzyme-Linked Immunosorbent Assay; ESR, Erythrocyte sedimentation rate.



**Figure 1** Two-year follow-up of patients with an initial positive for ANCA and their outcomes.

**Notes:** \*SSc-related death, \*\*Non-SSc related death.

of AAV was 8 years. Her serology was positive for anti-topoisomerase-I and anti-Ku antibodies. ANCA was negative at the initial test. Seven months after the initial ANCA test, she was diagnosed with MPO-AAV. Her clinical presentations of AAV were new onset of hypertension, proteinuria with urine sediment, rising serum creatinine level, and positive for p-ANCA and anti-MPO antibodies. A kidney biopsy revealed cellular crescents with pauci-immune depositions. She was treated with intravenous methylprednisolone 1000 mg continuously for 3 days with intravenous cyclophosphamide monthly for 6 months as the induction regimen. Her renal function turned to normal, free of urine sediment. Thereafter, mycophenolate mofetil was given as a maintenance regimen until the last follow-up, and to this writing, she has had no clinical relapse of AAV.

## Two Years Follow-Up of Patients with Initial Positive for ANCA and the Outcomes

Among the 40 cases of those with an initial screening test positive for ANCA, they had no AAV clinicals at the 2-year follow-up. Eight of the forty had repeated the ANCA test, but the majority did not repeat the test as they had no clinical symptoms suggestive of AAV. Only one case that had had an initial test positive for anti-MPO was persistently positive for anti-MPO. In addition, the one case that had initially tested positive for anti-PR3 continued to be positive for anti-PR3 at the 2-year follow-up. Both of these cases had no clinicals suspicious of vasculitis. Finally, four positive ANCA cases turned to negative tests (Figure 1).

At the 2-year follow-up, there was no statistically significant difference in the clinical characteristics of patients with persistent ANCA-positive vs ANCA-absent vis-à-vis NYHA functional class, internal organ involvement, skin thickness progression evaluation by mRSS, or laboratory tests (viz. blood count, renal function, liver function, or urinalysis) (Supplementary Table 1).

## Discussion

Vasculopathy is a crucial aspect of SSc pathogenesis.<sup>24,25</sup> Some features of vasculopathy are similar to systemic vasculitis or AAV, such as digital gangrene and skin ulcers. Based on the clinical manifestations, it is a challenge in clinical practice to differentiate between vasculopathy and coexisting SSc-vasculitis (SSc overlap systemic vasculitis). A vessel's pathology can be used to confirm a diagnosis and differentiate vasculopathy from systemic vasculitis as vessel

inflammation is not the principal pathology in SSc as it is in systemic vasculitis.<sup>26</sup> There is a limitation to doing biopsy in some cases, especially those patients with digital gangrene. Serology, particularly ANCA, can play a role in evaluating coexisting systemic vasculitis in SSc.

ANCA is a well-known autoantibody associated with AAV. The ANCA test is classified into c-ANCA and p-ANCA—using the IIF method, which has less specificity but high sensitivity. Thus, it is always used as a screening test (ie, anti-MPO and anti-PR3 by ELISA). A c-ANCA-positive is associated with GPA, but the diagnosis needs to be confirmed by testing for anti-PR3 using ELISA (which is more specific than the IIF method). A p-ANCA positive is associated with MPA and EGPA, but the diagnosis needs to be confirmed by testing for anti-MPO using ELISA.

A positive test for ANCA, using the IIF method, was reported in a meta-analysis. c-ANCA had a pooled sensitivity of 75.2% and a pooled specificity of 98.4%. By comparison, when using the anti-PR3 antibody, the p-ANCA had a pooled sensitivity of 46.3% and a pooled specificity of 91.4%. Thus, the pooled sensitivity depended on the immunoassay method used and ranged between 79.8% and 86.6%, while the pooled specificity ranged between 96.8% and 98.3%. As for the anti-MPO antibody, irrespective of method, the pooled sensitivity was 58.1%, and the pooled specificity was 95.6%.<sup>27</sup> Of which c-ANCA is associated with GPA, while p-ANCA with MPA and EGPA.<sup>28–30</sup> The ELISA-based makes use of purified specific antigens. Immunoassay-detecting antibodies against PR3 and MPO usually have higher specificities and positive predictive values than IIF patterns like p-ANCA and c-ANCA.<sup>27</sup> Anti-PR3 with c-ANCA are commonly detected in GPA, while anti-MPO and p-ANCA in MPA.

In SSc, the prevalence of ANCA-positive using either method was approximately around 12–22%.<sup>10,31</sup> However, SSc overlap AAV is quite rare. In a large cohort study of 2200 SSc, the SSc overlap with AAV was 1.6%.<sup>32</sup> Moxey et al<sup>7</sup> reported the significance of ANCA in SSc in an SSc cohort in Australia in 2019. Most cases were lcSSc, and 8.9% of the 1303 patients were ANCA positive: anti-PR3 being more common than anti-MPO (13.8% and 11.2%, respectively). Anti-topoisomerase I was more commonly found in ANCA-positive patients than in ANCA-negative ones. Most of these patients did not have any clinical features of AAV.<sup>7</sup> Only one patient in our study developed AAV and was negative for ANCA at the initial test. Our finding supports the low prevalence of SSc overlap AAV despite the high prevalence of ANCA-positive. Despite SSc overlap AAV being a rare disease,<sup>32,33</sup> these conditions ultimately lead to morbidity and mortality with organ dysfunction and failure.<sup>1,34</sup> Renal and pulmonary involvement are the most common manifestations of SSc overlap AAV.<sup>6,26,33,35</sup> Our patient, who developed AAV, also presented with proteinuria and urine sediment, which are not classical SSc features. The pathological findings suggested renal involvement in AAV, and the diagnosis was SSc overlap MPO-AAV. The initial ANCA test in this patient was negative, so an initial negative test does not necessarily rule out the development of AAV in SSc.

Our study showed that none of the ANCA-positive patients had clinical features of AAV even at the 2-year follow-up. ANCA might therefore be a nonspecific antibody in SSc, so is not a good predictor for AAV in SSc. Based on the study method, we evaluated the outcome of ANCA-positive patients at the 2-year follow-up, so we cannot conclude whether or not ANCA could be used as a predictor of AAV after longer-term follow-up. Furthermore, given the mean disease duration of 9 years in our enrolled cases, some experienced skin regression during the follow-up period, leading to a lower mRSS on the study date than expected. It is noteworthy that AAV was rarely detected even with a long disease duration.

Persistent-positive for ANCA when screening for asymptomatic AAV in SSc patients was rare. The persistent ANCA-positive patients were positive for ANCA by the ELISA method, and none were persistent for ANCA by the IIF method. The ANCA test using the ELISA method provides a greater specificity and positive predictive value than the ANCA test, using the IIF method.<sup>27</sup> It is, therefore, not surprising that persistent-ANCA was detected using the ELISA method (one with anti-MPO and one with anti-PR3). Despite the persistent ANCA-positives, none had clinicals suspicious of AAV at the 2-year follow-up. Long-term outcome follow-up should be done in patients with persistent ANCA-positive to check for the development of AAV.

Based on our observations, given the high prevalence of ANCA-positive but low prevalence of AAV during follow-up, there is no short-term benefit in ANCA screening for SSc patients who have no clinicals suspicious of SSc overlap

AAV. On the other hand, ANCA should be tested in SSc patients having clinicals suspicious of AAV such as glomerulonephritis.

There are some limitations to our study, including (a) the small number of patients with a repeated test for ANCA due to the lack of evidence for performing a follow-up test for ANCA in those with no clinicals suspicious of AAV and budget limitations, so the proportion of persistent-positive for ANCA in our study might be underestimated; (b) the lack of a quantitative result for ANCA for both the IIF and ELISA methods, so we cannot conclude whether the positive test was significant or not; and, (c) lost to follow-up was around 25%, so we cannot provide detailed clinicals of those patients at 2 years after performing the initial test for ANCA. Notwithstanding, none of those lost to follow-up had suspected AAV when we checked health status by mail and/or retrieved information from the Civil Registration Office. Strengths of our study included (a) the large sample size and appropriate time for follow-up so as to fulfill the objectives of our study; (b) this is the first report of outcomes of asymptomatic screening positive for ANCA, so our findings provide baseline information for physicians planning ANCA testing in SSc patients.

## Conclusion

AAV is a rare complication in SSc, so ANCA may have no role as an AAV screening test. Moreover, ANCA cannot be used to predict AAV development in SSc. We thus suggest testing for ANCA in SSc patients with clinicals suspicious AAV.

## Data Available Statement

Data and material are available from the corresponding author on reasonable request.

## Ethics Approval and Consent to Participate

The Human Research Ethics Committee of Khon Kaen University reviewed and approved the study as per the Helsinki Declaration and the Good Clinical Practice Guidelines (HE631305). The Human Research Ethics Committee of Khon Kaen University waived the requirement for informed consent because of the retrospective nature of the study. Participant privacy was protected by anonymized data and maintained confidentiality. The study methods were performed in accordance with the Helsinki Declaration statement.

## Consent for Publication

The authors consent to publication and grant the Publisher exclusive license of the full copyright.

## Acknowledgments

The authors thank (a) the Scleroderma Research Group, Khon Kaen University for support, and (b) Mr. Bryan Roderick Hamman under the aegis of the Publication Clinic Khon Kaen University, Thailand, for assistance with the English-language presentation. The abstract of this paper was presented at the 23rd Asia-Pacific League of Associations for Rheumatology (APLAR) Congress as a poster presentation with interim findings. The poster's abstract was published in 'Poster Abstracts' in *Int J Rheum Dis.* 2021;24(Suppl. 2):121–333. DOI: 10.1111/1756-185X.14200.

## Author Contributions

All authors made a significant contribution to the work reported, whether that is in the conception, study design, execution, acquisition of data, analysis and interpretation, or in all these areas; took part in drafting, revising, or critically reviewing the article; gave final approval of the version to be published; have agreed on the journal to which the article has been submitted; and agree to be accountable for all aspects of the work.

## Funding

The study received funding support from the Research and Graduate Studies, Khon Kaen University, Thailand.

## Disclosure

The authors report no conflicts of interest in this work.

## References

- Geetha D, Jefferson JA. ANCA-Associated Vasculitis: core Curriculum 2020. *Am J Kidney Dis.* 2020;75(1):124–137. doi:10.1053/j.ajkd.2019.04.031
- Martin-Nares E, Zuñiga-Tamayo D, Hinojosa-Azaola A. Prevalence of overlap of antineutrophil cytoplasmic antibody associated vasculitis with systemic autoimmune diseases: an unrecognized example of poliautoimmunity. *Clin Rheumatol.* 2019;38(1):97–106. doi:10.1007/s10067-018-4212-1
- Caramaschi P, Biasi D, Tonolli E, Carletto A, Bambara LM. Antineutrophil cytoplasmic antibodies in scleroderma patients: first report of a case with anti-proteinase 3 antibodies and review of the literature. *Joint Bone Spine.* 2002;69(2):177–180. doi:10.1016/s1297-319x(02)00367-6
- Ruffatti A, Sinico RA, Radice A, et al. Autoantibodies to proteinase 3 and myeloperoxidase in systemic sclerosis. *J Rheumatol.* 2002;29(5):918–923.
- Hashimoto H. Microscopic polyangiitis in systemic sclerosis. *Int J Rheumatol.* 2010;2010:148528. doi:10.1155/2010/148528
- Quéménéur T, Mouthon L, Cacoub P, et al. Systemic vasculitis during the course of systemic sclerosis: report of 12 cases and review of the literature. *Medicine.* 2013;92(1):1–9. doi:10.1097/MD.0b013e31827781fd
- Moxey J, Huq M, Proudman S, et al. Significance of anti-neutrophil cytoplasmic antibodies in systemic sclerosis. *Arthritis Res Ther.* 2019;21(1):57. doi:10.1186/s13075-019-1839-5
- Kamen DL, Wigley FM, Brown AN. Antineutrophil cytoplasmic antibody-positive crescentic glomerulonephritis in scleroderma—a different kind of renal crisis. *J Rheumatol.* 2006;33(9):1886–1888.
- Kant S, Shah AA, Hummers LK, Wigley FM, Geetha D. ANCA-associated vasculitis in scleroderma: a renal perspective. *Clin Nephrol.* 2018;90(6):413–418. doi:10.5414/CN109445
- Mahakkanukrauh A, Suwannaroj S, Nanagara R, Foocharoen C. Prevalence and clinical association of the presence of anti-neutrophilic cytoplasmic antibody in systemic sclerosis. *Arch Med Sci.* 2020. doi:10.5114/aoms.2019.85172
- van den Hoogen F, Khanna D, Fransen J, et al. 2013 classification criteria for systemic sclerosis: an American college of rheumatology/European league against rheumatism collaborative initiative. *Ann Rheum Dis.* 2013;72(11):1747–1755. doi:10.1136/annrheumdis-2013-204424
- LeRoy EC, Black C, Fleischmajer R, et al. Scleroderma (systemic sclerosis): classification, subsets and pathogenesis. *J Rheumatol.* 1988;15(2):202–205.
- Suppiah R, Robson JC, Grayson PC, et al. 2022 American College of Rheumatology/European Alliance of Associations for Rheumatology Classification Criteria for Microscopic Polyangiitis. *Arthritis Rheumatol.* 2022;74(3):400–406. doi:10.1002/art.41983
- Grayson PC, Ponte C, Suppiah R, et al. 2022 American College of Rheumatology/European Alliance of Associations for Rheumatology Classification Criteria for Eosinophilic Granulomatosis With Polyangiitis. *Arthritis Rheumatol.* 2022;74(3):386–392. doi:10.1002/art.41982
- Robson JC, Grayson PC, Ponte C, et al. 2022 American College of Rheumatology/European Alliance of Associations for Rheumatology Classification Criteria for Granulomatosis With Polyangiitis. *Arthritis Rheumatol.* 2022;74(3):393–399. doi:10.1002/art.41986
- Jennette JC, Falk RJ, Bacon PA, et al. 2012 revised International Chapel Hill Consensus Conference Nomenclature of Vasculitides. *Arthritis Rheum.* 2013;65(1):1–11. doi:10.1002/art.37715
- Jennette JC, Falk RJ, Andrassy K, et al. Nomenclature of systemic vasculitides. Proposal of an international consensus conference. *Arthritis Rheum.* 1994;37(2):187–192. doi:10.1002/art.1780370206
- Janion M. The Classification Of Cardiac Diagnosis. *JAMA.* 1921;77(18):1414–1415. doi:10.1001/jama.1921.02630440034013
- Simonneau G, Montani D, Celermajer DS, et al. Haemodynamic definitions and updated clinical classification of pulmonary hypertension. *Eur Respir J.* 2019;53(1). doi:10.1183/13993003.01913-2018
- Penn H, Howie AJ, Kingdon EJ, et al. Scleroderma renal crisis: patient characteristics and long-term outcomes. *QJM: Int J Med.* 2007;100(8):485–494. doi:10.1093/qjmed/hcm052
- Savarino E, Furnari M, de Bortoli N, et al. Gastrointestinal involvement in systemic sclerosis. *La Presse Médicale.* 2014;43(10, Part 2):e279–e291. doi:10.1016/j.lpm.2014.03.029
- Domenica Cappellini M, Motta I. Anemia in Clinical Practice—Definition and Classification: does Hemoglobin Change With Aging? *Semin Hematol.* 2015;52(4):261–269. doi:10.1053/j.seminhematol.2015.07.006
- Tefferi A, Patnaik MM, Pardanani A. Eosinophilia: secondary, clonal and idiopathic. *Br J Haematol.* 2006;133(5):468–492. doi:10.1111/j.1365-2141.2006.06038.x
- Asano Y, Sato S. Vasculopathy in scleroderma. *Semin Immunopathol.* 2015;37(5):489–500. doi:10.1007/s00281-015-0505-5
- Wigley FM. Vascular disease in scleroderma. *Clin Rev Allergy Immunol.* 2009;36(2–3):150–175. doi:10.1007/s12016-008-8106-x
- Kao L, Weyand C. Vasculitis in systemic sclerosis. *Int J Rheumatol.* 2010;2010:385938. doi:10.1155/2010/385938
- Guchelaar NAD, Waling MM, Adhin AA, van Daele PLA, Schreurs MWJ, Rombach SM. The value of anti-neutrophil cytoplasmic antibodies (ANCA) testing for the diagnosis of ANCA-associated vasculitis, a systematic review and meta-analysis. *Autoimmunity Rev.* 2021;20(1):102716. doi:10.1016/j.autrev.2020.102716
- Falk RJ, Jennette JC. Anti-Neutrophil Cytoplasmic Autoantibodies with Specificity for Myeloperoxidase in Patients with Systemic Vasculitis and Idiopathic Necrotizing and Crescentic Glomerulonephritis. *N Engl J Med.* 1988;318(25):1651–1657. doi:10.1056/NEJM198806233182504
- Jennette JC, Wilkman AS, Falk RJ. Diagnostic predictive value of ANCA serology. *Kidney Int.* 1998;53(3):796–798. doi:10.1038/ki.1998.36
- Niles JL, Pan GL, Collins AB, et al. Antigen-specific radioimmunoassays for anti-neutrophil cytoplasmic antibodies in the diagnosis of rapidly progressive glomerulonephritis. *J Am Soc Nephrol.* 1991;2(1):27–36.
- Clark KE. Review of systemic sclerosis and antineutrophil cytoplasmic antibody vasculitis overlap: using autoantibodies for a personalised medicine approach. *J Scleroderma Relat Disord.* 2023;8(1):7–13. doi:10.1177/23971983221126850
- Derrett-Smith EC, Nihtyanova SI, Harvey J, Salama AD, Denton CP. Revisiting ANCA-associated vasculitis in systemic sclerosis: clinical, serological and immunogenetic factors. *Rheumatology.* 2013;52(10):1824–1831. doi:10.1093/rheumatology/ket213

33. Liang KP, Michet CJ. ANCA-associated vasculitis in scleroderma: a case series of fourteen patients. *Rheumatology Reports*. 2011;3(1):e2–e2. doi:10.4081/rr.2011.e2
34. Steen VD, Medsger TA. Changes in causes of death in systemic sclerosis, 1972-2002. *Ann Rheum Dis*. 2007;66(7):940–944. doi:10.1136/ard.2006.066068
35. Arad U, Balbir-Gurman A, Doenyas-Barak K, Amit-Vazina M, Caspi D, Elkayam O. Anti-neutrophil antibody associated vasculitis in systemic sclerosis. *Semin Arthritis Rheum*. 2011;41(2):223–229. doi:10.1016/j.semarthrit.2010.11.001

Clinical, Cosmetic and Investigational Dermatology

Dovepress

**Publish your work in this journal**

Clinical, Cosmetic and Investigational Dermatology is an international, peer-reviewed, open access, online journal that focuses on the latest clinical and experimental research in all aspects of skin disease and cosmetic interventions. This journal is indexed on CAS. The manuscript management system is completely online and includes a very quick and fair peer-review system, which is all easy to use. Visit <http://www.dovepress.com/testimonials.php> to read real quotes from published authors.

Submit your manuscript here: <https://www.dovepress.com/clinical-cosmetic-and-investigational-dermatology-journal>