

Two Novel and Three Recurrent Mutations in the Mevalonate Pathway Genes in Chinese Patients with Porokeratosis

Xiuping Wang¹, Xiaoliang Ouyang², Deng Zhang¹, Yunxia Zhu¹, Liang Wu¹, Zhen Xiao³, Simin Yu¹, Wei Li², Chunming Li¹

¹Department of Dermatology, The Second Affiliated Hospital of Nanchang University, Nanchang, Jiangxi, People's Republic of China; ²Department of Plastic Surgery, The Second Affiliated Hospital of Nanchang University, Nanchang, Jiangxi, People's Republic of China; ³Department of Dermatology, Taiyuan Central Hospital, Taiyuan, Shanxi, People's Republic of China

Correspondence: Chunming Li, Department of Dermatology, The Second Affiliated Hospital of Nanchang University, Nanchang, Jiangxi, People's Republic of China, Tel/Fax +86 791 86278821, Email chunmingli@163.com

Purpose: Porokeratosis (PK) is a chronic autosomal-dominant cutaneous keratinization disorder exhibiting clinical and genetic heterogeneity. Mevalonate decarboxylase (*MVD*), farnesyl diphosphate synthase (*FDPS*), phosphomevalonate kinase (*PMVK*), and mevalonate kinase genes (*MVK*), which encode the mevalonate pathway, are disease-causing genes in PK.

Patients and Methods: Data and blood samples were collected from two Chinese families and five sporadic patients with porokeratosis. Whole-exome and Sanger sequencing were performed to detect pathogenic gene mutation in the patients.

Results: Five heterozygous mutations were identified, including a novel *FDPS* stop-gain mutation c.438T>G (p.Tyr146Ter), a novel *MVD* missense mutation c.683G>C (p.R228P), and three previously reported *MVD* mutations: c.746T>C (p.F249S), c.875A>G (p.N292S), and c.1111_1113del (p.371_371del). The novel *FDPS* c.438T>G mutation was predicted as “disease-causing” (p = 1) by Mutation Taster. The other novel *MVD* c.683G>C was also predicted as “deleterious” (score = 0.00) by Sorting Intolerant From Tolerant (SIFT), “probably damaging” (score = 1) by PolyPhen2, and “disease-causing” (p = 0.999) by Mutation Taster.

Conclusion: Our results extended the mutation spectrum of mevalonate pathway genes in porokeratosis and provided useful strategies for a more accurate diagnosis and genetic counseling.

Keywords: porokeratosis, mutation, *MVD*, *FDPS*, genetics

Introduction

Porokeratosis (PK; OMIM 175800) is a rare, clinically, and genetically heterogeneous disorder with abnormal epidermal differentiation that exhibits autosomal dominant inheritance. PK manifests as sharply demarcated hyperkeratotic papules and plaques with prominent peripheral ridging and central atrophy. Histologically, this characteristic feature is called the cornoid lamella, which is a column of parakeratotic cells in the epidermis. Based on the distribution and morphology of the lesions, PK is classified into several clinical variants, including disseminated superficial porokeratosis (DSP), linear porokeratosis (LP), disseminated superficial actinic porokeratosis (DSAP), porokeratosis of Mibelli (PM), and porokeratosis palmaris, plantaris, and disseminata (PPPD). Several rare clinical types, such as giant porokeratosis, porokeratosis ptychotropica, and punctate porokeratosis (PP), have also been reported.^{1,2} LP is at a certain risk of cancerous transformation into squamous or basal cell carcinoma.^{3,4} Four mevalonate pathway genes, including farnesyl diphosphate synthase (*FDPS*), mevalonate decarboxylase (*MVD*), phosphomevalonate kinase (*PMVK*), and mevalonate kinase (*MVK*) are PK disease-causing genes.^{3,5}

We performed whole-exome sequencing (WES) and Sanger sequencing to explore the pathogenic mutations in two Chinese families and five sporadic cases of porokeratosis. In addition, the pathogenicity was predicted via bioinformatics analysis.

Materials and Methods

Patients Recruitments and Sample Collection

Data and blood samples were collected from two Chinese families (one DSAP and DSP) and five sporadic cases (three DSP and two LP) between September 2021 and October 2022. PK was diagnosed based on clinical presentation and histological examination. All procedures were approved by the Ethics Committee of the Second Affiliated Hospital of Nanchang University. Approximately 5 mL of peripheral blood or 1 mL of saliva was collected from the participants. Written informed consent was obtained.

Whole-Exome Sequencing

Probands from two Chinese families and five patients with sporadic PK were selected for WES. DNA was isolated from peripheral blood, and a whole-exome library was constructed. Subsequently, a HiSeq 2000 Sequencing System (Illumina, San Diego, CA, USA) was used to perform a 2×150 bp paired-end massively parallel sequencing. Finally, Single Nucleotide Variants (SNVs) were filtered, and their functional effects were assessed by Mutation Taster (<http://www.mutationtaster.org/>), Sorting Intolerant From Tolerant (SIFT) (<https://sift.bii.a-star.edu.sg/>), and PolyPhen-2 (<http://genetics.bwh.harvard.edu/pph2/>).

Sanger Sequencing

Sanger sequencing confirmed the suspected pathogenic mutations. Primer pairs amplified the exons, including the exon/intron boundaries, by polymerase chain reaction (PCR) (Table 1). Samples were subsequently amplified by PCR, and products were directly sequenced using a 3730xl Genetic Analyzer (Applied Biosystems). Sequence comparisons and analyses were performed using PolyPhred Analysis Software.

Results

Clinical Manifestation of Porokeratosis

Two Chinese families and five sporadic cases were included in this study. These patients were diagnosed with PK based on typical clinical manifestations and histological features. The proband in family 1 (II-3) was diagnosed with DSP. The patient was a 73-year-old man with a 16-year history of multiple keratotic papules on the trunk, arms, and legs (Figure 1A). He showed no obvious symptoms. His daughter (III-4) had similar lesions on her face. The proband in family 2 (II-3) was diagnosed with DSAP. A 36-year-old woman presented with scattered superficial keratinized papules on her face at 31 years of age (Figure 1B). The lesions resolved slightly after CO₂ laser treatment; however, new lesions reappeared on the patient's face within approximately 6 months. The patient's mother had similar lesions in the same location. Sporadic cases 1–3 were diagnosed with DSP and showed typical keratotic papules involving the neck, trunk, arms, and legs (Figure 1C–E). Sporadic cases 4 and 5 were diagnosed with LP. Sporadic case 4 was a 22-year-old man with a 20-year history of annular linear plaques distributed along Blaschko's lines on his left arm, back, and chest (Figure 1F). The patient complained of obvious pruritus and scratches on his back. Sporadic case 5 had several asymptomatic "black dots" on the flexed side of his left lower limbs that gradually enlarged after birth. The lesions spread to the left side of the trunk and arms after a decade (Figure 1G).

Table 1 Amplification and Sequencing Primer Pairs

Gene	Mutation	Forward Primer	Reverse Primer
MVD	c.875A>G	CACACAGCAGGGTGGAGCTTTCA	AAGACCACGTGCAGGAGCCAAAT
MVD	c.746T>C	CACACAGCAGGGTGGAGCTTTCA	AAGACCACGTGCAGGAGCCAAAT
MVD	c.683G>C	CACACAGCAGGGTGGAGCTTTCA	AAGACCACGTGCAGGAGCCAAAT
MVD	c.1111_1113del	CACTTTGAGAGCAAATGAATGGA	ACTGTTGTAGACGCTTAGAGAAACG
FDPS	c.438T>G	AACCGAGACTAGAGATTGATTGCTTG	TACACACAGTCCTTTATCACCCTTTCT

Abbreviations: MVD, mevalonate decarboxylase; FDPS, farnesyl diphosphate synthase.

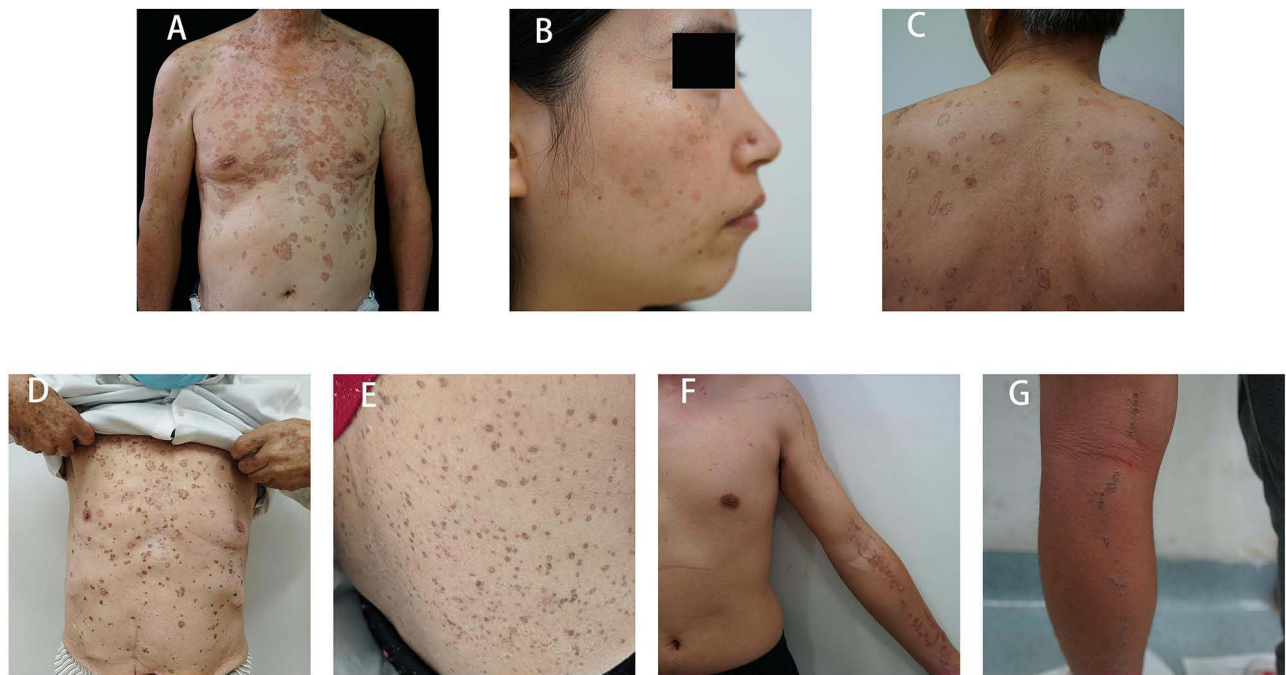


Figure 1 Clinical manifestations of the proband of two families and five sporadic cases. **(A)** Multiple, red-brown annular keratotic papules and plaques on the trunk and arms of the proband in families 1 with disseminated superficial porokeratosis (DSP); **(B)** Irregular annular and slightly elevated papules on the face of the proband in families 2 with disseminated superficial actinic porokeratosis (DSAP); **(C–E)** Multiple rounded hyperkeratotic plaques with central atrophy and peripheral ridging on the trunk of sporadic cases 1–3 with DSP; **(F and G)** Annular linear plaques on the limbs of sporadic cases 4–5 with linear porokeratosis (LP).

Mutation Analysis of Porokeratosis

Pedigrees for the two families and sporadic cases 4 and 5 included in this study are shown in [Figure 2A](#). Two novel and three recurrent heterozygous mutations were detected ([Table 2](#)). The novel *FDPS* stop-gain mutation, c.438T>G: p. Tyr146Ter, in exon 5 was found in sporadic case 3. Another novel *MVD* mutation, c.683G>C: p.R228P, in exon 7 was detected in sporadic case 5 and in his asymptomatic father. Three recurrent *MVD* mutations were also found in family 2 and three sporadic cases. The *MVD* mutation c.746T>C: p.F249S in exon 7 was found in sporadic cases 1, 2, and 4. The same mutation was detected in the patient's asymptomatic father and sister in sporadic case 4. The *MVD* mutation c.875A>G: p. N292S in exon 7 was identified in family 1. The *MVD* mutation c.1111_1113del: p.371_371del in exon 9 was detected in family 2 ([Figure 2B](#)).

Bioinformatics Analysis of the Mutation

All mutations were classified as disease-causing variants according to Mutation Taster, polyphen2, and SIFT. The novel *FDPS* c.438T>G mutation was predicted as “disease-causing” ($p = 1$) by Mutation Taster. The other novel *MVD* c.683G>C was also predicted as “deleterious” (score = 0.00) by SIFT, “probably damaging” (score = 1) by PolyPhen2, and “disease-causing” ($p = 0.999$) by Mutation Taster. For novel mutations, we constructed a 3D model of the wild-type proteins and the mutant proteins *FDPS* c.438T>G: p. Tyr146Ter ([Figure 3A and B](#)) and *MVD* c.683G>C ([Figure 3C and D](#)) using Swiss-Model (<http://swissmodel.expasy.org>).

Discussion

Mibelli et al first reported and described porokeratosis more than 100 years ago;⁶ however, its etiology and pathogenesis remain insufficiently understood. Exposure to ultraviolet, genetic susceptibility, immunosuppression, radiation, drugs and viral infections were considered risk factors for PK.^{7–11} In 2012, mutations in *MVK*, a mevalonate pathway gene, were identified as causative genes for DSAP. Subsequently, other mevalonate pathway genes, including *FDPS*, *MVD*, and *PMVK*, have been associated with PK. These gene mutations affect cholesterol synthesis, further affecting keratinocyte

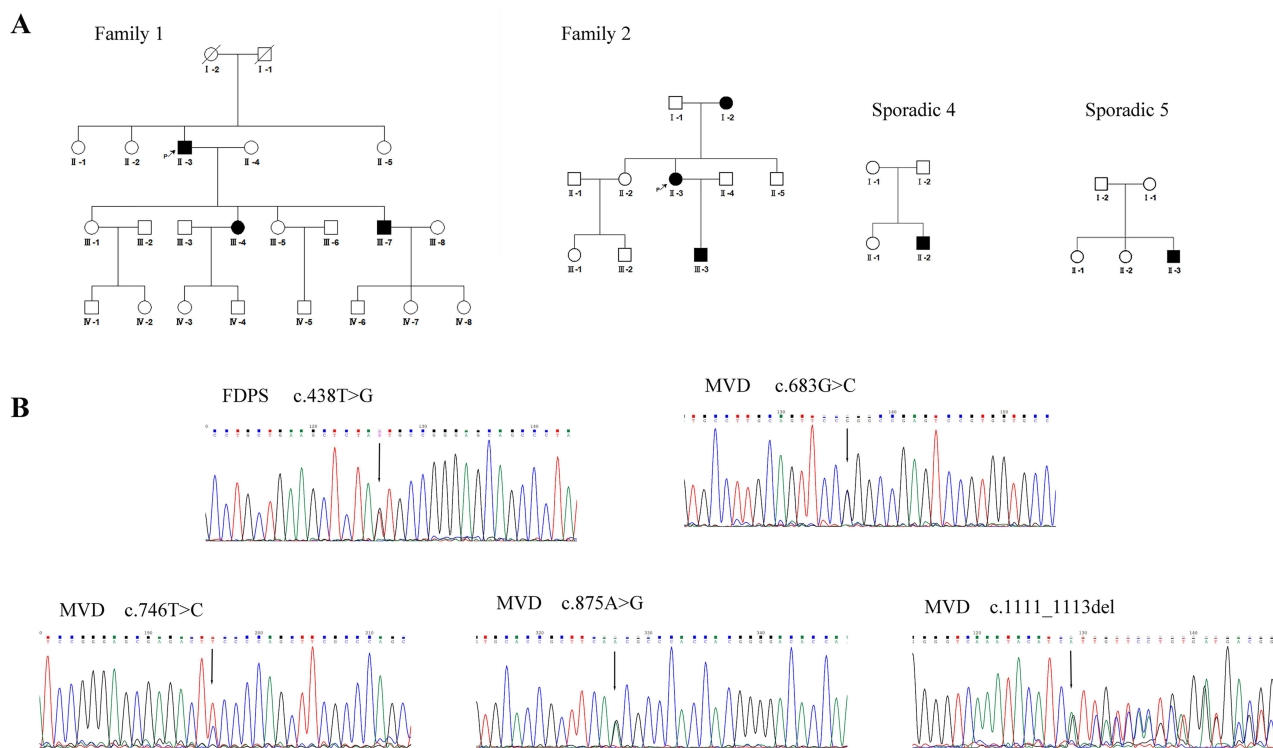


Figure 2 Pedigree chart and genetic mutation of PK in this study. **(A)** The pedigree chart of families 1–2 and sporadic cases 4–5. The filled symbols represent affected members; the arrow indicates the proband. **(B)** Mutational analysis of mevalonate pathway genes. The black arrow shows the mutation site.

keratinization.^{12,13} In 2015, Zhang et al reported that *FDPS*, *MVD*, *PMVK*, and *MVK* mutations were detected in 73% of sporadic PK cases and 98% of the pedigree with PK.⁵

We identified causative mutations in two Chinese families and five sporadic cases, including two novel and three recurrent heterozygous mutations. The novel *FDPS* mutation c.438T>G was found in sporadic case 3 with DSP. This new stop-gain mutation turns the tyrosine at position 146 into a termination codon. This makes 208 amino acids after position 146 of *FDPS* untranslatable, leading to domain deletion and impairment of the function of farnesyl diphosphate synthase. This was the second nonsense mutation in *FDPS* has been reported to date. To date, only eight mutations in *FDPS* have been identified: one nonsense, three missense, two splicing, and two gross deletion mutations.^{5,14–17} The other new *MVD* mutation, c.683G>C, found in sporadic case 5 with LP, was a missense mutation, leading to arginine substitution at codon 228 by proline. The same site *MVD* mutation variant c.683G>A was reported by Zhang et al in 2015.⁵ In addition, two of

Table 2 Clinical Characteristics and Gene Mutations in Patients with Porokeratosis

Family/Spora Dic Case	Subtype of Disease	Mutation					
		Gene	Exon	Nucleotide Substitution	Amino Acid Change	Type	Remarks
Family 1	DSP	<i>MVD</i>	7	c.875A>G	p.Asn292Ser	Missense	Reported
Family 2	DSAP	<i>MVD</i>	9	c.1111_1113del	p.371_371del	Inframe	Reported
Sporadic case 1	DSP	<i>MVD</i>	7	c.746T>C	p.Phe249Ser	Missense	Reported
Sporadic case 2	DSP	<i>MVD</i>	7	c.746T>C	p.Phe249Ser	Missense	Reported
Sporadic case 3	DSP	<i>FDPS</i>	5	c.438T>G:	p.Tyr146X	Nonsense	Novel
Sporadic case 4	LP	<i>MVD</i>	7	c.746T>C	p.Phe249Ser	Missense	Reported
Sporadic case 5	LP	<i>MVD</i>	7	c.683G>C	p.Arg228Pro	Missense	Novel

Abbreviations: DSP, disseminated superficial porokeratosis; DSAP, disseminated superficial actinic porokeratosis; LP, linear porokeratosis; *MVD*, mevalonate decarboxylase; *FDPS*, farnesyl diphosphate synthase.

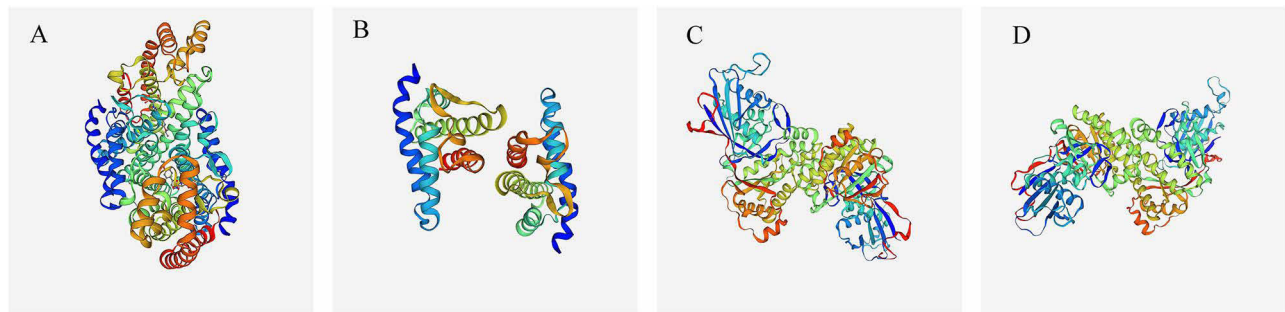


Figure 3 Three-dimensional structure of wild-type proteins and the novel mutant proteins of PK in this study. **(A)** Original 3D structure of FDPS; **(B)** 3D structure of the protein products of FDPS c.438T>G; **(C)** Original 3D structure of MVD; **(D)** 3D structure of the protein products of MVD c.683G>C.

the three recurrent *MVD* mutations are hotspot mutations: c.746T>C: p. Phe249Ser and c.875A>G: p. Asn292Ser.^{5,14,17,18} Another previously reported *MVD* mutation, c.1111_1113del: p.371_371del, is a deletion mutation that results in isoleucine deletion at codon 371.⁵

In our study, there is a wide range of onset age in patients with *MVD* mutations, spanning from months after birth to over 50 years old. Besides, the diameter of the lesions was relatively uniform and generally less than 2 cm. This finding is consistent with the study of Zhang et al, which analyzed genotype-phenotype correlations in PK patients.⁵ LP usually develops during childhood.¹⁹ However, we found that some adult family members of the two patients with LP (sporadic cases 4 and 5), who carried the same *MVD* mutation, were asymptomatic. One possible explanation is that these unaffected members later developed other PK subtypes. Members carrying the same mutation in the same family can manifest different clinical subtypes.²⁰ Another possible explanation is that the LP had incomplete penetrance. Porokeratosis is an inherited autosomal dominant disorder with variable penetrance. Based on the “two hits” hypothesis, a trigger factor on a genetically predisposed individual that could lead to the onset of PK. Leng et al,²¹ Qian et al,²² and Arisawa et al,²³ reported that some older, unaffected individuals in families with DSAP/DSP have the same mutation. Hence, genetic testing and long-term skin examinations of family members of sporadic cases are necessary.

This study had some potential limitations, including a relatively small study population and lack of genetic testing of skin samples.

Conclusion

In summary, we detected two novel and three recurrent mutations in the mevalonate pathway genes in two families and five Chinese patients with sporadic PK. Our results extend the mutation spectrum of mevalonate pathway genes in porokeratosis and provide useful strategies for a more accurate diagnosis and genetic counseling. Besides, long-term follow-up is needed both for a possible late-onset manifestation and also for the possible malignant transformation of PK.

Data Sharing Statement

All the data used for the analyses in this study are available from the corresponding author upon reasonable request. The mutations identified in this study can be found in the GenBank online repositories (accession numbers: OR354918, OR354919, OR354920, OR354921, OR354922, <https://www.ncbi.nlm.nih.gov/genbank/>).

Ethics Approval and Consent to Participate

All procedures performed in studies involving human participants were in accordance with the ethical standards of the Ethics Committee of the Second Affiliated Hospital of Nanchang University and with the 1964 Helsinki declaration and its later amendments or comparable ethical standards. Informed consent was obtained from all individual participants included in the study. The authors affirm that human research participants provided informed consent for publication of the images in Figure 1.

Acknowledgments

We thank all patients and their family members for participating in this study.

Funding

This study was funded by the National Natural Science Foundation of China (Project No. 81960569) and the Natural Science Foundation of Jiangxi Province (Project No. 20232BAB206126).

Disclosure

The authors have no relevant financial or non-financial interests to disclose for this work.

References

1. Peng JM, Xiao XM, Chen JW, et al. Novel mutation in MVK gene for co-occurrence of disseminated superficial actinic porokeratosis with porokeratosis ptychotropica. *J Dermatol*. 2021;48(3):e137–e139. doi:10.1111/1346-8138.15748
2. Xu HJ, Wen GD. Mixed porokeratosis with a novel mevalonate kinase gene mutation: a case report. *World J Clin Cases*. 2022;10(14):4528–4534. doi:10.12998/wjcc.v10.i14.4528
3. Zhang SQ, Jiang T, Li M, et al. Exome sequencing identifies MVK mutations in disseminated superficial actinic porokeratosis. *Nat Genet*. 2012;44(10):1156–1160. doi:10.1038/ng.2409
4. Inci R, Zagoras T, Kantere D, et al. Porokeratosis is one of the most common genodermatoses and is associated with an increased risk of keratinocyte cancer and melanoma. *J Eur Acad Dermatol Venereol*. 2023;37(2):420–427. doi:10.1111/jdv.18587
5. Zhang ZH, Li CH, Wu F, et al. Genomic variations of the mevalonate pathway in porokeratosis. *Elife*. 2015;4:e06322. doi:10.7554/eLife.06322
6. Oliveira RTG, Simoneti FS, Agostinho GLPL, et al. A rare case of multiple variants of porokeratosis in the same patient: the clue of dermoscopy for diagnosis and therapeutic update. *Dermatol Ther*. 2020;33(3):e13274. doi:10.1111/dth.13274
7. Liu Y, Wang JX, Qin YY, et al. Identification of three mutations in the MVK gene in six patients associated with disseminated superficial actinic porokeratosis. *Clin Chim Acta*. 2016;454:124–129. doi:10.1016/j.cca.2016.01.009
8. Abramovits W, Oquendo M. Introduction to autoinflammatory syndromes and diseases. *Dermatol Clin*. 2013;31(3):363–385. doi:10.1016/j.det.2013.04.010
9. Dumas M, Corre F, Payance A, et al. Eruptive disseminated superficial porokeratosis associated with acute hepatitis E. *Ann Dermatol Venereol*. 2019;146(10):655–658. doi:10.1016/j.annder.2019.05.004
10. Lu WS, Zheng XD, Yao XH, et al. A novel MVK missense mutation in one Chinese family with disseminated superficial actinic porokeratosis. *Mol Biol Rep*. 2014;41(11):7229–7233. doi:10.1007/s11033-014-3609-4
11. Romagnuolo M, Riva D, Violetti SA, et al. Disseminated superficial actinic porokeratosis following hydroxyurea treatment: a case report. *Australas J Dermatol*. 2023;64(1):e72–e75. doi:10.1111/ajd.13943
12. Jin R, Luo X, Luan K, et al. Disorder of the mevalonate pathway inhibits calcium-induced differentiation of keratinocytes. *Mol Med Rep*. 2017;16(4):4811–4816. doi:10.3892/mmr.2017.7128
13. Zhu T, Tian D, Zhang L, et al. Novel mutations in mevalonate kinase cause disseminated superficial actinic porokeratosis. *Br J Dermatol*. 2019;181(2):304–313. doi:10.1111/bjd.17596
14. Li M, Li Z, Wang J, et al. Mutations in the mevalonate pathway genes in Chinese patients with porokeratosis. *J Eur Acad Dermatol Venereol*. 2016;30(9):1512–1517. doi:10.1111/jdv.13653
15. Zhu PQ, Yan HM, Zhao HJ, et al. A novel premature termination mutation in FDPS in a Chinese family with disseminated superficial actinic porokeratosis. *Br J Dermatol*. 2019;180(6):1545–1546. doi:10.1111/bjd.17531
16. Li L, Zuo N, Yang DY, et al. Novel missense mutations of MVK and FDPS gene in Chinese patients with disseminated superficial actinic porokeratosis. *Clin Chim Acta*. 2021;523:441–445. doi:10.1016/j.cca.2021.10.026
17. Shi WH, Fu XA, Wang ZZ, et al. Twenty-two novel mutations in a Chinese cohort of 137 patients with porokeratosis were identified using microfluidics (Fluidigm). *J Dermatol Sci*. 2021;101(1):75–77. doi:10.1016/j.jderm.2020.10.013
18. Tao L, Huang YK, Yan KX, et al. A preliminary study of peripheral T-cell subsets in porokeratosis patients with MVK or MVD variants. *Skin Health Dis*. 2022;2(1):e82. doi:10.1002/ski.2.82
19. Chen HH, Liao YH. Onychodystrophy in congenital linear porokeratosis. *Br J Dermatol*. 2002;147(6):1272–1273. doi:10.1046/j.1365-2133.2002.05000_7.x
20. Shiiya C, Aoki S, Nakabayashi K, et al. Linear and disseminated porokeratosis in one family showing identical and independent second hits in MVD among skin lesions, respectively: a proof-of-concept study. *Br J Dermatol*. 2021;184(6):1209–1212. doi:10.1111/bjd.19824
21. Leng YJ, Yan LL, Feng HQ, et al. Mutations in mevalonate pathway genes in patients with familial or sporadic porokeratosis. *J Dermatol*. 2018;45(7):862–866. doi:10.1111/1346-8138.14343
22. Qian WJ, Wu J, Tang HY, et al. Mutation analysis of the MVD gene in a Chinese family with disseminated superficial actinic porokeratosis and a Chinese literature review. *Indian J Dermatol*. 2021;66(2):126–131. doi:10.4103/ijd.IJD_226_18
23. Arisawa Y, Ito Y, Tanahashi K, et al. Two cases of porokeratosis with MVD mutations, in association with bullous pemphigoid. *Acta Derm Venereol*. 2021;101(3):adv00423. doi:10.2340/00015555-3764

Clinical, Cosmetic and Investigational Dermatology

Dovepress

Publish your work in this journal

Clinical, Cosmetic and Investigational Dermatology is an international, peer-reviewed, open access, online journal that focuses on the latest clinical and experimental research in all aspects of skin disease and cosmetic interventions. This journal is indexed on CAS. The manuscript management system is completely online and includes a very quick and fair peer-review system, which is all easy to use. Visit <http://www.dovepress.com/testimonials.php> to read real quotes from published authors.

Submit your manuscript here: <https://www.dovepress.com/clinical-cosmetic-and-investigational-dermatology-journal>