

A Rapid and Safe Minimally Invasive Procedure for Percutaneous Pedicle Screw Removal: A Case-Control Study and Technical Description

Yan Ding^{1,*}, Banqin Wang^{2,*}, Yongjun Liu¹, Shengjie Dong¹, Xuri Sun¹, Zhilin Cao¹, Leisheng Wang¹

¹Department of Orthopedics, Yantaishan Hospital, Yantai, People's Republic of China; ²Department of Blood Transfusion, Shandong Provincial Qianfoshan Hospital Affiliated with Shandong First Medical University, Jinan, People's Republic of China

*These authors contributed equally to this work

Correspondence: Leisheng Wang, Department of Orthopedics, Yantaishan Hospital, No. 10087 Keji Road, Yantai, 264003, People's Republic of China, Tel +86-13792566016; +86-0535-6863898, Email 37724148@qq.com

Purpose: Percutaneous pedicle screw fixation is a common minimally invasive treatment for traumatic thoracolumbar and lumbar fractures; however, research on hardware removal after successful healing is limited. We aimed to introduce a rapid, safe, minimally invasive, and cost-effective method for percutaneous pedicle screw removal.

Patients and Methods: We conducted a retrospective analysis of demographic (age, sex, body mass index, alcohol use, and current smoking), clinical (hypertension and diabetes mellitus), surgical (affected levels, number of screws, time of surgery, and blood loss), and treatment cost characteristics of 92 patients who had undergone percutaneous pedicle screw removal between May 2016 and February 2023. The first 57 patients underwent the conventional method, and the remaining 35 underwent the modified method. Independent-sample *t*-tests and chi-square tests were used to compare continuous and categorical variables, respectively, between the two groups.

Results: No significant differences were observed in the demographic parameters, complications, or affected levels between the groups. However, the average surgical time ($P=0.000$) was significantly shorter, and the average blood loss volume ($P=0.002$) and total cost ($P=0.000$) were significantly lower in the modified group than in the conventional group.

Conclusion: Compared with the conventional method, our modified method can shorten the surgical time, reduce blood loss, and reduce the total cost of treatment. It is a quick and safe minimally invasive method that does not require additional surgical instruments and is suitable for implementation in primary hospitals.

Keywords: bone screw, device, Kirschner wire, surgery, control

Introduction

The incidence of thoracolumbar and lumbar fractures resulting from traumatic events is high; thus, they are a leading cause of hospitalization and disability.¹ Conservative treatment, especially bed rest, can cause deep venous thrombosis, respiratory system disease, pressure ulcers, and psychological distress.^{2,3} Consequently, surgery is the most frequently used treatment, especially among relatively young patients who require adequate stability and restoration of normal spinal alignment.⁴ Non-fusion surgery with short posterior segmental fixation has reportedly shown good therapeutic effects in recent decades.⁴⁻⁶ Percutaneous pedicle screw fixation can alleviate the disadvantages of the open approach, such as stripping-induced muscle denervation, increased intramuscular pressure, ischemia, back pain, and physical dysfunction.⁷ Meanwhile, the clinical efficacy and radiological results are similar to those of the conventional open technique.⁸⁻¹¹ Theoretically, non-fusion surgery preserves the regional mobility of the affected spine. However, all implants used in non-fusion surgeries should be removed because of the potential risk of implant breakage caused by long-term fretting wear of the non-fusion segments.¹ The

advantages of implant removal after bone consolidation include early mobilization, minimal soft tissue irritation, and regional mobility preservation.⁸

Previous studies have focused on implant removal to reduce potential hazards and improve clinical outcomes.^{1,12–14} Nevertheless, to our knowledge, only one cohort study with 10 cases¹⁵ and one case report¹⁶ have documented techniques for removing percutaneous pedicle screws, and no case-control research on surgical technology is available. Both studies required specialized surgical instruments, limiting their applicability. The aim of this case-control study was to introduce a rapid and safe minimally invasive method for removing percutaneous pedicle screws without the need for special surgical instruments.

Materials and Methods

Setting

This retrospective study included 92 patients who underwent percutaneous pedicle screw removal after successful posterior non-fusion fixation of traumatic thoracolumbar or lumbar fractures at our hospital between May 2016 and February 2023. The first 57 patients underwent the conventional method from May 2016 to June 2021. Subsequently, we developed a modified method through communication and discussion in our department. Thus, the last 35 patients underwent the modified method between July 2021 and February 2023.

Participants

The inclusion criteria were: (1) implant removal after non-fusion posterior percutaneous pedicle screw fixation; (2) initial fractures at the level from T10 to L5; and (3) bony consolidation of the affected vertebrae confirmed by radiological images before removal. The exclusion criteria were: (1) fractures above the level of T10; (2) initial fractures treated using open posterior fixation or other fixation techniques; (3) initial surgical complications, such as infection and neurological deficits; and (4) unavailability of complete clinical and radiological data.

This study was conducted in accordance with the principles of the Declaration of Helsinki and approved by the ethics committee of Yantaishan Hospital (approval no. 2023105). Written informed consent was obtained from each patient, or their authorized signatory, whose images or clinical data were used.

Variables and Data Measurement

All patients who had undergone non-fusion percutaneous posterior fixation for traumatic thoracolumbar or lumbar fractures required follow-up assessments using X-rays every 3 months. Computed tomography scanning was recommended if the healing status of the fractured vertebrae was uncertain. When vertebral healing was observed, implant removal was suggested.¹⁷ Patient demographics (age, sex, body mass index, alcohol use, and current smoking status), clinical (hypertension and diabetes mellitus), surgical (affected levels, number of screws, time of surgery, and blood loss), and treatment cost characteristics were extracted from medical records and analyzed. The number of screws was varied between four and six (not fixed); thus, we compared the average time (surgical time/number of screws) and average blood loss volume (blood loss volume/number of screws) instead of the absolute surgical time and blood loss volume to account for individual differences.

Surgical Technique

All operations were performed by experienced and qualified surgeons. While screw systems varied, the methods for hardware removal remained consistent.¹⁵ All procedures were performed under general anesthesia with the patient in the prone position. For conventional removal surgery, we cut through the soft tissue, explored the hardware, and removed the plugs, rods, and screws individually. In the modified removal surgery, the previous skin incision was re-opened, cutting through all layers until the scalpel reached the end of the screw and plug. The assistant then widened the incision using a vessel clamp, allowing the operator to insert a system-specific set screw-retaining compressor into the plug hole and drive it out. The same process was repeated to remove other plugs on the ipsilateral side. After removing all the plugs on one side, the rod was removed using the push-and-pull method. The

rod was pushed into the cephalic or caudal soft tissue out of the screw saddle of the last screw and then pulled out from the closest incision. Next, we used the blunt end of a Kirschner wire (diameter: 1.5 mm) to slide at the bottom of the polyaxial screw saddle. The aim was to blindly probe the hole at the bottom. When the Kirschner wire contacted with the edge of the hole, it would smoothly slide into the axis channel of the screw. Then, the system-specific screwdriver could easily be inserted into the screw saddle using the guide of the Kirschner wire, and both the screw and the Kirschner wire could be removed together. Afterwards, plugs, rods, and polyaxial screws on the contralateral side were removed using the same methods. Finally, the incisions were closed after removing all the screws. A typical case is illustrated in Figure 1.

Statistical Methods

Continuous variables are expressed as mean \pm standard deviation, and categorical variables are expressed as frequencies or percentages. Independent-sample *t*-tests and chi-square tests were performed to analyze differences in continuous and

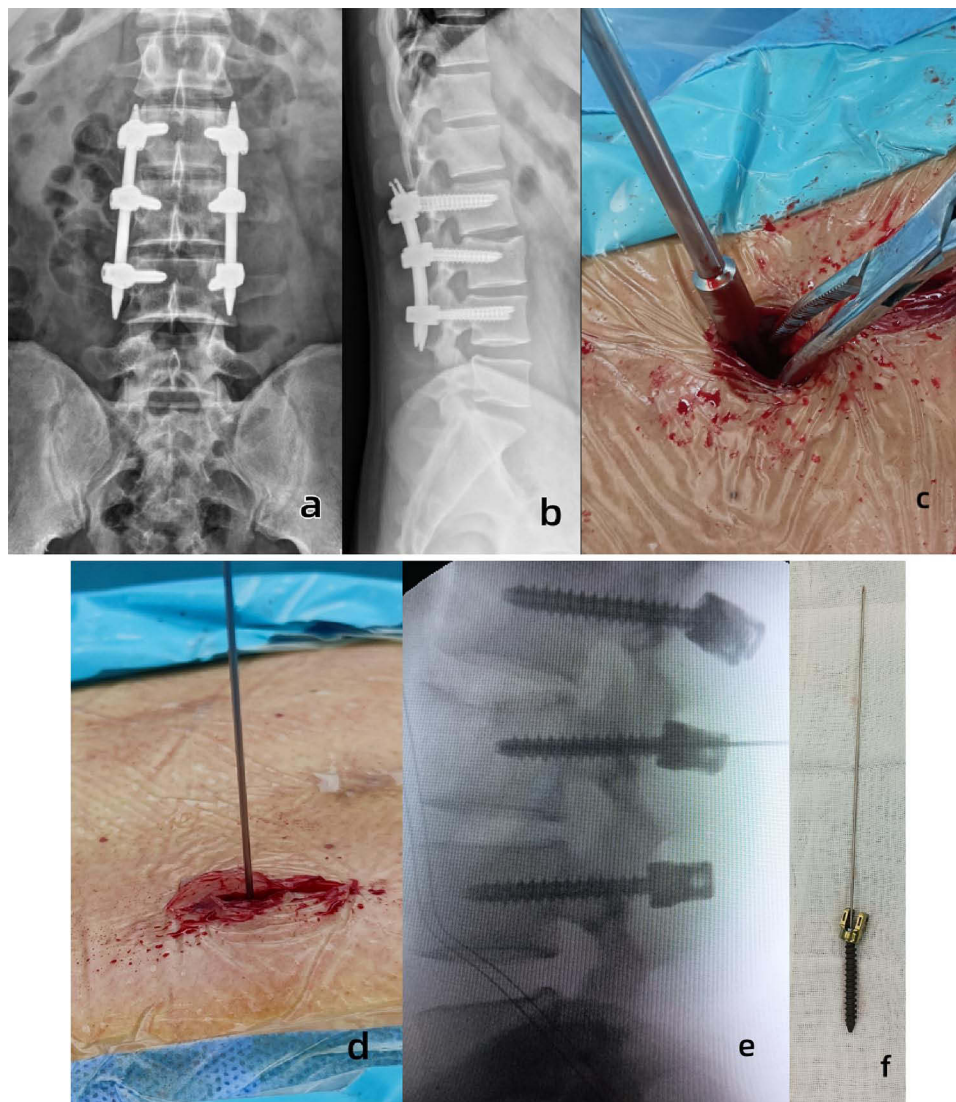


Figure 1 Typical case. Male patient aged 25 years with a history of L3 fracture caused by a car accident 1 year before. (a) Anteroposterior X-ray film before hardware removal. (b) Lateral X-ray film before hardware removal showing bone healing. (c) Incision distraction by the vessel clamp and system-specific set screw retaining compressor insertion. (d) Kirschner wire insertion in a blind manner with the blunt end ahead. (e) Lateral X-ray after Kirschner wire insertion into the axial channel of a percutaneous pedicle screw. (f) Status of the screw with Kirschner wire after removal. A sharp end can be observed on the opposite side of the screw head, indicating that the blunt end was in the screw.

Table 1 Comparison of Demographic, Clinical, and Surgical Characteristics and the Total Treatment Cost Between the Two Groups

		Conventional Group	Modified Group	P-value
Total count		57	35	
Age (mean ± standard deviation, y)		48.89±10.30	49.31±11.42	0.856
BMI (mean ± standard deviation, kg/m ²)		24.87±4.01	25.02±3.24	0.847
Sex	Male (%)	35 (61.40%)	25 (71.43%)	0.327
	Female (%)	22 (38.60%)	10 (28.57%)	
Alcohol use	Yes (%)	4 (7.02%)	3 (8.57%)	0.785
	No (%)	53 (92.98%)	32 (91.43%)	
Current smoking	Yes (%)	3 (5.26%)	6 (17.14%)	0.063
	No (%)	54 (94.74%)	29 (82.86%)	
Hypertension	Yes (%)	10 (17.54%)	3 (5.57%)	0.230
	No (%)	47 (82.46%)	32 (91.43%)	
Diabetes mellitus	Yes (%)	1 (1.75%)	0 (0%)	0.431
	No (%)	56 (98.25%)	35 (100%)	
Affected level	T11	2 (3.51%)	2 (5.71%)	0.359
	T12	12 (21.05%)	6 (17.14%)	
	L1	25 (43.86%)	11 (31.43%)	
	L2	10 (17.54%)	13 (37.14%)	
	L3	7 (12.28%)	3 (8.57%)	
	L4	1 (1.75%)	0 (0%)	
Average surgical time (mean ± standard deviation, min)		12.96±4.64	9.40±3.15	0.000 ^a
Average blood loss volume (mean ± standard deviation, mL)		14.40±15.91	7.16±3.40	0.002 ^a
Total cost (mean ± standard deviation, ¥)		19,073.42±573.35	17,472.77±274.33	0.000 ^a

Note: ^aP<0.01.

Abbreviation: BMI, body mass index.

categorical variables, respectively, between groups. SPSS (version 25.0, IBM SPSS, Armonk, NY, USA) was used for statistical analyses. A *P*-value of <0.05 was considered statistically significant.

Results

The conventional group comprised 35 men and 22 women aged 19–69 years. The modified group included 25 men and 10 women aged 25–67 years.

Table 1 presents the results of univariate analysis of demographic, clinical, surgical, and total cost characteristics. No significant differences were observed in the demographic or clinical characteristics, or affected levels. However, the average surgical time (*P*=0.000) was significantly shorter, while the average blood loss volume (*P*=0.002) and total cost (*P*=0.000) were significantly lower in the modified group.

Discussion

Our study revealed that, compared with the conventional method, our modified method can shorten surgical time, reduce blood loss volume, and reduce total treatment cost, and it is a rapid and safe minimally invasive procedure for percutaneous pedicle screw removal.

The decision to remove implants after non-fusion fixation remains controversial.¹ Considering the drawbacks of preserving implants, such as local pain, the potential risk of implant breakage, dysfunction, damage to the spine caused by the implants,^{18–20} and rare complications such as hypersensitivity reactions,²¹ most clinicians consider implant removal after non-fusion surgery beneficial.¹ Cappuccio et al² considered removal mandatory when fixation involved L2 or lower segments. Finite element analysis also recommended the removal of fixation to mitigate adjacent segment stress.²² Jeon et al²³ followed a cohort of patients over 2 years and reported that back pain and physical dysfunction were significantly lower in the implant removal group than in the control group. Only a few authors have argued against the removal of implants, even if screw breakage may occur.¹² Secondary kyphosis,^{24–27} recurrent instability,²⁸ and fixed vertebral body compression fractures^{2,29} were major concerns causing some authors to oppose implant removal. However, complications are rare. In our hospital, >50% of patients who received non-fusion percutaneous pedicle screw fixation complained of back pain after surgery, regardless of whether the pain was in the operative area or the region below. The exact mechanism of implant-related pain remains unclear but may involve local microenvironments, metallic properties, surgical site infections, or allergic reactions.^{30,31} Complete remission of back pain is infrequent;³² however, back pain caused by non-fusion fixation should be relieved after implant removal, consequently resulting in improved quality of life.¹ Thus, all patients who received non-fusion percutaneous pedicle screw fixation were recommended for hardware removal after bone healing at our hospital.

Implant removal surgery has been widely used for non-fusion in recent years; however, most studies have reported that the range of segmental motion can be regained after implant removal.^{1,6,18,23} Ko et al³³ reported that the regained range of motion was 9.12° based on a mean removal time of 12.2 months. Jeon et al²³ discovered that the mean regain in the segmental motion angle was 4.2° based on a mean removal time of 18.3 months. Wu et al¹ concluded that patients could gain a better segmental range of motion within 2 years; however, the range of motion in those who underwent hardware removal after 2 years was significantly decreased. This decrease might be caused by spontaneous stiffness of the facet joints due to long-term fixed segment immobilization. Oh et al⁸ also reported that early implant removal within 1 year after percutaneous pedicle screw fixation resulted in better range of motion than did implant removal after 1 year. Axelsson et al¹⁴ reported that segmental mobility can be restored even after a minimum of 1.5 years after hardware removal. In our practice, when patients' radiographic images reveal fractured vertebra consolidation, we recommend removing the hardware as early as possible. However, due to variations in patients' schedules and intentions, they often choose a timing that suits their convenience. In our research, we did not include the hardware removal time and fracture type at primary trauma. These variables might be more closely related to the fracture prognosis rather than our study aim, which centered on the technique.

To our knowledge, no case-control study has reported minimally invasive techniques for removing percutaneous pedicle screws. In 2004, Salerni¹⁵ reported on a cohort of 10 patients who had undergone microremoval of percutaneous pedicle screws using a tubular retractor, loupe magnification, and headlight. A case report by Grasso et al¹⁶ in 2020 detailed a method involving the use of a lumbar Caspar self-retractor and a surgical microscopic view. In contrast, our method does not require specialized instruments. To our knowledge, the Caspar retractor, tubular retractor, loupe magnification, headlight, and microscope are unavailable in most spinal departments in China and, possibly, other developing countries, limiting their use. Rather than Caspar and tubular retractors, our approach involves incision distraction using a vessel clamp, effectively creating space similar to that achieved with retractors. Even if the plug accidentally falls from the driver, it can be easily retrieved from the retracted space. However, the vessel clamp should not be loosened until the plug has been removed from the incision. To remove the polyaxial screw, Salerni¹⁵ inserted a spinal needle directly into the axis of the screw to guide the direction of the screwdriver. The author stated that because the head of the polyaxial screw was locked to the rod, it was typically inconsistent with the screw axis. Consequently, a C-arm fluoroscope might be necessary, and an additional skin incision might be chosen as the entry point for the needle between the two extended lines of the two axes. Then, the removal of the locking devices could be performed with greater precision.¹⁵ Our method involves the use of a 1.5-mm-diameter Kirschner wire instead of a spinal needle, offering certain

advantages. Firstly, it is readily available in various diameters as it is commonly used in all subspecialties of orthopedics. Secondly, the diameter of the hollow shaft of the main percutaneous pedicle screw is 1.6 mm, and the diameter of the guide pin used in the primary operation is usually 1.5 mm. Thus, the 1.5 mm diameter Kirschner wire can effectively guide the screwdriver, similar to the guide pin, at its maximum. In cases whereby inserting a 1.5 mm Kirschner wire is challenging, the operator can use one with a 1.2 mm diameter instead. Furthermore, the Kirschner wire has one sharp and another blunt end. The operator can use the blunt end to probe the hole, which is safer than using the sharp spinal needle, which might damage the soft tissue or even a large vessel,³⁴ if inserted outside the vertebrae, or if the sharp end breaches the anterior wall of the vertebrae during insertion or screw-driving. The C-arm was not needed in our practice because, regardless of the direction of the screw saddle, it could easily be inserted into the end of the screw using the Kirschner wire guide.

Our results revealed that our modified method can shorten the surgical time, reduce blood loss, and reduce the total cost compared with the conventional method. The conventional method explores the hardware extensively, which wastes time, especially in cases where the fractured vertebrae are located at L3 and below. This region is the deepest due to lumbar lordosis, or when patients have excess fat or muscular tissue. The biggest contributing factor to prolonged surgical time is the difficulty in easily placing the screwdriver at the end of the screw without guidance. This issue arises because the polyaxial screw head is locked to the rod and typically inconsistent with the screw axis; this also increases incision bleeding volume.¹⁵ However, in the modified method, all the procedures may be performed by probing and feeling. Exploring the hardware is almost unnecessary, which can save time and consequently reduce blood loss volume. One additional Kirschner wire is required to perform the modified procedure, incurring an additional cost of 20–30 Chinese Yuan in our hospital. However, this cost is easily offset by the time saved during surgery. Shorter anesthesia duration and reduced anesthesia drug usage further contribute to overall cost savings.

Our study had several limitations. Firstly, it was a retrospective case-control study based on a review of medical records. This introduces a potential risk of bias due to misinterpretation of the descriptions, and the overall evidence level was relatively low. Secondly, the study included a small number of patients and was conducted at a single spine center, which may have reduced the confidence level of the study. A large-scale multicenter study should be conducted to further verify our conclusions. In addition, the grouping of patients was based on the date of the hardware removal surgery, as we did not previously propose a modified technique. The growth and experience of the operators may have impacted the results, leading to potential bias.

Conclusion

The modified technique can shorten the surgical time and reduce blood loss volume and the total treatment cost compared to the conventional method. We developed the technique based on our clinical experience; the learning curve for this procedure appears to be relatively flat, and it does not require additional surgical instruments. This technique is suitable for utilization in primary hospitals. Further large-scale multicenter studies are needed to validate these findings.

Data Sharing Statement

The additional unpublished data from the study can be obtained from the corresponding author.

Ethics Approval and Informed Consent

This study was conducted in accordance with the principles of the Declaration of Helsinki and approved by the ethics committee of Yantaishan Hospital (approval no. 2023105). Written informed consent was obtained from each patient, or their authorized signatory, whose images or clinical data were used.

Funding

The authors declare that no funds, grants, or other support were received during the preparation of this manuscript.

Disclosure

The authors report no conflicts of interest in this work.

References

1. Wu J, Zhu J, Wang Z, et al. Outcomes in thoracolumbar and lumbar traumatic fractures: does restoration of unfused segmental mobility correlated to implant removal time. *World Neurosurg.* 2022;157:e254–e263. doi:10.1016/j.wneu.2021.09.138
2. Cappuccio M, De Lure F, Amendola L, et al. Vertebral body compression fracture after percutaneous pedicle screw removal in a young man. *J Orthop Traumatol.* 2015;16(4):343–345. doi:10.1007/s10195-014-0328-5
3. Rampersaud YR, Annand N, Dekutoski MB. Use of minimally invasive surgical techniques in the management of thoracolumbar trauma: current concepts. *Spine.* 2006;31(11):S96–S102. doi:10.1097/01.brs.0000218250.51148.5b
4. Jindal N, Sankhala SS, Bachhal V. The role of fusion in the management of burst fractures of the thoracolumbar spine treated by short segment pedicle screw fixation: a prospective randomised trial. *J Bone Joint Surg Br.* 2012;94(8):1101–1106. doi:10.1302/0301-620X.94B8.28311
5. Dai LY, Jiang LS, Jiang SD. Posterior short-segment fixation with or without fusion for thoracolumbar burst fractures. A five to seven-year prospective randomized study. *J Bone Joint Surg Am.* 2009;91(5):1033–1041. doi:10.2106/JBJS.H.00510
6. Lan T, Chen Y, Hu SY, Li AL, Yang XJ. Is fusion superior to non-fusion for the treatment of thoracolumbar burst fracture? A systematic review and meta-analysis. *J Orthop Sci.* 2017;22(5):828–833. doi:10.1016/j.jos.2017.05.014
7. Kim DY, Lee SH, Chung SK, Lee HY. Comparison of multifidus muscle atrophy and trunk extension muscle strength: percutaneous versus open pedicle screw fixation. *Spine.* 2005;30(1):123–129. doi:10.1097/01.brs.0000148999.21492.53
8. Oh HS, Seo HY. Percutaneous pedicle screw fixation in thoracolumbar fractures: comparison of results according to implant removal time. *Clin Orthop Surg.* 2019;11(3):291–296. doi:10.4055/cios.2019.11.3.291
9. Li K, Li Z, Ren X, et al. Effect of the percutaneous pedicle screw fixation at the fractured vertebra on the treatment of thoracolumbar fractures. *Int Orthop.* 2016;40(6):1103–1110. doi:10.1007/s00264-016-3156-9
10. Weber BR, Grob D, Dvorák J, Muntener M. Posterior surgical approach to the lumbar spine and its effect on the multifidus muscle. *Spine.* 1997;22(15):1765–1772. doi:10.1097/00007632-199708010-00017
11. Kramer M, Katzmaier P, Eisele R, Ebert R, Kinzl L, Hartwig E. Surface electromyography-verified muscular damage associated with the open dorsal approach to the lumbar spine. *Eur Spine J.* 2001;10(5):414–420. doi:10.1007/s005860100294
12. Chou PH, Ma HL, Liu CL, et al. Is removal of the implants needed after fixation of burst fractures of the thoracolumbar and lumbar spine without fusion? A retrospective evaluation of radiological and functional outcomes. *Bone Joint J.* 2016;98-B(1):109–116. doi:10.1302/0301-620X.98B1.35832
13. Jentzsch T, Gomes de lima V, Seifert B, Sprangel K, Werner CML. The benefits of elective spinal implant removal: a retrospective study of 137 patients. *Eur Spine J.* 2016;25(3):856–864. doi:10.1007/s00586-015-4211-8.
14. Axelsson P, Strömqvist B. Can implant removal restore mobility after fracture of the thoracolumbar segment. *Acta Orthop.* 2016;87(5):511–515. doi:10.1080/17453674.2016.1197531
15. Salerni AA. Minimally invasive removal or revision of lumbar spinal fixation. *Spine J.* 2004;4(6):701–705. doi:10.1016/j.spinee.2004.03.023
16. Grasso G, Paolini S, Salli M, Torregrossa F. Lumbar spinal fixation removal by a minimal invasive microscope-assisted technique. Case report with technical description. *Neurol India.* 2020;68(5):1211–1213. doi:10.4103/0028-3886.299148
17. Liang C, Liu G, Liang G, et al. Healing pattern classification for thoracolumbar burst fractures after posterior short-segment fixation. *BMC Musculoskelet Disord.* 2020;21(1):373. doi:10.1186/s12891-020-03386-z.
18. Kim HS, Kim SW, Ju CI, Wang HS, Lee SM, Kim DM. Implant removal after percutaneous short segment fixation for thoracolumbar burst fracture: does it preserve motion. *J Korean Neurosurg Soc.* 2014;55(2):73–77. doi:10.3340/jkns.2014.55.2.73
19. Smits AJ, den Ouden L, Jonkergouw A, Deunk J, Bloemers FW. Posterior implant removal in patients with thoracolumbar spine fractures: long-term results. *Eur Spine J.* 2017;26(5):1525–1534. doi:10.1007/s00586-016-4883-8
20. Butt MF, Farooq M, Mir B, Dhar AS, Hussain A, Mumtaz M. Management of unstable thoracolumbar spinal injuries by posterior short segment spinal fixation. *Int Orthop.* 2007;31(2):259–264. doi:10.1007/s00264-006-0161-4
21. Kim J. A rare case of delayed hypersensitivity reaction to metal ions secondary to a remnant pedicle screw fragment after spinal arthrodesis. *Acta Orthop Traumatol Turc.* 2020;54(4):461–464. doi:10.5152/j.aott.2020.20148.
22. Hsieh YY, Chen CH, Tsuang FY, Wu LC, Lin SC, Chiang CJ. Removal of fixation construct could mitigate adjacent segment stress after lumbosacral fusion: a finite element analysis. *Clin Biomech.* 2017;43:115–120. doi:10.1016/j.clinbiomech.2017.02.011
23. Jeon CH, Lee HD, Lee YS, Seo JH, Chung NS. Is it beneficial to remove the pedicle screw instrument after successful posterior fusion of thoracolumbar burst fractures. *Spine.* 2015;40(11):E627–E633. doi:10.1097/BRS.0000000000000870
24. Lindsey RW, Dick W, Nunchuck S, Zach G. Residual intersegmental spinal mobility following limited pedicle fixation of thoracolumbar spine fractures with the fixateur interne. *Spine.* 1993;18(4):474–478. doi:10.1097/00007632-199303010-00011
25. Kanezaki S, Miyazaki M, Ishihara T, Notani N, Tsumura H. Magnetic resonance imaging evaluation of intervertebral disc injuries can predict kyphotic deformity after posterior fixation of unstable thoracolumbar spine injuries. *Medicine.* 2018;97(28):e11442. doi:10.1097/MD.00000000000011442
26. Chen JX, Xu DL, Sheng SR, et al. Risk factors of kyphosis recurrence after implant removal in thoracolumbar burst fractures following posterior short-segment fixation. *Int Orthop.* 2016;40(6):1253–1260. doi:10.1007/s00264-016-3180-9
27. Wang XY, Dai LY, Xu HZ, Chi YL. Kyphosis recurrence after posterior short-segment fixation in thoracolumbar burst fractures. *J Neurosurg Spine.* 2008;8(3):246–254. doi:10.3171/SPI/2008/8/3/246
28. Seitz H, Schwarz FS, Karner M, Nau T. Adolescent lumbar chance lesion: recurrent instability after hardware removal. *J Trauma.* 2010;68(1):E16–E19. doi:10.1097/TA.0b013e31806215a2
29. Waelchli B, Min K, Cathrein P, Boos N. Vertebral body compression fracture after removal of pedicle screws: a report of two cases. *Eur Spine J.* 2002;11(5):504–506. doi:10.1007/s00586-002-0417-7
30. Jamil W, Allami M, Choudhury MZ, Mann C, Bagga T, Roberts A. Do orthopaedic surgeons need a policy on the removal of metalwork? A descriptive national survey of practicing surgeons in the United Kingdom. *Injury.* 2008;39(3):362–367. doi:10.1016/j.injury.2007.10.028
31. Kim HJ, Kang KT, Moon SH, et al. The quantitative assessment of risk factors to overstress at adjacent segments after lumbar fusion: removal of posterior ligaments and pedicle screws. *Spine.* 2011;36(17):1367–1373. doi:10.1097/BRS.0b013e318221a595
32. Stavridis SI, Bücking P, Schaeren S, Jeanneret B, Schnake KJ. Implant removal after posterior stabilization of the thoraco-lumbar spine. *Arch Orthop Trauma Surg.* 2010;130(1):119–123. doi:10.1007/s00402-009-0962-1

33. Ko SB, Lee SW. Result of posterior instrumentation without fusion in the management of thoracolumbar and lumbar unstable burst fracture. *J Spinal Disord Tech.* 2014;27(4):189–195. doi:10.1097/BSD.0b013e31825bfc8e
34. Vanichkachorn JS, Vaccaro AR, Cohen MJ, Cotler JM. Potential large vessel injury during thoracolumbar pedicle screw removal. A case report. *Spine.* 1997;22(1):110–113. doi:10.1097/00007632-199701010-00018

Journal of Pain Research

Dovepress

Publish your work in this journal

The Journal of Pain Research is an international, peer reviewed, open access, online journal that welcomes laboratory and clinical findings in the fields of pain research and the prevention and management of pain. Original research, reviews, symposium reports, hypothesis formation and commentaries are all considered for publication. The manuscript management system is completely online and includes a very quick and fair peer-review system, which is all easy to use. Visit <http://www.dovepress.com/testimonials.php> to read real quotes from published authors.

Submit your manuscript here: <https://www.dovepress.com/journal-of-pain-research-journal>