


# An Infant with Measles Developed Ecthyma Gangrenosum Caused by Coagulase-Negative *Staphylococcus*: A Rare Case Report from Somalia

Ahmed Isse Ali<sup>1</sup> , Abdullahi Ali Mohamed<sup>2</sup>, Ibrahim Mohamed Hirsi<sup>2</sup>, Mohamed Nur Ali<sup>2</sup>

<sup>1</sup>Department of Dermatology, Mogadishu-Somali Turkey Training and Research Hospital, Mogadishu, Somalia; <sup>2</sup>Department of Pediatric, Mogadishu-Somali Turkey Training and Research Hospital, Mogadishu, Somalia

Correspondence: Ahmed Isse Ali, Email daade100@gmail.com

**Introduction and Importance:** Ecthyma gangrenosum is a skin lesion that can be caused by either bacterial hematogenous seeding or a primary skin infection. Despite being the most frequent causal agent, *Pseudomonas aeruginosa* is not the only bacteria that has been involved. Other types of bacteria may also be implicated in the etiology of EG: cocci bacteria, both gram-positive and gram-negative.

**Case Presentation:** Here, we report the case of a 10-month-old male infant who developed ecthyma gangrenosum after a measles infection. At the time of admission, the patient had a high fever of about 40.3°C and appeared conscious. Physical examination revealed several skin lesions that were in various stages of development and appeared as nodules with a central crust and round, ulcerated, necrotic papules in the face, chest, and upper extremities. Laboratory tests showed CRP of 25 mg/l, LDH of 579 U/L, WBC of  $15.06 \times 1000/\text{mm}^3$ , and absolute neutrophils of 1930/mm<sup>3</sup> (12.8%). The result of the culture showed coagulase-negative *Staphylococcus*. According to the drug susceptibility test results, intravenous Vancomycin (20 mg/kg per dose, 3 times daily) should be started. A coagulase-negative *Staphylococcus* was eliminated as a result of this defervescence. The necrotic lesion was surgically removed from the patient.

**Clinical Discussion:** Ecthyma gangrenosum is the all-over-the-body cutaneous manifestation of pseudomonas infection in sepsis patients. Patients who suffer from severe illnesses. Immune deficiencies commonly increase the chance of acquiring EG. Our patient had a history of measles, which led to neutropenia before developing EG. The management of ecthyma gangrenosum requires early identification and antimicrobial treatment.

**Conclusion:** We describe a measles patient who developed coagulase-negative *Staphylococcus* ecthyma gangrenosum and had good results from both surgical debridement and systemic antibiotics. Our case serves as an example of the uncommon presentation of ecthyma gangrenosum. This example emphasizes the value of an early diagnosis and vigorous antimicrobial therapy in cases where ecthyma gangrenosum is clinically suspected.

**Keywords:** ecthyma gangrenosum, coagulase-negative *Staphylococcus*, measles

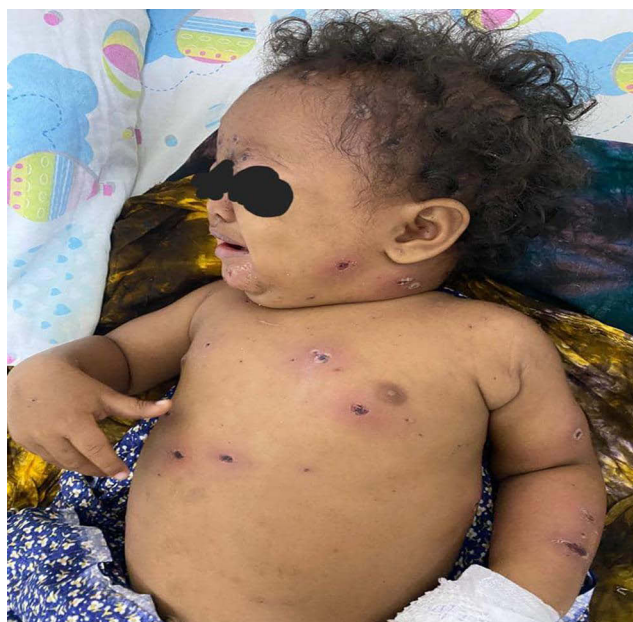## Introduction

Ecthyma gangrenosum is an uncommon cutaneous lesion caused by the aerobic gram-negative opportunistic bacterial pathogen *Pseudomonas aeruginosa*. Sepsis is not a frequent consequence in patients without bacteremia. Patients with impaired immune systems are more frequently impacted.<sup>1</sup> Despite being the most frequent causal agent, *Pseudomonas aeruginosa* is not the only bacteria that has been involved.<sup>2</sup> Other types of bacteria may also be implicated in the etiology of EG: cocci bacteria, both gram-positive and gram-negative.<sup>3</sup>

This illness often affects the extremities, gluteal, and perineal areas, and it has been linked to fatal septicaemic infections and high mortality.<sup>4</sup> We report a case of ecthyma gangrenosum in an infant after a measles infection.

## Case Presentation

A 10-month-old male infant was brought into the pediatrics unit with a 10-day history of high-grade fever and generalized body rashes without any prior vaccination history.



**Figure 1** Ecthyma gangrenosum ulcers in the face, chest, and upper extremities.

At the time of admission, the patient had a high fever of about 40.3°C and appeared conscious. Physical examination revealed several skin lesions that were in various stages of development and appeared as nodules with a central crust and round, ulcerated, necrotic papules.

The face, chest, and upper extremities were all affected by the lesions (Figure 1). After obtaining samples of the patient’s blood, cerebrospinal fluid, and skin lesion (pustule), an empiric course of intravenous Clindamycin (10 mg/kg per day) and Ceftriaxone (50 mg/kg per day) was started.

Laboratory tests showed CRP 25 mg/l, LDH 579 U/L, WBC 15.06 × 1000/mm<sup>3</sup>, HGB 8.4 g/dl, and absolute neutrophils 1930/mm<sup>3</sup> (12.8%), PLT 323 × 1000/mm<sup>3</sup>.

Coagulase-negative *Staphylococcus* was found in the tissues that were taken from the lesion, supporting the diagnosis of ecthyma gangrenosum.

Coagulase-negative *Staphylococcus aureus*, an isolated strain, was susceptible to vancomycin, quinupristin, daptomycin, and vancomycin (Table 1). According to the drug susceptibility test results, intravenous Vancomycin (20 mg/kg per dose, 3

**Table 1** The Cultured Organism’s Antibiotic Sensitivity

Study Name	The Result
Wound culture	Growth was seen
<b>Organism: Coagulase-Negative Staphylococcus</b>	
Antibiotic	Conclusion
Trimethoprim-Sulfamethoxazole	Resistant
Fusidic acid	Resistant
Cefoxitin	Resistant
Penicillin G	Resistant
Daptomycin	Sensitive
Quinupristin/Dalfopristin	Sensitive
Ciprofloxacin	Resistant
Vancomycin	Sensitive

times daily) should be started. Coagulase-negative *Staphylococcus aureus* was eliminated as a result of this defervescence. The necrotic lesion was surgically removed from the patient. Twenty days after the treatment, the patient made a complete recovery. The lesions significantly improved. The necrotic lesion was surgically removed from the patient, and there was no sign of recurrence or new lesions. Lesions were seen on subsequent visits.

## Discussion

Ecthyma gangrenosum (EG) is a well-known cutaneous infection that is mostly linked to bacteremia caused by *Pseudomonas aeruginosa*. The etiopathogenesis of EG has also been linked to various pathogens, including *Candida* sp., *Escherichia coli*, *Citrobacter* sp., *Klebsiella* sp., *Staphylococcus aureus*, and *Streptococcus pyogenes*.<sup>5</sup>

Although the gluteal or perineal region is the most typical location for EG lesions (57%), other unusual locations can also be affected, including the extremities, trunk, face, and very infrequently the periorbital region.<sup>4</sup>

Our patient had lesions that appeared as nodules with a central crust and round, ulcerated, necrotic papules. The left forehead, left side of the chest, and area next to the breasts were all affected by the lesions.

*Pseudomonas aeruginosa* is the most frequently linked bacterium in the pathogenesis of EG. *Staphylococcus aureus*,<sup>6,7</sup> and gram-negative cocci such as *Neisseria gonorrhoea*<sup>8</sup> or gram-negative bacteria such as *E. coli* may also be involved.<sup>9</sup> In our patient, the causative organism is coagulase-negative *Staphylococcus*, which is a gram-positive bacteria. In 2023, according to our knowledge, there is one case report of EG caused by coagulase-negative *Staphylococcus*, especially *Staphylococcus lentus*.<sup>5</sup>

Patients with cancer, hypogammaglobulinemia, steroid therapy, immunodeficiency, particularly neutropenia, and malignancies are at a higher risk of contracting this infection.<sup>10</sup> In immunocompromised patients, the death rate from EG varies from 38% to 96%, while in nonbacteremic patients, it is 16%. Although neutropenia is the most common risk factor for EG.<sup>11</sup>

Viral diseases like measles have the ability to directly or indirectly inhibit bone marrow granulocytosis. Neutropenia can range greatly in severity, from moderate to severe.<sup>12</sup> Our patient had a history of measles, which led to neutropenia before developing EG

The management of ecthyma gangrenosum requires early identification and antimicrobial treatment. A better prognosis is linked to a lack of bacteremia.

To stop the spread of infection and septicemia, surgical drainage of small abscesses and debridement of all necrotizing tissues may be required.<sup>13</sup> In nonsepticemic cases, the death rate is typically around 15%. However, in septicemic patients, the rate is incredibly varied and can reach up to 96%.<sup>14</sup> Thus, the potential application of the right treatment and identification of the lesions can be essential to their survival. The lesions significantly improved. The necrotic lesion was surgically removed from the patient, and there was no sign of recurrence or new lesions. Lesions were seen on subsequent visits.

## Provenance and Peer Review

Not commissioned, externally peer-reviewed.

## Ethical Approval

Case reports are not subject to ethical review at our institution. However, the parent of the child provided us with written authorization before publishing this case report and the associated pictures.

## Consent for Publication

Written informed consent was obtained from the parent of the child for publication of this case report and accompanying images. A copy of the written consent is available for review by the Editor-in-Chief of this journal on request.

## Author Contributions

Every author contributed significantly to the work reported, whether it was in the design, execution, acquisition of data, analysis, and interpretation, or in all of these areas; they also participated in the article's drafting, revision, or critical

review; they approved the final version that was published; they agreed on the journal to which the article was submitted; and they agreed to take responsibility for every aspect of the work. Guarantor: Ahmed Isse Ali, the corresponding author.

## Funding

There is no funding to report.

## Disclosure

The authors report no conflicts of interest in this work.

## References

1. Al Muqarrab FJ, Al Mosbeh MJ, Al Haddad TA, Al Muhainy NA. Hemorrhagic vesiculobullous lesions of Ecthyma gangrenosum in a diabetic patient with myelofibrosis: a rare presentation of septic shock without Pseudomonas aeruginosa Bacteremia. *Am J Case Rep.* 2023;24:e939905–1. doi:10.12659/AJCR.939905
2. Nagata YK, Sekiya N, Fukushima K, Horiuchi M, Doki N. Ecthyma gangrenosum caused by Staphylococcus aureus in hematological malignancies: case reports and literature review. *Medicine.* 2022;101(33):e30070. doi:10.1097/MD.00000000000030070
3. Birlutiu V, Birlutiu RM, Baicu M, Iancu GM. A case report of double etiology of ecthyma gangrenosum: pseudomonas aeruginosa and Enterococcus faecalis in an immunocompromised child occurred during influenza evolution. *Medicine.* 2019;98(20):e15651. doi:10.1097/MD.00000000000015651
4. Singh TN, Devi KM, Devi KS. Ecthyma gangrenosum: a rare cutaneous manifestation caused by pseudomonas aeruginosa without bacteraemia in a leukaemic patient—a case report. *Indian J Med Microbiol.* 2005;23(4):262. doi:10.1016/S0255-0857(21)02534-2
5. Bairwa M, Choudhury A, Vamadevan S, Parchani A, Kumar S, Gangadharan J. A rare presentation of Ecthyma gangrenosum-like LESIONS due to Staphylococcus lentus in an immunocompetent adult: a case report. *Indian J Crit Care Case Rep.* 2023;2(4):85–87. doi:10.5005/jp-journals-11006-0060
6. Reich HL, Fadeyi DW, Naik NS, Honig PJ, Yan AC. Nonpseudomonal ecthyma gangrenosum. *J Am Acad Dermatol.* 2004;50(5):114–117. doi:10.1016/j.jaad.2003.09.019
7. Chang AY, Carlos CA, Schuster M, Xu X, Rosenbach M. Nonpseudomonal ecthyma gangrenosum associated with methicillin-resistant staphylococcus aureus infection: a case report and review of the literature. *Cutis.* 2012;90(2):67–69.
8. Glicksman JM, Short DH, Knox JM, Freeman RG. Gonococcal skin lesions: report of a case of gonococcal ecthyma. *Arch Dermatol.* 1967;96(1):74–76. doi:10.1001/archderm.1967.01610010080015
9. Patel JK, Perez OA, Viera MH, Halem M, Berman B. Ecthyma gangrenosum caused by Escherichia coli bacteremia: a case report and review of the literature. *Cutis.* 2009;84(5):261–267.
10. Chan YH, Chong CY, Puthuchery J, Loh TF. Ecthyma gangrenosum: a manifestation of Pseudomonas sepsis in three paediatric patients. *Singapore Med J.* 2006;47(12):1080–1083.
11. Ulpiano Trillig A, Miendje Deyi VY, Youatou P, Konopnicki D. Ecthyma gangrenosum caused by coinfection with group A Streptococcus and Staphylococcus aureus: an emerging etiology? Case reports and literature review. *Acta Clin Belg.* 2021;76(1):53–57. doi:10.1080/17843286.2019.1630570
12. Frater JL. How I investigate neutropenia. *Int J Lab Hematol.* 2020;42(S1):121–132. doi:10.1111/ijlh.13210
13. Mouna K, Akkari H, Faten H, et al. Ecthyma gangrenosum caused by Escherichia coli in a previously healthy girl. *Pediatr Dermatol.* 2015;32(4):e179–e180. doi:10.1111/pde.12595
14. Kim HJ, Grossniklaus HE, Wojno TH. Periorbital ecthyma gangrenosum: a case report and review of the literature. *Ophthal Plast Reconstr Surg.* 2014;30(5):e125–e129. doi:10.1097/IOP.0b013e3182a6504a

International Medical Case Reports Journal

Dovepress

Publish your work in this journal

The International Medical Case Reports Journal is an international, peer-reviewed open-access journal publishing original case reports from all medical specialties. Previously unpublished medical posters are also accepted relating to any area of clinical or preclinical science. Submissions should not normally exceed 2,000 words or 4 published pages including figures, diagrams and references. The manuscript management system is completely online and includes a very quick and fair peer-review system, which is all easy to use. Visit <http://www.dovepress.com/testimonials.php> to read real quotes from published authors.

Submit your manuscript here: <https://www.dovepress.com/international-medical-case-reports-journal-journal>