

# Antifungal Susceptibility and Biological Characteristics of *Fonsecaea monophora* Causing Cerebral Phaeohyphomycosis in Jinhua, China

Wenzi Bi, Licheng Xu, Laibin Zong, Zhiqiang Zhu , Xiaoping Xia

The Fourth Affiliated Hospital, Zhejiang University School of Medicine, Yiwu, Zhejiang, People's Republic of China

Correspondence: Xiaoping Xia, Tel +86579-89979999, Email xiaopingxia@zju.edu.cn

**Background:** The management of cerebral abscesses caused by dark-pigmented *Fonsecaea monophora* in healthy individuals continues to be challenging due to no consensus on the therapeutic regimen. Due to the absence of an accurate identification method, *Fonsecaea* species are often misidentified due to indistinct morphology features.

**Materials and Methods:** An *F. monophora* strain from an immunocompetent host with cerebral abscess was collected and identified by ITS rDNA molecular sequencing. The ITS sequences of the isolate were compared with that of the other ten Chinese *F. monophora* isolates obtained from GenBank for difference comparison and phylogenetic analysis. Fluorescence, Gram stains, and median lactate were used to observe the colonial morphology. Antifungal susceptibility testing was implemented to demonstrate the antibiotic susceptibility profile. *Galleria mellonella* larvae were used as a model to study virulence of *F. monophora*. Medical records and clinical data of the patient were collected and analyzed.

**Results:** Antifungal susceptibility testing indicated that triazole antifungal drugs possess remarkable antifungal effect against *F. monophora*, and satisfactory antifungal effect of itraconazole was corresponding to the drug susceptibility results. Compared with the GM test, the serum G test was found to be more sensitive. The virulence and melanization in *G. mellonella* models for *F. monophora* were observed, and the death rates of infected larvae were positively related to injected concentrations of fungus. The phylogenetic tree was constructed from the ITS sequences of the clinical isolate along with ten Chinese *F. monophora* isolates, revealing that there is high relatedness in *F. monophora* strains collected from China.

**Conclusion:** *F. monophora* is an important neurotropic dematiaceous fungus and increasingly causing disease in immunocompetent individuals by means of noninvasive ways. Fungal culture, stainings, and molecular methods could be utilized to identify the etiologic agent. Triazole antifungal drugs can be applied as empiric therapeutic agents for phaeohyphomycosis.

**Keywords:** phaeohyphomycosis, *Fonsecaea monophora*, DNA sequence analysis, antifungal susceptibility testing

## Introduction

Phaeohyphomycosis (PHM) is a group of superficial and deep mycoses, including central nervous system (CNS) infections, pulmonary infections, cutaneous and subcutaneous infections, associated with high mortality and caused by dematiaceous fungi that have brown-pigmented cell walls due to the formation of melanin.<sup>1,2</sup> Previously, fungal brain infections generally occurred in immunocompromised patients and the pathogenic fungi were various. However, over half of the cerebral phaeohyphomycosis cases were reported in immunocompetent patients in a comprehensive review.<sup>3</sup> Considering that dematiaceous fungi are ubiquitous in the environment and their ability to cause invasive infections in immunocompetent and immunocompromised hosts, the propensity of this condition needs emphasis and cannot be ignored.<sup>4</sup>

The discovered etiological agents of PHM are mainly the genera *Fonsecaea*, *Phialophora*, and *Cladophialophora*.<sup>5</sup> The genus *Fonsecaea* comprises several related species, and new species of the genus *Fonsecaea* have been gradually described recently based on the internal transcribed spacer (ITS) region sequence analysis. Among them, *Fonsecaea monophora* was recently segregated from *Fonsecaea pedrosoi*, one of the major etiologic agents of chromoblastomycosis. *F. monophora*

was found to cause infections in many organ systems, including the brain, gallbladder, and lymph node in the human host, and its predominantly neurotropic character has aroused wide public concern in recent years.<sup>6</sup> Cerebral phaeohyphomycosis was documented mostly in tropical regions,<sup>7</sup> but it has not been reported in otherwise healthy patients, in Zhejiang province, China.

Here, an *F. monophora* clinical isolate was collected from an immunocompetent host with cerebral abscess diagnosed by computerized tomography, and it was investigated by ITS rDNA molecular sequencing, antifungal susceptibility testing, morphologic observation, and virulence study. The corresponding antifungal treatment regimen was also analyzed. This study is aimed at providing a better understanding of the pathogen characteristics and practical experience related to this sophisticated mycosis in China to achieve early diagnosis and efficacious treatment.

## Materials and Methods

### Strains and Morphology

A 61-year-old retiree patient presented to our outpatient department in April 2022 due to an intermittent headache of unknown cause. The stereotactic puncture drainage of the brain abscess was performed on April 28, 2022, and the pus was drained during surgery and sent for etiological examination. In the microbiology laboratory, the cerebral abscess specimen taken during surgery was stained by Gram and fungal fluorescence, in addition, it was inoculated on potato dextrose agar (PDA) and candida color culture medium at different temperatures (28°C and 35°C) for 2 weeks. The fungal culture were stained with fluorescence, Gram, and median lactate to observe the colonial morphology.

### Molecular Identification and Phylogenetic Analysis

DNA was extracted from one-week-old colonies scraped from the growth on PDA media using the protocol DNA Purification from Yeast Using the Gentra Puregene Yeast/Bact. Kit (QIAGEN, Germany). The ITS 1–5.8S rDNA-ITS 2 region of rDNA was amplified by polymerase chain reaction (PCR) using primers ITS-1 (5'-TCCGTAGGTGAACCTGCGG-3') and ITS-4 (5'-TCCTCCGCTTATTGATATGC-3') which were specific for internal transcribed spacer element, corresponding to related studies.<sup>8</sup> PCR assays were performed using a C1000 Touch Thermal Cycler (Bio-Rad, USA) and conducted with the following conditions: 95°C for 3 min, followed by 25 cycles of 95°C for 30s, 50°C for 30s, and 72°C for 30s and a final extension of 72°C for 5 min. Amplicons were sent to Beijing Ruiboxingke Biotechnology Co., Ltd. (Beijing, China) for direct sequencing. Nucleotide sequences were compared on the GenBank database using BLAST (<http://blast.ncbi.nlm.nih.gov/Blast.cgi>).

The ITS sequences of the isolate were determined and compared with those of other ten Chinese *F. monophora* isolates (*F. monophora* strain CGMHD 0311, *F. monophora* strain CGMHD 0145, *F. monophora* strain BMU07666, *F. monophora* strain CMCCf D6h, *F. monophora* strain SUMS0012, *F. monophora* isolate IS00391, *F. monophora* isolate BMU07699, *F. monophora* isolate HZ0221, *F. monophora* strain 1750 and a *F. monophora* without definition) using Blast Program.

### In vitro Antimicrobial Susceptibility Testing

Minimum inhibitory concentrations (MICs) were determined by broth microdilution method, according to the recommendations of the Clinical and Laboratory Standards Institute (CLSI) M38-A2 protocol with modifications.<sup>9</sup> Amphotericin B (AMB), 5-flucytosine (5FC), fluconazole (FLC), itraconazole (ITC), posaconazole (POS), voriconazole (VRC), caspofungin (CAS), and micafungin (MFG) were tested. *Candida parapsilosis* ATCC22019 was used as a quality control.

### *Galleria mellonella* Larvae as a Model to Study Virulence of *F. monophora*

Larvae weighing 250–300 mg were selected (20 per strain) and maintained at 16°C before use. Larvae infections were implemented referred to the previous study with modulations.<sup>10</sup> Larvae were grouped and infected with 20 µL saline solution or conidia inoculum with concentrations of  $1 \times 10^8$ ,  $1 \times 10^6$ ,  $1 \times 10^5$ ,  $1 \times 10^4$  per mL via the last left proleg, respectively. After injection, larvae were incubated at 37°C and observed daily. Larvae were considered dead and removed away when they failed to respond to touch. Graphs of the survival rate of larvae were generated using

GraphPad Prism 5 software. Survival data were analyzed by log-rank comparisons of Kaplan–Meier survival curves. Statistical significance ( $P$  value) was calculated by SPSS 17.0, and a  $P$  value is less than 0.05 was considered statistically significant.

## Clinical Data Analysis

Medical records and clinical data (patient age, gender, comorbidities, occupation, immunologic status, underlying medical conditions, clinical features, physical examination, laboratory results, antifungal administration, outcome, and prognosis) of the patient were collected and analyzed.

## Result

### Laboratory Examination results and Clinical Data

The patient was a 61-year-old retiree weighing 63kg and presented to our outpatient department in April 2022 due to an intermittent headache of unknown origin. He was otherwise healthy and without any other clinical signs of infection. Physical examinations were normal, in addition, meningeal irritation signs, neck stiffness, Kernig signs, and Brudzinski signs were all not detected.

The results of blood routine examination were as follows: haemoglobin 16.3 g/dl, leucocyte count  $4.8 \times 10^9/l$  (neutrophils  $3.2 \times 10^9/l$ , lymphocytes  $1.3 \times 10^9/l$ , monocyte  $0.3 \times 10^9/l$ , eosinophils  $0.01 \times 10^9/l$ , basophilic granulocyte,  $0.01 \times 10^9/l$ ), C-reactive protein 1.7 mg/l. Biochemical parameters and troponin I (0.001ng/mL) are normal. The patient was tested negative for human immunodeficiency virus (HIV). Routine examination and biochemical test of cerebrospinal fluid were also normal, except for the increased cerebrospinal fluid protein (1060.79mg/l). The serum G test result was 117  $\mu\text{g/L}$  which indicated the presence of fungal infection. The serum GM test result was normal (0.09 pg/mL).

Magnetic resonance imaging (MRI) revealed a space-occupying lesion which was highly suspected of a brain abscess in the right temporal lobe. In the stereotactic puncture drainage of the brain abscess, the pus was drained and sent for bacteriological examination.

The patient was commenced on intravenous liposomal amphotericin B 50mg/kg/day qd and oral itraconazole 200 mg/kg/day qd. Liver functions and renal functions were deviant after the five-day antifungal treatment. Considering the possibility of side effects of amphotericin B, itraconazole was selected for subsequent single-drug treatment.

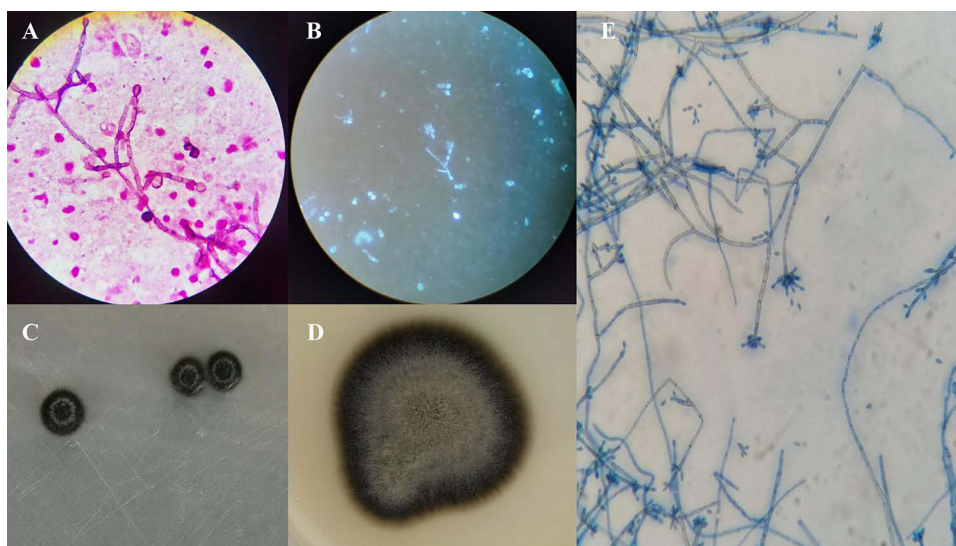
### Strain Identification Results

Attempts to identify the fungus were failed by the MALDI-TOF-MS system. Strain identity was verified by sequencing the ribosomal internal transcribed spacer (ITS), and the PCR product was found to be similar to the sequences of many *F. monophora* strains in the GenBank database (<https://www.ncbi.nlm.nih.gov/>). The sequence showed 99% homology with *F. monophora* strain 35,641 in GenBank (Sequence ID: MH382070.1) and was confirmed as *F. monophora*.

### Morphology

The cerebral abscess specimen was stained by Gram and fungal Fluorescence separately. Hypha and thick-walled spores could be found by microscopic observation (Figure 1A and B).

After culturing the cerebral abscess specimen for 7 days at 35°C, the evident colonies grew at a slow speed on the PDA media (Figure 1C). The colonies grew at a slow speed and grew better at 35°C than at 28°C. Velvety fungal spores, black hypha, typical morphology with conidiogenesis process, and dry colonies with friable texture were noted after 14 days (Figure 1D). Hyphae were dense at the dark-brown periphery of the colony, and convex central protrusions were grayish-white. The fungus had an olive colored septate hyphae with branches and multiple elliptic conidia were arranged at the apex of the conidiophores by microscopic observation after lactophenol cotton blue staining of culture (Figure 1E).



**Figure 1** (A) Microscopic observation of the cerebral abscess specimen by Gram staining (Original magnification  $\times 1000$ ). (B) Microscopic observation of the cerebral abscess specimen by Fluorescent staining (Original magnification  $\times 400$ ). (C) The Macroscopic appearance of colonies on solid PDA media for 7 days at 35 °C. (D) The Macroscopic appearance of colonies on solid PDA media for 14 days at 35 °C. (E) Fungal morphology stained with median lactate (Original magnification  $\times 400$ ).

## Antifungal Susceptibility Testing

Table 1 demonstrates the antibiotic susceptibility profile of the clinical strain. This strain had high MIC values in response to many antifungal drugs. The results indicated that VRC, POS, and ITC had the strongest anti-*F. monophora* effect. MFG and FLC had poor antifungal effects, and fungal growth was still observed at high concentrations.

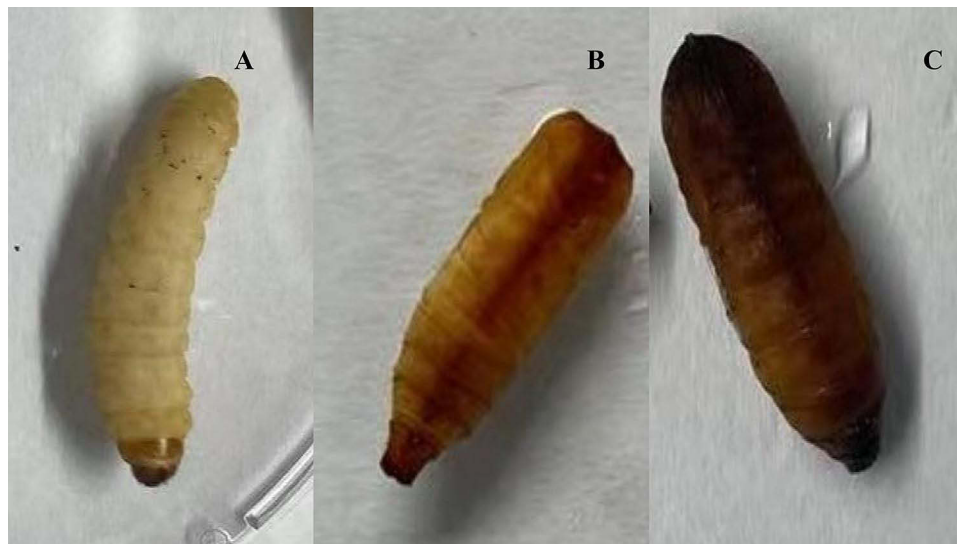
## Pathogenicity and Virulence of *F. monophora* in *G. mellonella* Larvae

Before injecting, healthy *G. mellonella* larvae were typically creamy (Figure 2A). Four groups of larva were injected with  $1 \times 10^4$ ,  $1 \times 10^5$ ,  $1 \times 10^6$ , and  $1 \times 10^8$  per mL melanized strain conidia separately, and were incubated at 37°C. The survival condition of the infected larvae was monitored daily.

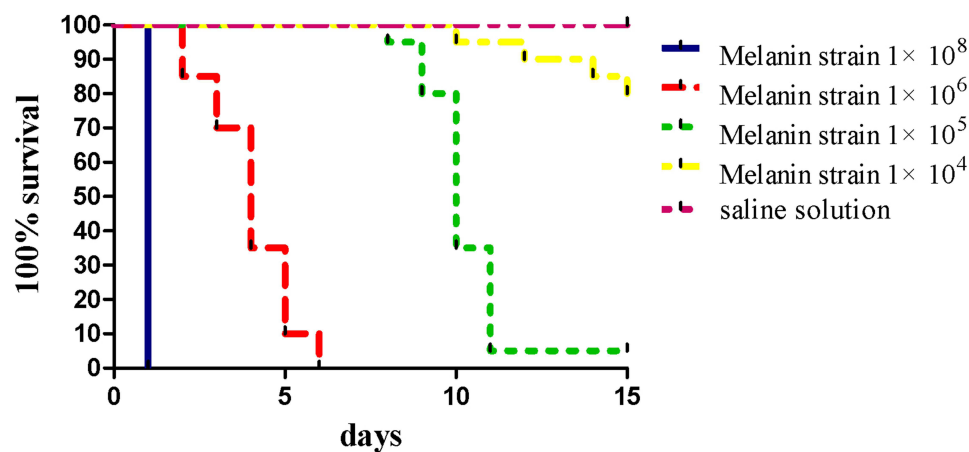
Melanization, comprising the synthesis and deposition of melanin at the infection position, showed up as black change on the cream-colored larvae (Figure 2B). Black larvae were completely melanized and died soon (Figure 2C). All larvae which were injected with  $1 \times 10^8$  per mL melanized strain conidia, were all killed within 24 hours. The melanized strain showed lower virulence to *G. mellonella* at the inoculation of  $1 \times 10^4$  conidia per insect. The death rates of infected larvae were positively related to injected concentrations of *F. monophora* (Figure 3). Distinct death rates of infected

**Table 1** Fungal Susceptibility

Antifungal Agents	MICs ( $\mu\text{g/mL}$ )
Amphotericin B	2
5'flucytosine	2
Fluconazole	16
Itraconazole	0.12
Posaconazole	0.06
Voriconazole	0.06
Caspofungin	2
Micafungin	>8



**Figure 2** (A) Image of a healthy *G. mellonella* larvae with a typical creamy color. (B) Image of infected larvae which produce distinctive black changes on the cream-colored larvae on account of melanization. (C) Image of infected larvae which was black because of complete melanization and died soon.



**Figure 3** Survival curves of *G. mellonella* infected with 20  $\mu$ L saline solution or conidia inoculum with different concentrations of  $1 \times 10^8$ ,  $1 \times 10^6$ ,  $1 \times 10^5$ ,  $1 \times 10^4$  per mL.

larvae were observed between groups with different injected concentrations of fungus ( $P < 0.001$ ), and the death rates of infected larvae were positively correlated with injected concentrations of fungus. However, no significant difference was found between the infection with  $1 \times 10^4$  conidia per insect and saline solution ( $P > 0.05$ ).

## Sequence Analysis and Phylogenetic Analysis

The ITS regions of the *F. monophora* clinical isolate were amplified to produce approximately 600 bp fragments, and sequenced. The ITS sequences were compared with those of other ten Chinese *F. monophora* isolates obtained from GenBank for difference comparison and phylogenetic analysis (Figure 4). ITS tree revealed the phylogenetic relationship among the genus *Fonsecaea*, obtained by neighbor-joining analysis using Mega 7.0.<sup>8</sup> The numbers given on the branches are the frequencies with which a given branch appeared in 1000 bootstrap replications. *F. monophora* strain 1750 and *F. monophora* isolate BMU07699 were used as outgroups (Figure 5).


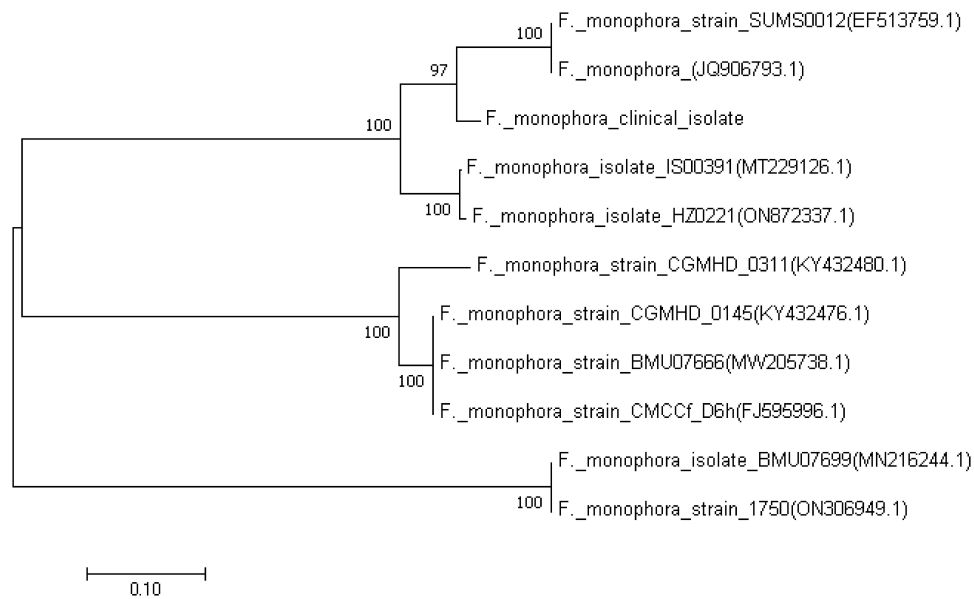


Figure 4 Comparison of the internal transcribed spacer (ITS) sequence of the *F. monophora* clinical isolate with those of the other ten Chinese *F. monophora* isolates.



**Figure 5** Neighbor-joining tree was constructed based on the internal transcribed spacer (ITS) sequences of the genus *Fonsecaea* isolated from China.

## Discussion

Since 2004, *F. monophora* was segregated from *F. monophora* by De Hoog et al, more *F. monophora* were isolated and identified by rDNA ITS sequencing. There is a significant difference in the pathogenicity of the two, with *F. monophora* being predominantly neurotropic in the human host. Cindy Fransisca et al re-evaluated twenty isolates recovered from chromoblastomycosis patients which were originally identified as *F. pedrosoi*, and 17 strains were verified to be *F. monophora* by rDNA ITS sequence.<sup>11</sup> Finally, they found twenty strains were *F. monophora*, only four strains corresponded to *F. pedrosoi*.

The most frequent manifestation of cerebral phaeohyphomycosis is solitary brain abscess which could cause severe headache.<sup>12</sup> Such serious fungal infections are generally associated with severe immunocompromised status. Otitis media and trauma resulting in the implantation of pathogenic fungus into the skin may be the cause of the disease.<sup>13</sup> Considering that dematiaceous fungi which are the main pathogens for phaeohyphomycosis distribute in the environment, especially in the soil, several studies connected phaeohyphomycosis with the patients' occupation. However, in our study, the patient was retired and did not engage in related agriculture. In addition, he had neither tympanitis nor a history of trauma, and was immunocompetent. Cerebral phaeohyphomycosis was mostly documented in tropical regions and immunocompromised hosts. However, in this study, we found that *F. monophora* could cause severe cerebral abscesses in immunocompetent individuals by means of noninvasive ways. The study provided extremely significant insights to realize the infected groups and infected way of *F. monophora*.

Inflammatory indicators of serum in this study were within normal ranges. The G test result was higher than the upper limit of the normal range, in contrast, the serum GM test result was normal. The possible reasons could be that substrates for the detection of GM test and G test were different, and there were differences in metabolic regulation and influencing factors between the substrates. Hence, the combined detection of two tests could improve the diagnosis rate of invasive fungal disease, and the serum G test was found to be more sensitive for the diagnosis of phaeohyphomycosis.

Early and rapid diagnosis are crucial for the effective treatment of invasive fungal diseases. The direct results of etiological diagnosis provide a basis for empirical and early treatment. MRI only revealed a space-occupying lesion in the right temporal lobe, nevertheless, gram staining and fungal fluorescence staining of the cerebral abscess specimen provided evidence for fungal infection immediately. Given the fact that pathogen cultures have a significant turnaround time which often delays the diagnosis, the development of molecular diagnostics for more rapid identification is necessary and promising. The results indicated that voriconazole, posaconazole and itraconazole had remarkable anti-*F. monophora* effect.

In agreement with previous literature,<sup>14–16</sup> the satisfactory antifungal effect of itraconazole was corresponding to the drug susceptibility results in this study. Taking many factors into consideration, including remarkable antifungal effects and relatively low side effects, triazole antifungal drugs can be applied as empiric therapeutic drugs for phaeohiphomycosis.<sup>17</sup>

Although the *G. mellonella* infection model is still in its infancy, *G. mellonella* has become increasingly applied as a substitute host to study infectious diseases and the virulence of the pathogen in recent years.<sup>18,19</sup> In this study, it has been shown that the virulence and melanization in *G. mellonella* models for *F. monophora*, and the death rates of infected larvae were positively related with injected concentrations of fungus. Experimental conditions and operations often differ between individual research labs and need standardized operating procedures to reduce the differences. We constructed the phylogenetic tree from the ITS sequences of the clinical isolate along with ten Chinese *F. monophora* isolates, revealing that there is high relatedness in *F. monophora* strains collected from several regions in China.

In conclusion, our study presents one confirmed *F. monophora*-caused cerebral abscess case. *F. monophora* is an important neurotropic dematiaceous fungus and increasingly causing disease in immunocompetent individuals by means of noninvasive ways. Fungal culture, stainings, and molecular methods were utilized to identify the etiologic agent. The study is crucial on account of the increased incidence of cerebral infections by *F. monophora* and triazole antifungal drugs can be applied as empiric therapeutic drugs for phaeohiphomycosis.

## Ethics Approval and Consent for Publication

This study has been reviewed and approved by the Research Ethics Committee of the Fourth Affiliated Hospital of Zhejiang University School of Medicine (1018-2-J1). The consent form was signed by the patient before surgery and the patient consented to publish the clinical details. In addition, written informed consent was obtained.

## Funding

No funding was granted.

## Disclosure

The authors declare that they have no conflicts of interest.

## References

1. Arcobello JT, Revankar SG. Phaeohiphomycosis. *Semin Respir Crit Care Med*. 2020;41(1):131–140. doi:10.1055/s-0039-3400957
2. Pouran L, Naser TM, Mohammad R, et al. Disseminated phaeohiphomycosis caused by *Cyphellophora ludoviensis*: a novel case report from Iran. *Australas J Dermatol*. 2020;61(3):250–252. doi:10.1111/ajd.13262
3. Revankar SG, Sutton DA, Rinaldi MG. Primary central nervous system phaeohiphomycosis: a review of 101 cases. *Clin Infect Dis*. 2004;38(2):206–216. doi:10.1086/380635
4. Takei H, Goodman JC, Powell SZ. Cerebral phaeohiphomycosis caused by *Ladophialophora bantiana* and *Fonsecaea monophora*: report of three cases. *Clin Neuropathol*. 2007;26(1):21–27. doi:10.5414/npp26021
5. Qiu Y, Zhang J, Tang Y, et al. Case report: fever- pneumonia- lymphadenectasis- osteolytic- subcutaneous nodule: disseminated chromoblastomycosis caused by *Phialophora*. *J Infect Chemother*. 2019;25(12):1031–1036. doi:10.1016/j.jiac.2019.05.002
6. He Y, Zheng HL, Mei H, et al. Phaeohiphomycosis in China. *Front Cell Infect Microbiol*. 2022;12:895329. doi:10.3389/fcimb
7. Surash S, Tyagi A, De Hoog GS, et al. Cerebral phaeohiphomycosis caused by *Fonsecaea monophora*. *Med Mycol*. 2005;43(5):465–472. doi:10.1080/13693780500220373
8. Lim SW, Suh MK, Kang GS, et al. Molecular phylogenetics of *Fonsecaea* strains isolated from chromoblastomycosis patients in South Korea. *Mycoses*. 2011;54(5):e415–e420. doi:10.1111/j.1439-0507.2010.01937
9. Coelho RA, Brito-Santos F, Figueiredo-Carvalho MHG, et al. Molecular identification and antifungal susceptibility profiles of clinical strains of *Fonsecaea* spp. isolated from patients with chromoblastomycosis in Rio de Janeiro, Brazil. *PLoS Negl Trop Dis*. 2018;12(7):e0006675. doi:10.1371/journal.pntd.0006675
10. Liu Y, Huang X, Liu H, et al. Increased virulence of albino mutant of *Fonsecaea monophora* in *Galleria mellonella*. *Med Mycol*. 2019;57(8):1018–1023. doi:10.1093/mmy/myz007
11. Fransisca C, He Y, Chen Z, et al. Molecular identification of chromoblastomycosis clinical isolates in Guangdong. *Med Mycol*. 2017;55(8):851–858. doi:10.1093/mmy/myw140
12. Ochiai H, Kawano H, Minato S, et al. Cerebral phaeohiphomycosis: case report. *Neuropathology*. 2012;32(2):202–206. doi:10.1111/j.1440-1789.2011.01244.x
13. Litchevski V, Goldschmidt A, Nass D, et al. Cerebral phaeohiphomycosis in an immunocompetent patient: a case report and literature summary. *Clin Neurol Neurosurg*. 2014;124:179–181. doi:10.1016/j.clineuro
14. Najafzadeh MJ, Badali H, Illnait-Zaragozi MT, et al. In vitro activities of eight antifungal drugs against 55 clinical isolates of *Fonsecaea* spp. *Antimicrob Agents Chemother*. 2010;54(4):1636–1638. doi:10.1128/AAC.01655-09

15. Shen Y, Jiang B, Zhang H, et al. Combination therapy for an elderly patient with chromoblastomycosis caused by *Fonsecaea monophora*: a case report. *Ann Transl Med.* 2022;10(2):114. doi:10.21037/atm-21-6119
16. Daboit TC, Magagnin CM, Heidrich D, et al. A case of relapsed chromoblastomycosis due to *Fonsecaea monophora*: antifungal susceptibility and phylogenetic analysis. *Mycopathologia.* 2013;176(1–2):139–144. doi:10.1007/s11046-013-9660-1
17. Al-Abdely HM, Alkhunaizi AM, Al-Tawfiq JA, et al. Successful therapy of cerebral phaeohyphomycosis due to *Ramichloridium mackenziei* with the new triazole posaconazole. *Med Mycol.* 2005;43(1):91–95. doi:10.1080/13693780400011104
18. Tsai CJ, Loh JM, Proft T. *Galleria mellonella* infection models for the study of bacterial diseases and for antimicrobial drug testing. *Virulence.* 2016;7(3):214–229. doi:10.1080/21505594.2015.1135289
19. Kaito C. Understanding of bacterial virulence using the silkworm infection model. *Drug Discov Ther.* 2016;10(1):30–33. doi:10.5582/ddt.2016.01020

## Infection and Drug Resistance

Dovepress

### Publish your work in this journal

Infection and Drug Resistance is an international, peer-reviewed open-access journal that focuses on the optimal treatment of infection (bacterial, fungal and viral) and the development and institution of preventive strategies to minimize the development and spread of resistance. The journal is specifically concerned with the epidemiology of antibiotic resistance and the mechanisms of resistance development and diffusion in both hospitals and the community. The manuscript management system is completely online and includes a very quick and fair peer-review system, which is all easy to use. Visit <http://www.dovepress.com/testimonials.php> to read real quotes from published authors.

Submit your manuscript here: <https://www.dovepress.com/infection-and-drug-resistance-journal>