



Preventing Blindness with Early Cataract Surgery and Micro-Invasive Glaucoma Surgery in Patients Over 50: Guidance for Patients, Physicians and World Governments in Dealing with Glaucoma

Daniel Laroche ^{1,2}, Chisom T Madu ³

¹Department of Ophthalmology, New York Eye and Ear Infirmary, Icahn School of Medicine at Mount Sinai, New York, NY, USA; ²Advanced Eye Care of New York, New York, NY, USA; ³City University of New York School of Medicine, New York, NY, USA

Correspondence: Daniel Laroche, Advanced Eye Care of New York, New York, NY, USA, Email dlarochemd@aol.com

Purpose: To offer clinical guidance and address safety and efficacy concerns regarding the growing use of micro-invasive glaucoma surgery (MIGS) as an initial treatment for glaucoma in adult patients.

Design: Narrative literature review.

Methods: A review was conducted to assess outcomes and complications of MIGS in the treatment of glaucoma, both alone and in combination with lens replacement. These outcomes were compared with those of standard glaucoma surgery and/or glaucoma management with medication.

Results: MIGS are effective at lowering intraocular pressure (IOP) over long periods of follow-up. These techniques share a similarly high safety profile between one another. MIGS were found to have lower complication rates and to be more effective in reducing the total amount of medication needed to maintain control of intraocular pressure than standard surgery approaches.

Conclusion: MIGS techniques are growing in popularity and have been demonstrated to be a safe and effective alternative to standard glaucoma surgery. Guidance in the implementation of these procedures has been outlined.

Keywords: micro-invasive glaucoma surgery, micro-bypass stent, goniotomy, lens replacement

Introduction

Glaucoma is a leading cause of blindness worldwide, and its diagnosis and management are crucial for preventing vision loss.¹ Elevated intraocular pressure (IOP) is a significant risk factor for glaucoma progression, and reducing IOP is the primary goal of treatment. Pharmacotherapy is typically the first-line therapy for glaucoma management; however, it has limitations including noncompliance and undesirable adverse effects. Laser and surgical treatments may provide long-term IOP reduction, but have procedural risks and treatment failure. Traditional incisional procedures have begun to be replaced by minimally invasive glaucoma surgeries (MIGS) with improved safety profiles and minimal decreases in efficacy.¹

Several MIGS procedures have been developed to reduce IOP by targeting different outflow pathways. These include trabecular meshwork bypass procedures (iStent), suprachoroidal shunts (Cypass microstent), canaloplasty, gonioscopy-assisted transluminal trabeculotomy (GATT), among others.²⁻⁶ MIGS procedures offer advantages such as reduced complications compared to traditional surgeries; however, there is emerging evidence on their long-term efficacy compared to traditional surgeries or medical therapy. The development of new devices and techniques for MIGS has provided options for more individualized surgical approaches.⁷ MIGS have transformed the surgical management of glaucoma, a less invasive alternative with improved safety profiles compared to traditional surgeries.

MIGS are indicated for treatment in patients with progressive primary open-angle glaucoma (POAG) that has failed to be managed by topical medication and/or laser trabeculoplasty. MIGS serve as a less invasive alternative to traditional

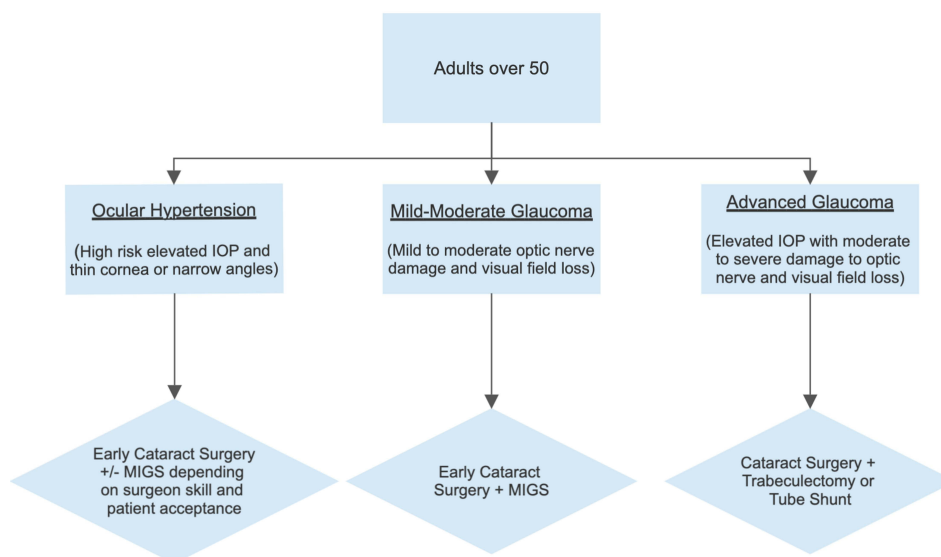


Figure 1 Surgical Management for Adults over the Age of 50 with Elevated Intraocular Pressure.

glaucoma surgeries.^{4,8,9} In the United States specifically, many trabecular meshwork MIGS are indicated for use in the reduction of IOP in adult patients with mild-to-moderate POAG only when performed in conjunction with cataract surgery (Figure 1).^{10–13}

Cataract and microinvasive glaucoma surgery has gained a tremendous amount of popularity in treating glaucoma patients earlier and with safer surgery. This is transforming the landscape of how physicians treat glaucoma. Several questions have arisen from patients, physicians, and governments about this new approach to glaucoma treatment. Within this narrative review, we attempt to address these concerns.

Should Physicians Wait for Failed Medical Management of Glaucoma to Warrant a MIGS Procedure?

Physicians should not wait for the failed medical management of glaucoma before considering a MIGS procedure. Okuda et al show that the longer patients are on medications, the lower the success rate of MIGS.¹⁴ Among glaucoma patients, a longer duration of anti-glaucoma medication use was significantly associated with surgical failure of MIGS trabeculectomy. Some people have described failed medical management for glaucoma as “all medications or nearly all of the medications that could have been tried on the patient have been tried”. With this definition many patients can progress quickly. Failed medical management of glaucoma can be defined as persistently elevated IOP and progressive vision loss despite the prescription of one or more topical medications at maximal dosage. This may be due to the combined effect of multiple factors including patient non-compliance, poor ocular absorption, long-term drug resistance, and metabolic interactions with other drugs. In cases of failed management using topical medication, laser trabeculectomy is often implemented as a second-line treatment.^{15–17}

There is some evidence to support the use of MIGS as an earlier treatment for glaucoma in patients with cataracts or clear lenses.¹⁸ In standalone procedures MIGS have been shown to be effective in reducing the IOP of mild-to-moderate open-angle glaucoma (OAG) patients and maintaining reductions in IOP of up to 35% after 24 months.^{19–21} However, recent iris registry data has shown that patients who did not have cataract surgery will need to have this thereafter.²²

The ocular hypertension treatment study demonstrated how patients with cataract surgery had lower IOP and better visual fields.²³ Early cataract surgery and MIGS procedures augment this opportunity because they are highly safe for patients. The mean normal IOP is 15 mmHG. The mean IOP in patients with untreated glaucoma is 18 mmHG.²⁴ There are exceptions depending on corneal thickness. The main reason for the increase in IOP is age-related enlargement of the lens.^{25–27} This narrows the drainage angle, increasing pigment liberation from the posterior iris, and increasing pigment

obstruction of the trabecular meshwork.^{28,29} The main risk factors for this enlarging lens are increased age, excessive UV exposure from sunlight, family history of glaucoma, smoking, diabetes, hypertension, trauma, and medications such as steroids. Early cataract surgery can help prevent glaucoma in these patients.³⁰

What Factors Should Be Considered When Selecting One MIGS Procedure Over Another?

All MIGS procedures share five common characteristics which include a high safety profile, negligible disruption of normal anatomy, an ab interno approach, efficacy in lowering IOP and/or reducing total medication, and ease of use.³¹ Common MIGS procedures often involve stent placement or goniotomy in order to bypass the trabecular meshwork and increase aqueous outflow. Trabecular meshwork bypass by stent placement is performed using devices such as the iStent (1st generation), iStent Inject, iStent Infinite and Hydrus Microstent all of which share the same indication for use in treating mild-to-moderate glaucoma during concurrent cataract removal.³² The iStent is easier to insert, but often times does not properly get into Schlemm's canal, potentially limiting its efficacy.³³ The Hydrus is larger and slightly more challenging to place accurately into Schlemm's canal. Among MIGS procedures, the Hydrus has the longest follow-up study on its effectiveness over cataract surgery alone. The Hydrus has also been shown to be more effective than selective laser trabeculoplasty (SLT) in reducing medication use.³⁴ Clear lens extraction and Hydrus has been shown to lower IOP, reduce medication use and preserve visual field in patients with open angle glaucoma.¹⁸ Trabecular meshwork bypass by tissue excision can be performed using the Kahook Dual Blade (KDB), Trabectome, Gonioscopy Assisted Transluminal Trabeculotomy (GATT), or TRAB 360. Goniotomy MIGS procedures have a greater range of indications than stent procedures. However, these procedures can increase the risk of hyphema. To reduce this risk, care should be taken to limit goniotomy to 4–5 hours and to have patients keep their heads elevated above the waist for 4 days after the procedure. They may be used in patients with OAG, angle closure glaucoma, or ocular hypertension, and can be performed during cataract surgery, or as a stand-alone procedure.³² VISCO360 ab interno canaloplasty can dilate the canal, but must be accompanied by goniotomy to be effective.

Other MIGS procedures involve enhancing or shunting aqueous outflow through alternative pathways such as the suprachoroidal space (CyPass Micro-Stent), or the subconjunctival space (XEN gel stent). Devices that operate through Schlemm's canal may be performed with or without cataract surgery for treating mild-to-moderate OAG. However, suprachoroidal devices have been withdrawn from the market by the FDA. Laroche et al have described intrascleral ciliary sulcus suprachoroidal microtube surgery.³⁵ This 12-month retrospective study demonstrated that intrascleral ciliary sulcus suprachoroidal microtube surgery can reduce IOP and medication burden in pseudophakic patients with glaucoma. However, despite several successes, surveillance should take place for IOP spikes, possible tube obstruction, and the need for additional glaucoma surgery. Subconjunctival devices are only approved for the treatment of refractory glaucoma in cases where maximal medication and previous glaucoma treatments prove ineffective.³² Trabeculectomy has also been shown to be more effective than Xen.³⁶ Another option when performing MIGS to lower IOP is to reduce aqueous production by ciliary body ablation through endocyclophotocoagulation (ECP). ECP can be performed with or without phacoemulsification and has a unique indication for patients with angle closure and plateau-iris glaucoma due to the ability for it to deepen the angle.³²

Glaucoma type, disease progression/severity, patient age, structural damage, and physician experience seem to be among the most important factors in weighing the effectiveness of one MIGS treatment over another.

Is There Sufficient Evidence to Support Placement of Stents Outside of Cataract Surgery for POAG? For Standalone Stent Procedures, What Evidence Exists That Speaks to Durable Long-Term Outcomes?

The current literature provides some evidence to support the placement of stents outside of cataract surgery. Due to FDA regulations requiring most stent procedures to be performed in conjunction with cataract surgery, there is still a need for additional studies directly comparing stand-alone stent procedures to combined stent and cataract removal. A prospective and longitudinal study by Hengerer et al evaluating the 5-year safety and effectiveness of stand-alone stent and combined stent-cataract procedures (n = 125 eyes; iStent Inject) found that stand-alone stent placement reduced mean IOP by 42% (25.3 to 14.6 mmHg) and prescribed medications by 75% (2.98 to 0.74) with stable disease parameters throughout.³⁷ These reductions

were greater than those observed in the combination group where mean IOP was reduced by 39% (22.6 to 13.8 mmHg) and prescribed medications were reduced by 69% (2.52 to 0.78).³⁷ These results suggest long-term viability in stand-alone stent placement. International studies evaluating iStent Inject as a stand-alone procedure, but without comparison groups receiving combined iStent Inject and cataract surgery, showed IOP reductions of 10.2–12.2 mmHg (39.7–48.4%) with 72.0–94.7% of participants achieving at least a 20% reduction from baseline IOP.^{38–40} Stand-alone stent placement has been shown to be successful in reducing the necessity of medication for POAG management.^{39–41}

A small study supported stand-alone MIGS trabeculotomy over combinations with cataract removal. In a prospective case series (n = 17 eyes) comparing patients with mild-to-moderate OAG undergoing combined viscodilation of Schlemm's canal and collector channels and 360° trabeculotomy (OMNI) as a standalone procedure or combined with cataract surgery, there was a 12-month absolute mean IOP reduction of 6.25 mmHg from a baseline of 18.5 mmHg among patients whom underwent combination surgery and an 8.7 mmHg reduction from a baseline of 22.1 mmHg among patients who underwent stand-alone OMNI.⁴² In addition to an overall greater reduction in mean IOP, reductions in eyes undergoing standalone OMNI were 2–4 mmHg greater at each time point than eyes undergoing combined treatment.⁴²

In a study comparing Hydrus versus two stents in mild to moderate open angle glaucoma, about half of those patients, were pseudophakic.⁴³ Washout IOP was in the high 20s and the 12 month complete success rate, defined as no repeat surgery and pressure maintained below 18 mmHg without medications, was 30% in the Hydrus group and 9.3% in the iStent group. Standalone MIGS in OAG with the Hydrus resulted in a higher surgical success rate and fewer medications compared with the double iStent procedure. MIGS devices have similar safety profiles. In a meta-analysis on standalone iStent outcomes including four randomized trials and nine single arm studies, 778 eyes achieved a mean IOP reduction of 30% at 60 months.⁴⁴ The results suggest that these devices are a safe and effective alternative for long term IOP.

Why Should Cataract Surgery and MIGS Be Performed as Early as Possible in a Patient with Both Cataract/Clear Dysfunctional Lens and POAG? Why Cataract Surgery Alone May Be Insufficient

In most instances of patients presenting with both cataract and POAG, MIGS combined with cataract surgery is a reasonable approach for treatment. A 2016 survey of AGS members found that for the treatment of POAG, phacoemulsification alone was chosen as the preferred surgical approach in 44% ± 32% of patients and that a combination of phacoemulsification with MIGS was preferred in 22% ± 27% of patients.⁴⁵ However, eight years later in 2023, there is more data with the Hydrus five-year study showing the safety and efficacy of cataract surgery and the Hydrus stent, as well as its superiority over cataract surgery alone.⁴⁶ The combined used with MIGS resulted in less need for secondary surgery.

Patient preference also plays a role when debating stand-alone cataract surgery for POAG. Although combined procedures are more effective at reducing IOP, especially in cases of more severe disease progression, combined MIGS and cataract surgery procedures are associated with an increased risk for post-operative complications.^{47,48}

What are the Risks of MIGS That You Should Be Aware of? Does This Impact Your Confidence in Placement of Standalone Stents?

The most common complications of MIGS are hyphema, IOP spikes, and the misposition of stents.⁴⁹ These complications are often self-limiting and can be managed. Suggestions in managing this are reducing steroid use appropriately and advising patients to keep their head elevated after the procedure for four days to reduce episcleral venous pressure and blood reflux and pressurizing the eye to 15–20 mmHg at the end of the procedure. Hypotony will increase the risk of blood reflux and hyphema. Surgeons must be aware of potential complications, and be comfortable in managing them, to ensure a good outcome.⁵⁰

When are Standalone MIGS Best Used Without the Combination of Cataract Surgery?

Since the enlarging lens is the most common identifiable cause of open angle glaucoma,⁵¹ performing early combined cataract extraction and MIGS works the best.⁴⁶ Goniotomy can be performed in young patients with steroid-induced glaucoma and juvenile open angle glaucoma.⁵² Not all ophthalmologists are capable with MIGS. Thus, many patients

with glaucoma and cataracts receive cataract surgery alone. When this occurs, patients may often need medications.⁵³ These patients are candidates for MIGS goniotomy to lower IOP on less medications.⁵⁴

What Constitutes the Failure or Success of a MIGS Procedure?

In the literature, criteria used for defining surgical success in evaluating stent procedures is an IOP reduction $\geq 20\%$ on the same or fewer medications.^{55,56} Lowering IOP and reducing medication use often improves compliance and reduces visual field progression.⁴⁶ Patients with low pressures on multiple medications can often benefit from MIGS and the decrease in medication use.⁵⁷

Why Should Cataract Surgery and MIGS Be Used as First Line Treatments? Why Initial Treatment with Cataract Extraction/Clear Lens Extraction and MIGS Should Be the Standard of Care

Alternatives to stents for the treatment of POAG involve argon laser trabeculoplasty (ALT) and SLT. However, ALT and SLT are not as effective as stents.³⁴ In cases of failed management using topical medication, laser trabeculoplasty may be performed to improve aqueous outflow. MIGS stent placement should be offered as a first-line treatment with cataract surgery/clear lens extraction by experienced surgeons since studies have shown that the longer the delay to MIGS, the lower the chance of success.¹⁴ Early uncomplicated cataract surgery/clear lens extraction and MIGS in persons over the age of 50 with glaucoma has been shown to lower IOP and dramatically lower medication burden.¹⁸

When is Standalone Stent Surgery Considered Reasonable and Necessary? Which Options are the Best?

While most stand-alone stents share similar indications, there are situations in which one technique may be preferable over another. First, a physician must decide on the best suited site of anatomical intervention. The three available sites of intervention to operate on are Schlemm's canal, the suprachoroidal space, and the subconjunctival space. The advantage of operating through Schlemm's canal is a high safety profile with a lower risk of hypotony and its attributable complications.³ Omni goniotomy works well, and Sinsky hook, or needle goniotomy, is very affordable.⁵⁸ Kahook goniotomy and 23 or 25 gauge needle goniotomy can also be used, but their sharper tips can lead to increased bleeding. iStent leads to the least bleeding but may not always be as efficacious if it is not inserted into the canal properly.⁵⁹ This method should also be used only in patients with mild to moderate glaucoma and is not appropriate for patients with greater than moderate disease severity or elevated episcleral venous pressure. Patients with advanced glaucoma with MIGS have been shown to progress.⁵⁴ Stents through Schlemm's canal are associated with a high risk of fibrosis that may result in the obstruction of placed stents.³ Stents placed through the suprachoroidal space are more effective at reducing IOP than stents placed through Schlemm's canal, but they share the same risk of fibrosis and device obstruction.³ Furthermore, suprachoroidal placement has an increased risk of transient hypotony and IOP spikes. Finally, subconjunctival stents are highly effective in reducing IOP in patients with more severe cases of glaucoma and have the potential to be coupled with antifibrotic agents.³ This procedure has a high risk of failure secondary to complications with bleb formation and obstruction of the stent.³

Is There Evidence to Support Placement of a Single Stent Over Multiple Stents or Should Stents Be Placed Serially While Monitoring IOP?

The placement of a single iStent is less effective at lowering IOP and managing glaucoma than the placement of multiple iStents. A study comparing groups that received either two or three iStents ($n = 53$ eyes) observed a 20% reduction in IOP and a 64% reduction in medication was in the two-iStent group, compared to a 20% reduction of IOP and an 85% reduction in medication in the three-iStent group.⁶⁰ This suggests that the number of stents used may have a greater correlation to the need for additional medications than to IOP reduction, with a greater number of stents seeming to be preferable to fewer. The role of additional stents in reducing the need for glaucoma medication is further explored in a prospective, randomized study comparing the placement of one, two, and three trabecular micro-bypass stents ($n = 119$ subjects).⁶¹ At 18 months, the implantation of each additional stent resulted in significantly greater reductions in IOP and medication use with mean

unmedicated IOP being 15.9 ± 0.9 mmHg, 14.1 ± 1.0 mmHg, and 12.2 ± 1.1 mmHg among one-stent, two-stent, and three-stent subjects, respectively.⁶¹ Mermoud showed that as many as $\frac{1}{2}$ of iStents did not enter Schlemm's canal, affecting their efficacy.⁵ Thus, this may be a reason multiple iStents are required to achieve the efficacy of one Hydrus. Hydrus is much larger and thus, does not need multiple stents. Other procedures such as goniotomy can be performed over several clock hours, also not requiring multiple stents. Sinskey goniotomy is a less expensive option that can reduce the cost of Schlemm's canal MIGS.⁴⁹ Once beyond four clock-hours of goniotomy, there is an increased risk of complications from hyphema.

How Does Surgeon Experience Impact Success with These Procedures?

MIGS procedures require additional training and have a steep learning-curve. This makes surgeon experience an important consideration when deciding on which type of procedure is most suitable. Effective practice requires training in direct gonioscopy, patient and microscope positioning, the ability to clearly identify angle structures, and practical training in angle-based procedures.⁶² The most prevalently taught MIGS technique taught at US residency programs (n = 30 programs) is the iStent (61%) followed by ECP (41%), trabectome (36%), and the Kahook blade (14%).⁶³ To be proficient at MIGS it is also important to perform these on a weekly basis to develop the experience needed for excellent surgery. Transitioning to earlier performance of cataract extraction/MIGS allows a surgeon to become more proficient and have greater success. Studies have shown that the delay in angle surgery due to years of medication and laser use reduces the success of MIGS.¹⁴

For Goniotomy

For What Types of Glaucoma Should Goniotomy Be Offered as a Therapy? Is Ocular HTN an Acceptable Indication for Either Stents or Goniotomy?

MIGS goniotomy techniques such as the KDB, trabectome, GATT, TRAB 360, Sinskey hook goniotomy, and straight bent cystotome⁵¹ may be used for a wider spectrum of disease than stand-alone stent placement. Studies have demonstrated efficacy in performing micro-invasive goniotomy for the treatment of refractory glaucoma, primary and secondary OAG, angle-closure glaucoma, pseudoexfoliation glaucoma, pigmentary glaucoma, and ocular hypertension.^{32,64} The most identifiable cause of ocular hypertension is age-related enlargement of the lens.²⁵ In patients over 50 with ocular hypertension, many will benefit from earlier cataract surgery/refractive lensectomy and goniotomy to reduce IOP, reduce the need for medication use, and dramatically reduce the progression to glaucoma. The KDB and GATT, specifically, have also seen wide use in the treatment of congenital glaucoma and juvenile OAG.^{64,65}

Who is the Optimal Patient for a Goniotomy and in Whom Should It Be Avoided?

Historically, the usual patients for traditional goniotomy are children with primary congenital glaucoma being its most common indication.⁶⁶ Qualities that made a patient an optimal candidate for goniotomy procedures are young age, clear corneas, uncontrolled IOP, and multi drug allergies.^{67,68} Recently, with new data on the safety and efficacy of cataract surgery and goniotomy in lowering IOP, this is being performed much more. Although it can be used for treating any severity of glaucoma, goniotomy should be avoided in patients with low IOP targets, as they would experience significantly reduced therapeutic effects which would not justify the risk of complications. Other contraindications include angle dysgenesis, poor angle visualization, corneal clouding, low angle pigmentation, and any other condition that may result in non-identifiable angle structures.⁶⁹ MIGS goniotomy is also best avoided in patients with ocular inflammation, neovascular glaucoma, and vitreous collapse into the anterior chamber.

How is a Classic Goniotomy Procedure for Pediatric Glaucoma Different from Goniotomy in Adults? If Pediatric Goniotomy is Frequently a Bilateral Procedure, Would a Bilateral Approach Be Reasonable in an Adult Population as Well? What Quality of Evidence Exists for Goniotomy in the Geriatric Population?

Goniotomy is used in treating primary and secondary glaucoma in children. This is often due to a delay in the development of traditional angle structures. Goniotomy bypasses developmental membrane obstruction to Schlemm's

canal which develops with age. In pediatric glaucoma, this developmental delay in the angle is often bilateral, necessitating that goniotomy also be performed bilaterally. In pediatric patients, there is more time and effort needed for pre-operative evaluation, post operative follow-up, and monitoring. In adults, a normal angle can be damaged due to an enlarging lens narrowing Schlemm's canal.⁷⁰ This enlarged lens also increases pigment liberation from the posterior iris that obstructs the trabecular meshwork. Consequently, in an elderly patient with glaucoma, it is often important to remove the lens with early cataract surgery and perform goniotomy to bypass the obstructed trabecular meshwork to restore outflow to Schlemm's canal. The earlier that this is performed, the greater the chance of preventing blindness from glaucoma becomes. Many of these patients will return to normal intraocular pressures and do not need medications. A classic goniotomy procedure for pediatric glaucoma differs from goniotomy in adults in that children require smaller angle incisions and have eyes that respond more effectively to bypassing abnormal angle development. Although pediatric goniotomy is frequently a bilateral procedure, a bilateral approach may be less effective in treating glaucoma within an elderly population where the presentation is less likely to be bilateral.

Why Has Adult Goniotomy Utilization Increased a Hundred-Fold Between 2007 and 2017 in the United States?

Although classic goniotomy is primarily indicated for children, adult goniotomy utilization increasing a hundred-fold between 2007 and 2017 is not surprising. Multiple factors, of which now include the creation of minimally invasive options such as the KDB and GATT, have contributed to its rise in popularity and has established goniotomy as a viable treatment option for adults. In addition, the increased safety of cataract surgery and data on the efficacy of this treatment to lower IOP in combination with goniotomy demonstrate that it is a powerful new treatment for glaucoma patients. Micro-invasive goniotomy combined with cataract surgery in patients with mild to moderate glaucoma lowers IOP reduces the need for medications, and can decrease the rate of blindness from glaucoma when performed early and appropriately.⁷¹

There is a great deal that shows that when pressure is controlled, the risk of vision loss decreases. And in controlling pressure, as the Horizon study showed, stents may be better at lowering IOP than medications in terms of patient outcomes.⁴⁶ Equivalent pressure lowering with a stent versus medications resulted in half the rate of visual field loss in patients who had the stent compared to those who received medication. Stable IOP, less peaks and troughs, and less reliance on medication adherence provide evidence to support using surgery as a primary treatment for lowering IOP.

It is important to preserve the visual field and brightness of vision. Glaucoma contributes to a loss in sensitivity to stimuli in peripheral vision. Mean deviation, a metric used to measure this sensitivity to stimuli in the visual field, reflects how much brighter things would need to be made in order to be visible. Mean deviation is logarithmic and measured using a decibel scale from 0 to -30. Losing one or two decibels is not catastrophic, but nonetheless influences vision. This may manifest as reading fewer words per minute, increased incidental falls, driving limitations, reduced mobility, and social withdrawal. On an individual scale, these changes may not seem significant. However, when considering tens of thousands of patients simultaneously suffering from minor vision losses, the cumulative detrimental effects these changes on society become more apparent.

In summary, early cataract surgery combined with microinvasive glaucoma surgery is growing in popularity and has been shown to be a safe and effective alternative to traditional glaucoma surgery. Currently, it may not be feasible to aim for a nationwide implementation of earlier cataract surgery in many countries due to associated costs and a lack of available skilled surgeons to meet an increase in the demand for surgery. In the United States, there are approximately 19,216 active ophthalmologists,⁷² and only about 10,000 actually perform cataract surgery.⁷³ Recent studies have shown that patients who underwent MIGS concurrently with phacoemulsification had lower reoperation rates compared to those undergoing stand-alone MIGS. However, there are also many specialists available to deal with potential complications. In addition, there are techniques like YAG capsulotomy which help to improve the outcomes of downstream adverse events after surgery such as posterior capsule opacification and preserve good vision. Surgeons must be trained in MIGS to meet the needs of the aging population worldwide. There are other conditions that can contribute to glaucoma, such as low blood pressure, mitochondrial dysfunction, glial dysfunction, as well as conditions in low-pressure individuals that may mimic glaucoma, for which a MIGS approach does not apply. The options which have been discussed in this report may

offer initial guidance to patients, physicians, and governments around the world and assist in preventing blindness from glaucoma in an affordable way.

Funding

There is no funding to report.

Disclosure

Daniel Laroche is a speaker for Sight Sciences, and Johnson and Johnson. Chisom Madu has no conflicts of interest and is not receiving funding from any agency in the public, commercial, or not-for-profit sectors.

References

1. Wagner IV, Stewart MW, Dorairaj SK. Updates on the diagnosis and management of glaucoma. *Mayo Clin Proc Innov Qual Outcomes*. 2022;6:618–635. doi:10.1016/j.mayocpiqo.2022.09.007
2. Mathew DJ, Buys YM. Minimally invasive glaucoma surgery: a critical appraisal of the literature. *Annu Rev Vis Sci*. 2020;6:47–89. doi:10.1146/annurev-vision-121219-081737
3. Pereira ICF, van de Wijdeven R, Wyss HM, Beckers HJM, den Toonder JMJ. Conventional glaucoma implants and the new MIGS devices: a comprehensive review of current options and future directions. *Eye*. 2021;35:3202–3221. doi:10.1038/s41433-021-01595-x
4. Fingeret M, Dickerson JE. The role of minimally invasive glaucoma surgery devices in the management of glaucoma. *Optomet Vision Sci*. 2018;95:155–162. doi:10.1097/OPX.0000000000001173
5. Gillmann K, Mansouri K, Ambresin A, Bravetti GE, Mermoud A. A prospective analysis of iStent inject microstent implantation: surgical outcomes, endothelial cell density, and device position at 12 months. *J Glaucoma*. 2020;29:639–647. doi:10.1097/IJG.0000000000001546
6. Saeed E, Golaszewska K, Dmuchowska DA, Zalewska R, Konopińska J. The preserflo microshunt in the context of minimally invasive glaucoma surgery: a narrative review. *Int J Environ Res Public Health*. 2023;20:2904. doi:10.3390/ijerph20042904
7. Sunaric Megevand G, Bron AM. Personalising surgical treatments for glaucoma patients. *Prog Retin Eye Res*. 2021;81:100879. doi:10.1016/j.preteyeres.2020.100879
8. Nichani P, Popovic MM, Schlenker MB, Park J, Ahmed IIK. Microinvasive glaucoma surgery: a review of 3476 eyes. *Surv Ophthalmol*. 2021;66:714–742. doi:10.1016/j.survophthal.2020.09.005
9. Ahmed IIK. MIGS and the FDA: what's in a name? *Ophthalmology*. 2015;122:1737–1739. doi:10.1016/j.ophtha.2015.06.022
10. (FDA) USFDA. iStent inject trabecular micro-bypass system (Model G2-M-IS)–P170043; 2018.
11. (FDA) USFDA. Hydrus[®] Microstent - P170034; 2018.
12. (FDA) USFDA. CyPass[®] System (Model 241-S) - P150037; 2018.
13. (FDA) USFDA. Glaukos iStent[®] trabecular micro-bypass stent (Models: GTS-100R, GTS-100L) and inserter (GTS-100i) - P080030; 2018.
14. Okuda M, Mori S, Takano F, et al. Association of the prolonged use of anti-glaucoma medications with the surgical failure of ab interno microhook trabeculotomy. *Acta Ophthalmol*. 2022;100:e1209–e1215. doi:10.1111/aos.15090
15. Crawley L, Zamir SM, Cordeiro MF, Guo L. Clinical options for the reduction of elevated intraocular pressure. *Ophthalmol Eye Dis*. 2012;4:43–64. doi:10.4137/OED.S4909
16. Laser Trial Research Group G. The Glaucoma Laser Trial (GLT) and glaucoma laser trial follow-up study: 7. Results. Glaucoma laser trial research group. *Am J Ophthalmol*. 1995;120:718–731. doi:10.1016/S0002-9394(14)72725-4
17. Wong MOM, Lee JWY, Choy BNK, Chan JCH, Lai JSM. Systematic review and meta-analysis on the efficacy of selective laser trabeculoplasty in open-angle glaucoma. *Surv Ophthalmol*. 2015;60:36–50. doi:10.1016/j.survophthal.2014.06.006
18. Laroche D, Oseni J, Nkrumah G, Ng C. Clear lensectomy with hydrus stent in black and afro-latino patients: a 1-year retrospective study. *J Ophthalmol*. 2022;2022:8011745. doi:10.1155/2022/8011745
19. Hoeh H, Ahmed IIK, Grisanti S, et al. Early postoperative safety and surgical outcomes after implantation of a suprachoroidal micro-stent for the treatment of open-angle glaucoma concomitant with cataract surgery. *J Cataract Refract Surg*. 2013;39:431–437. doi:10.1016/j.jcrs.2012.10.040
20. Hoeh H, Vold SD, Ahmed IK, et al. Initial clinical experience with the cypass micro-stent: safety and surgical outcomes of a novel supraciliary microstent. *J Glaucoma*. 2016;25:106–112. doi:10.1097/IJG.0000000000000134
21. Höh H, Grisanti S, Grisanti S, Rau M, Ianchulev S. Two-year clinical experience with the CyPass micro-stent: safety and surgical outcomes of a novel supraciliary micro-stent. *Klin Monbl Augenheilkd*. 2014;231:377–381. doi:10.1055/s-0034-1368214
22. Yang SA, Mitchell WG, Hall N, et al. Usage patterns of minimally invasive glaucoma surgery (MIGS) differ by glaucoma type: IRIS registry analysis 2013–2018. *Ophthalmic Epidemiol*. 2022;29:443–451. doi:10.1080/09286586.2021.1955391
23. Mansberger SL, Gardiner SK, Gordon M, Kass M, Ramulu P. Cataract surgery lowers intraocular pressure and medication use in the medication group of the ocular hypertension treatment study. *Am J Ophthalmol*. 2022;236:53–62. doi:10.1016/j.ajo.2021.07.008
24. Sommer A. Glaucoma risk factors observed in the Baltimore eye survey. *Curr Opin Ophthalmol*. 1996;7:93–98. doi:10.1097/00055735-199604000-00016
25. Laroche D, Capellan P. The aging lens and glaucoma in persons over 50: why early cataract surgery/refractive lensectomy and microinvasive trabecular bypass can prevent blindness and cure elevated eye pressure. *J Natl Med Assoc*. 2021;113:471–473. doi:10.1016/j.jnma.2021.03.001
26. Kader MA, Pradhan A, Shukla AG, Maheswari D, Ramakrishnan R, Midya D. Lowering of intraocular pressure after phacoemulsification in primary open-angle and angle-closure glaucoma: correlation with lens thickness. *Indian J Ophthalmol*. 2022;70:574–579. doi:10.4103/ijo.IJO_1538_21
27. Mansberger SL, Gordon MO, Jampel H, et al. Reduction in intraocular pressure after cataract extraction: the ocular hypertension treatment study. *Ophthalmology*. 2012;119:1826–1831. doi:10.1016/j.ophtha.2012.02.050
28. Semple HC, Ball SF. Pigmentary glaucoma in the black population. *Am J Ophthalmol*. 1990;109:518–522. doi:10.1016/S0002-9394(14)70680-4

29. Laroche D, Rickford K, Sinon J, Brown A, Ng C, Sakkari S. Preventing blindness from glaucoma with patient education, the NIDEK GS-1 Gonioscope, lensectomy and microinvasive glaucoma surgery. *J Natl Med Assoc.* 2023;115:175–185. doi:10.1016/j.jnma.2023.01.014
30. Ling JD, Bell NP. Role of cataract surgery in the management of glaucoma. *Int Ophthalmol Clin.* 2018;58:87–100. doi:10.1097/IIO.0000000000000234
31. Saheb H, Ahmed II. Micro-invasive glaucoma surgery: current perspectives and future directions. *Curr Opin Ophthalmol.* 2012;23:96–104. doi:10.1097/ICU.0b013e32834ff1e7
32. Aref AA, Tripathy K, Ridha F, Ertel MK, Eliassi-Rad B, Seibold LK. Microinvasive Glaucoma Surgery (MIGS). EyeWiki; 2020.
33. Gillmann K, Bravetti GE, Mermoud A, Mansouri K. A prospective analysis of istent inject microstent positioning: schlemm canal dilatation and intraocular pressure correlations. *J Glaucoma.* 2019;28:613–621. doi:10.1097/IJG.0000000000001273
34. Fea AM, Ahmed II, Lavia C, et al. Hydrus microstent compared to selective laser trabeculoplasty in primary open angle glaucoma: one year results. *Clin Exp Ophthalmol.* 2017;45:120–127. doi:10.1111/ceo.12805
35. Laroche D, Nkrumah G, Ng C. Real-world efficacy of the intrascleral ciliary sulcus suprachoroidal microtube technique in black and afro-latinx patients with glaucoma: a 1-year retrospective study. *Ther Adv Ophthalmol.* 2023;15:25158414221147445. doi:10.1177/25158414221147445
36. Cappelli F, Cutolo CA, Olivari S, et al. Trabeculectomy versus Xen gel implant for the treatment of open-angle glaucoma: a 3-year retrospective analysis. *BMJ Open Ophthalmol.* 2022;7:e000830. doi:10.1136/bmjophth-2021-000830
37. Hengerer FH, Auffarth GU, Conrad-Hengerer I. iStent inject trabecular micro-bypass with or without cataract surgery yields sustained 5-year glaucoma control. *Adv Ther.* 2022;39:1417–1431. doi:10.1007/s12325-021-02039-4
38. Fea AM, Belda JI, Rekas M, et al. Prospective unmasked randomized evaluation of the iStent inject (®) versus two ocular hypotensive agents in patients with primary open-angle glaucoma. *Clin Ophthalmol.* 2014;8:875–882. doi:10.2147/OPTH.S59932
39. Voskanyan L, García-Feijóo J, Belda JI, Fea A, Jünemann A, Baudouin C. Prospective, unmasked evaluation of the iStent® inject system for open-angle glaucoma: synergy trial. *Adv Ther.* 2014;31:189–201. doi:10.1007/s12325-014-0095-y
40. Hengerer FH, Auffarth GU, Riffel C, Conrad-Hengerer I. Second-generation trabecular micro-bypass stents as standalone treatment for glaucoma: a 36-month prospective study. *Adv Ther.* 2019;36:1606–1617. doi:10.1007/s12325-019-00984-9
41. Neuhann R, Neuhann T. Second-generation trabecular micro-bypass stent implantation: retrospective analysis after 12- and 24-month follow-up. *Eye Vision.* 2020;7:1. doi:10.1186/s40662-019-0169-7
42. Grabska-Liberek I, Duda P, Rogowska M, et al. 12-month interim results of a prospective study of patients with mild to moderate open-angle glaucoma undergoing combined viscodilation of Schlemm's canal and collector channels and 360° trabeculectomy as a standalone procedure or combined with cataract surgery. *Eur J Ophthalmol.* 2022;32:309–315. doi:10.1177/1120672121998234
43. Ahmed IIK, Fea A, Au L, et al. A prospective randomized trial comparing hydrus and iStent microinvasive glaucoma surgery implants for standalone treatment of open-angle glaucoma: the COMPARE study. *Ophthalmology.* 2020;127:52–61. doi:10.1016/j.ophtha.2019.04.034
44. Healey PR, Clement CI, Kerr NM, Tilden D, Aghajanian L. Standalone iStent trabecular micro-bypass glaucoma surgery: a systematic review and meta-analysis. *J Glaucoma.* 2021;30:606–620. doi:10.1097/IJG.0000000000001805
45. Vinod K, Gedde SJ, Feuer WJ, et al. Practice preferences for glaucoma surgery: a survey of the American glaucoma society. *J Glaucoma.* 2017;26:687–693. doi:10.1097/IJG.0000000000000720
46. Ahmed IIK, De Francesco T, Rhee D, et al. Long-term outcomes from the HORIZON randomized trial for a schlemm's canal microstent in combination cataract and glaucoma surgery. *Ophthalmology.* 2022;129:742–751. doi:10.1016/j.ophtha.2022.02.021
47. Lochhead J, Casson RJ, Salmon JF. Long term effect on intraocular pressure of phacotrabeculectomy compared to trabeculectomy. *Br J Ophthalmol.* 2003;87:850–852. doi:10.1136/bjo.87.7.850
48. Ogata-Iwao M, Inatani M, Takihara Y, Inoue T, Iwao K, Tanihara H. A prospective comparison between trabeculectomy with mitomycin C and phacotrabeculectomy with mitomycin C. *Acta Ophthalmol.* 2013;91:e500–501. doi:10.1111/aos.12133
49. Laroche D, Martin A, Brown A, Sakkari S, Ng C. Mispositioned hydrus microstents: a case series imaged with NIDEK GS-1 gonioscope. *J Ophthalmol.* 2022;2022:1605195. doi:10.1155/2022/1605195
50. Yook E, Vinod K, Panarelli JF. Complications of micro-invasive glaucoma surgery. *Curr Opin Ophthalmol.* 2018;29:147–154. doi:10.1097/ICU.0000000000000457
51. Laroche D, Scheive M. How to stop people from going blind from glaucoma using early cataract surgery/refractive lensectomy and microinvasive glaucoma surgery. *Clin Ophthalmol.* 2022;16:815–821. doi:10.2147/OPTH.S354338
52. Choi EY, Walton DS. Goniotomy for steroid-induced glaucoma: clinical and tonographic evidence to support therapeutic goniotomy. *J Pediatr Ophthalmol Strabismus.* 2015;52:183–188. doi:10.3928/01913913-20150427-05
53. Ahmed IIK, Rhee DJ, Jones J, et al. Three-year findings of the HORIZON trial: a schlemm canal microstent for pressure reduction in primary open-angle glaucoma and cataract. *Ophthalmology.* 2021;128:857–865. doi:10.1016/j.ophtha.2020.11.004
54. Laroche D, Nkrumah G, Ugoh P, Ng C. Real world outcomes of kahook dual blade goniotomy in black and afro-latinx adult patients with glaucoma: a 6-month retrospective study. *J Natl Med Assoc.* 2021;113:230–236. doi:10.1016/j.jnma.2020.09.147
55. Grover DS, Flynn WJ, Bashford KP, et al. Performance and safety of a new Ab interno gelatin stent in refractory glaucoma at 12 Months. *Am J Ophthalmol.* 2017;183:25–36.
56. Best UP, Domack H, Schmidt V, Khalifa M. Mikroinvasive glaukomchirurgie–Wirksamkeit von trabekulären stents bei kombinierten eingriffen: eine klinische studie an 65 augen [Microinvasive glaucoma surgery-Efficacy of trabecular stents in combined interventions: a clinical study on 65 eyes]. *Ophthalmologie.* 2019;116:771–779. German. doi:10.1007/s00347-018-0824-8
57. Chang EK, Gupta S, Chachanidze M, Hall N, Chang TC, Solá-Del Valle D. Safety and efficacy of microinvasive glaucoma surgery with cataract extraction in patients with normal-tension glaucoma. *Sci Rep.* 2021;11:8910. doi:10.1038/s41598-021-88358-6
58. Laroche D, Okaka Y, Ng C. A novel low cost effective technique in using a 23 gauge straight cystotome to perform goniotomy: making micro-invasive glaucoma surgery (MIGS) accessible to the Africans and the diaspora. *J Natl Med Assoc.* 2019;111:193–197. doi:10.1016/j.jnma.2018.09.006
59. Popovic M, Campos-Moller X, Saheb H, Ahmed IIK. Efficacy and adverse event profile of the istent and iStent inject trabecular micro-bypass for open-angle glaucoma: a meta-analysis. *J Curr Glaucoma Pract.* 2018;12:67–84. doi:10.5005/jp-journals-10028-1248
60. Belovay GW, Naqi A, Chan BJ, Rateb M, Ahmed II. Using multiple trabecular micro-bypass stents in cataract patients to treat open-angle glaucoma. *J Cataract Refract Surg.* 2012;38:1911–1917. doi:10.1016/j.jcrs.2012.07.017

61. Katz LJ, Erb C, Carceller GA, et al. Prospective, randomized study of one, two, or three trabecular bypass stents in open-angle glaucoma subjects on topical hypotensive medication. *Clin Ophthalmol*. 2015;9:2313–2320. doi:10.2147/OPTH.S96695
62. Dhingra D, Bhartiya S. Evaluating glaucoma surgeries in the MIGS context. *Rom J Ophthalmol*. 2020;64:85–95. doi:10.22336/rjo.2020.18
63. Yim CK, Teng CC, Warren JL, Tsai JC, Chadha N. Microinvasive glaucoma surgical training in United States ophthalmology residency programs. *Clin Ophthalmol*. 2020;14:1785–1789. doi:10.2147/OPTH.S255103
64. Sieck EG, Epstein RS, Kennedy JB, et al. Outcomes of kahook dual blade goniotomy with and without phacoemulsification cataract extraction. *Ophthalmol Glaucoma*. 2018;1:75–81. doi:10.1016/j.ogla.2018.06.006
65. Rahmatnejad K, Pruzan NL, Amanullah S, et al. Surgical outcomes of gonioscopy-assisted transluminal trabeculotomy (GATT) in patients with open-angle glaucoma. *J Glaucoma*. 2017;26:1137–1143. doi:10.1097/IJG.0000000000000802
66. Walton DS, Hodapp E. Angle surgery: goniotomy. In: Grajewski AL, Bitrian E, Papadopoulos M, Freedman SF, editors. *Surgical Management of Childhood Glaucoma: Clinical Considerations and Techniques*. Cham: Springer International Publishing; 2018:49–55.
67. Seibold LK, Aref AA, Young CC, Gill Z. Kahook Dual Blade: ab Interno Trabeculectomy. EyeWiki; 2022.
68. Lippincott Williams and Wilkins. *Shields Textbook of Glaucoma*. Philadelphia, PA: Lippincott Williams and Wilkins; 2010.
69. Tanito M, Matsuo M. Ab-interno trabeculotomy-related glaucoma surgeries. *Taiwan J Ophthalmol*. 2019;9:67–71. doi:10.4103/tjo.tjo_38_19
70. Lee RY, Chon BH, Lin SC, He M, Lin SC. Association of ocular conditions with narrow angles in different ethnicities. *Am J Ophthalmol*. 2015;160:506–515.e501. doi:10.1016/j.ajo.2015.06.002
71. Kim WJ, Kim JM, Lee WH, Kim KN, Kim CS. Effect of combined goniotomy and phacoemulsification on intraocular pressure in open-angle glaucoma patients. *Clin Exp Ophthalmol*. 2019;47:757–765. doi:10.1111/ceo.13506
72. American Academy of Ophthalmology ; 2014 <https://www.aao.org/newsroom/eye-health-statistics>. Eye Health Statistics
73. Lindstrom R. Future of cataract surgery seems promising. Heallo; 2021.

Clinical Ophthalmology

Dovepress

Publish your work in this journal

Clinical Ophthalmology is an international, peer-reviewed journal covering all subspecialties within ophthalmology. Key topics include: Optometry; Visual science; Pharmacology and drug therapy in eye diseases; Basic Sciences; Primary and Secondary eye care; Patient Safety and Quality of Care Improvements. This journal is indexed on PubMed Central and CAS, and is the official journal of The Society of Clinical Ophthalmology (SCO). The manuscript management system is completely online and includes a very quick and fair peer-review system, which is all easy to use. Visit <http://www.dovepress.com/testimonials.php> to read real quotes from published authors.

Submit your manuscript here: <https://www.dovepress.com/clinical-ophthalmology-journal>