

# Mesenteric Arterial Thrombosis Revealing Relapse of Nephrotic Syndrome in Young Women

Maryem Ferjani<sup>1</sup>, Yosra Zaimi<sup>2</sup>, Nouha Trad<sup>2</sup>, Yousra Hammi<sup>1</sup>, Myriam Ayari<sup>2</sup>, Shema Ayadi<sup>2</sup>, Taha Sayari<sup>1</sup>, Tahar Gargah<sup>1</sup>

<sup>1</sup>Department of Pediatrics, Charles Nicolle Hospital, Tunis, Tunisia; <sup>2</sup>Department of Gastroenterology, Charles Nicolle Hospital, Tunis, Tunisia

Correspondence: Nouha Trad, Department of Gastroenterology, Charles Nicolle Hospital, Boulevard of April 9, 1938, Bab Saadoun, Tunis, 1007, Tunisia, Tel +216 50858104, Email nouha1med7@gmail.com

**Background:** Nephrotic syndrome (NS) is associated with a hypercoagulable state and may be complicated by thrombotic events. Venous thrombosis is well-acknowledged, while arterial thrombosis is rather unusual.

**Case Presentation:** We present the case of a 20-year-old woman with a 12-year history of idiopathic NS revealed by extensive cerebral venous thrombosis with pulmonary embolism treated with anticoagulation therapy and oral corticosteroid therapy followed by mycophenolate mofetil (MMF). The thrombophilia assessment did not show any abnormalities. The evolution was marked by the occurrence of several NS relapses controlled by oral corticosteroid therapy until 2017. Subsequently, the patient had not presented a relapse of her disease. The anticoagulant treatment and the MMF were therefore stopped. One year later, the patient presented with severe diffuse acute abdominal pain associated with postprandial vomiting and bilateral lower limb edema. Laboratory results confirmed a NS relapse. An abdominal CT scan revealed acute thrombosis of the superior mesenteric artery with acute mesenteric ischemia. Intraoperative exploration showed mesenteric ischemia with extensive necrosis of the small intestine making their resections incompatible with life. The patient died after 48 hours.

**Conclusion:** Mesenteric arterial thrombosis, which is a rare but life-threatening NS complication, should always be considered, especially in the case of acute non-specific digestive symptoms.

**Keywords:** nephrotic syndrome, mesenteric ischemia, recurrence

## Introduction

Nephrotic syndrome (NS) is a well-known condition characterized by a hypercoagulable state due to dysfunction in the hemostatic system. In fact, thrombotic events remain one of the most serious and life-threatening complications of NS with significant morbidity and mortality.<sup>1</sup> Venous thrombosis during this syndrome has been frequently reported in studies. Nevertheless, NS-related arterial thrombosis is rarer and less well-known.<sup>2</sup> To the best of our knowledge, four cases of mesenteric arterial thrombosis as a manifestation of NS have been reported so far in the literature.<sup>3–6</sup> Herein, we report a case of mesenteric arterial thrombosis revealing NS relapse and leading to acute mesenteric ischemia and poor outcome.

## Case Report/Case Presentation

A 20-year-old woman was followed up since the age of eight for idiopathic NS inaugurated by cerebral venous thrombosis extended to the right jugular vein with a massive pulmonary embolism. The patient did not have any sequelae. She had no other medical or surgical history. A family history of thrombosis has not been reported. The patient was not biopsied because she had no kidney failure nor gross hematuria, or hypertension at first presentation; added to that, she had no extra renal signs suggestive of a secondary nephrotic syndrome. She was accordingly put on anticoagulant therapy (Oral vitamin K antagonist) and oral corticosteroid therapy with good evolution. Thereafter, the patient received several cures of high-dose corticosteroids for steroid-dependent relapses of NS. She was, hence, put on

mycophenolate mofetil (MMF) as a background therapy to avoid corticosteroids and ensure normal growth. An exhaustive assessment of thrombophilia was performed and did not show any abnormality. Homocysteine rate, blood fibrinogen rate, Protein C, protein S, antithrombin III, factor V Leiden mutation, JAK-2 mutation, cryoglobulins, anticardiolipin antibodies, lupus anticoagulant and beta-1-glycoprotein antibodies were normal. The anticoagulant treatment was stopped after nine years. The evolution was enameled by the occurrence of several relapses of her disease controlled by oral corticosteroid therapy. Remission of NS has been noted since 2017, so MMF was gradually stopped in 2019 and the patient remained asymptomatic and without any relapse.

One year later, the patient came up to our emergency department for acute intense diffuse abdominal pain without any particular irradiation associated with postprandial vomiting and bilateral lower limb edema for the last six hours. The physical examination revealed an intense epigastric tenderness with normal vital signs (arterial pressure of 120/70 mm Hg, heart rate of 83 bpm, and oxygen saturation at 100% on room air). The patient was afebrile with normal consciousness. The rest of the physical examination was unremarkable. The urinalysis with labstix revealed proteinuria. The hemogasanalysis results showed metabolic acidosis with respiratory compensation. Further laboratory tests revealed hypoalbuminemia, hypercholesterolemia, a prothrombin time at 90%, high levels of D-dimer, lactate dehydrogenase, and creatine phosphokinase as well as a biological inflammatory syndrome with a CRP of 37 mg/L, and leucocytosis at  $26.4 \times 10^3/\mu\text{L}$ . Renal and liver functions were normal (Table 1).

The patient was hospitalized in an intensive care unit with close monitoring of vital signs and initiation of resuscitation measures. An abdominal ultrasound was performed urgently showing an intra-abdominal effusion of low to moderate abundance. An abdominal CT scan revealed acute thrombosis of the superior mesenteric artery with acute mesenteric ischemia shown in Figures 1 and 2. The patient was immediately routed to the operating room. Intraoperative exploration confirmed mesenteric ischemia with extensive necrosis of almost entirely of the small bowel making their resections incompatible with life shown in Figure 3. The patient died after 48 hours.

**Table 1** Laboratory Findings of the Patient in the Emergency Department

Laboratory Parameters	Result	Normal Range
Hemoglobin (g/dl)	13.6	12–18
Hematocrit (%)	56	40–52
White blood count ( $\times 10^3/\mu\text{L}$ )	26.4	5–10
Neutrophils ( $\times 10^3/\mu\text{L}$ )	22.9	1.5–7
Platelets ( $\times 10^3/\mu\text{L}$ )	451	150–400
CRP (mg/L)	37	<8
Albumin (g/dL)	1.38	3.5–5
Cholesterol (mg/dL)	270	123.55–200
Lactate dehydrogenase (U/L)	643	91–260
Creatine phosphokinase (U/L)	400	22–269
Alanine transaminase (U/L)	13	6–55
Aspartate transaminase (U/L)	29	5–34
Gamma-glutamyl transferase (U/L)	38	6–36
Alkaline phosphatase (U/L)	98	40–150
Total bilirubin (mg/dL)	0.87	<1

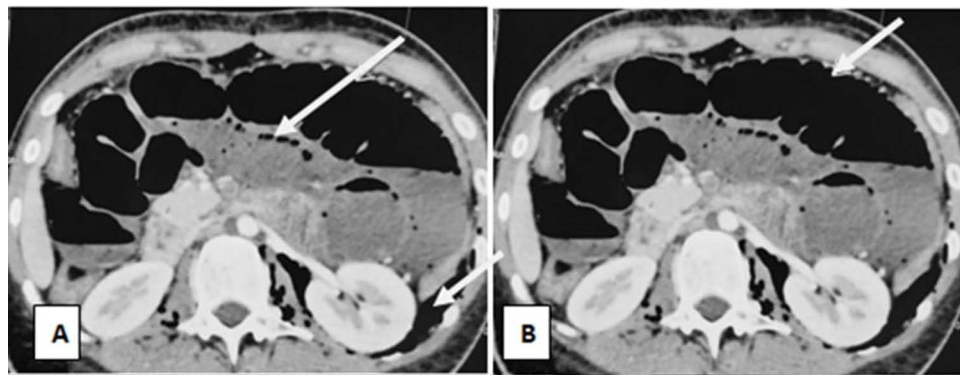
(Continued)

**Table I** (Continued).

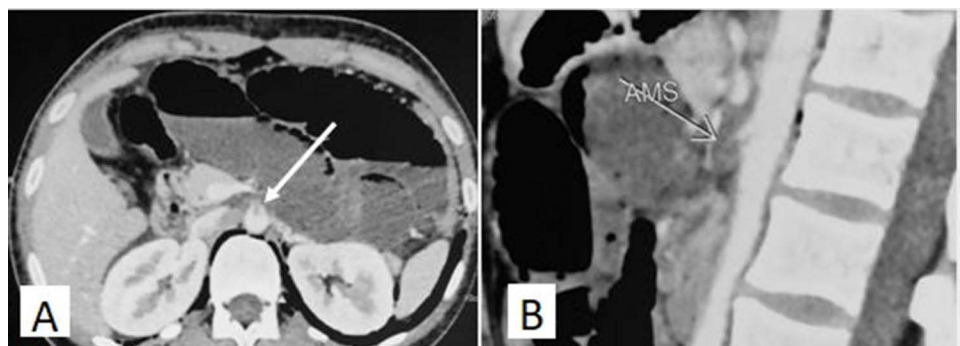
Laboratory Parameters	Result	Normal Range
Urea (mg/dL)	40.8	19.8–42
Creatinemia (mg/dL)	0.80	0.59–1.53
Natremia (mmol/L)	129	136–145
Kalemia (mmol/L)	4	3.5–4.5
Chloremia (mmol/L)	100	101–111
Lipasemia (U/L)	22	8–78
Prothrombin time (%)	90	70–100
D-dimer (ng/mL)	3000	220–500
Proteinuria (dipstick urinalysis)	4+	Negative

## Discussion

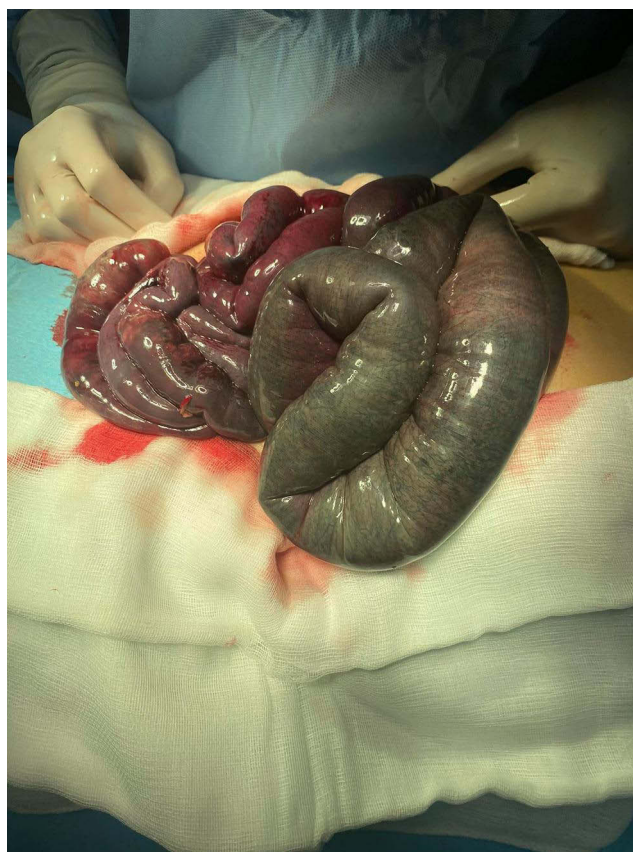
We report a case of mesenteric ischemia caused by an acute thrombosis of the superior mesenteric artery, occurring in a young patient with a history of a NS evolving for twelve years and in remission for three years. NS is caused by kidney damage resulting in loss of urine protein through small pores in podocytes. This syndrome is characterized by significant proteinuria, hypoalbuminemia, and hypercholesterolemia. Severe complications may occur during the course of NS, including acute kidney injury,



**Figure 1** Axial CT-scan: **(A)** Pneumoperitoneum (white arrows) of large abundance extending to the retroperitoneum, the retrocrural space and the mediastinum; **(B)** Diffuse hypoenhancement of the small bowel, with marked dilatation (white arrow) of the small and large bowel loops.



**Figure 2** Thrombosis of the superior mesenteric artery (arrows): **(A)**: Axial CT- scan; **(B)**: Sagittal reconstruction.  
**Abbreviation:** AMS, superior mesenteric artery.



**Figure 3** An intraoperative aspect of mesenteric ischemia with extensive necrosis of almost all of the small bowel.

infection, bone mineral loss, and thromboembolic events.<sup>7</sup> These thromboembolic complications might be the first manifestation of NS or may occur over time.<sup>8</sup> Our patient presented two episodes of thromboembolic complications during the follow-up, one of which was the inaugural NS. NS was incriminated with no abnormality of the thrombophilia assessment.

The predisposition to thromboembolic complications in NS could be due to a hypercoagulable state. The pathophysiology of this condition is not fully understood but it seems to be multifactorial including acquired risk factors and a genetic predisposition. An imbalance of antithrombotic and prothrombotic factors would be the main mechanism of the hypercoagulable state.<sup>8,9</sup> Since the primary glomerular filtration barrier defect of NS induces protein leakage, many coagulation regulatory proteins are pathologically released in urine including antithrombin III and protein S. However, the liver increases the synthesis of procoagulant factors (such as fibrinogen, factors V, VIII, and alpha-2-macroglobulin) to counterbalance this urinary loss of proteins. There is also an increase in platelet activation and aggregability and a decrease in fibrinolytic activity.<sup>6,7</sup> Moreover, steroids, by shortening prothrombin and speeding up partial thromboplastin times, can worsen the hypercoagulable condition.<sup>8–10</sup>

Furthermore, several studies have shown that the risk of thrombosis is often impacted by the severity and duration of NS.<sup>2,11</sup> In our case, the patient was followed up for an NS for 12 years and she received several courses of steroids but she had been in remission for three years.

Venous thrombosis was predominant and well acknowledged during NS while arterial thrombosis was less frequent, involving coronary, cerebral, renal, and femoral arteries more than any other vessels. As far as we know, four cases of mesenteric arterial thrombosis as a manifestation of NS have been reported so far in the literature (Table 2).<sup>3–5</sup> Mesenteric arterial thrombosis causes acute and severe abdominal pain in most patients, usually associated with nausea and vomiting. In the early phase of thrombosis, there is a discrepancy between the intensity of the abdominal pain and the minimal results of the physical examination. This non-specific symptomatology with poor physical examination makes

**Table 2** Summary of Reported Cases of Mesenteric Thrombosis Complicating Nephrotic Syndrome

Case Characteristics:	Year of Publication	Journal	Authors
Congenital nephrotic syndrome of Finnish type in a term newborn complicated by Mesenteric arterial thrombosis and with poor outcome	1995	<i>Zhonghua Min Guo Xiao Er Ke Yi Xue Hui Za Zhi.</i>	Tsai MJ et al <sup>3</sup>
Mesenteric arterial thrombosis complicating a nephrotic syndrome	1997	The New Zealand Medical Journal	McGregor DO et al <sup>4</sup>
Mesenteric and cerebral arterial thrombosis in an 8-year-old child with nephrotic syndrome	2002	The Indian Society of Nephrology	Sandhu JS et al <sup>5</sup>
Mesenteric arterial thrombosis causing short bowel syndrome in an 8-year-old child with a steroid-dependent nephrotic syndrome and a homozygous mutation of methylenetetrahydrofolate reductase	2008	Pediatric Nephrology	Ulinski T et al <sup>6</sup>
Our case: mesenteric arterial thrombosis revealing nephrotic syndrome relapse and leading to acute mesenteric ischemia and poor outcome in 20-year-women.	2023	-	Ferjani M et al

the diagnosis of mesenteric arterial thrombosis difficult. Untreated mesenteric arterial thrombosis often moves towards acute mesenteric ischemia with intestinal necrosis. At this point, the abdominal pain becomes more and more diffuse as the ischemia progresses. Mesenteric infarction can also be signaled by fever, bloody diarrhea, and shock. The evolution at this stage, as in the case of our patient, is often towards death.<sup>12</sup> Infection, as a common NS complication, can also contribute to this fatal outcome.<sup>7</sup> Indeed, according to the study by Alfakeekh et al, 76.4% of patients with childhood NS had at least one infection.<sup>13</sup> The pathogenesis of this complication is related to defects in cell-mediated immunity, urinary loss of immunoglobulins, properdin factor B band, and complement factors.<sup>7</sup>

In the present case, the dilemma of anticoagulation therapy in patients with NS in remission was raised. The KDIGO 2021 Clinical Practice Guidelines for the Management of Glomerular Diseases recommend that prophylactic anticoagulation should be considered in NS if serum albumin is <2.0 to 2.5 g/dl with additional risk for thrombosis (proteinuria >10 g/d; body mass index >35 kg/m<sup>2</sup>; genetic predisposition for thromboembolism; New York Heart Association class III or IV heart failure; recent orthopedic or abdominal surgery; or prolonged immobilization). Contraindications to prophylactic anticoagulation according to these guidelines were an uncooperative patient, a bleeding diathesis, a central nervous lesion prone to hemorrhage, prior gastrointestinal bleeding, frailty, and a genetic abnormality influencing warfarin metabolism or efficacy.<sup>14</sup>

Once the TE event has occurred, anticoagulant therapy is required for 6 to 12 months and/or for the duration of the NS.<sup>14</sup> After remission of the NS and in the absence of severe hypoproteinemia and other risk factors for thrombosis, the recommendations do not pronounce on the prolongation or discontinuation of anticoagulation, but we believe that the balance between the risk of thromboembolism and the risk of bleeding must always be taken into consideration.

Our patient presented with venous thrombosis for which she was treated with an oral vitamin K antagonist for nine years. Discontinuation of anticoagulation therapy was considered in the absence of thromboembolic risk factors. Nevertheless, the prolongation of this treatment may be beneficial to avoid thromboembolic recurrence. Larger randomized studies are needed to better support this hypothesis.

## Conclusion

Our observation highlights that mesenteric arterial thrombosis is a rare and life-threatening complication of NS even in remission, which should always be suspected in any patient with any acute non-specific digestive symptoms.

## Abbreviations

NS, nephrotic syndrome; MMF, mycophenolate mofetil.

## Acknowledgment

We express our gratitude to the staff of the department of Pediatrics of Charles Nicolle Hospital who were involved in the patient's care.

Statement of Ethics: Ethical approval is not required for this study in accordance with local or national Guidelines. Written informed consent for publication of clinical details and accompanying images was obtained from the family of the patient (parents).

## Author Contributions

All authors made a significant contribution to the work reported, whether that is in the conception, study design, execution, acquisition of data, analysis, and interpretation, or in all these areas; took part in drafting, revising or critically reviewing the article; gave final approval of the version to be published; have agreed on the journal to which the article has been submitted; and agree to be accountable for all aspects of the work.

## Funding

The authors declared that no funding was involved in supporting this work.

## Disclosure

The authors have no conflicts of interest to declare for this work.

---

## References

1. Kerlin BA, Haworth K, Smoyer WE. Venous thromboembolism in pediatric nephrotic syndrome. *Pediatr Nephrol.* 2014;39:989–997. doi:10.1007/s00467-013-2525-5
2. Tavit B, Kara F, Topaloglu R, et al. Case series of thromboembolic complications in childhood nephrotic syndrome: hacettepe experience. *Clin Exp Nephrol.* 2015;19:506-13. doi:10.1007/s10157-014-1005-y
3. Tsai MJ, Wu TJ, Teng RJ, Yau KI, Tsau YK. Mesenteric arterial thrombosis complicating congenital nephrotic syndrome of Finnish type: report of one case. *Zhonghua Min Guo Xiao Er Ke Yi Xue Hui Za Zhi.* 1995;36:445-7.
4. McGregor DO, Bailey RR. Mesenteric arterial thrombosis complicating the nephrotic syndrome. *N Z Med J.* 1997;110:62.
5. Sandhu JS, Jain D, Sandhu P, Singh R, Surgery P. Mesenteric and cerebral arterial thrombosis in nephrotic syndrome-a case report. *Indian J Nephrol.* 2002;12:59–60.
6. Ulinski T, Guignonis V, Baudet-Bonneville V, Auber F, Garcette K, Bensman A. Mesenteric thrombosis causing short bowel syndrome in nephrotic syndrome. *Pediatr Nephrol.* 2003;18:1295-7. doi:10.1007/s00467-003-1281-3
7. Hilmanto D, Mawardi F, Lestari AS, Widiasta A. Disease-associated systemic complications in childhood nephrotic syndrome: a systematic review. *Int J Nephrol Renovasc Dis.* 2022;15:53–62. doi:10.2147/IJNRD.S351053
8. Wang C, Greenbaum LA. Nephrotic syndrome. *Pediatr Clin North Am.* 2019;66:73-85. doi:10.1016/j.pcl.2018.08.006
9. Kerlin BA, Ayoob R, Smoyer WE. Epidemiology and pathophysiology of nephrotic syndrome-associated thromboembolic disease. *Clin J Am Soc Nephrol.* 2012;7:513-20. doi:10.2215/CJN.10131011
10. Mukherjee AP, Toh BH, Chan GL, Lau KS, White JC. Vascular complications in nephrotic syndrome: relationship to steroid therapy and accelerated thromboplastin generation. *Br Med J.* 1970;4:273-6. doi:10.1136/bmj.4.5730.273
11. Mahmoodi BK, ten Kate MK, Waanders F, et al. High absolute risks and predictors of venous and arterial thromboembolic events in patients with nephrotic syndrome. *Circulation.* 2008;117:224-30. doi:10.1161/CIRCULATIONAHA.107.716951
12. Tilsed JVT, Casamassima A, Kurihara H, et al. ESTES guidelines: acute mesenteric ischaemia. *Eur J Trauma Emerg Surg.* 2016;42:253-70. doi:10.1007/s00068-016-0634-0
13. Alfakeekh K, Azar M, Sowailmi BA, et al. Immunosuppressive burden and risk factors of infection in primary childhood nephrotic syndrome. *J Infect Public Health.* 2019;12:90-4. doi:10.1016/j.jiph.2018.09.006
14. Rovin BH, Adler SG, Barratt J, et al. KDIGO 2021 clinical practice guideline for the management of glomerular diseases. *Kidney Int.* 2021;100: S1-276. doi:10.1016/j.kint.2021.05.015

### International Medical Case Reports Journal

Dovepress

### Publish your work in this journal

The International Medical Case Reports Journal is an international, peer-reviewed open-access journal publishing original case reports from all medical specialties. Previously unpublished medical posters are also accepted relating to any area of clinical or preclinical science. Submissions should not normally exceed 2,000 words or 4 published pages including figures, diagrams and references. The manuscript management system is completely online and includes a very quick and fair peer-review system, which is all easy to use. Visit <http://www.dovepress.com/testimonials.php> to read real quotes from published authors.

Submit your manuscript here: <https://www.dovepress.com/international-medical-case-reports-journal-journal>