

Post Traumatic Frontal Sinus Mucocele with Subcutaneous Extension: A Case Report and Literature Review

Endris Hussen Ali 

Department of Neurosurgery, St. Paul's Millennium Medical College, Addis Ababa, Ethiopia

Correspondence: Endris Hussen Ali, Department of Neurosurgery, St. Paul's Millennium Medical College, Addis Ababa, Ethiopia, Tel +251 905484748, Email idrisdoc2007@gmail.com

Background: Langenbach (1820) first described paranasal sinus mucoceles under the name of hydatids. Roulette (1909) introduced the name mucocele. Paranasal sinus mucocele is the accumulation of mucus secretions and exfoliated epithelium in the sinuses, causing enlargement of the sinus walls. It is considered a cystic, dilatation-eroding lesion. However, the mucocele often occurs as a localized mass, causing bone erosion and displacement of surrounding structures. If left untreated, a nearby mucocele in the brain can become infected and lead to death. Frontal sinuses are often involved; sphenoid, ethmoid, and maxillary mucoceles are rare. Mucoceles usually result from sinus ostium obstruction due to infection, fibrosis, inflammation, trauma, surgery, or obstruction by tumors such as osteomas. Of all causes, patients most often present with cranio-facial trauma (82.97%) and the most common mechanism is human aggression (90.85%).

Case Presentation: This 30-year-old male patient presented with a frontal head swelling of one year duration that started after he sustained a stick injury on the frontal head one year ago, and he has an associated frontal headache for one year. There was a 4x5cm frontal, firm, palpable, non-tender lesion extending from the nasion to the frontal head. On the brain CT scan, there was frontal bone erosion at multiple sites with partial frontal sinus opacity, an externally growing mass, and an old frontal sinus fracture noted. Bifrontal craniotomy and bilateral frontal sinus cranialization were done, and the patient was discharged on the third day and seen a month later with complete improvement from headache and swelling.

Conclusion: The incidence and pathophysiology of posttraumatic frontal sinus mucoceles are not known yet. The surgical management of mucocele demand a multidisciplinary team involving neurosurgeons, ear nose and throat surgeons, oral and maxillofacial surgeons, ophthalmologists and plastic and reconstructive surgeons. By treating the primary cause, frontal sinus fracture at contact, this case report aims to raise awareness of and prevent frontal sinus mucocele and related complications.

Keywords: frontal sinus, mucocele, post-traumatic, subcutaneous extension, cranialization

Introduction

Mucocele are collections of mucus enclosed in a sac sinus epithelium lining in the air sinus that arise from an obstruction that can cause an expansion of the sinus by resorption of the bone walls. Mucoceles are benign, slow-growing lesions that commonly occur in the frontal or ethmoid sinus groups and occur as an isolated lesion. The sac may be filled with pus as the result of chronic infection; in this case, it is known as a chronic mucopyocele. Mucoceles usually result from sinus ostium obstruction due to infection, fibrosis, inflammation, trauma, surgery, or obstruction by tumors such as osteomas. Of all causes, patients most often present with cranio-facial trauma (82.97%), and the most common mechanism is human aggression (90.85%). About half of the patients have previously experienced post-traumatic epistaxis.¹ Whether the anterior or posterior wall as well as the naso-frontal duct are fractured will determine the appropriate course of treatment. Usually, there are four different sorts of therapy. When fracture displacement is minimal and sinus ventilation is guaranteed, the first treatment is conservative. Relocating and repairing the fractures is the second stage. In this circumstance, proper post-operative airflow through the naso-frontal duct must be provided by the surgeon. Sinus obliteration is the third. Even though

the posterior table is still intact, the naso-frontal ducts in this case are extensively damaged, making them unable to maintain appropriate sinus ventilation.² Mucocele following sinus tumors like osteoma and fibrous dysplasia is rare. Osteoma that is symptomatic and has a secondary mucocele must be completely removed, the mucocele must be resected, and the mucous membrane must be curetted to stop recurrence.³ Approximately 60–89% occur in the frontal sinuses, then 8–30% in the ethmoid sinus, and less than 5% in the maxillary sinus. Mucoceles in the sphenoid sinuses are not common. The presentation is usually frontal swelling with headache, sometimes diplopia, proptosis, visual loss, and facial asymmetry. The mainstay of treatment is exenteration of the mucocele with cranialization of the frontal sinus with a muscle pack at the frontonasal duct ostium to prevent recurrence and infection, as recurrence is reported in the literature. Endoscopic surgery is taking over the open approach for non-complex lesions.⁴

Case Presentation

This 30-year-old male patient presented with a frontal head swelling of one year duration that started after he sustained a stick injury on the frontal head one year ago, and he has an associated frontal headache for one year. There was no history of rhinosinusitis, no history of sinus surgery, and no history of radiation exposure. There was a 4 × 5 cm frontal, firm, palpable, non-tender lesion extending from the nasion to the frontal head. The neurologic examination was unremarkable; there was no sign or symptom of meningitis or a brain abscess. On a brain CT scan, there was frontal bone erosion at multiple sites with partial frontal sinus opacity, an externally growing mass, and an old frontal sinus fracture noted (see Figures 1 and 2). An MRI was not done due to social reasons. Nasal endoscopy and ophthalmologic examination were unremarkable. We prepared him and took him to the OR after informed written consent was obtained. We put him in a supine position, intubated him, and placed him in a supine position with slight neck extension (see Figure 3), a bicoronal skin incision, and a bifrontal craniotomy. The intraoperative finding was a soft tissue mass eroding the frontal bone and involving the frontal head galea and enlarged frontal sinuses filled with mucocele. Then, we did soft tissue mass resection from the frontal galea, mucocele exenteration, frontal sinus posterior wall or inner wall rongeuroid and flattened, all frontal sinus mucosa excised, and the ostium identified and packed with muscle bilaterally. Then a pericranial pedicled flap was applied on the frontal lobe dura down to the frontal skull base. Skin closed in two layers with a drain left in the subgaleal space, the patient was stable, extubated, transferred to PACU, and then discharged on the third postoperative day with an improved headache and frontal swelling. After a month at an outpatient follow-up clinic, we found him completely improved from his headache and swelling.

Discussion

Mucoceleles are benign lesions that occur in the paranasal sinuses and are the result of the accumulation of mucinous secretions due to obstruction of the frontonasal duct secondary to inflammation, trauma, anatomical aberrations, tumors, and rarely

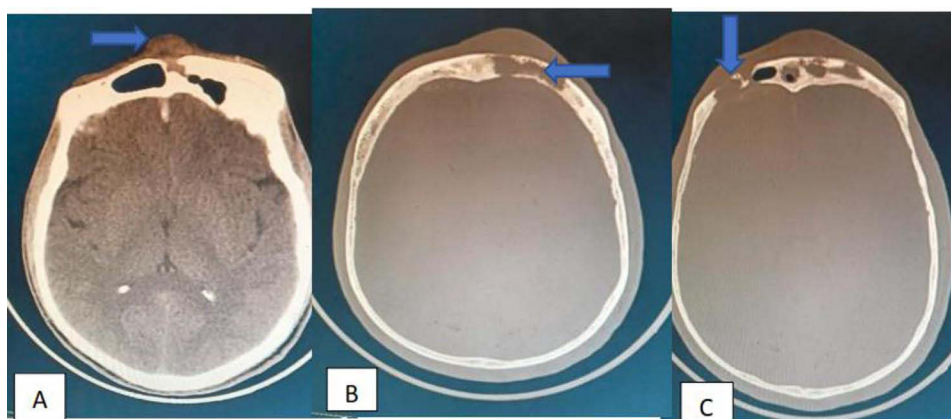


Figure 1 Bone and brain window plain CT scan demonstrating mass arising from the left frontal sinus protruding on midline (A), old fracture of the frontal sinuses (C) and erosive changes due to the mucocele (B).

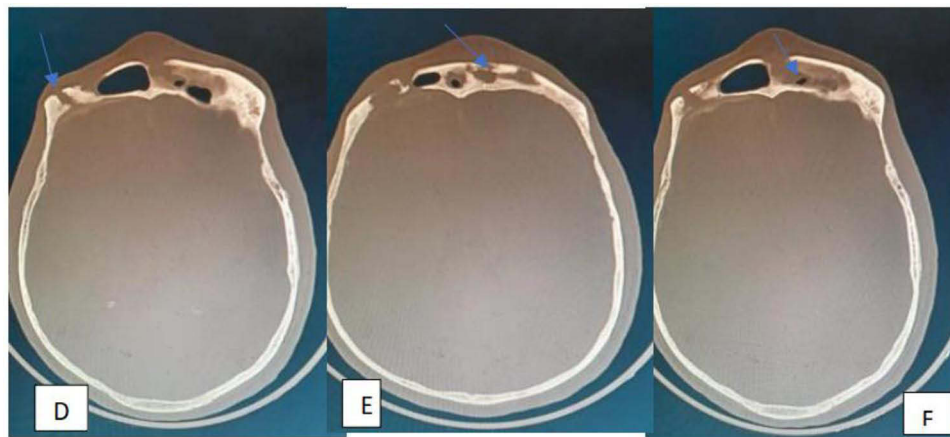


Figure 2 Brain CT scan bone window demonstrating old left frontal sinus fracture (D) with partially opacified frontal sinuses and erosion of frontal bone due to the mucocele (E and F).

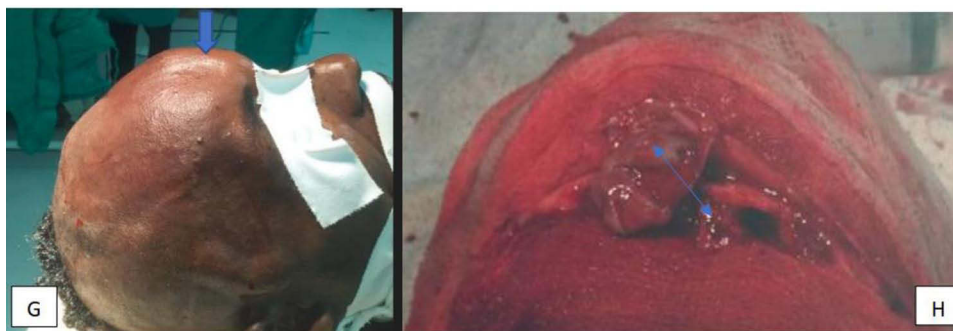

Figure 3 Photos of the patient perioperatively on operating table at supine position demonstrating frontal mass (G and H), the mucocele is well visualized with extension to the subcutaneous tissue.

fibrous dysplasia. Paranasal sinus mucoceles most commonly arise from the frontal sinus (60%), with most of the rest involving the ethmoid labyrinth and maxillary and sphenoid sinuses. The most common causes of frontal sinus mucoceles are traumatic and inflammatory changes, and sometimes they are iatrogenic after sinus surgery.⁵ Continued mucous secretion leads to the development of an expanding epithelial-lined mass, which can lead to bone erosion.⁶ A chronic infection will cause mucomyelocele, which is a collection of pus in the paranasal sinus (see Table 1). A detailed histopathological study revealed that the following frontal recess obstruction and subsequent infection in the frontal sinus cavity require constant stimulation leads to the production of lymphocytes and monocytes full of cytokines by lining fibroblasts. These cytokines, conversely, support bone resorption and remodeling, leading to mucocele enlargement. Cultured fibroblasts derived from frontoethmoidal mucosal cells, prostaglandin levels increase significantly in E2 and collagenase compared with normal frontal sinus mucosal fibroblasts. Studies have found that high levels of prostaglandin E2 play a key role in the osteolytic process explaining aggressive behavior in mucocele.⁴ The pathophysiology of post-trauma mucocele formation is unknown. Current theories include retained mucosa in the cavity, tissue remnants on the edges of the fracture segment or frontal sinus cleft, or remucosalization of the frontal sinus through the nasofrontal outflow tract. Mucoceles may develop within a fat-obiterated frontal sinus cavity. However, in the frontal sinus obliterated by bone substitute, potential space for mucocele expansion is not available. Mucocele instead expands by taking the path of least resistance through the adjacent bony wall of the orbital roof. This in turn predisposes patients to vision-threatening orbital complications if left untreated urgently, especially in cases of acute infection.⁷ Mucoceles can form at any age but are diagnosed in most patients aged 30 to 60 rare in pediatric age groups (see Table 1). There is no specific sex predominance. Aspirational mucocele material can sometimes be cultured helps to rule

Table 1 Previous Case Reports of Frontal Sinus Mucocele

Authors	Age/Sex	Presentation	Infection	Subcutaneous Mass	Open or Endoscopic Surgery	Outcome	Recurrence
Flavio et al ⁸	37/m	Frontal trauma 21 years ago Frontal mass	None	None	Endoscopic	Excellent	None
Christina et al ⁴	9/f	Right frontal mass with bifid septum Congenital malformation	None	There is subcutaneous mass	Open	Excellent	None
Widmeyer et al ⁶	68/m	Chronic sinusitis and sinus surgery 5 years ago Diplopia 1 month	Yes Culture growth	No	Endoscopic	Excellent	None
Corey w et al ⁹	Case 1 26/m	Trauma 2 years Left eye proptosis and swelling Left visual loss	Yes treated	No	Open	Excellent	Unknown
Corey w et al ⁹	Case 2 57/m	Trauma 17 years ago Left eye proptosis, diplopia and visual loss	Yes mucopyocele	No	Open transorbital and endoscopic	Fair	Recurrence in 9 months
Francesco et al ⁷	23/m	Trauma 9 years ago Impaired mentation, symptom of meningitis	Yes meningitis	No	Open bifrontal craniotomy, cranialization and antibiotics	Excellent	None
Ryan A et al ¹⁰	80/f	Trauma 45 years ago Frontal mass	Yes mucopyocele	Mainly presented as subcutaneous mass	Open bifrontal craniotomy, cranialization and antibiotics	Excellent	None

out superinfection of the mucocele. The study proved that the most common isolates were *Staphylococcus aureus*, alpha-hemolytic streptococci, *Haemophilus* species, and gram-negative bacilli. Among anaerobic bacteria were *Propionibacterium acnes*, *Peptostreptococcus*, *Prevotella*, and *Fusobacterium* species.⁴

The clinical presentation of mucoceles varies with the anatomical site. The typical presentation is insidious at the onset. Patients with frontoethmoidal mucoceles may develop frontal headaches, facial asymmetry, or swelling, as well as ophthalmic manifestations such as impaired visual acuity, decreased eye motility, or proptosis. The clinical presentation of mucoceles varies from asymptomatic to incapacitating headaches and visual disturbances. Proptosis (83%) and diplopia (45%) are common presentations (see Table 1). On physical examination, periorbital tenderness, swelling, chemosis, decreased visual acuity, and restriction of extraocular movement can be determined. Erosion of the posterior wall of the frontal sinus can lead to meningitis or a CSF fistula by eroding the duramater as well. The posterior frontal sinus wall is prone to erosion since it is thin-walled. There is a tendency for bone erosion and intracranial expansion more often seen in the presence of infection. The direction of proptosis can help significantly with lesion localization mass to the apex of the orbit produces straight forward proptosis, while lesions located anteriorly at the fronto-ethmoidal complex produce lateral, downward, and forward proptosis, which is also caused by lesions invading the orbit from a large frontal sinus.⁴

In addition to complete blood counts and organ function tests, serum electrolyte imaging is recommended. For CT diagnosis of mucocele: homogeneous isodense mass, well-defined margins, and surrounding patchy osteolysis are the triads. Sinus wall erosion with marginal sclerosis is also another finding. In general, mucoceles are fairly bright on T1W images compared to the brain and iso-hyperintense on T2W images, and this is pathognomonic for mucoceles. Neoplastic processes

are isointense to the brain on both T1 and T2W images. Hyperintensity on the T1W image indicates proteinaceous or hemorrhagic material in the lesion. This can result in a misdiagnosis. Another shortcoming of MRI in the diagnosis of mucoceles is that if they contain impermeable proteinaceous material, it can become an almost void signal on T1W and T2W images like air. This will make it difficult to find on MRI alone. On the CT, however, the thickened content will be of high density, which makes diagnosis easier. CT and MRI are complementary in complicated cases.⁴

As most frontal sinus mucocele are post-traumatic, preventive measures including cranialization, endoscopic maintenance of the frontonasal duct and frontal sinus patency, and repairing frontal sinus fractures with synthetic material are important options of management depending on patient factors and institutional experience.

Once patients develop mucocele, open surgery with a bicoronal skin incision and bifrontal craniotomy, then removing the posterior wall of the frontal sinuses and obliterating both frontonasal duct ostiums with either muscle or fat using a pericranial pedicled flap, then replacing the bone and fixing it in a cosmetically acceptable way, is one of the oldest, most effective, and most commonly practiced procedures around the world (see [Table 1](#)).

The literature has described autogenous bone grafting for frontal sinus obliteration. Cancellous bone grafts, which are often taken from the ilium, have been utilized extensively to close the gap. Cancellous bone aids in the re-ossification of the defect both peripherally and centrally. The ability to radiologically distinguish between resorption, infection, and mucocele formation during the postoperative period is another benefit of cancellous bone for obliteration over fat or muscle tissue. Calvarial split bone can be harvested in a much more practical and secure manner. In the case of harvested quantities, if bone is not enough to fill a large sinus, it can be enlarged with an admixture of bone substitutes such as demineralized bone matrix.¹¹

Nowadays, endoscopic surgery with marsupialization is taking over open surgery; this is less invasive, has minimal blood loss, and has minimal morbidity⁴ (see [Table 1](#)).

Endoscopic surgery is difficult in the following cases, making open surgery the preferred strategy: recurrent mucocele; large complex mucocele; mucocele with intracranial extension; any sinonasal lesion preventing normal drainage; location of mucocele at the most external posterosuperior part of the sinus.⁴

From our center's experience, once cranialization is done, we have never witnessed a patient with a recurrence of a mucocele.

The most common complications of mucoceles are recurrence, infection (including meningitis), epidural abscess, subdural abscess, and brain abscess. Broad-spectrum antibiotics must be administered properly in superinfected cases, and culture and sensitivity tests should be sent for every case.

The problem with the use of synthetic materials is the high risk of infection in this region.

Conclusion

The exact incidence of frontal sinus mucocele and the pathophysiology of posttraumatic mucocele formation are unknown. Both brain CT and brain MRI have to be done to rule out other common differentials. Cranialization remains the most commonly used procedure in all cases, though nowadays endoscopic surgeries with marsupialization are taking over. The most common complications of mucocele are infection, recurrence, and mass effects on adjacent structures. The surgical management of mucocele demands a multidisciplinary team involving neurosurgeons, ear, nose, and throat surgeons, oral and maxillofacial surgeons, ophthalmologists, and plastic and reconstructive surgeons.

Abbreviations

CBC, complete blood count; CSF, cerebrospinal fluid; CT, computerized tomography; MRI, magnetic resonance imaging; T1W, T1-weighted images; T2W, T2-weighted images; OR, operating room.

Institutional Approval

Institutional approval is not required for publication.

Informed Consent

Written informed consent has been provided by the patient to have the case details and any accompanying images published.

Disclosure

The author reports no conflict of interest in this work.

References

1. Sakae FA, Filho BCA, Lessa M, Voegels RL, Butugan O. Bilateral frontal sinus mucocele. *Braz J Otorhinolaryngol.* 2006;72(3):428. doi:10.1016/S1808-8694(15)30981-2
2. Christina M, Purzycki AR, Couture D, David LR. Pediatric frontal mucocele secondary to a bifid frontal sinus septum. *J Craniofac Surg.* 2010;21(5):1525–1528. doi:10.1097/SCS.0b013e3181ef2d8f
3. Weidmayer S. Frontal mucocele with intracranial extension causing frontal lobe syndrome. *Am Acad Optom.* 2015;92(5):e138–e142. doi:10.1097/OPX.0000000000000594
4. Corey W, Chandra RK, Cohen N. Orbital mucopyocele after the use of alloplastic materials in the management of frontal sinus fractures. *Otolaryngology.* 2006;135:974–976. doi:10.1016/j.otohns.2005.09.011
5. Cultrera F, Giuffrida M, Mancuso P. Delayed post-traumatic frontal sinus mucopyocele presenting with meningitis. *J Cranio Maxillo Fac Surg.* 2006;34:502–504. doi:10.1016/j.jcms.2006.07.863
6. Ryan A. Frontal sinus mucopyocele presenting as a subcutaneous forehead mass. *J Oral Maxillofac Surg.* 2015;2015:1–7.
7. Aggarwal S, Bhavana K, Keshri A, Kumar R, Srivastava A. Frontal sinus mucocele with orbital complications: management by varied surgical approaches. *Asian J Neurosurg.* 2012;7(3):135–140. doi:10.4103/1793-5482.103718
8. Anghel I, Anghel A, Soreanu C, Dumitru M. Craniofacial trauma produced by a violent mechanism Coltea ENT Clinic experience. *Rom J Leg Med.* 2012;20:215–218. doi:10.4323/rjlm.2012.215
9. Dumitru M, Vrinceanu D, Banica B. Review management of aesthetic and functional deficits in frontal bone trauma. *Medicina.* 2022;1756(58):1–9.
10. Manaka H, Tokoro K, Sakata K, Ono A, Yamamoto I. Intradural extension of mucocele complicating frontoethmoid sinus osteoma: case report. *Surgical Neurol.* 1998;50:453–456.
11. Derham C, Bucur S, Russell J, Liddington M, Chumas P. Frontal sinus mucocele in association with fibrous dysplasia: review and report of two cases. *Childs Nerv Syst.* 2011;27:327–331. doi:10.1007/s00381-010-1266-z

International Medical Case Reports Journal

Dovepress

Publish your work in this journal

The International Medical Case Reports Journal is an international, peer-reviewed open-access journal publishing original case reports from all medical specialties. Previously unpublished medical posters are also accepted relating to any area of clinical or preclinical science. Submissions should not normally exceed 2,000 words or 4 published pages including figures, diagrams and references. The manuscript management system is completely online and includes a very quick and fair peer-review system, which is all easy to use. Visit <http://www.dovepress.com/testimonials.php> to read real quotes from published authors.

Submit your manuscript here: <https://www.dovepress.com/international-medical-case-reports-journal-journal>