

A Case of Tuberculosis Cutis Orificialis

XiaoYan Zhang, Jifeng Liu

Department of Dermatology, Hangzhou Third People's Hospital, Affiliated Hangzhou Dermatology Hospital of Zhejiang University School of Medicine, Hangzhou, People's Republic of China

Correspondence: Jifeng Liu, Department of Dermatology, Hangzhou Third People's Hospital, Affiliated Hangzhou Dermatology Hospital of Zhejiang University School of Medicine, 38 West Lake Avenue, Hangzhou, 310009, People's Republic of China, Tel +86-13758145226, Email fliu8166@126.com

Abstract: This work reports a case of a 49-year-old male suffering from chronic tuberculosis who developed painful ulcers around the anus for approximately eight months. The colonoscopy revealed the presence of ulcers in the transverse colon, which were also found in the skin and intestine, as revealed by microscopic examination. The skin ulcer was positive for tuberculosis bacilli, leading to the final diagnosis of Tuberculosis cutis orificialis. The patient had a previous history of tuberculosis, which indicated that the infection in the lungs moved down to invade the intestines and finally the skin.

Keywords: skin ulcers, tuberculosis, tuberculosis cutis orificialis

Cutaneous tuberculosis presents a broad spectrum of clinical manifestations that depend on the mode of transmission of mycobacteria to the skin and the immune status of the host.¹ Tuberculosis cutis orificialis is a rare form of tuberculosis and this patient had a focus of mycobacteria infection in the intestines, from which the mycobacteria spread to the skin.

Case Report

A 49-year-old male patient came to our department due to painful ulcers around the anus, which had progressively enlarged in just over 8 months (Figure 1). The patient had a previous history of eczema with infection diagnosed at the local hospital before coming to our department, and he received cephalosporin antibiotics. However, the lesions did not heal significantly. The patient denied a history of marked chronic cough, low-grade fever, and emaciation for the past 8 months. He reported a history of tuberculosis 10 years ago for which he did not receive standard systematic treatment.

The biopsy of the ulcer indicated a granulomatous inflammation of the infected area (Figure 2a). The colonoscopy revealed the presence of ulcers in the transverse colon, and the biopsy showed a similar feature as the sample from the skin (Figure 2b). The patient did not have any evident symptom of abdominal pain or diarrhea. Although the samples from the diseased skin and intestine were negative for acid-fast staining, smears of the perianal ulcer secretion were positive for tuberculosis bacilli (Figure 3). The computer examination of the chest revealed the presence of old pulmonary tuberculosis. The full blood cell

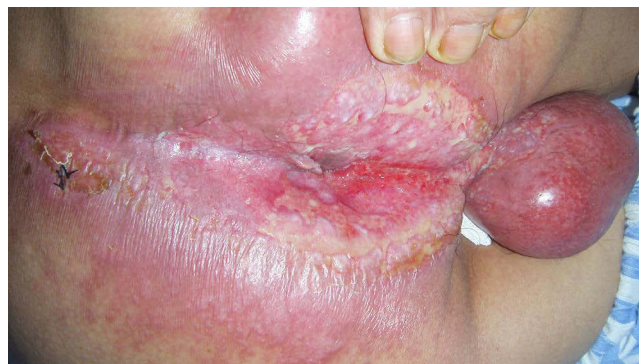


Figure 1 Ulcers around the anus extending to scrotum.

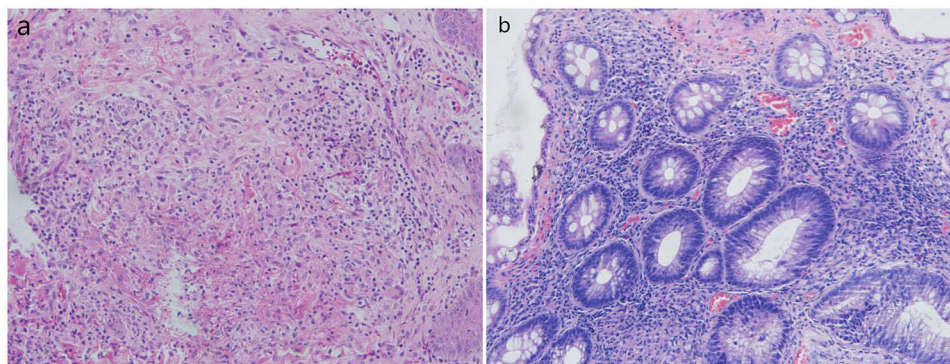


Figure 2 (a and b) Biopsy from the ulcer edge in the skin and transverse colon revealing the infection and granulomatous inflammation (H&E, 100x magnification).

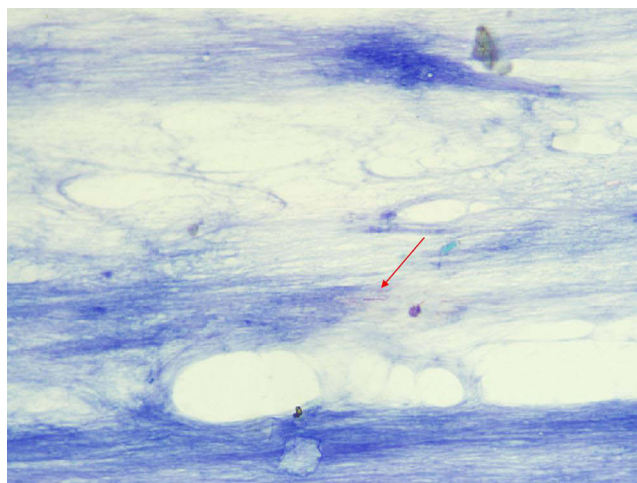


Figure 3 Smear of the perianal ulcer secretion showing tuberculosis bacilli. (The red arrow indicates the presence of tuberculosis bacilli).

count, liver and renal function, HIV, and syphilis serology were normal or negative, except for a CRP level of 59 mg/L (normal range 0–10 mg/L) and albumin level of 29 g/L (normal range 40–55 g/L). The patient was then diagnosed with Tuberculosis cutis orificialis according to the clinical and histological examination, and he was treated with rifampicin, isoniazid, ethambutol, and pyrazinamide for a total of 6 months. The ulcers healed completely after 1 month of treatment.

Discussion

Tuberculosis is primarily an infection caused by *Mycobacterium tuberculosis*, which can involve multiple organs in the body. When the skin is affected, it is defined as cutaneous tuberculosis. This disease presents different clinical manifestations, and this diversity makes diagnosis difficult.² Our patient showed similar features in the intestines and skin after biopsy. Although the samples showed nonspecific inflammation without classic granuloma formation, smears of the perianal ulcer secretion were positive for tuberculosis bacilli, providing evidence for the diagnosis of tuberculosis.

Tuberculosis cutis orificialis induces a rare form of cutaneous tuberculosis that affects only 2% of patients with tuberculosis.³ Skin involvement may occur following exogenous inoculation, contiguous spread from a nearby focus of infection, or hematogenous spread from a distant focus. It presents a wide range of clinical manifestations, which depends on the mode of disease spread.⁴ The history of our patient was very clear, and sufficient evidence was available to suggest that it was an endogenous autoinoculation infection that moved from the lungs to the intestine and finally to the skin. This report highlighted that tuberculosis treatment must be systematic, standard, adequate, and the patient must complete the entire treatment regimen.⁵

Data Sharing Statement

Data sharing is not applicable to this article as no datasets were generated or analyzed in this study.

Ethics Statement

A written informed consent was obtained from the patient for the publication of this case report and accompanying images. The authors have no ethical conflicts to disclose. The release of this case study did not require institutional approval.

Funding

This work was supported by the Hangzhou Science and Technology Bureau, China (grant no. 202004A17).

Disclosure

The authors declare no conflict of interest.

References

1. Hill MK, Sanders CV. Cutaneous Tuberculosis. *Microbiol Spectr*. 2017;5(1):5. doi:10.1128/microbiolspec.TNMI7-0010-2016
2. Charifa A, Mangat R, Amanda M. *Oakley.cutaneous Tuberculosis*. Treasure Island (FL): StatPearls Publishing; 2023
3. Turkmen M, Turk BG, Kandiloglu G, Dereli T. Tuberculosis cutis orificialis in an immunocompetent patient. *Cutis*. 2015;95(2):E4–6.
4. Mansfield BS, Pieton K. Tuberculosis Cutis Orificialis. *Open Forum Infect Dis*. 2019;6(10):ofz428. doi:10.1093/ofid/ofz428
5. Krawiecka E, Szponar E. Tuberculosis of the oral cavity: an uncommon but still a live issue. *Postepy Dermatol Alergol*. 2015;32(4):302–306. doi:10.5114/pdia.2014.43284

Clinical, Cosmetic and Investigational Dermatology

Dovepress

Publish your work in this journal

Clinical, Cosmetic and Investigational Dermatology is an international, peer-reviewed, open access, online journal that focuses on the latest clinical and experimental research in all aspects of skin disease and cosmetic interventions. This journal is indexed on CAS. The manuscript management system is completely online and includes a very quick and fair peer-review system, which is all easy to use. Visit <http://www.dovepress.com/testimonials.php> to read real quotes from published authors.

Submit your manuscript here: <https://www.dovepress.com/clinical-cosmetic-and-investigational-dermatology-journal>