

# Nonselective $\beta$ -blocker propranolol for orbital and periorbital hemangiomas in infants: a new first-line of treatment?

Rania El-Essawy<sup>1</sup>  
Rascha Galal<sup>2</sup>  
Sameh Abdelbaki<sup>1</sup>

<sup>1</sup>Department of Ophthalmology,

<sup>2</sup>Department of Pediatrics, Faculty of Medicine, Cairo University, Cairo, Egypt

**Purpose:** To determine the effectiveness and possible side effects of using propranolol for the treatment of orbital and periorbital infantile hemangiomas.

**Methods:** Infants with periorbital or orbital hemangiomas who had not received either local or systemic corticosteroids were recruited. The changes in tumor size, color, and texture, and any side effects of the drug were recorded.

**Results:** Fifteen infants with a mean age of  $8.13 \pm 4.7$  months were treated according to the set protocol. A change in the color and texture of the hemangioma occurred in the first week following treatment. Mean duration of treatment was  $7.67 \pm 3.96$  months. The size of hemangiomas decreased from a mean of  $2.4 \pm 0.9$  cm to a mean of  $1.6 \pm 1.0$  cm 3 months after treatment ( $P = 0.001$ ). One patient had to stop the drug because of peripheral vascular ischemia. Another case had the dose reduced to control a mild hyperglycemia. Serious side effects were not observed. A single case of tumor regrowth (8.3%) was recorded.

**Conclusion:** Treatment of 1–2 mg/kg/day propranolol proved to be effective and associated with minimal side effects. It is likely to replace steroids as the first-line of treatment of hemangiomas in infants.

**Keywords:** orbital and periorbital hemangioma,  $\beta$ -blockers, propranolol, corticosteroids, adrenal suppression

## Introduction

Infantile hemangioma (IH) is the most common pediatric tumor, occurring in 5%–10% of 1-year-old children, with up to 60% presenting in the head and neck region.<sup>1</sup> Large hemangiomas can cause amblyopia in up to 60% of cases due to astigmatism or occlusion of the visual axis.<sup>2</sup> Various modalities have been employed to induce regression in these lesions, such as laser therapy, cryotherapy, radiotherapy, injection of sclerosing agents, interferon- $\alpha$ , and vincristine,<sup>3</sup> but corticosteroids – whether systemic or intralesional – remain the mainstay of treatment of IH.<sup>4,5</sup> Systemic side effects of corticosteroids have been observed following systemic as well as intralesional administration and include behavior changes, irritability, insomnia, cushingoid appearance, hypertension, growth deceleration, adrenal suppression, and increased susceptibility to infections.<sup>6</sup> Local side effects include eyelid hypopigmentation,<sup>7</sup> subcutaneous fat atrophy,<sup>8</sup> and eyelid necrosis.<sup>9</sup> Intralesional injections have also been reported to cause ophthalmic artery or central retinal artery occlusions.<sup>10</sup> In June 2008, Léauté-Labrèze et al reported an accidentally discovered profound regression of a rapidly growing facial hemangioma in a 9-week-old baby following nonselective  $\beta$ -blocker propranolol administration for a cardiac indication.<sup>11</sup> Over the last 2 years, most of the studies on this matter were retrospective

Correspondence: Rania El-Essawy  
92 El Tahrir Street,  
Dokki, Giza, Egypt  
Tel +20 2 3762 7077  
Fax +20 2 3760 5625  
Email dr.relessawy@gmail.com

case reports or case series with limited number of infants included as well as follow-up interval, and some of the cases had already received prior systemic or local corticosteroids at some point. Several important questions remained unanswered. Are these results reproducible? What is the efficacy of the drug? What is the optimal dose, method of initiation, and duration of therapy? What about recurrence and possible side effects? The purpose of the present study was, therefore, to prospectively evaluate the results of this old antihypertensive drug as a new first-line of treatment for IH.

## Patients and methods

An interventional prospective case series was conducted between August 2009 and December 2010 after the approval of the local ethics committee and informed consent from the legal guardians of the participants were obtained. Inclusion criteria were infants newly diagnosed of having periorbital or orbital IH, who had not been previously treated with local or systemic corticosteroids. In one case of a deep-seated orbital hemangioma causing proptosis, a biopsy was obtained through an inferior transconjunctival orbitotomy to confirm the diagnosis before being included. Propranolol hydrochloride (PH) was given orally to these infants under the supervision of the pediatrician (RG) according to the hospital's safety protocol originally designed for other indications of PH administration in infants. Before an infant was given PH, a detailed medical history was taken and a complete ophthalmic examination performed, followed by physical examination and any necessary investigations including blood picture, blood glucose, and electrolytes. Infants with any systemic diseases, especially respiratory or cardiac disease, elevated blood sugar, or other contraindications to  $\beta$ -adrenergic blockers, were not recruited. Patients were hospitalized and a starting dose of 0.16 mg/kg every 8 hours before meals was given under close observation. If the vital signs and glucose levels remained normal, the dose was gradually increased over 2 weeks to 0.67 mg/kg every 8 hours (2 mg/kg/day). The commercially available preparation Inderal® (AstraZeneca plc, London, UK) as a 10 mg tablet was used, crushed and dissolved in 10 cc of distilled water (1 mg/cc). After the final dose of 2 mg/kg/day had been reached (usually within 1–2 weeks), the patient was discharged and instructed to visit the outpatient clinic every 2 weeks initially, during the first 3 months, then every 1–2 months. During these visits, the pediatrician would ask direct questions about the possible adverse effects of PH, such as gastrointestinal or respiratory symptoms; monitor the heart rate, blood pressure, blood glucose, and serum electrolytes;

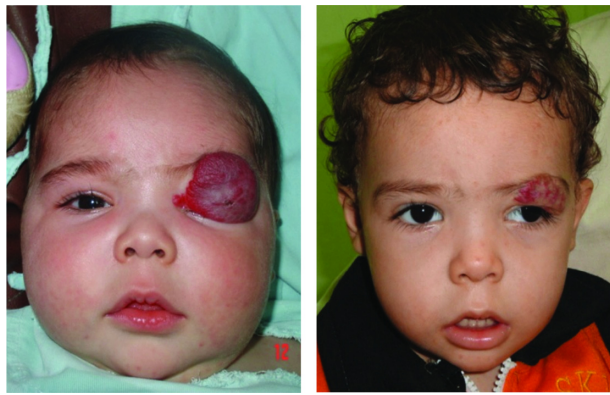and perform a thorough clinical examination including weighing the infant, and adjusting the dose of PH accordingly. Changes in the tumor in terms of color, texture, or size, and any side effects of the drug were recorded and documented by photograph. A volume estimate of the tumor was determined by taking two maximum orthogonal measurements of the lesion from the axial computed tomography (CT) scans prior to and 3 months after treatment with PH. Subdermal lesions were also measured clinically at each visit. The mean of the higher figure of the two orthogonal measurements was compared prior to, 3, and 6 months after treatment or at the end of therapy if earlier. The treatment was discontinued if the lesion had completely involuted clinically, if the parents decided that the lesion was no longer recognizable and did not want to carry on with taking the medication, or if no further decrease in size was achieved despite continuation of therapy for at least 3 months. PH treatment was tapered gradually over 2 weeks. Patients with large hemangiomas affecting the eyelid were subjected to amblyopia therapy as soon as the visual axis was cleared after prescribing glasses for any considerable refractive errors.

Data was analyzed using SPSS/Win statistical package (v 15; SPSS Inc, Chicago, IL). Numerical data were expressed as mean and standard deviation. For quantitative data, comparison of repeated measures was done using Wilcoxon signed-rank test. A *P* value <0.05 was considered significant.

## Results

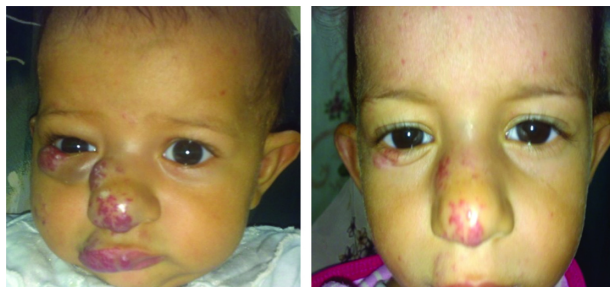Fifteen infants (11 females and 4 males) fit the inclusion criteria and were included in this study; their mean age at presentation was  $8.13 \pm 4.7$  months. With only one case exception, all hemangiomas were subdermal, ie, affecting the upper or lower eyelids or both, including the root of the nose and sometimes with a superficial element (strawberry nevus). In two cases there was an additional involvement of the tip of the nose and the lips with similar lesions. A single case had a deep orbital lesion.

The tumor responded to the drug and decreased in size in all of the cases (100%). A change in color from intense red to purple, associated with a palpable softening of the lesion, was observed as early as 1 week after PH administration (Figures 1 and 2). The visual axis, if initially obliterated, was cleared within a few weeks. The mean size of hemangiomas as measured by CT decreased from  $2.4 \pm 0.9$  cm (range  $4.0 \times 4.0$  cm to  $1.0 \times 0.5$  cm) before treatment to a mean of  $1.6 \pm 1.0$  cm (range  $3.0 \times 3.0$  cm to  $0.25 \times 0.25$  cm) 3 months after PH administration (*P* = 0.001), and continued

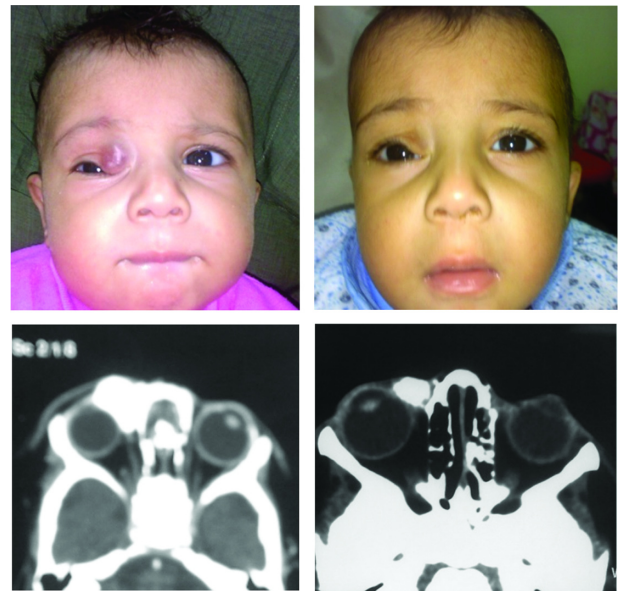

**Figure 1** A large upper-lid hemangioma prior to and 4 months after treatment.

to involute resulting in a satisfactory cosmetic result in all except one case which showed an initially huge hemangioma affecting the root of the nose and medial parts of the eyelids and orbit which continued to be disfiguring and surgical resection of the residual lesion was advocated (Figure 3). On CT, the lesion appeared homogenous, showing intense enhancement with infusion during the pretreatment proliferative phase and later, with involution, it decreased in size and appeared heterogeneous, showing fibrofatty changes (Figures 4 and 5). The mean duration of treatment required was  $7.67 \pm 3.96$  months and the mean follow-up period after propranolol had been stopped was  $5.13 \pm 3.27$  months. No serious adverse effects were observed. An acceptable decrease in heart rate and blood pressure occurred in all patients within the first month (Table 1). These were considered secondary circulatory system drug effects rather than complications and did not require the cessation of therapy. Mild hyperglycemia (above 140 mg), confirmed on three occasions, was detected in one patient after 2 months of treatment and resolved by reducing the dose to 1 mg/kg/day. Peripheral vascular ischemic changes in the form of mottling, coldness, and hypoperfusion of the skin of the trunk and lower limbs occurred in another case that had no history of a vascular disease; PH was stopped and these changes

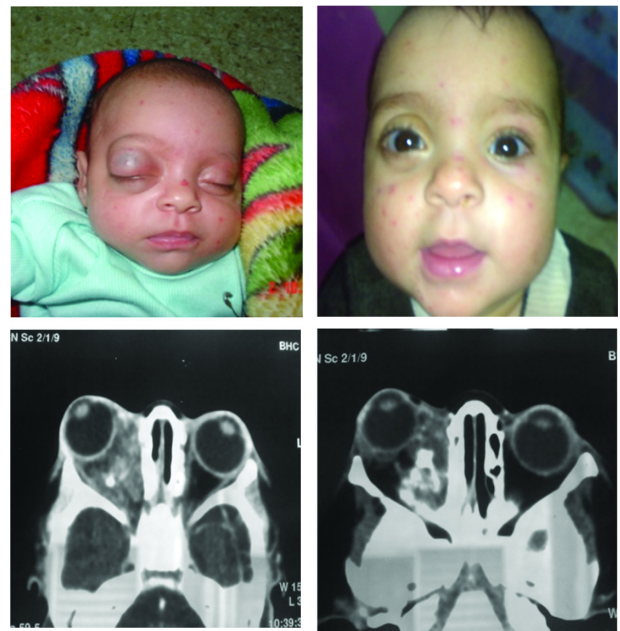


**Figure 2** Multiple facial hemangiomas prior to and 6 months after treatment.

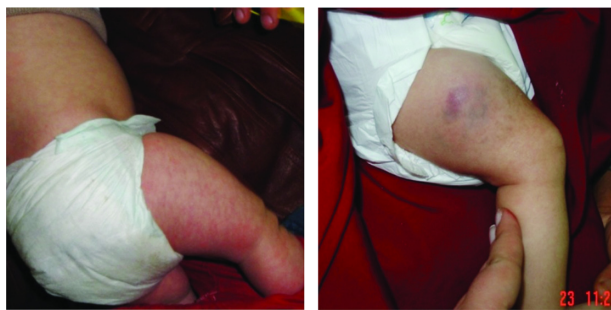

**Figure 3** A right upper-lid hemangioma prior to and 3 months after propranolol hydrochloride administration with an evident decrease in size as shown by the axial computed tomography scan with enhancement.

resolved completely without sequel (Figure 5). A single case (8.3%) showed signs of regrowth after 3 months of cessation of therapy: a 12-month-old female who presented with subdermal upper-lid hemangiomas was treated with PH for 11 months. The lesion considerably decreased in size and treatment was terminated upon request of her parents.



**Figure 4** A 2-week-old girl with a right deep orbital hemangioma causing proptosis prior to and 3 months after treatment; computed tomography scan with enhancement shows a change in the size and appearance of the lesion being initially homogenous in the proliferative phase, then becoming heterogeneous denoting fibrofatty degeneration when starting involution.



**Figure 5** Thigh of a 2-month-old child showing peripheral vascular ischemic changes at 3 weeks from propranolol hydrochloride administration; mottling became more apparent after 4 weeks. These changes were reversible.

## Discussion

This is one of few prospective studies concerning the use of oral PH for the treatment of IH that was preceded by or accompanied with administration of corticosteroids. No treatment failure was observed in any patients in this study who were able to continue the administration of PH (14 patients). PH proved to be well tolerated, safe, and without considerable complications when used in infants.

All other current drug-based therapeutic options for IH, similar to steroids, have been known to cause serious complications in the pediatric population. Therapy with immunomodulators such as cyclophosphamide or vincristine has been associated with myelosuppression and hepatotoxic effect. Also, serious neurotoxic effects in the form of spastic diplegia in up to 20% of cases were reported when interferon- $\alpha$ 2a was used in treatment of IH.<sup>12</sup>

Recently, new molecular and cellular insights have helped in understanding the pathophysiology of IH. An intrinsic defect in endothelial cells caused by a genetic mutation of the endothelial cell or its progenitor has been suggested,<sup>13</sup> another theory involves the hypoxia-inducible factor 1a, a major regulator of cellular response to hypoxia.<sup>15</sup> Finally, release

of placental cells into the circulation that might embolize to fetal vascular sites has been proposed.<sup>14</sup> In favor of this placental hypothesis are the recent reports of increased incidence of IH associated with chorionic villus sampling, but not with amniocentesis,<sup>15</sup> and the demonstration that both IH endothelium and placental vessels share the expression of several surface markers as glucose transporter 1, which is not found in other vascular tumors or malformations, nor normal skin.<sup>14</sup>

The proliferation and involution of hemangiomas are controlled by complex interactions of molecular, cellular, and hormonal regulators. Takahashi et al hypothesized that during the third trimester of fetal development, masses of plump immature endothelial cells coexist with immature pericytes, which maintain their proliferative capacity for a limited period during postnatal life.<sup>16</sup> Angiogenic peptides, such as  $\beta$ -fibroblast growth factor, vascular endothelial growth factor, and proliferating cell nuclear antigen, induce proliferation of these immature cells, resulting in the development of the hemangioma. As the endothelial cells differentiate, an influx of mast cells, various myeloid cells, and tissue inhibitors of metalloproteinases occurs. Tissue inhibitors of metalloproteinases, along with interferon and transforming growth factor produced by the mast cells, terminate the endothelial cell proliferation and induce involution by apoptosis of endothelial cells.<sup>17</sup>

In view of the new theories for pathogenesis, possible explanations for the therapeutic effect of such  $\beta$ -blockers as propranolol on IH may include vasoconstriction due to decreased release of nitric oxide, which results in the early visible change in color and is associated with a palpable softening of the hemangioma.<sup>18</sup> Decreased expression of proangiogenic factors like vascular endothelial growth factor and  $\beta$ -fibroblast growth factor may occur through the down regulation of the Raf-mitogen-activated protein kinase pathway,<sup>19</sup> matrix metalloproteinase 9 secretion, and human brain microvascular endothelial cells tubulogenesis,<sup>20</sup> which explains the progressive improvement of the hemangioma, possibly through the triggering of apoptosis of capillary endothelial cells, which results in further tumor involution.<sup>21</sup>

Pediatricians recite a long list of possible side effects of  $\beta$ -blockers including fatigue, gastrointestinal upset, nightmares, anxiety, dizziness, and bronchospasm, as well as hyperlipidemia and hyperglycemia.<sup>22</sup> Thus, they are relatively contraindicated in children with asthma or diabetes.  $\beta$ -blockers may also predispose young children,

**Table 1** Changes in size, heart rate, blood pressure, and blood glucose prior to and 3 months after treatment

	Pretreatment	After 3 months	P value
Largest diameter (cm)	2.4 $\pm$ 0.9	1.6 $\pm$ 1.0	0.001
Heart rate (beats/minute)	104.3 $\pm$ 9.4	93.4 $\pm$ 6.8	0.001
Systolic blood pressure (mmHg)	111.7 $\pm$ 13.1	92.1 $\pm$ 6.7	0.001
Diastolic blood pressure (mmHg)	68.2 $\pm$ 10.8	57.9 $\pm$ 7.8	0.007
Blood glucose (mg/dL)	114.0 $\pm$ 20.6	115.8 $\pm$ 14.8	0.300

especially infants, to hypoglycemia with even masking of the  $\beta$ -sympathetic-related symptoms,<sup>23</sup> but this has been reported mainly in circumstances of diminished feeding. This was avoided in the authors' study by ensuring that children were well fed during drug therapy. The occurrence of a reversible peripheral vascular ischemic-like change that was not linked to any original disease and, therefore, had to be linked to the administration of PH is reported for the first time in this study.

Although partial regrowth of the tumor has been commonly reported with oral corticosteroids,<sup>24</sup> to the authors' knowledge, previous studies have not mentioned the regrowth of the hemangioma after stopping PH except in a single study in which a recurrence of the hemangioma within 8 weeks of stopping the drug was reported in two patients when PH was given for a short duration and was tailed down rapidly.<sup>25</sup> In this study, however, a single case (8.3%) showed signs of regrowth of the hemangioma 3 months after PH administration had been stopped. The reason for this was possibly the cessation of therapy while the tumor still had proliferating cells. A longer follow-up period of a greater number of patients treated with PH is needed before reaching a conclusion in this matter.

## Conclusion

A PH dose between 1–2 mg/kg/day for 6 to 12 months is both effective and safe for the treatment of IH. However, a collaborative approach with a pediatrician is required. A pretreatment work up and gradual loading and tapering with close monitoring on an outpatient basis during the initial phase of treatment is recommended. The use of PH would be extremely beneficial in multiple and miliary hemangiomatosis and in deep orbital lesions where surgical excision or steroid injections are hazardous.  $\beta$ -blockers may well replace corticosteroids as the first-line of treatment for IH with improved tolerability and side-effect profile. In the future, steroid use can be limited to cases of allergy, resistance, or contraindications to  $\beta$ -blockers.

## Acknowledgment

The authors appreciate the consent of the guardians of those cases whose photos were used in this report so as not to mask their features to help show clearly the effect of treatment.

## Disclosure

The authors report no conflicts of interest in this work.

## References

- Powell J. Update on hemangiomas and vascular malformations. *Curr Opin Pediatr.* 1999;11(5):457–463.
- Schwartz SR, Blei F, Ceisler E, Steele M, Furlan L, Kodsi S. Risk factors for amblyopia in children with capillary hemangiomas of the eyelids and orbit. *JAAPOS.* 2006;10(3):262–368.
- Frieden IJ, Haggstrom AN, Drolet BA, et al. Infantile hemangiomas: current knowledge, future directions. Proceedings of a research workshop on infantile hemangiomas, April 7–9, 2005, Bethesda, Maryland, USA. *Pediatr Dermatol.* 2005;22(5):383–406.
- Chowdri NA, Darzi MA, Fazili Z, Iqbal S. Intralesional corticosteroid therapy for childhood cutaneous hemangiomas. *Ann Plast Surg.* 1994;33(1):46–51.
- Orawiec B, Stefanczyk L, Czajkowski J, Bogorodzki B, Gralek M. Periorbital capillary hemangiomas in children—treatment and monitoring of treatment. *Klin Oczna.* 1996;98(3):217–220. Polish.
- George ME, Sharma V, Jacobson J, Simon S, Nopper AJ. Adverse effects of systemic glucocorticosteroid therapy in infants with hemangiomas. *Arch Dermatol.* 2004;140(8):963–969.
- Cogen MS, Elsas FJ. Eyelid depigmentation following corticosteroid injection for infantile ocular adnexal hemangioma. *J Pediatr Ophthalmol Strabismus.* 1989;26(1):35–38.
- Townshend LM, Buckley EG. Linear subcutaneous fat atrophy after a single corticosteroid injection for ocular adnexal hemangioma. *Am J Ophthalmol.* 1990;109(1):102–103.
- Sutula FC, Glover AT. Eyelid necrosis following intralesional corticosteroid injection for capillary hemangioma. *Ophthalmic Surg.* 1987;18(2):103–105.
- Kushner BJ, Lemke BN. Bilateral retinal embolization associated with intralesional corticosteroid injection for capillary hemangioma of infancy. *J Pediatr Ophthalmol Strabismus.* 1993;30(6):397–399.
- Léauté-Labrèze C, Dumas de la Roque E, Hubiche T, Boralevi F, Thambo JB, Taieb A. Propranolol for severe hemangiomas of infancy. *N Engl J Med.* 2008;358(24):2649–2651.
- Barlow CF, Priebe CJ, Mulliken JB, et al. Spastic diplegia as a complication of interferon alfa-2a treatment of hemangiomas of infancy. *J Pediatr.* 1998;132(3 Pt 1):527–530.
- Ritter MR, Butschek RA, Friedlander M, Friedlander SF. Pathogenesis of infantile haemangioma: new molecular and cellular insights. *Expert Rev Mol Med.* 2007;9(32):1–19.
- North PE, Waner M, Mizeracki A, et al. A unique microvascular phenotype shared by juvenile haemangiomas and human placenta. *Arch Dermatol.* 2001;137(5):559–570.
- Burton BK, Schulz CJ, Angle B, Burd LI. An increased incidence of hemangiomas in infants born following chorionic villous sampling (CVS). *Prenat Diagn.* 1995;15(3):209–214.
- Takahashi K, Mulliken JB, Kozakewich HP, Rogers RA, Folkman J, Ezekowitz RA. Cellular markers that distinguish the phases of hemangioma during infancy and childhood. *J Clin Invest.* 1994;93(6):2357–2364.
- Ritter MR, Reinisch J, Friedlander SF, Friedlander M. Myeloid cells in infantile hemangioma. *Am J Pathol.* 2006;168(2):621–628.
- Shyu KG, Liou JY, Wang BW, Fang WJ, Chang H. Carvedilol prevents cardiac hypertrophy and overexpression of hypoxia-inducible factor-1 and vascular endothelial growth factor in pressure-overloaded rat heart. *J Biomed Sci.* 2005;12(2):409–420.
- D'Angelo G, Lee H, Weiner RI. cAMP-dependent protein kinase inhibits the mitogenic action of vascular endothelial growth factor and fibroblast growth factor in capillary endothelial cells by blocking Raf activation. *J Cell Biochem.* 1997;67(3):353–366.
- Annabi B, Lachambre MP, Plouffe K, Mounjdjian R, Beliveau R. Propranolol adrenergic blockade inhibits human brain endothelial cells tubulogenesis and matrix metalloproteinase-9 secretion. *Pharmacol Res.* 2009;60(5):438–445.

21. Sommers Smith SK, Smith DM. Beta blockade induces apoptosis in cultured capillary endothelial cells. *In Vitro Cell Dev Biol Anim.* 2002; 38(5):298–304.
22. Wiysonge C, Bradley H, Mayosi B, et al. Beta-blockers for hypertension. *Cochrane Database Syst Rev.* 2007;1:CD002003.
23. Chavez H, Ozolins D, Losek JD. Hypoglycemia and propranolol in pediatric behavioral disorders. *Pediatrics.* 1999;103(6 Pt 1): 1290–1292.
24. Abry F, Kehrli P, Speeg-Schatz C. Hemangioma of the eyelids and orbit in children: therapeutic follow-up. *J Fr Ophthalmol.* 2007;30(2): 170–176. French.
25. Chik KK, Luk CK, Chan HB, Tan HY. Use of propranolol in infantile haemangioma among Chinese children. *Hong Kong Med J.* 2010;16(5): 341–346.

## Clinical Ophthalmology

Dovepress

### Publish your work in this journal

Clinical Ophthalmology is an international, peer-reviewed journal covering all subspecialties within ophthalmology. Key topics include: Optometry; Visual science; Pharmacology and drug therapy in eye diseases; Basic Sciences; Primary and Secondary eye care; Patient Safety and Quality of Care Improvements. This journal is indexed on

Submit your manuscript here: <http://www.dovepress.com/clinical-ophthalmology-journal>

PubMed Central and CAS, and is the official journal of The Society of Clinical Ophthalmology (SCO). The manuscript management system is completely online and includes a very quick and fair peer-review system, which is all easy to use. Visit <http://www.dovepress.com/testimonials.php> to read real quotes from published authors.