


Narrowband Intense Pulsed Light Treatment for Refractory Facial Rash Associated with Dermatomyositis

Yuxin Zheng, Suiqing Cai 

Department of Dermatology, Zhejiang University School of Medicine Second Affiliated Hospital, Hangzhou, People's Republic of China

Correspondence: Suiqing Cai, Department of Dermatology, Zhejiang University School of Medicine Second Affiliated Hospital, Hangzhou, 310009, People's Republic of China, Email 2191008@zju.edu.cn

Abstract: Dermatomyositis is an inflammatory myopathy characterized by typical skin findings. Cutaneous findings of DM include heliotrope eruption, Gottron papules, Gottron sign, poikiloderma, periorbital edema, facial swelling. The unique cutaneous manifestations of dermatomyositis are often resistant to conventional treatments. Narrowband intense pulsed light is a novel treatment that may reduce vasodilation. Furthermore, it may have a role in regulating inflammation associated with dermatomyositis. We present a case of cutaneous dermatomyositis that was successfully treated with narrowband intense pulsed light.

Keywords: intense pulsed light, dermatomyositis, pulsed dye laser

Introduction

Dermatomyositis (DM) is a common idiopathic inflammatory myopathy, and skin manifestations are among its most significant symptoms.¹ Cutaneous findings of DM include heliotrope eruption, Gottron papules, Gottron sign, poikiloderma, periorbital edema, facial swelling, nail fold changes, Shawl sign, V sign, Holster sign, scalp involvement, cutaneous vasculitis, and calcinosis cutis.^{1,2} In some cases, periorbital edema can progress to facial swelling,¹ and intractable disfiguring facial rashes can severely disturb the patient's daily life. Therefore, medical approaches should be tailored according to the symptoms of the individual.

Laser therapy is considered a novel and effective method of managing recalcitrant connective tissue diseases. Such treatments include pulsed dye lasers (PDLs), argon lasers, CO₂ lasers, erbium lasers, neodymium-doped YAG lasers, and intense pulsed light (IPL).^{3,4} PDL and IPL treatments are effective for facial erythema.³ Additionally, cutaneous DM has been successfully treated with PDLs and argon lasers.⁴ However, to the best of our knowledge, IPL is rarely used for patients diagnosed with DM. During this study, we used a novel therapy comprising narrowband IPL with a wavelength of 500 to 600 nm to treat patients with DM. Narrowband IPL can efficiently cover the two absorption peaks of oxyhemoglobin (542 nm) and deoxyhemoglobin (577 nm). Because of the mechanism of selective photothermolysis, the comparatively high absorption by oxyhemoglobin and hemoglobin results in thermal coagulation and vascular closure.³

Case Report

A 25-year-old man presented to the rheumatology clinic with swelling around the eyes and rashes on the face and dorsal hands that he had experienced for more than 3 years. The patient reported mild and symmetrical proximal muscle weakness in the upper arm. A clinical examination revealed violaceous papules and plaques on the metacarpophalangeal and interphalangeal joints of the hands (Figure 1). However, no symptoms of dysphagia or respiratory problems were observed. Laboratory examination results revealed elevated lactate dehydrogenase and creatine kinase levels. Other laboratory test results, including aldolase, antinuclear antibodies (anti-SSA, anti-SSB, anti-dsDNA, anti-Smith, anti-Jo1, anti-RNP, anti-centromere, anti-histone and anti-Scl-70), rheumatoid factor, anti-mitochondrial antibody, and anti-neutrophil cytoplasmic antibody levels,

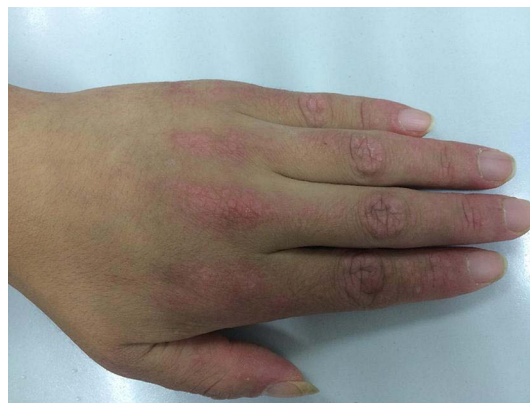

Figure 1 Gottron papules of the patient.

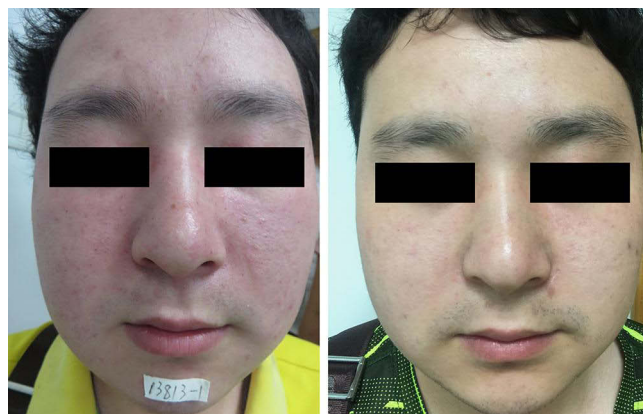

Figure 2 Photos of the patient's face before (left) and after (right) narrow-band intense pulsed light treatment.

were within the normal ranges. Sixteen myositis-specific autoantibodies were also detected and none was positive. Because the typical Gottron papules, heliotrope rash, muscle weakness, and high creatine kinase levels were observed, the final diagnosis was DM. After treatment with systemic corticosteroids, hydroxychloroquine, and immunosuppressive mycophenolate mofetil, muscle enzymes returned to normal levels and myasthenia symptoms were relieved; however, facial swelling and rashes did not improve. Because of the high cost of medications and procedures, the patient refused further treatments, such as rituximab and intravenous immunoglobulin administration. However, his refractory facial rash that caused a burning sensation seriously affected his quality of life; therefore, he visited our dermatology department to seek a suitable solution. The patient refused to use topical glucocorticoids because of concerns regarding side effects. Topical tacrolimus cream was used to treat the patient's facial condition; however, the rash and swelling did not improve. The Cutaneous Dermatomyositis Disease Area and Severity Index⁵ activity score and damage score were 9 and 4, respectively. Based on the pathology of DM, vascular dilatation and a perivascular infiltrate consisting of lymphocytes were identified; therefore, we chose narrowband IPL treatment (Alma Lasers Ltd.; specific parameters: wavelength, 500–600 nm; energy, 7.0–8.6 mJ/cm²; pulse width, 12 ms). The patient underwent four treatment sessions every 4 weeks for a total of 16 weeks. After each session, icepacks were applied to the laser-treated areas for 10 minutes. Surprisingly, after four treatment sessions, the patient's facial rash almost completely subsided (Figure 2). The Cutaneous Dermatomyositis Disease Area and Severity Index activity score and damage score were 1 and 0, respectively. The patient participated in follow-up for at least 1.5 years without side effects and rash relapse.

Discussion

Patients with DM require individualized therapy; furthermore, involvement of the skin is often challenging and recalcitrant to conventional treatment.⁶ DM treatment includes photoprotection, topical corticosteroids, calcineurin inhibitors, antimalarials,

systemic corticosteroids, methotrexate, mycophenolate mofetil, intravenous immunoglobulin, and rituximab.⁶ Evidence has indicated that intravenous immunoglobulin is beneficial for refractory cutaneous DM, and rituximab remains a viable option for patients with refractory inflammatory myopathy; however, further studies are necessary to evaluate the efficacy of rituximab.⁷

A previous study found that treatment including PDL therapy for dermatological conditions resulted in notably alleviated poikiloderma, telangiectasias, and Gottron papules without recurrence for three patients with DM.⁴ Two other patients received argon laser treatment, and their telangiectasias faded almost entirely.⁴ However, there are no published case reports of the use of IPL for DM treatment.

According to the current literature, a broad range of skin disorders, such as vascular lesions, pigmented lesions, unwanted hair growth, acne vulgaris, and photodamage, can be treated with IPL.⁸ Additionally, IPL has been used to treat connective tissue diseases such as refractory discoid lupus erythematosus⁹ and systemic sclerosis.^{10,11} For our case, IPL was selected as the treatment of choice based on the pathology of DM. The dermatopathology of DM is characterized by hyperkeratosis, vacuolar interface dermatitis, perivascular lymphocyte infiltration, and dermal edema. Additionally, endothelial cell damage, decreased capillaries, and vascular expansion are observed.² Narrowband IPL successfully treats facial swelling and rashes of patients with DM, mainly because of its capacity to regulate the inflammatory response and decrease vasodilatory effects.¹² Specifically, the pulses induce photothermolysis in blood vessels through the selective absorption of light by oxyhemoglobin.¹⁰ Additionally, the broad spectrum of narrowband IPL generates radiation that is distributed deep in the blood vessels, leading to mild vessel rupture and clotting.¹⁰ The side effects of IPL, such as swelling, erythema, hyperpigmentation, hypopigmentation, and scarring, can be avoided by changing the fluence and wavelength according to the skin type.⁸ Gan et al¹³ surveyed the treatment of facial telangiectasia with narrowband IPL and found that 90% of cases achieved more than 50% clearance after treatment. The reported adverse effects of narrowband IPL are mild, reversible, and transient.¹³ Li et al¹⁴ reported successful IPL treatment for patients with telangiectasia and hyperpigmentation after second-degree burns; more than 80% of the patients were satisfied with the outcomes, and no complications were reported. Retamar et al¹⁵ evaluated IPL treatment for patients with linear and spider facial telangiectasias and found that 67.1% of the patients experienced 80% to 100% clearance, and no scarring or other permanent adverse effects were reported. Furthermore, no adverse skin effects were observed.

Although PDL has been regarded as the standard therapy for vascular diseases,¹³ its side effects should be considered. Severe purpura and edema are the most frequent side effects of this therapy, which generally last 2 weeks or more and are inconvenient to the patient.¹³ IPL is associated with fewer negative side effects than PDL.^{13,15} Thus, we propose IPL as a novel therapy for the treatment of DM when it affects the appearance of the skin.

Conclusion

Narrowband IPL therapy is a novel and noninvasive approach that can be used to manage DM with refractory facial rashes. This method is advantageous because it is associated with fewer side effects than PDL. Therefore, we suggest its use as an auxiliary treatment with traditional treatment to alleviate symptoms and prevent disfigurement.

Consent Statements

Written informed consent was obtained from the patient for the publication of the case details and accompanying images. Reviewed and approved by the Second Affiliated Hospital of Zhejiang University Human Research Ethics Board; approval 2022-0744.

Disclosure

The authors report no conflicts of interest in this work.

References

1. Mainetti C, Terziroli Beretta-Piccoli B, Selmi C. Cutaneous manifestations of dermatomyositis: a comprehensive review. *Clin Rev Allergy Immunol.* 2017;53(3):337–356. doi:10.1007/s12016-017-8652-1
2. DeWane ME, Waldman R, Lu J. Dermatomyositis: clinical features and pathogenesis. *J Am Acad Dermatol.* 2020;82(2):267–281. doi:10.1016/j.jaad.2019.06.1309

3. Yepuri V, Patil AD, Fritz K, et al. Light-based devices for the treatment of facial erythema and telangiectasia. *Dermatol Ther.* 2021;11(6):1879–1887. doi:10.1007/s13555-021-00607-8
4. Brauer JA, Gordon Spratt EA, Geronemus RG. Laser therapy in the treatment of connective tissue diseases: a review. *Dermatol Surg.* 2014;40(1):1–13. doi:10.1111/dsu.12339
5. Tiao J, Feng R, Bird S, et al. The reliability of the Cutaneous Dermatomyositis Disease Area and Severity Index (CDASI) among dermatologists, rheumatologists and neurologists. *Br J Dermatol.* 2017;176(2):423–430. doi:10.1111/bjd.15140
6. Cobos GA, Femia A, Vleugels RA. Dermatomyositis: an update on diagnosis and treatment. *Am J Clin Dermatol.* 2020;21(3):339–353. doi:10.1007/s40257-020-00502-6
7. Wright NA, Vleugels RA, Callen JP. Cutaneous dermatomyositis in the era of biologicals. *Semin Immunopathol.* 2016;38(1):113–121. doi:10.1007/s00281-015-0543-z
8. Babilas P, Schremel S, Szeimies RM, Landthaler M. Intense pulsed light (IPL): a review. *Lasers Surg Med.* 2010;42(2):93–104. doi:10.1002/lsm.20877
9. Ekback MP, Troilius A. Laser therapy for refractory discoid lupus erythematosus when everything else has failed. *J Cosmet Laser Ther.* 2013;15(5):260–265. doi:10.3109/14764172.2013.787802
10. Murray AK, Moore TL, Richards H, Ennis H, Griffiths CE, Herrick AL. Pilot study of intense pulsed light for the treatment of systemic sclerosis-related telangiectases. *Br J Dermatol.* 2012;167(3):563–569. doi:10.1111/j.1365-2133.2012.11019.x
11. Rosholm Comstedt L, Svensson A, Hesselstrand R, Lehti L, Troilius Rubin A. Effects of intense pulsed light in microstomia in patients with systemic sclerosis: a pilot study. *J Cosmet Laser Ther.* 2017;19(3):143–148. doi:10.1080/14764172.2016.1262961
12. Li D, Lin SB, Cheng B. Intense pulsed light: from the past to the future. *Photomed Laser Surg.* 2016;34(10):435–447. doi:10.1089/pho.2016.4139
13. Gan H, Yue B, Wang Y, Lu Z. Treatment of facial telangiectasia with narrow-band intense pulsed light in Chinese patients. *J Cosmet Laser Ther.* 2018;20(7–8):442–446. doi:10.1080/14764172.2018.1427871
14. Li N, Han J, Hu D, et al. Intense pulsed light is effective in treating postburn hyperpigmentation and telangiectasia in Chinese patients. *J Cosmet Laser Ther.* 2018;20(7–8):436–441. doi:10.1080/14764172.2017.1418517
15. Retamar RA, Chames C, Pellerano G. Treatment of linear and spider telangiectasia with an intense pulsed light source. *J Cosmet Dermatol.* 2004;3(4):187–190. doi:10.1111/j.1473-2130.2004.00071.x

Clinical, Cosmetic and Investigational Dermatology

Dovepress

Publish your work in this journal

Clinical, Cosmetic and Investigational Dermatology is an international, peer-reviewed, open access, online journal that focuses on the latest clinical and experimental research in all aspects of skin disease and cosmetic interventions. This journal is indexed on CAS. The manuscript management system is completely online and includes a very quick and fair peer-review system, which is all easy to use. Visit <http://www.dovepress.com/testimonials.php> to read real quotes from published authors.

Submit your manuscript here: <https://www.dovepress.com/clinical-cosmetic-and-investigational-dermatology-journal>