


# COVID-19 Related Acute Macular Neuroretinopathy (AMN): A Case Series

Truong Andy Vu <sup>1-3</sup>, Megan Schillerstrom<sup>3,4</sup>, Saoul Mancha<sup>3</sup>, William Eric Sponsel<sup>2,3</sup>

<sup>1</sup>University of the Incarnate Word, School of Osteopathic Medicine, San Antonio, TX, 78235, USA; <sup>2</sup>University of the Incarnate Word, Department of Visual Science, San Antonio, TX, 78235, USA; <sup>3</sup>Sponsel Eye Experts, San Antonio, TX, 78233, USA; <sup>4</sup>Trinity University, Department of Neuroscience, San Antonio, TX, 78212, USA

Correspondence: Truong Andy Vu, University of the Incarnate Word School of Osteopathic Medicine, 7615 Kennedy Hill Dr, San Antonio, TX, 78235, USA, Email [tvu@student.uiwtx.edu](mailto:tvu@student.uiwtx.edu)

**Purpose:** Following the emergence of coronavirus disease 2019 (COVID-19) eye care practitioners have become accustomed to identifying and managing an array of ocular complications following the viral infection. Acute macular neuroretinopathy (AMN) is one such complication that has been reported. While the etiology of AMN has eluded researchers, current literature is suggestive of a microvascular compromise within the deep capillary plexus of the retina.

**Observations:** In this case series, we aim to explore two individual cases of presumed AMN following confirmed COVID-19 infection. Our observations and findings support the diagnosis of AMN following the criteria outlined in literature.

**Conclusion and Importance:** Although acute macular neuroretinopathy is rare, it should be considered by clinicians when considering diagnosis. With the changing landscape of the pandemic, careful and thorough history and testing are key in the diagnosis of AMN.

**Keywords:** COVID-19, acute macular retinopathy, neuroretinopathy

## Introduction

Acute macular neuroretinopathy (AMN) is a rare disease causing transient or permanent vision loss. It is characterized by a wedge-shaped, dark-reddish intraretinal lesion pointing toward the fovea.<sup>1</sup> Although AMN's etiology is not understood, recent studies have suggested a microvascular origin, where ischemia causes depletion of the oxygen supply to the photoreceptors.<sup>2</sup> Studies using spectral-domain optical coherence tomography (SD-OCT) identified a relationship between AMN and ischemia in the retinal deep capillary plexus (DCP).<sup>3</sup>

The literature review reports an associated relationship between viral infections such as influenza and AMN.<sup>4</sup> There has been a notable surge in AMN cases adjunct to COVID-19 throughout the pandemic.<sup>5</sup> COVID-19 is known to cause an inflammatory response and vascular alteration.<sup>6</sup> Therefore, the currently theorized etiology suggests that the hypercoagulable state and vasculitis caused by COVID-19 create microthrombosis leading to an increased incidence of AMN.<sup>2,7</sup>

This case series details two cases of presumed unilateral and bilateral AMN in patients with mild COVID-19 infection and our observations.

## Case Report

Patient A was a 20-year-old Hispanic female who presented with worsening bilateral blurred vision and decreased visual acuity after an RT-PCR confirmed case of COVID a year prior. She had a history of uncontrolled type 1 diabetes with an H-A1C of 13 for which she is taking Lantus and Novolog.

Her best corrected visual acuity was 20/20 OD and 20/100 OS on presentation. She described asymmetry of light sensitivity, with subjective decrease in brightness of the transilluminator in her right eye (OD) compared to her left eye (OS). Red cap test also showed a subjective desaturation OD. On slit lamp examination, the ocular surface and anterior segment were unremarkable; no signs of diabetic retinopathy were noted in either eye and both maculae appeared normal in color and contour. Visual field (VF) 10–2 testing revealed mild scattered depressions bilaterally (OU) and a notable

temporal paracentral scotoma OS (Figure 1A and B). Macular optical coherence tomography (OCT); (Figure 2) showed slight disruption of nasal parafoveal outer photoreceptor segments and interdigitation zone OD and focal atrophy and excavation of nasal parafoveal outer photoreceptor segments and interdigitation zone OS. The focal atrophy and excavation of nasal parafoveal outer photoreceptor segments and interdigitation zone OS corresponded anatomically with her paracentral scotoma. Electroretinogram (ERG) testing was normal in both eye. Her visual evoked potentials (VEP) exhibited decreased amplitude OD and increased latency OS with high contrast test stimuli (Figure 3). These findings prompted radiologic testing was ordered to further evaluate for COVID-19 related microvascular and tissue irregularities along the visual pathway.

Patient B is a 60-year-old white male who presented with worsening left eye pain and blurred vision over the course of one month after having a confirmed RT-PCR case of COVID-19. He had a history of controlled DM-II and hypertension for which he was taking Exforge and Metformin.

On presentation, the patient's visual acuity was 20/20 OU and anterior segment were unremarkable OU. Dilated retinal examination showed early and non-significant epiretinal membrane (ERM) OU. Watzke-Allen testing was normal

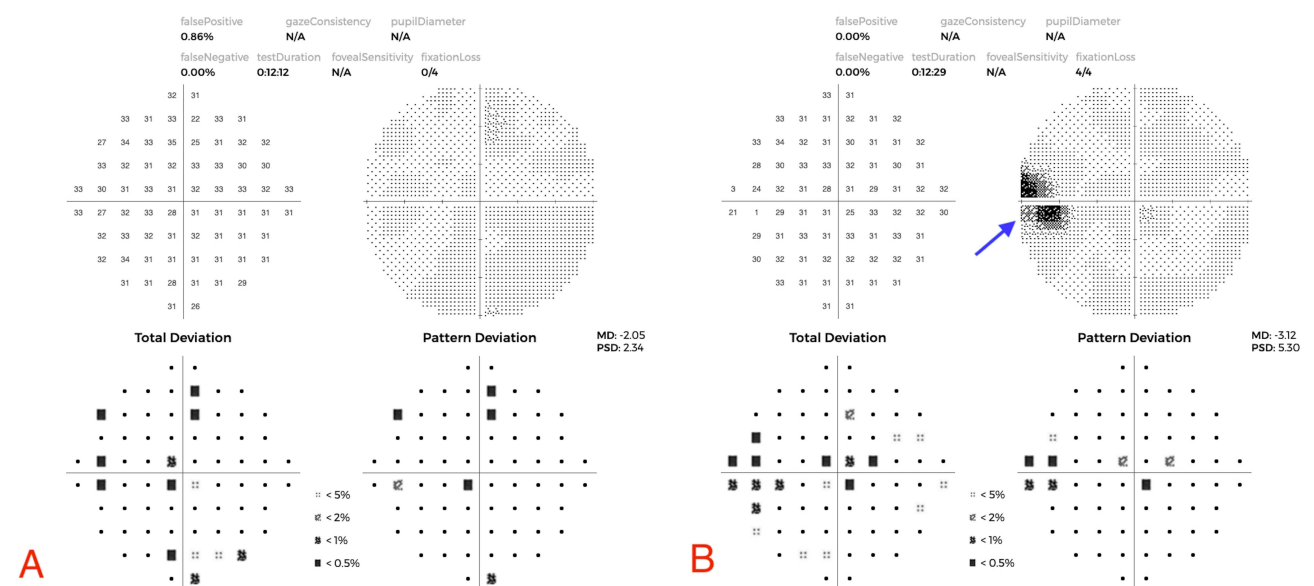


Figure 1 (A) 10-2 Visual field (VF): OD mild scattered VF depression. (B) 10-2 Visual field (VF): OS mild scattered VF depression and scotoma. Arrow pointing to a wedge-shaped scotoma.

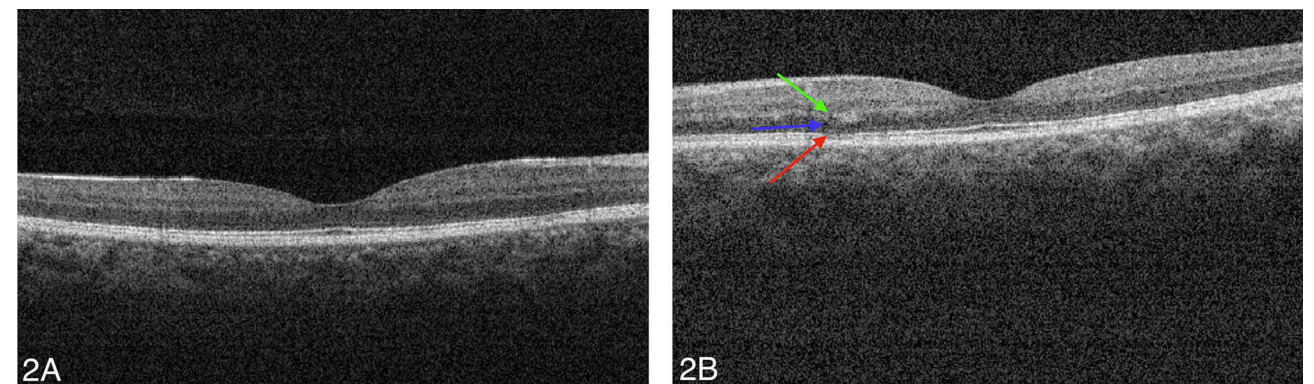
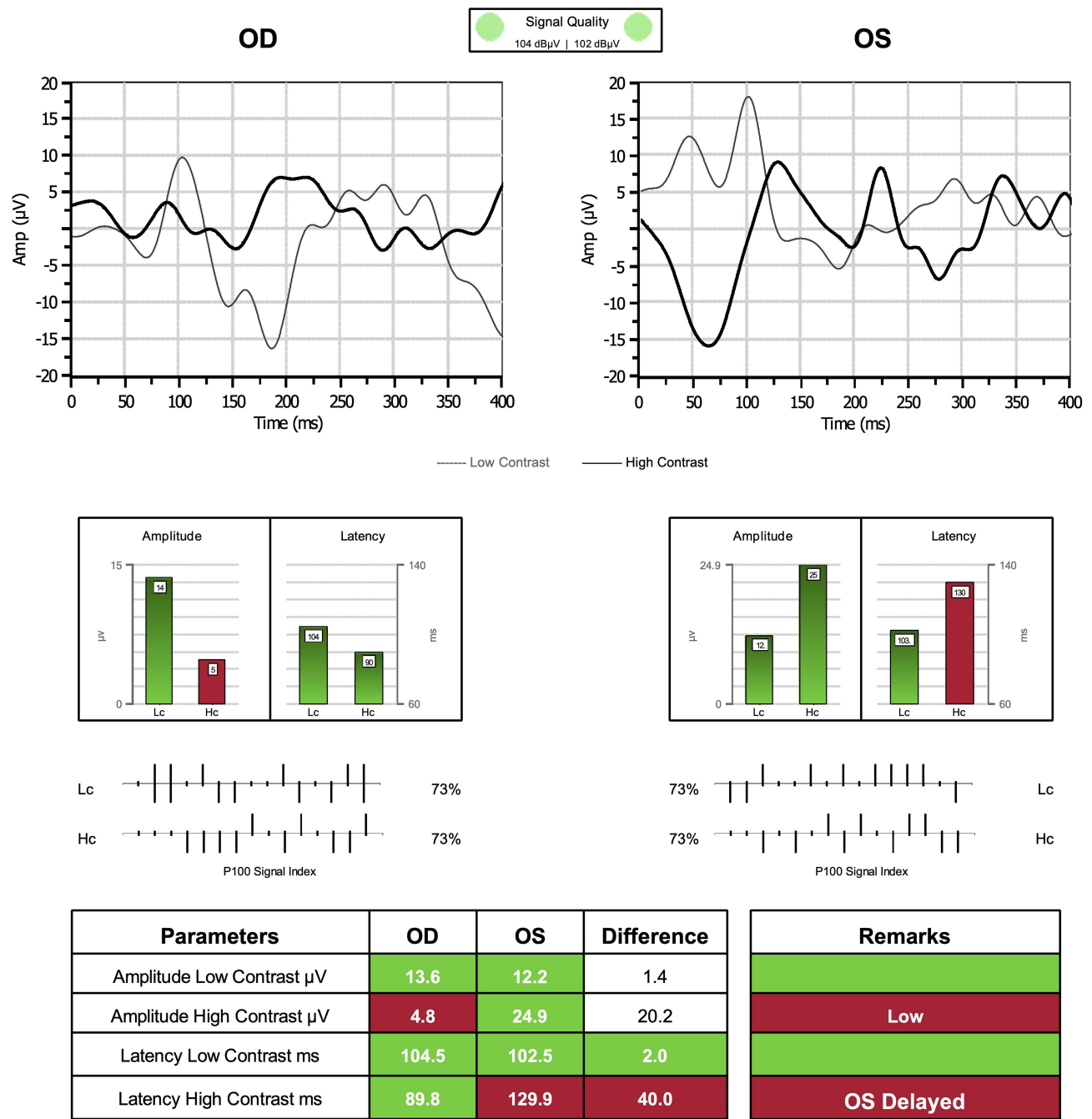


Figure 2 (A) Optical coherence tomography (OCT): OD slight disruption of nasal parafoveal outer photoreceptor segments and interdigitation zone. (B) Optical coherence tomography (OCT): OS focal atrophy and excavation of nasal parafoveal outer photoreceptor segments and interdigitation zone. Blue arrow: Outer nuclear layer; Red arrow: Photoreceptors; Green arrow: Outer plexiform layer.

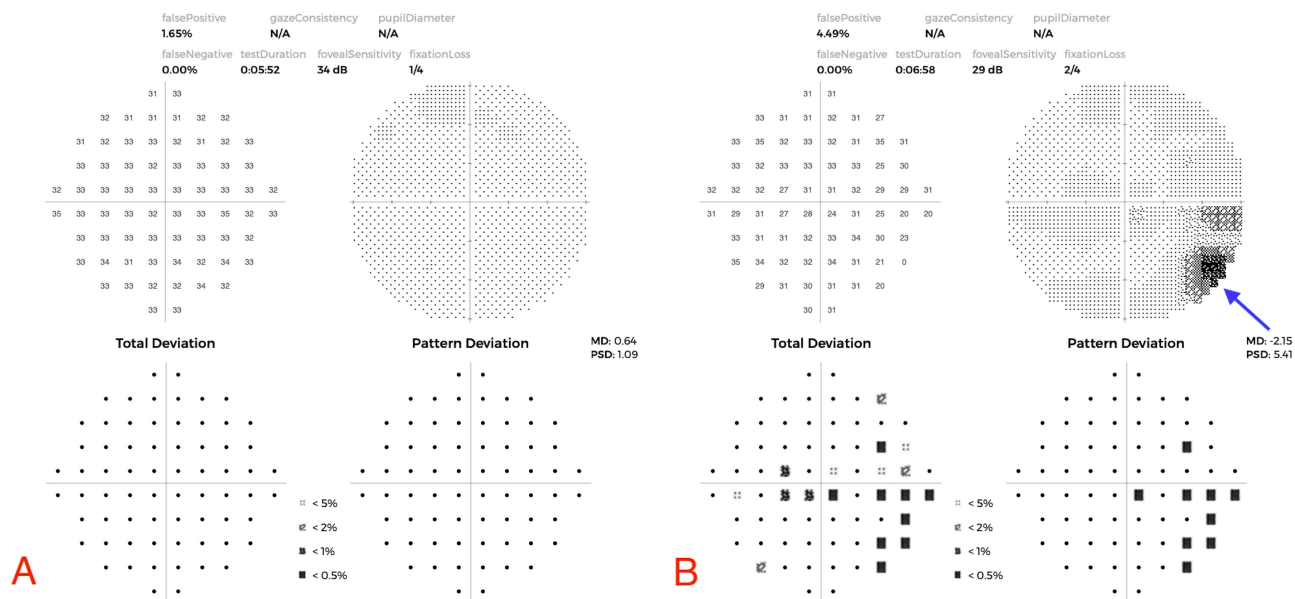


**Figure 3** Visual evoked potential: Decreased amplitude with high contrast test stimuli OD and increased latency of high contrast test stimuli OS. Red color cells outside normative ranges. Green cells are within normative ranges.

**Abbreviations:** LC, Low contrast; HC, High contrast.

OD but elicited a temporal scotoma OS. Visual field 10–2 (VF) testing showed bilateral mild scattered VF depression and temporal scotoma in the left eye (Figure 4A and B). Macular OCT imaging showed normal macular profile and contour with a subtle early ERM temporal OU. Upon further investigation a notable disruption of nasal paracentral photoreceptors with overlying atrophied outer nuclear layer was found OS (Figure 5B and C) and normal thickness in OD (Figure 5A).

At the patient’s 5 month follow up visit, the patient reported he still noticed the temporal wedge-shaped scotoma OS with little improvement in visual discomfort. The patient’s visual acuities were 20/16 OD and 20/20+ OS and anterior



**Figure 4 (A)** 10–2 Visual field (VF): OD mild scattered VF depression. **(B)** 10–2 Visual field (VF): OS mild scattered VF depression and temporal scotoma in the left eye. Arrow pointing to a wedge-shaped scotoma.

segment were unremarkable OU. Dilated retinal examination showed no changes to the retinae and maculae. Repeat OD OCT macular scans remains unchanged (Figure 5D) and OS showed minimally improved architecture of ellipsoid zone, photoreceptor outer segments and interdigitation zone (Figure 5E).

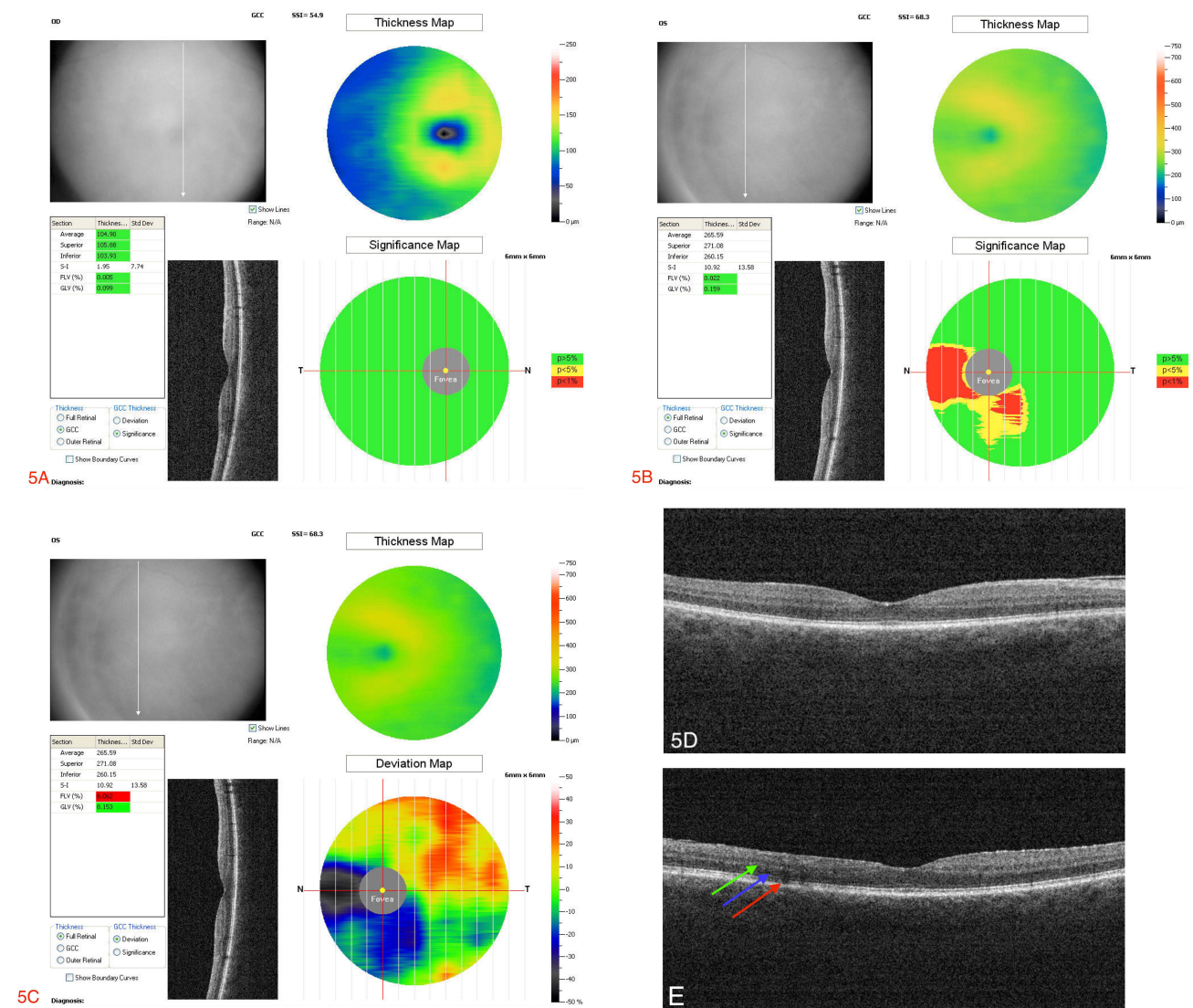
## Discussion

Acute macular neuroretinopathy (AMN) is a rare disease causing transient or permanent vision loss. Although rare, there has been a notable uprise in cases reported presumably to COVID-19 throughout the pandemic.<sup>5</sup> COVID-19 is known to cause a pro-inflammatory cascade resulting in vascular alteration.<sup>6</sup> Therefore, the currently theorized etiology suggests that the hypercoagulable state and vasculitis caused by COVID-19 create microthrombosis leading to an increased incidence of AMN further supporting the theorized microvascular etiology of AMN.<sup>2,7</sup>

Visual evoked potential (VEP) was used to primarily evaluate the visual pathway from the optic nerve to the occipital lobe. There are two parameter types that the VEP will check, one being the signal amplitude to both a high and low contrast stimulus and the other being the signal latency to both a high and low contrast stimulus. For the report in question, we can see the patients’ signal amplitude when tested with low contrast stimuli fall within normative data ranges, whereas when tested with high contrast stimuli the right eye shows a reduction in the signal amplitude. When evaluating the latency of the test results we can see that when tested with low contrast stimuli the patient’s result falls within normative ranges, but there is a notable and significant delay in the signal conduction of the left eye when tested with a high contrast stimulus. The delay in signal latency left eye may be secondary to dysfunction or injury of the visual pathway from the left optic nerve.

Being a relatively rare diagnosis prior to the pandemic, there is no official suggested course of treatment for AMN. In our practice with observation and moderate treatment, patients had mild improvement in visual acuity at follow-up. However, testing results show little improvement in visual and anatomical defects. This further suggests that although AMN is acute, the changes and damages caused by inflammation and ischemia may have long-lasting effects.

The challenge we faced was access to obtain OCT-A as our glaucoma practice is focused on serving the underserved and special needs population. However, our presumed diagnosis is plausible based on the clinical criteria and traditional presentation of AMN. AMN clinical presentation is a painless and acute vision loss with a classical wedge defect scotoma as seen in both cases. In contrast to optic neuritis, which typically is characterized as an acute loss in vision loss



**Figure 5 (A)** Optical coherence tomography (OCT) ganglion cell analysis: Normal macular profile OD. Significance mapping: Green is  $p > 5\%$ , yellow is  $p < 5\%$  and red is  $< 1\%$ . Thickness mapping: Blue 50 to ~ 80 microns, green  $> 80$  to ~180 microns, yellow  $> 180$  to  $< 175$  microns. **(B)** Optical coherence tomography (OCT) ganglion cell analysis: Atrophy of nasal papillary bundle OS. Significance mapping: Green is  $p > 5\%$ , yellow is  $p < 5\%$  and red is  $< 1\%$ . Thickness mapping: Blue 50 to ~ 80 microns, green  $> 80$  to ~180 microns, yellow  $> 180$  to  $< 175$  microns. **(C)** Optical coherence tomography (OCT) Full thickness analysis: Atrophy of nasal papillary bundle OS. Thickness mapping: Blue 50 to ~ 160 microns, green 200 to ~300 microns, yellow  $> 300$  to  $< 370$  microns. Deviation mapping: Red: ~25 to 40%, Orange: ~20 to 25%, yellow: -10 to 15%, green -5 to 5%, blue -25 to -15%, black and grey -30 to -50%. **(D)** Optical coherence tomography (OCT): OD 5 months follow up shows normal macular scan. **(E)** Optical coherence tomography (OCT): OS macular scan 5 months shows minimal improved architecture of ellipsoid zone, photoreceptor outer segments and interdigitation zone. Blue arrow: Outer nuclear layer; Red arrow: Photoreceptors; Green arrow: Outer plexiform layer.

with painful eye movement.<sup>8</sup> Of which our cases highlight that although rare and with limited access, a clinician can deduce a diagnosis of AMN.

## Literature Analysis

In October 2022, a PubMed and Google search was performed using key search terms such as “Acute Macular neuro retinopathy” and “COVID-19”. Three notable articles outline their experiences with AMN in patients who had COVID-19 or the COVID-19 vaccination.<sup>5,9,10</sup> Similar to these cases, our patients had similar findings on examination and testing as outlined in the literature. However, our patients presented with AMN after several weeks (patient A) or after multiple confirmed cases of COVID throughout the course of 2 years. Additionally, decreased visual acuity (VA) which is a rare complication during our review; both of our patients had decreased VA that took months to resolve post-COVID.<sup>9</sup>

## Conclusion

Acute macular neuroretinopathy is a rare diagnosis; however, with the changing landscape of the pandemic, it is quickly becoming more prevalent. We recognize that the limitation to our case series is the number of patients secondarily due to the rarity. Thus, efforts in reporting different clinical presentations are important to better understand the etiology of AMN and its natural history. Furthermore, the diagnosis of AMN should be considered and be at the forefront of clinicians. Careful and thorough history, testing, and consideration are key in the diagnosis of AMN.

## Patient Consent

Patient 1: The patient consented to publication of the case and has signed the consent form.

Patient 2: The patient consented to publication of the case and has signed the consent form.

## Publication

No institutional approval required.

## Funding

No funding or grant support.

## Disclosure

The following authors have no financial disclosures: T.V, M.S, S.M, W.S

## References

1. Bos PJM, Deutman AF. Acute Macular Neuroretinopathy. *Am J Ophthalmol.* 1975;80(4):573–584. doi:10.1016/0002-9394(75)90387-6
2. El-Asrar AM A, Herbort CP, Tabbara KF. Differential Diagnosis of Retinal Vasculitis. *Middle East Afr J Ophthalmol.* 2009;16(4):202–218. doi:10.4103/0974-9233.58423
3. Rahimy E, Sarraf D. Paracentral acute middle maculopathy spectral-domain optical coherence tomography feature of deep capillary ischemia. *Curr Opin Ophthalmol.* 2014;25(3):207. doi:10.1097/ICU.0000000000000045
4. Bhavsar KV, Lin S, Rahimy E, et al. Acute macular neuroretinopathy: a comprehensive review of the literature. *Surv Ophthalmol.* 2016;61(5):538–565. doi:10.1016/j.survophthal.2016.03.003
5. Jalink MB, Bronkhorst IHG. A sudden rise of patients with acute macular neuroretinopathy during the COVID-19 pandemic. *Case Rep Ophthalmol.* 2022;13:96–103. doi:10.1159/000522080
6. Hernandez M, González-Zamora J, Recalde S, et al. Evaluation of macular retinal vessels and histological changes in two cases of COVID-19. *Biomedicines.* 2021;9(11):1546. doi:10.3390/biomedicines9111546
7. Abou-Ismaïl MY, Diamond A, Kapoor S, Arafah Y, Nayak L. The hypercoagulable state in COVID-19: incidence, pathophysiology, and management. *Thromb Res.* 2020;194:101–115. doi:10.1016/j.thromres.2020.06.029
8. Abel A, McClelland C, Lee MS. Critical review: typical and atypical optic neuritis. *Surv Ophthalmol.* 2019;64(6):770–779. doi:10.1016/j.survophthal.2019.06.001
9. Dinh RH, Tsui E, Wieder MS, et al. Acute macular neuroretinopathy and coronavirus disease 2019. *Ophthalmol Retina.* 2023;7(2):198–200. doi:10.1016/j.oret.2022.09.005
10. Ahmed W, Suri A, Ahmed A. COVID-19 and acute macular neuroretinopathy – an underlying association? *Ann Med Surg.* 2022;78:103847. doi:10.1016/j.amsu.2022.103847

International Medical Case Reports Journal

Dovepress

Publish your work in this journal

The International Medical Case Reports Journal is an international, peer-reviewed open-access journal publishing original case reports from all medical specialties. Previously unpublished medical posters are also accepted relating to any area of clinical or preclinical science. Submissions should not normally exceed 2,000 words or 4 published pages including figures, diagrams and references. The manuscript management system is completely online and includes a very quick and fair peer-review system, which is all easy to use. Visit <http://www.dovepress.com/testimonials.php> to read real quotes from published authors.

Submit your manuscript here: <https://www.dovepress.com/international-medical-case-reports-journal-journal>