

# Aphallia: A Rare Congenital Anomaly in a Low-Resource Setting

Awet Ghebreberhan Mehretab<sup>1,\*</sup>, Nahom Daniel Berhe<sup>2,\*</sup>, Emnet Tekeste Fekadu<sup>3</sup>

<sup>1</sup>Department of Surgery, Adi Quala Hospital, Adi Quala, Eritrea; <sup>2</sup>Department of Internal Medicine, Mendefera Zonal Referral Hospital, Mendefera, Eritrea; <sup>3</sup>Department of Surgery, Barentu Military Hospital, Barentu, Eritrea

\*These authors contributed equally to this work

Correspondence: Awet Ghebreberhan Mehretab, Department of Surgery, Adi Quala Hospital, Main Street, P.O. Box 47, Adi Quala, Eritrea, Tel +291 7 283 515, Email awetgmg@gmail.com

**Abstract:** Aphallia is a very uncommon congenital condition with an incidence of about one in 30 million births. It is characterized by the absence of a penis which is due to the failure of the genital tubercle to form or develop fully. In this case report, we present a 3-month-old male infant with aphallia from a remote part of Eritrea who was subsequently lost to follow-up and discuss the challenges that are faced when dealing with such a complex congenital anomaly in a developing country. This report highlights the importance of having accessible healthcare services for early detection, appropriate management, and counseling of the affected individual and their families. Finally, healthcare providers should work together in the future to improve the quality of life of affected individuals and their families as the management of aphallia requires multidisciplinary collaboration and comprehensive care to reduce the potential long-term psychological and social consequences of the condition.

**Keywords:** aphallia, congenital absence of penis, penile agenesis, developing countries, Eritrea

## Introduction

Congenital malformations are structural or functional abnormalities that occur during fetal development. Congenital absence of the penis is an exceptionally rare genitourinary anomaly occurring in about one in 30 million births.<sup>1</sup> Imminger initially described the condition in 1853, and at this moment, less than 100 cases have been reported worldwide.<sup>2</sup>

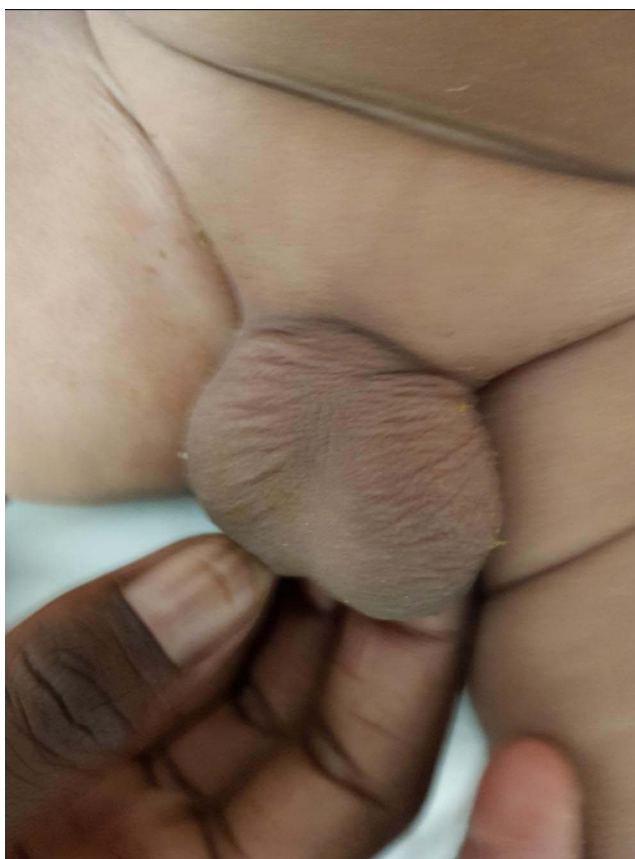
While congenital malformations affect populations worldwide, the burden is disproportionately higher in developing countries, particularly among low socioeconomic strata.<sup>3,4</sup> Having a complex congenital anomaly like aphallia in developing countries can have significant physical, psychological, and social consequences for affected individuals and their families.<sup>5</sup>

The management of aphallia among experts remains controversial, with differing opinions on the best approach. Historically, gender reassignment during childhood has been viewed as the best option but some experts now recommend decisions be made after discussions with the patient and family, considering socio-sexual future, genotype, and fertility.<sup>6,7</sup>

Developing countries lack the resources, infrastructure, and healthcare systems to effectively address and manage complex congenital anomalies like aphallia. In this case report, we will discuss the limitations in management and highlight the importance of having multidisciplinary collaboration, and proper counseling services in developing countries.

## Case

A 3-month-old male infant came referred to our hospital with complaints of an absent phallus. The infant was born at home to a 35-year-old multigravida mother who had an unsupervised antenatal period. The mother and her family live in a remote area with limited access to healthcare services and no transportation services. The mother had to travel 5 hours on foot to reach the nearest health center, where the infant was evaluated first and was subsequently referred to our hospital. The infant was born of a non-consanguineous marriage and there was no family history of any congenital anomalies. No history of ingestion of drugs or any known teratogens.



**Figure 1** Photograph illustrating aphallia with a normal scrotum.

Physical examination showed a well-developed infant with a body weight of 6kg. There was a complete absence of the penis with a well-formed scrotum and bilaterally descended testes. The anal opening was located normally, but the urethral opening was not visible anywhere in the perineum (Figure 1). The rest of the general and systemic physical examination was normal.

At the time of evaluation ultrasonography of the abdomen showed normal-sized kidneys with no hydronephrosis. The renal function tests were within normal limits for his age with a creatinine of 0.3mg/dl and BUN of 8mg/dl. The serum electrolytes were; K<sup>+</sup>: 5.5mEq/l, Na<sup>+</sup>: 138mEq/l, Ca<sup>2+</sup>: 9.2 mg/dl, and Cl<sup>-</sup>: 9.2mEq/l. The mother was counseled about the condition and referred to a tertiary hospital, but she took the child home without visiting the referral hospital. We, the authors tried our best to find the child by making multiple telephone calls with the administrators of the village and the local clinic but the child could not be found. We even send a healthcare professional to the village as part of an EPI outreach program but the child could not be found.

## Discussion

Aphallia is a very rare congenital anomaly that is characterized by the absence of a penis. External genital differentiation into the male sex starts in the 7th week of gestation and is completed by 16–17 weeks.<sup>8–10</sup> The pathogenesis of aphallia is unknown but it's thought to be due to failure of the genital tubercle to form or to develop fully during this time.<sup>11</sup>

The diagnosis of aphallia is usually made in the absence of the phallus, male karyotype, and normally developed scrotum with normal testicles. The differential diagnosis of aphallia include micropenis, rudimentary penis, penile amputation, concealed penis, and male pseudohermaphroditism.<sup>12</sup> In our case, the karyotyping could not be performed because we did not have the laboratory tests and the patient became lost to follow-up.

The management of aphallia involves a multidisciplinary approach that includes counseling, hormonal therapy, and surgical interventions such as phalloplasty or gender reassignment surgery. In the past, female sex assignments were

common due to their ease and cosmetic benefits, but in recent years, there has been a shift in gender reconstruction for aphallia.<sup>6</sup> Now expert's decision in choosing gender reconstruction must go through discussions with the patient and his/her family while still taking into account the socio-sexual future and the patient's fertility.<sup>7</sup> In this case, the parents decided to rear the child as a boy.

The management of congenital anomalies such as aphallia can be especially difficult in low-resource settings because of limited access to health care services, diagnostic tests, and surgical intervention. In addition, the healthcare facilities are usually located far from those affected communities which makes it more difficult for them considering their financial problems. In our case, the infant's parents lived in a remote area and were unable to bring him to the hospital until he became 03 months old and was subsequently lost to follow-up. This is an example of a missed opportunity to learn more about an anomaly with a very low incidence. Some possible solutions are having high-quality counseling, proper follow-up, and the establishment of international specialized referral centers where patients with rare congenital anomalies could be managed in collaboration with the local hospitals. In addition, as shown in previous studies the parents are likely to hide the child at home or become lost to follow-up as the parents and family consider this a stigma and usually cannot decide on the treatment options offered to the child.<sup>5</sup>

Finally, this case report underscores the importance of working together in a Multidisciplinary fashion to address rare congenital malformations like aphallia and improve the outcomes for affected individuals globally.

## Conclusion

Aphallia is a rare congenital anomaly that requires a multidisciplinary management approach for optimal outcomes. In addition to the physical abnormality, it can have significant psychological consequences for the affected individuals. Therefore, active cooperation between doctors and parents is paramount to decrease the negative impact of this malformation. In low-resource settings, there are many challenges to managing such patients, including limited access to healthcare services, financial limitations, and social stigma. In addition, diagnostic modalities like karyotyping and advanced imaging studies are difficult to perform. Despite these challenges, healthcare workers must provide the needed counseling, referral, and management choices for people affected by aphallia to improve their quality of life.

## Consent

A signed written informed consent was obtained from the mother at the time of the examination for the case details and images to be published. The institutional research ethics review committee of the Ministry of Health of Eritrea, has informed that the approval for this case report is not required.

## Disclosure

The authors report no conflicts of interest in this.

## References

1. Kessler WO, McLaughlin AP. Agenesis of penis. Embryology and management. *Urology*. 1973;1:226–229. doi:10.1016/0090-4295(73)90741-3
2. Rattan KN, Kajal P, Pathak M, et al. Aphallia: experience with 3 cases. *J Pediatr Surg*. 2010;45:e13–6. doi:10.1016/j.jpedsurg.2009.10.057
3. DeSilva M, Munoz FM, Mcmillan M, et al. Congenital anomalies: case definition and guidelines for data collection, analysis, and presentation of immunization safety data. *Vaccine*. 2016;34:6015–6026. doi:10.1016/j.vaccine.2016.03.047
4. Centers for Disease Control and Prevention. Congenital anomalies - definitions; 2020. Available from: <https://www.cdc.gov/ncbddd/birthdefects/surveillancemanual/chapters/chapter1-4.html>. Accessed July 21, 2023.
5. Downing KF, Oster ME, Klewer SE, et al. Disability among young adults with congenital heart defects: congenital heart survey to recognize outcomes, needs, and well-being 2016–2019. *J Am Heart Assoc*. 2021;10:e022440. doi:10.1161/JAHA.121.022440
6. Demirer Z, Aip BF, Uguz S, Guragac A, Irkilata HC. A rare case of penis agenesis (Aphallia) with associated multiple urogenital anomalies. *Int J Surg Case Rep*. 2015;15:10–12. doi:10.1016/j.ijscr.2015.08.004
7. Kumar A, Faiz N. Aphallia: case report and review of the literature. *Saudi Surg J*. 2015;3(1):13. doi:10.4103/2320-3846.15380
8. Belman A, King L. Urethra. In: Kelalis P, King L, Belman A, editors. *Clinical Pediatric Urology*. Vol. 1. Philadelphia: WB Saunders; 1976:577.
9. Moore K, Persaud T. *Before We are Born: Essentials of Embryology and Birth Defects*. Philadelphia: WB Saunders; 1998.
10. Baskin L. Hypospadias and urethral development. *J Urol*. 2000;163:951–956. doi:10.1016/S0022-5347(05)67861-5
11. Joshi A, Gross J, Thomalla JV. Congenital aphallia: review of pathogenesis and current treatment guidelines. *Urology*. 2015;86(2):384–387. doi:10.1016/j.urology.2015.04.031
12. Sathaye S, Sathaye U. Isolated aphallia: a case report and review of literature. *Afr J Urol*. 2023;29:9. doi:10.1186/s12301-023-00339-5

**International Medical Case Reports Journal**

Dovepress

**Publish your work in this journal**

The International Medical Case Reports Journal is an international, peer-reviewed open-access journal publishing original case reports from all medical specialties. Previously unpublished medical posters are also accepted relating to any area of clinical or preclinical science. Submissions should not normally exceed 2,000 words or 4 published pages including figures, diagrams and references. The manuscript management system is completely online and includes a very quick and fair peer-review system, which is all easy to use. Visit <http://www.dovepress.com/testimonials.php> to read real quotes from published authors.

Submit your manuscript here: <https://www.dovepress.com/international-medical-case-reports-journal-journal>