




Spring-Powered Needle-Free Injection of Triamcinolone Acetonide and 5-Fluorouracil for Keloid Treatment

Eva Krishna Sutedja , Annisa Sundani, Kartika Ruchiatan , Endang Sutedja 

Department of Dermatology and Venereology, Faculty of Medicine, Universitas Padjadjaran - Dr. Hasan Sadikin Hospital, Bandung, West Java, Indonesia

Correspondence: Eva Krishna Sutedja, Department of Dermatology and Venereology, Faculty of Medicine, Universitas Padjadjaran - Dr. Hasan Sadikin Hospital, Jl. Pasteur 38, Bandung, West Java, 40161, Indonesia, Tel/Fax +62 222032426 ext 3449, Email evakrishna@yahoo.com

Introduction: Keloid is an abnormal fibroproliferative healing response characterized by excessive and invasive tissue growth beyond the wound boundaries. The conventional treatment involves injecting drugs such as triamcinolone acetonide (TA), 5-fluorouracil (5-FU), or their combination intralesionally. However, the pain associated with injections often leads to low patient compliance and treatment failure. The spring-powered needle-free injector (NFI) provides an affordable alternative option for drug delivery with reduced pain.

Case: This case report presents a 69-year-old female patient with a keloid treated using a spring-powered needle-free injector (NFI) for drug delivery. The keloid was assessed using the Vancouver Scar Scale (VSS) and the Patient and Observer Scar Assessment Scale (POSAS). The patient's pain level was measured using the Numeric Pain Rating Scale (NPRS). TA and 5-FU mixed with lidocaine were loaded into the NFI and injected at a dose of 0.1 mL/cm². The treatment was repeated twice a week. After four sessions, the keloid flattened by 0.5 cm, VSS score decreased from 11 to 10, and POSAS scores decreased from 49 to 43 (observer) and from 50 to 37 (patient). The NPRS during each procedure was 1, indicating minimal pain.

Discussion: The spring-powered NFI is a simple and cost-effective device that operates based on Hooke's law, producing a high-pressure fluid jet for effective skin penetration. The NFI demonstrated effectiveness in treating keloid lesions, resulting in visible improvement after four treatments.

Conclusion: The spring-powered NFI offers an affordable and painless alternative to keloid treatment.

Keywords: 5-fluorouracil, keloid treatment, needle-free injection, spring-powered, triamcinolone acetonide

Introduction

Keloid is an abnormal fibroproliferative healing response that causes excessive and invasive tissue growth beyond the original boundaries of the wound.¹ This condition affects patient's quality of life, physical status, and psychological wellness.² Despite the numerous treatment options available, keloid treatment remains a challenge for healthcare professionals due to the high recurrence rates.^{3,4} Intralesional drug injection, either with 5-fluorouracil (5-FU), triamcinolone acetonide (TA), or combination of both, are the commonly used treatment for keloid.⁵ However, this procedure can be excruciating and may negatively affect patient compliance leading to the failure of treatment.⁶ As such, there is a need for the development of more effective, tolerable, and patient-friendly treatment options for keloid.

Needle-free injector (NFI) is a drug delivery device that uses one of several forces such as Lorentz force, shock wave, gas pressure, electrophoresis, or through mechanical spring compression to push the drug into the skin without the use of a needle.^{7,8} Among these methods, the spring-powered NFI stands out as the simplest and most cost-effective option, as it operates according to Hooke's law, which governs the relationship between the applied force and the resulting displacement of the spring.⁷ From an engineering standpoint, this method is relatively affordable as it does not require any electrical power or electronic components.⁹

Several studies have shown that steroid injections administered with NFI for hypertrophic wounds and keloids can reduce the thickness of the scars with less pain.^{5,10,11} To date, there have been few case reports on keloid treatment using the NFI method. However, no keloids specifically treated by spring-powered NFI with a combination of TA and 5-FU have been reported. In this report, we present a successful case of keloid treatment using the spring-powered NFI with a combination of 5-FU and TA. This approach offers improved patient compliance and success rates due to its minimal discomfort during the procedure.

Case Report

A 69-year-old female presented to our Dermatology and Venereology Clinic with a significant complaint of extensive scar tissue on her back. According to the patient, the scar tissue was first noticed 18 years ago when it was the size of a peanut. After a year of injection therapy with a local physician, there was some improvement in the thickness of the lesion. However, the patient noticed that the scar tissue regrew and increased in size. Despite further injection therapies, the lesion continued to grow over time. Two weeks before her consultation, the patient reported the itch worsened, prompting her to seek medical care at our clinic.

During the physical examination, we observed several keloidal lesions on both the left and right scapula, with the largest lesion measured $8.5 \times 5.5 \times 1$ cm (Figure 1). To assess the patient's scarring we used the Vancouver scar scale (VSS) and the patient and observer scar assessment scale (POSAS). The initial VSS score was 11 and POSAS for observer component score was 49, with patient component score was 50. During procedure, patient is required to scale the pain of injection with numeric pain rating scale (NPRS).

We treated the lesions with a combination of TA (40 mg/mL) and 5-FU (50 mg/mL) intralesional injection using NFI (Thesera®) at a dose of 0.1 mL/cm^2 (Figure 2). The injection site was marked with 1 cm^2 squares. The NFI injector body was set at 10, and a mixture of 0.5 mL TA (40 mg/mL), 4 mL 5-FU (50 mg/mL), and 0.5 mL 2% lidocaine was inserted into the head ampule for approximately 0.1 mL. The nozzle was pressed against the lesion, and the tip of the NFI was pressed until the mixture solution was discharged. This process was repeated until all the marked areas were covered. This procedure was repeated twice a week. Patient scaled NPRS as 1 for every procedure.

Over a period of 68 days, the procedure was repeated four times. Throughout this time, there was a noticeable improvement in the lesion, as it began to flatten for 0.5 cm (Figure 3). In addition, VSS score decreased to 10, while the POSAS score decreased to 43 for the observer component and 37 for the patient component. The patient was also reported that the current procedure was less painful compared to the prior technique with conventional intralesional injection.

Discussion

Keloids are a skin condition where scar tissue develops and extends beyond the boundaries of the original wound in a finger-like projection. In contrast to hypertrophic scars, which are confined to the area of the injury, keloids can grow uncontrollably.¹² The incidence of keloids varies, ranging from 0.09% to 16%. The development of keloids can be influenced by both genetic and environmental factors.¹³ A recent study in 2021 by Oei et al¹⁴ reported 44 cases of keloids, with a higher prevalence among women (58.8%). Notably, the majority of patients (63.6%) did not have a family history of keloids. Patients with Fitzpatrick skin types III to IV are more prone to developing keloids.¹²

The primary goal of keloid therapy is to prevent functional and cosmetic impairment.¹⁵ Intralesional corticosteroid injections are a common treatment for keloids. It can soften and flatten lesions by reducing fibroblast proliferation, collagen synthesis, glycosaminoglycan synthesis, and suppressing proinflammatory mediators.^{16,17} Among the corticosteroids, TA is the most used corticosteroid for this purpose.¹² However, in cases where patients do not respond to corticosteroid treatment, 5-FU is preferred. 5-FU inhibits fibroblast proliferation, prevents DNA and RNA synthesis, and suppresses type-1 collagen expression in fibroblasts stimulated by TGF- β .^{18,19} In a 2014 study by Khan et al,²⁰ 150 keloid patients were treated with either TA monotherapy or a combination of TA and 5-FU. The combination group had a higher success rate, with improvements observed in 84% of patients, compared to 68% of patients in the monotherapy group. However, although the combination of TA and 5-FU for treating keloid is widely recognized, there is no consensus on the appropriate ratio of the two compounds.^{20,21} In this study, we followed the mixture proposed by

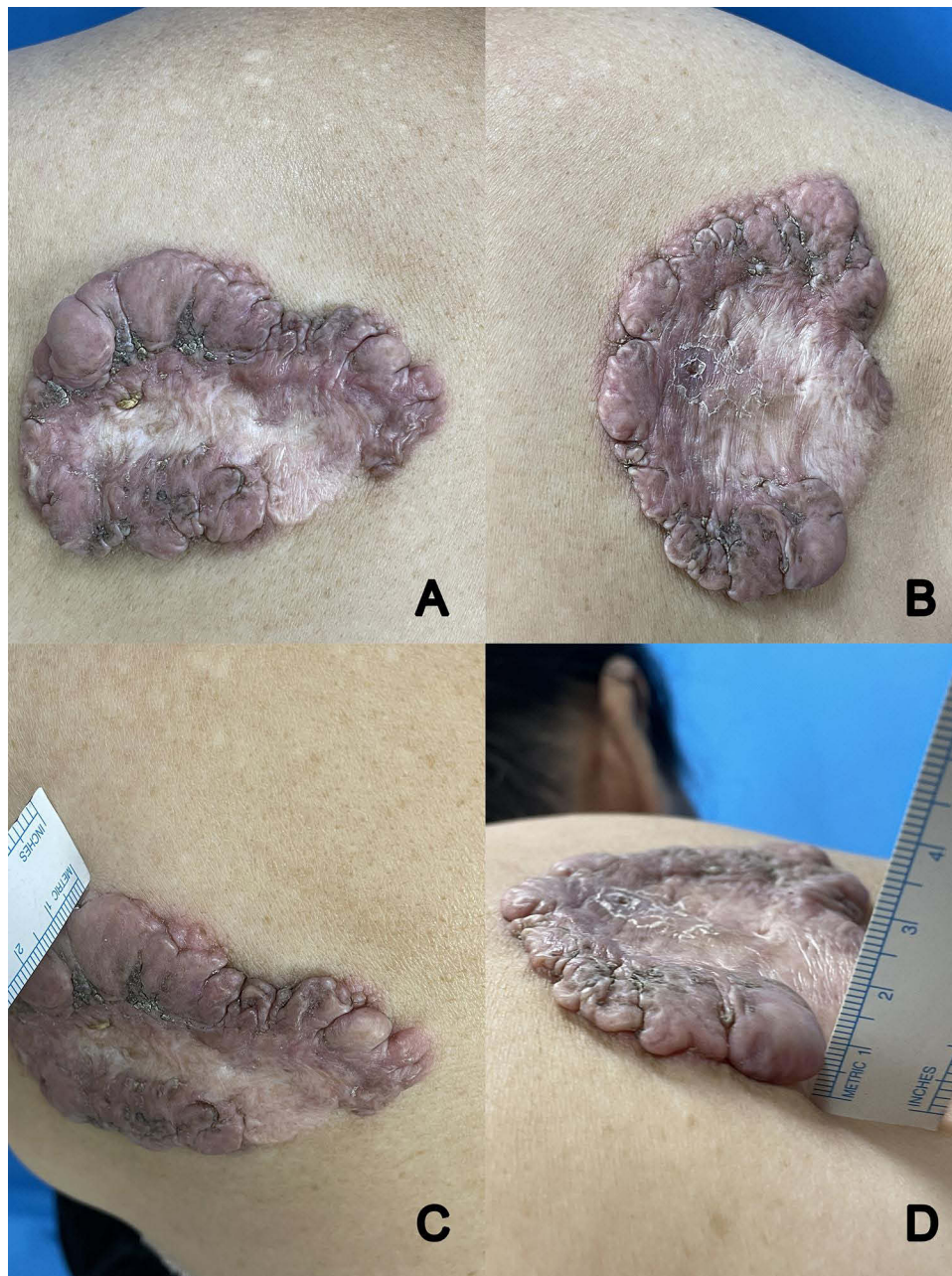


Figure 1 Lesion before treatment (A–C). Notice the thickness of the lesion is 1 cm (D).

Levenberg et al,⁵ which involved the combination of 0.5 mL of TA (40 mg/mL) and 4 mL of 5-FU (50 mg/mL). Additionally, 0.5% lidocaine 2% was added into the combination to achieve analgesia effect.⁵

Intralesional injection is typically performed manually using a syringe, but this method can cause discomfort and requires an experienced person to apply sufficient pressure for the drug to effectively infiltrate the keloid. Non-uniform distribution can result in uneven depth, surface atrophy, telangiectasia, and recurrence rates of up to 50%.²² Controlled fluid pressure, however, enables deep and uniform penetration throughout the thickness of the wound.²³ Another option is pressure-controlled jet injection, which has been shown to be effective in a study by Levenberg et al⁵ on 21 keloid patients, resulting in a 53% reduction in VSS score, a 79% reduction in itching, and a decrease in the color, stiffness, thickness, and irregularity components of POSAS.

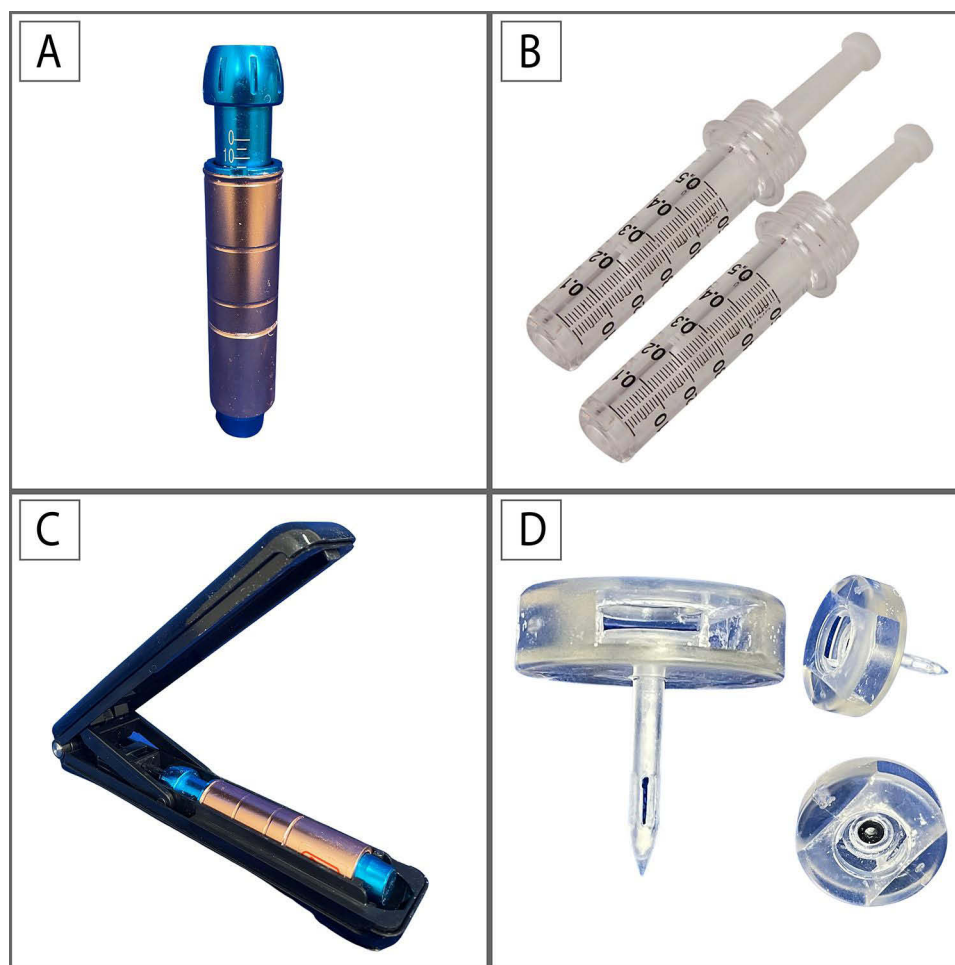

Figure 2 Spring-powered NFI device. Injector body (A). Nozzle (B) drug delivery disposable sterile medication cartridge. Reset box (C) for charging the injector. Adapter (D) for filling nozzle from vial.

Needle-free injector is a device that can deliver medication at high speeds without a needle.¹¹ These devices use a high-velocity jet to puncture the skin surface and deliver drugs to the required depth without using a needle.⁷ NFIs are classified based on their mode of operation (spring-powered, laser power, and energy-propelled systems), the type of material to be injected (liquid, powder, or projectile), drug delivery mechanisms, and target location (intra-dermal, intramuscular, or subcutaneous).⁸ The high speed of the fluid stream significantly reduces skin propagation momentum and ultimately decreases dermal pain receptor activation.⁵ A conventional NFI comprises a dose chamber with three major components: (a) an injection chamber having sufficient mechanical strength to hold the drug to be injected under pressure, (b) a nozzle with an orifice diameter of 50–360 μm (~150 μm) and (c) a pressure source for energizing the injecting drug to form high-velocity microjets (typical velocity higher than 100 m/s).⁷

The spring-powered NFI is the easiest and simplest device among the others. This device works according to Hooke's law, which states that the force is proportional to the spring displacement.²⁴ In this system, the energy stored during the mechanical compression of a spring is used to accelerate the driving piston (Figure 4). By adjusting the piston friction and the spring compression, the velocity range of the propelled microjet can be controlled (usually in the range 80–200 m/s).⁷ Its simplicity in the engineering point of view leads to cheaper manufacturing cost, thus it is more affordable compared to the other NFI. As for the clinical point of view, the spring-powered NFI is easy to handle and applicable virtually to all liquid formulation.⁹ NFIs can be used in several skin disorders such as depressed scars, hypertrophic scars, wrinkles, anesthesia, alopecia areata, condyloma acuminata, basal cell carcinoma, and keloids.¹¹ However, clinicians must also be aware of the potential adverse effects of NFI use, such as the formation of blebs or epidermoid cysts. As of

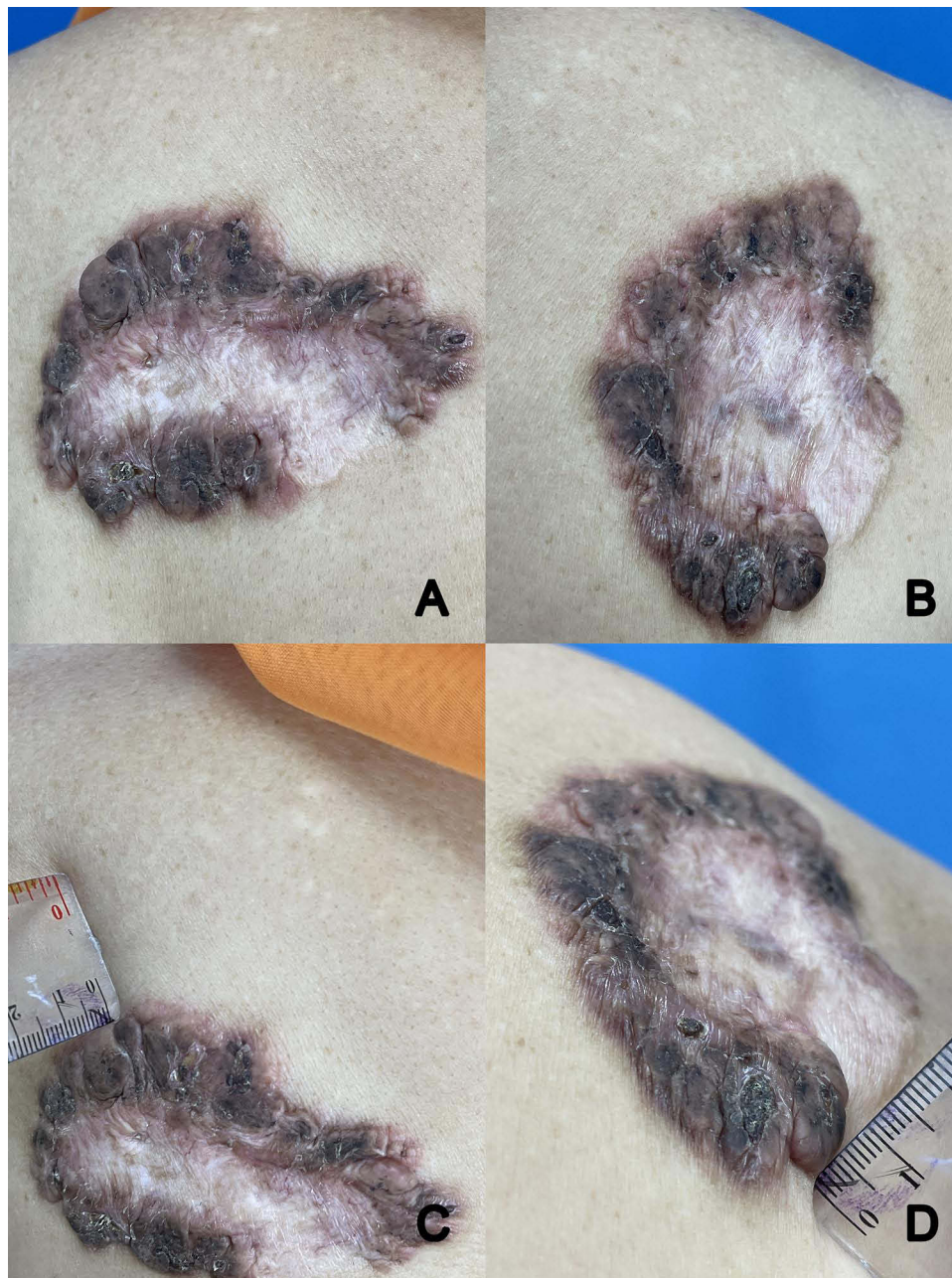


Figure 3 Lesion after 4 sessions (A–C). The thickness had been decreased to 0.5 cm (D).

the writing of this case report, there are no guidelines available regarding the parameters used for various clinical conditions.⁷

The use of NFI in treating keloid has been observed in a few studies. Saray et al²⁵ reported that the use of bleomycin with air-powered jet injector yielded 73.3% complete flattening of keloid lesions. Levenberg et al⁵ reported the use of jet volumetric remodeling technology to deliver TA and 5-FU for keloid in 39 keloid lesions. There was a significant improvement in VSS (53%), pain (69%), and pruritus (79%). In this study, we used the spring-powered NFI for the procedure. The pain experienced during the procedure was relatively tolerable, as indicated by NPRS score 1 for each procedure. The effectiveness of the treatment was demonstrated by the VSS score decreasing from 11 to 10. Additionally, the POSAS score for the observer component decreased from 49 to 43, and for the patient component, it decreased from 50 to 37. Notably, the itching, thickness, and irregularity components showed significant improvement.

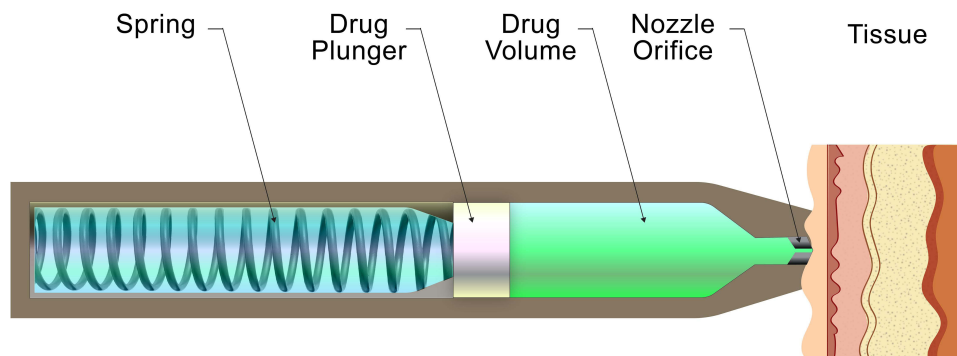


Figure 4 Schematic illustration of spring-powered needle-free injector.

Conclusion

The use of spring-powered NFI with a combination of TA and 5-FU is found to be effective to treat keloid. The spring-powered NFI has the potential to become a viable and affordable alternative to traditional needle-based treatments for keloids.

Ethical Statement

The publication of images was included in the patient's consent for publication of the case. The case report has been approved by the institutional ethics committee of Dr. Hasan Sadikin Hospital, Bandung, Indonesia (Ethical clearance no: LB.02.01/X.6.5/138/2023).

Consent Statement

The authors certify that they have obtained all appropriate patient consent forms. The patient signed a consent form for the publication of the case details and images.

Acknowledgments

The authors would like to thank Department of Dermatology and Venereology, Faculty of Medicine, Universitas Padjadjaran – Dr. Hasan Sadikin Hospital, Bandung, for providing meeting, editorial, and general administrative support.

Disclosure

The authors report no conflicts of interest in this work.

References

1. Limandjaja GC, Niessen FB, Scheper RJ, Gibbs S. The keloid disorder: heterogeneity, histopathology, mechanisms and models. *Front Cell Dev Biol.* 2020;8:360. doi:10.3389/fcell.2020.00360
2. Barone N, Safran T, Vorstenbosch J, Davison PG, Cugno S, Murphy AM. Current advances in hypertrophic scar and keloid management. Paper presented at: Seminars in Plastic Surgery; 2021.
3. Finnon KW, McLean S, Di Guglielmo GM, Philip A. Dynamics of transforming growth factor beta signaling in wound healing and scarring. *Adv Wound Care.* 2013;2(5):195–214. doi:10.1089/wound.2013.0429
4. Shih B, Garside E, McGrouther DA, Bayat A. Molecular dissection of abnormal wound healing processes resulting in keloid disease. *Wound Repair Regen.* 2010;18(2):139–153. doi:10.1111/j.1524-475X.2009.00553.x
5. Levenberg A, Vinshtok Y, Artzi O. Potentials for implementing pressure-controlled jet injection in management of keloids with intralesional 5FU and corticosteroids. *J Cosmet Dermatol.* 2020;19(8):1966–1972. doi:10.1111/jocd.13522
6. Slemp AE, Kirschner RE. Keloids and scars: a review of keloids and scars, their pathogenesis, risk factors, and management. *Curr Opin Pediatr.* 2006;18(4):396–402. doi:10.1097/01.mop.0000236389.41462.ef
7. Mohizin A, Kim JK. Current engineering and clinical aspects of needle-free injectors: a review. *J Mech Sci.* 2018;32:5737–5747.
8. Ravi AD, Sadhna D, Nagpaal D, Chawla L. Needle free injection technology: a complete insight. *Int J Pharm Inv.* 2015;5(4):192. doi:10.4103/2230-973X.167662
9. Schramm-Baxter J, Mitragotri S. Needle-free jet injections: dependence of jet penetration and dispersion in the skin on jet power. *J Control Release.* 2004;97(3):527–535. doi:10.1016/j.jconrel.2004.04.006

10. Alshehri A, Wahdan W, Maamoun MJ. Comparative study between intralesional steroid injection and silicone sheet versus silicone sheet alone in the treatment of pathologic scars. *Arch Balkan Med Union*. 2015;50:364–366.
11. Han HS, Hong JY, Kwon TR, et al. Mechanism and clinical applications of needle-free injectors in dermatology: literature review. *J Cosmet Dermatol*. 2021;20(12):3793–3801. doi:10.1111/jocd.14047
12. Smith N, Cha K, Bichakjian C, et al. Perioperative considerations in dermatology surgery. In: Kang S, Amagai M, Buckner AL, editors. *Fitzpatrick's Dermatology*, 9th ed. New York: McGraw-Hill; 2019:3723–3724.
13. Huang C, Wu Z, Du Y, Ogawa R. The epidemiology of keloids. In: Teot L, Mustoe T, Middelkoop E, Gauglitz G, editors. *Textbook on Scar Management*. Switzerland: Springer; 2020:30–34.
14. Oei F, Putra IB, Jusuf NK. The relationship between skin color and keloid. *Bali Med J*. 2021;10(2):835–838. doi:10.15562/bmj.v10i2.2619
15. Vivas AC, Tang JC, Maderal AD, Viera MH. Reviews-hypertrophic scars and keloids, part 1: conventional treatments. *J Cosmet Dermatol*. 2012;25(7):309.
16. Ekstein SF, Wyles SP, Moran SL, Meves A. Keloids: a review of therapeutic management. *Int J Dermatol*. 2021;60(6):661–671. doi:10.1111/ijd.15159
17. Pratchyapruit W, Vashrangsi N. A new therapeutic modality intralesional 5-fluorouracil in the treatment of keloids and hypertrophic scar. *Inst Dermatol Asses*. 2012;13(9):157–163.
18. Sharma S, Bassi R, Gupta A. Treatment of small keloids with intralesional 5-fluorouracil alone vs. intralesional triamcinolone acetonide with 5-fluorouracil. *J Pak Assoc Dermatol*. 2012;22(1):35–40.
19. Wolfram D, Tzankov A, Pülzl P, Piza-Katzer H. Hypertrophic scars and keloids—a review of their pathophysiology, risk factors, and therapeutic management. *Dermatol Surg*. 2009;35(2):171–181. doi:10.1111/j.1524-4725.2008.34406.x
20. Khan MA, Bashir MM, Khan FA. Intralesional triamcinolone alone and in combination with 5-fluorouracil for the treatment of keloid and hypertrophic scars. *J Pak Med Assoc*. 2014;64(9):1003–1007.
21. Gauglitz GG, Korting HC, Pavicic T, Ruzicka T, Jeschke MG. Hypertrophic scarring and keloids: pathomechanisms and current and emerging treatment strategies. *Mol Med*. 2011;17(1):113–125. doi:10.2119/molmed.2009.00153
22. Perdanasari AT, Lazzeri D, Su W, et al. Recent developments in the use of intralesional injections keloid treatment. *Arc Plast Surg*. 2014;41(06):620–629. doi:10.5999/aps.2014.41.6.620
23. Mashiko T, Abo Y, Kuno S, Yoshimura K. A novel facial rejuvenation treatment using pneumatic injection of non-cross-linked hyaluronic acid and hypertonic glucose solution. *Dermatol Surg*. 2015;41(6):755–758. doi:10.1097/DSS.0000000000000359
24. Baker AB, Sanders JE. Fluid mechanics analysis of a spring-loaded jet injector. *IEEE Trans Biomed Eng*. 1999;46(2):235–242. doi:10.1109/10.740886
25. Saray Y, Güleç AT. Treatment of keloids and hypertrophic scars with dermojet injections of bleomycin: a preliminary study. *Int J Dermatol*. 2005;44(9):777–784. doi:10.1111/j.1365-4632.2005.02633.x

Clinical, Cosmetic and Investigational Dermatology

Dovepress

Publish your work in this journal

Clinical, Cosmetic and Investigational Dermatology is an international, peer-reviewed, open access, online journal that focuses on the latest clinical and experimental research in all aspects of skin disease and cosmetic interventions. This journal is indexed on CAS. The manuscript management system is completely online and includes a very quick and fair peer-review system, which is all easy to use. Visit <http://www.dovepress.com/testimonials.php> to read real quotes from published authors.

Submit your manuscript here: <https://www.dovepress.com/clinical-cosmetic-and-investigational-dermatology-journal>