

# Toxic Epidermal Necrolysis Associated with Misoprostol: A Case Report

Okbu Frezgi <sup>1</sup>, Mulugeta Russom <sup>2-4</sup>

<sup>1</sup>Gynecology and Obstetric Unit, Orotta College of Medicine and Health Sciences, Asmara, Eritrea; <sup>2</sup>Eritrean Pharmacovigilance Centre, National Medicines and Food Administration, Ministry of Health, Asmara, Eritrea; <sup>3</sup>Department of Medical Informatics, Erasmus Medical Centre, Rotterdam, the Netherlands; <sup>4</sup>European Program for Pharmacovigilance and Pharmacoepidemiology, University of Bordeaux, Bordeaux, France

Correspondence: Mulugeta Russom, Eritrean Pharmacovigilance Centre, National Medicines and Food Administration, Ministry of Health, Asmara, Eritrea, Tel +291-7197450, Email [satiswt@gmail.com](mailto:satiswt@gmail.com)

**Abstract:** Misoprostol, a synthetic prostaglandin E1 analog, is currently used for medical termination of pregnancy. In the summary of the product characteristics of different market authorization holders of misoprostol tablets, approved by major regulators, serious mucocutaneous reactions, including toxic epidermal necrolysis are not documented as adverse effects. We are now reporting an unusual case of toxic epidermal necrolysis following the use of misoprostol 200 mcg tablets prescribed for termination of a pregnancy. A 25-year-old grand multipara woman from the Gash-Barka region of Eritrea visited Tesseney hospital with a history of amenorrhea that lasted for four months. She was admitted as a case of missed abortion for medical termination of pregnancy. Following three doses of misoprostol 200 mcg tablet the patient developed toxic epidermal necrolysis. Except misoprostol, no other possible alternatives that could explain the condition were identified. Accordingly, the adverse effect was judged to be possibly related to misoprostol. The patient recovered after four weeks of treatment without sequelae. Toxic epidermal necrolysis could, therefore, be a possible adverse effect of misoprostol that needs to be further investigated with better epidemiological studies.

**Keywords:** missed abortion, misoprostol, toxic epidermal necrolysis, Eritrea

## Introduction

Misoprostol, a synthetic prostaglandin E1 analog, was initially developed as an anti-ulcer agent and is currently used for medical termination of pregnancy.<sup>1,2</sup> It has been shown to inhibit either the release/activity of a variety of cytokines and other mediators that may evoke inflammatory reactions and/or tissue damage.<sup>2</sup> Generally, misoprostol is considered as a well-tolerated drug and the commonly reported reactions are diarrhea, abdominal pain, menstrual cramps, nausea, chills, shivering and fever.<sup>1-3</sup> To the best of the authors' knowledge, serious cutaneous reactions such as toxic epidermal necrolysis (TEN), Stevens-Johnson syndrome (SJS) and erythema multiforme are not documented adverse effects of misoprostol.<sup>1-3</sup> In the World Health Organization's global pharmacovigilance database, there are seven spontaneously reported cases of epidermal necrolysis, following the use of misoprostol, reported between 1997 and 2020.<sup>4</sup> In the summary of product characteristics (SmPC) of different market authorization holders of misoprostol tablets approved by major regulators such as the European Medicines Agency (EMA), Medicines and Healthcare Products Regulatory Authority (MHRA) of the UK, the US Food and Drug Administration (FDA), and Australian Therapeutic Goods (TGA), serious mucocutaneous reactions including TEN are not documented as adverse effect.<sup>1-3,5</sup>

Recently, a 25-year-old grand multipara Eritrean woman encountered TEN following the use of misoprostol 200 mcg tablets prescribed for termination of a pregnancy. TEN is an acute and life-threatening medical condition that is usually drug-related; although it does occur in children, infections are rarely responsible for the disease.<sup>6</sup> The most common precipitating medications that have been associated with TEN are non-steroidal anti-inflammatory drugs, sulfonamides, antiepileptics, and different antibiotics.<sup>6</sup> TEN is characterized by extensive detachment of the epidermis and having a poor prognosis (death rate: 30–40%).<sup>7</sup> This article therefore reports the first case of TEN associated with misoprostol tablets in the medical literature.

## Case Presentation

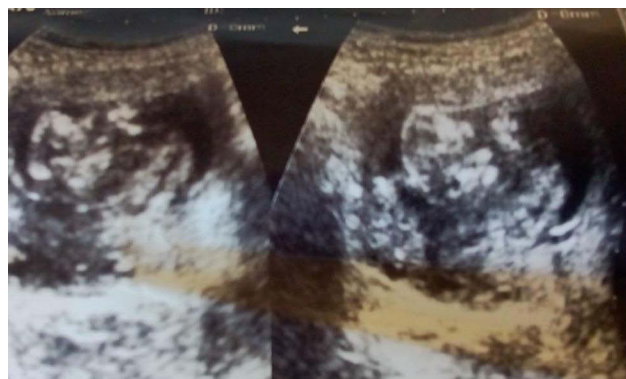A 25-year-old grand multipara, housewife, Eritrean woman came to a community hospital in the Gash-Barka region of Eritrea, on the 8<sup>th</sup> of December 2018. During admission the patient complained of amenorrhea that had lasted for four months. She denied a history of taking any herbal/conventional medicine, a previous miscarriage and recent travel to neighboring countries. The patient reported no previous episodes of a similar nature, no past history of medical, surgical and drug allergy. On physical examination, she had pink conjunctiva and anicteric sclera with lesions in oral mucosa. Chest was clear to auscultation and S1/S2 were well heard without murmur or gallop rhythm. The tip of the uterus was palpable, abdominally, at 12 weeks. On vaginal examination, the cervix was closed and the uterus was bimanually palpable without adnexal masses. She had no history of skin rash/lesion or discoloration while visiting the outpatient department. She was investigated with complete blood count, blood group, and urine analysis and imaging. Her complete blood count showed: White blood cell (WBC)  $7.2 \times 10^3$ , hemoglobin (Hgb) 12.3 g/dl, hematocrit (HCT) 38.2 and platelet count  $356 \times 10^3 /\mu\text{L}$ , and urine analysis was normal. Pregnancy test with human chorionic gonadotropin (HCG) dipstick was positive. Trans-abdominal ultrasonography evaluation showed 12 weeks gestation by crown rump length, with absent fetal heartbeat by different sonographers (Figure 1).

After thorough discussion with the patient and her husband, a decision was reached for immediate admission to the hospital as a case of missed abortion for termination of pregnancy. The patient then took three doses of intravaginal misoprostol 200 mcg tablets in four hour intervals. Following the third dose of misoprostol tablet, the patient developed a diffused itching and burning sensation all over her body, shivering, abdominal cramps and scanty vaginal bleeding.

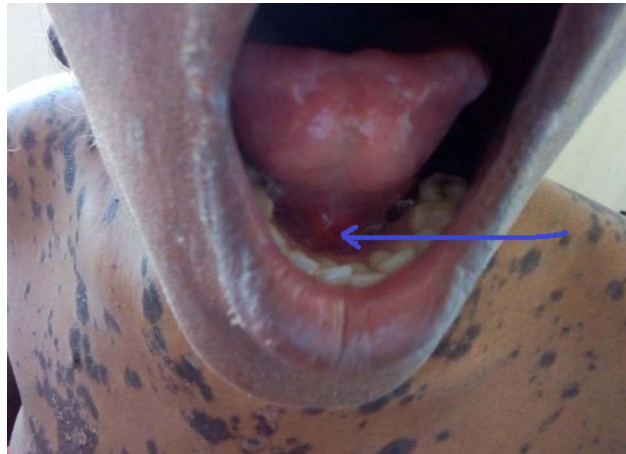
On physical examination, the patient was acutely sick looking but well orientated to time, person and place. She was hemodynamically stable with vital signs of blood pressure 110/70 mmHg on right arm in supine position, pulse rate 96 beats/minute right radial artery, temperature 38.4 °C in left axilla and respiratory rate 20 breaths/minute. On vaginal examination, the cervix was closed with blood on the examining finger. On December 10, 2018, misoprostol was discontinued and oral chlorpheniramine started to treat the itching and burning sensation. On December 11, patient developed a generalized maculopapular skin rash that started at her neck and expanded to nearly all the skin surface including buccal mucosa (Figure 2). The oral cavity revealed several ulcers mainly affecting the sublingual area without extension into the pharynx. The lesions were very painful which prevented her from taking regular meals.

At the beginning, the skin rash was diffuse erythematous, maculopapular, non-blanching affecting the trunk, bilateral upper and lower limbs, face, and neck. The lesions had a dark red area surrounded by a paler pink zone. The ulceration was more severe on the trunk and lower back without blistering and evidence of superimposed cellulitis (Figure 3). There was no sign of meningitis or facial deviation. Ophthalmological examination revealed no sign of conjunctivas involvement. Due to limitations of laboratory setups, skin biopsy could not be performed. At first, Steven Johnson syndrome was entertained but, later, as the lesions become extensive and covered more than 40% body surface with mucosal involvement, the case was diagnosed as TEN.

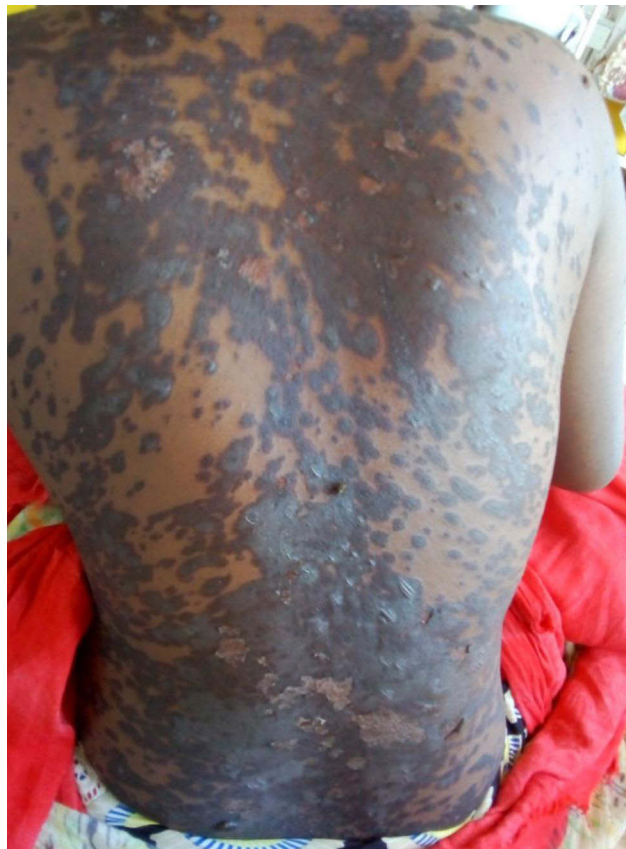The patient was managed with hydrocortisone 100 mg intravenously four times daily, normal saline 0.9% infusion, ibuprofen 400 mg tablets three times daily, and chlorphenamine maleate tablet 4 mg three times daily. Ampicillin 1 gram intravenously every six hours was also started as prophylaxis because the skin barrier was broken and the hospital



**Figure 1** Trans-abdominal sonography showed non-alive fetus with gestational age of 12 weeks by crown rump length.



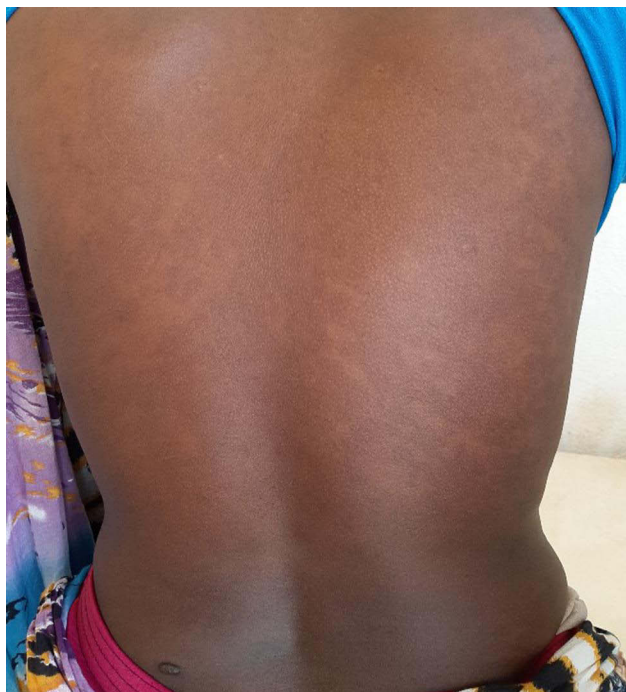**Figure 2** This figure, with arrow, shows buccal mucosa involvement on the 5<sup>th</sup> day.



**Figure 3** Shows skin lesions developed at the fifth day of initiation of misoprostol tablet.

environment was prone for nosocomial infection. he patient was also isolated in a separate and relatively clean room to prevent nosocomial infection. Following hydrocortisone injection, the patient reported marked reduction in pruritus without improvement to the skin lesion, which progressed over the next two days that involved all extremities and partly her face. After four days of treatment with hydrocortisone, it was shifted to prednisolone tablet 30 mg, twice daily.

A week after her admission, December 15, 2018, the mother spontaneously expelled the fetus and the remnant was cleared by evacuation with curettage. After 12 days of hospitalization, the patient was discharged with tapered doses of prednisolone tablet. The patient fully recovered gradually, over a four-week period, without sequelae (Figure 4). Finally,



**Figure 4** Shows fully recovered skin after a six-month follow-up visit.

the patient consented for her anonymized details and images to be published in an international journal. Ethical approval for publishing case reports was not required by the Ministry of Health of the State of Eritrea.

## Discussion

Taking the development of the cutaneous reaction, proportion of the body surface area affected and clinical characteristics of the reaction (involvement of the mucous membrane) into consideration, the case was diagnosed as TEN. Clinically, TEN begins with a prodrome of fever, malaise and influenza-like symptoms, one to three days before the development of mucocutaneous lesions. Mucous membranes are involved in nearly all cases and buccal mucosa is the frequently affected area.<sup>8</sup> In the early stages, skin pain may be prominent and out of proportion to clinical findings.<sup>9</sup> After one to three days, the skin lesions could progress to full-thickness epidermal necrosis.

In the summary of product characteristics (SmPCs) of misoprostol tablet, approved by major regulators, there is no mention of TEN as an adverse reaction; making the case unusual.<sup>1-3,5</sup> All SmPCs document only rash as a cutaneous adverse reaction. Searches made in PubMed, Google scholar, and the online drug information databases such as Martindale: the Complete Drug Reference,<sup>10</sup> Drugdex<sup>11</sup> and the SIDER side-effect resource<sup>12</sup> could not find any association between misoprostol and TEN. In literature, there is a single case report of severe hypersensitivity reaction associated with misoprostol in a patient administered for abortion which recovered following a tapered three-week treatment with prednisolone tablets.<sup>13</sup> There is however a case report that associates documented TEN following use of mifepristone; the same drug class with misoprostol.<sup>14</sup>

During investigation, efforts were made to identify other possible alternative explanations. The patient had no history of infection/immunodeficiency and other drugs intake. The immunological basis of this disease is still unclear but patients with AIDS or other viral infections are at increased risk of serious cutaneous reactions such as TEN.<sup>15</sup> In our case, however, disease conditions that are likely to compromise her immunity such as HIV could not be identified.

The mechanism on how misoprostol could cause TEN is unknown. The pathologic mechanisms that could induce toxic epidermal necrolysis are also incompletely understood.<sup>7</sup> The short interval between a recurrent exposure and the onset of symptoms was consistent with an immunologic process. Currently, a promising line of investigation is granulysin, a cytolytic protein produced and secreted by cytotoxic T-lymphocytes and natural killer (NK) cells, which

is found to have an implication with the pathologic process of TEN.<sup>16</sup> Granulysin was identified as the most highly expressed cytotoxic molecule both in fluid and cells from blisters in patients with TEN. Recent studies have shown that keratinocytes in TEN undergo apoptosis, not simply necrosis and the extensive keratinocyte apoptosis results in large areas of epidermal detachment.<sup>7</sup>

The management of TEN usually involves a multispecialty team, that includes experts in critical care, plastic surgery/wound care, dermatology, infectious disease, ophthalmology, and nutrition.<sup>14</sup> As there was no Burn Centre in the hospital, she was managed in a gynecology ward which could have exposed her to nosocomial infection. The management of TEN with hydrocortisone and ampicillin injection was found to be effective for the mother. To minimize the risk of fluid and electrolyte imbalance due to increased trans-epidermal water loss, intravenous fluids were provided. The study shows that, beyond supportive care, there are no universally effective and established therapies for TEN.<sup>7</sup> Immediate and regular ophthalmological check-ups were also performed to identify the risks of ocular complications and no problem was observed.

There were some limitations in diagnosing and managing the case. First, diagnosis of TEN was made based on the observed clinical features. Second, TEN was associated with misoprostol mainly based on temporality, positive dechallenge, and the fact that no other possible alternative explanation was identified. Though TEN is usually drug-related, other risk factors such as acute viral infection and cancer that might contribute to the case could not be ruled out. The patient, however, had no such medical history and a complete blood count at baseline showed no signs of infection. Third, conducting repeated cultures of the skin, blood, catheters, gastric, and urinary tubes is usually recommended to guide the appropriate use of antibiotics. This, however, could not be performed due to lack of a laboratory set-up.

## Conclusion

TEN could be a possible adverse effect of misoprostol that needs to be further investigated with better epidemiological studies. It is important to note that skin lesions may not appear until a few days after onset of the prodromal flu-like symptoms. Thus, informing consumers of the early signs and symptoms of serious cutaneous reactions and the need for immediate consultation of healthcare professionals is important.

## Ethics Approval and Consent to Participate

Obtaining ethical clearance from the Ministry of Health's Ethical Clearance and Protocol Review Committee is not required for case reports. Informed consent was obtained from the patient to publish her anonymized personal details and accompanying images in an international journal.

## Acknowledgments

We would like to thank Dr. Henok Tekie, Dr. Ghide Gebreweld, Dr. Tsegegab Kiflezghi, Dr. Abdulaziz Mohammed Seid, and Abel Abraham, BSN from Tesseney Hospital for their comments and valuable insights.

## Funding

No funding was used for this study.

## Disclosure

The authors declare that they have no competing interests.

---

## References

1. UK Electronic Medicines Compendium (emc). Summary of product characteristic of misoprostol (cytotec) 200 microgram tablet (Pfizer limited). Available from: <https://www.medicines.org.uk/emc/product/1642/smpc#gref>. Accessed January 23, 2023.
2. US-Food and Drug Administration. Prescribing information of misoprostol 200 microgram tablet. Available from: [https://www.accessdata.fda.gov/drugsatfda\\_docs/label/2002/19268slr037.pdf](https://www.accessdata.fda.gov/drugsatfda_docs/label/2002/19268slr037.pdf). Accessed January 23, 2023.
3. European Medicines Agency. Summary of product characteristic of misoprostol 200 microgram tablet. Available from: [https://www.ema.europa.eu/en/documents/outside-eu-product-information/hemoprostol-product-information\\_en.pdf](https://www.ema.europa.eu/en/documents/outside-eu-product-information/hemoprostol-product-information_en.pdf). Accessed February 13, 2023.

4. Bettuzzi T, Ingen-Housz-Oro S, Purtillo CC, et al. Changing spectrum of suspected drugs of epidermal necrolysis: a World Health Organization pharmacovigilance database analysis from 1997–2020. *J Am Acad Dermatol*. 2021;85(6):1581–1584. doi:10.1016/j.jaad.2020.10.091
5. Australian public assessment report for misoprostol; 2012. Available from: <https://www.tga.gov.au/sites/default/files/auspar-misoprostol-121002.pdf>. Access on February 13, 2023.
6. Bastuji-Garin S, Rzany B, Stern RS, et al. Clinical classification of cases of toxic epidermal necrolysis, Stevens-Johnson syndrome, and erythema multiforme. *Arch Dermatol*. 1993;129(1):92–96. doi:10.1001/archderm.1993.01680220104023
7. Garcia-Doval I, LeCleach L, Bocquet H, et al. Toxic epidermal necrolysis and Stevens-Johnson syndrome: does early withdrawal of causative drugs decrease the risk of death? *Arch Dermatol*. 2000;136(3):323–327. doi:10.1001/archderm.136.3.323
8. Auquier-Dunant A, Mockenhaupt M, Naldi L, et al. Correlations between clinical patterns and causes of erythema multiforme majus, Stevens-Johnson syndrome, and toxic epidermal necrolysis: results of an international prospective study. *Arch Dermatol*. 2002;138(8):1019–1024. doi:10.1001/archderm.138.8.1019
9. Piechota M, Banach M, Kopeck A, Rysz J, Narbutt J. Toxic epidermal necrolysis (Lyell's syndrome): case report and review of the literature. *Arch Med Sci*. 2008;4(4):480–485.
10. Buckingham R, ed. Martindale: the complete drug reference. London: Pharmaceutical Press. Available from: <http://www.medicinescomplete.com.cmezproxy.chmeds.ac.nz/>. Accessed February 10, 2023.
11. University of Minnesota. Micromedex Help Guide. Available from: [www.micromedexsolutions.com](http://www.micromedexsolutions.com). Accessed February 10, 2023.
12. Kuhn M, Letunic I, Jensen LJ, Bork P. The SIDER database of drugs and side effects. *Nucleic Acids Res*. 2015. doi:10.1093/nar/gkv1075
13. Madaan M, Puri M, Sharma R, Trivedi SS. Hypersensitivity reaction to misoprostol - a case report. *IJCM*. 2012;3(3). doi:10.4236/ijcm.2012.33044
14. Lecorvaisier-Pieto C, Joly P, Thomine E, Tanasescu S, Noblet C, Lauret P. Toxic epidermal necrolysis after mifepristone/gemeprost-induced abortion. *J Am Acad Dermatol*. 1996;35(1):112. doi:10.1016/S0190-9622(96)90520-4
15. Palmieri TL, Greenhalgh DG, Saffle JR, et al. A multicenter review of toxic epidermal necrolysis treated in US burn centers at the end of the twentieth century. *J Burn Care Rehabil*. 2002;23(2):87–96. doi:10.1097/00004630-200203000-00004
16. Chung WH, Hung SI, Yang JY, et al. Granulysin is a key mediator for disseminated keratinocyte death in Stevens-Johnson syndrome and toxic epidermal necrolysis. *Nat Med*. 2008;14:1343–1350. doi:10.1038/nm.1884

### International Medical Case Reports Journal

Dovepress

### Publish your work in this journal

The International Medical Case Reports Journal is an international, peer-reviewed open-access journal publishing original case reports from all medical specialties. Previously unpublished medical posters are also accepted relating to any area of clinical or preclinical science. Submissions should not normally exceed 2,000 words or 4 published pages including figures, diagrams and references. The manuscript management system is completely online and includes a very quick and fair peer-review system, which is all easy to use. Visit <http://www.dovepress.com/testimonials.php> to read real quotes from published authors.

Submit your manuscript here: <https://www.dovepress.com/international-medical-case-reports-journal-journal>