

# Revision Procedure After Surgery for Atypical Hangman's Fracture Primarily Performed Only from the Posterior Approach – An Attempt to Maintain Head Rotation: Case Report

Bartosz Godlewski , Maciej Dominiak , Adam Bebenek 

Department of Orthopaedics and Traumatology, with Spinal Surgery Ward, Scanmed – St. Raphael Hospital, Cracow, Poland

Correspondence: Bartosz Godlewski, Department of Orthopaedics and Traumatology, with Spinal Surgery Ward, Scanmed – St. Raphael Hospital, ul. Adama Bochenka 12, Cracow, 30-693, Poland, Tel/Fax +48 12 3855634, Email bartoszgodlewski@wp.pl

**Introduction:** Hangman's fracture, also known as traumatic spondylolisthesis of the axis, is defined as a bilateral fracture of the C2 pars interarticularis. In 1965, Schneider used this term to describe a pattern of similarities seen in fractures associated with judicial hangings. However, this fracture pattern is only observed in approximately 10% of injuries associated with hangings.

**Case Report:** We present a case of an atypical hangman's fracture caused by a headlong dive into a swimming pool and striking the pool's bottom. The patient had undergone surgery at another centre, where posterior C2-C3 stabilisation was performed. Due to the presence of screws in the C1-C2 joint spaces, the patient could not perform rotational movements of the head. Anterior stabilization to prevent C2 dislocation against C3 was also not performed, and appropriate spinal stability was not ensured. Our decision to reoperate was motivated, among other factors, by our intention to restore rotational head movements. The revision surgery was performed from both an anterior and posterior approach. After the surgery, the patient was able to rotate his head while maintaining cervical spine stability. The case presented here represents not only a unique example of an atypical C2 fracture but also highlights a fixation technique that provided the necessary stability for successful fusion. The utilized method restored functional rotational movement of the head, thus preserving the patient's quality of life, which is of paramount importance considering the patient's age.

**Conclusion:** The decision-making process regarding the technique for treating hangman's fractures, especially atypical fractures, should account for the patients' quality of life after the operation. The preservation of as much of the physiological range of motion as possible with maintained spinal stability should be the goal of therapy in every case.

**Keywords:** hangman's fracture, traumatic spondylolisthesis of C2, axis fracture, cervical spine, fusion

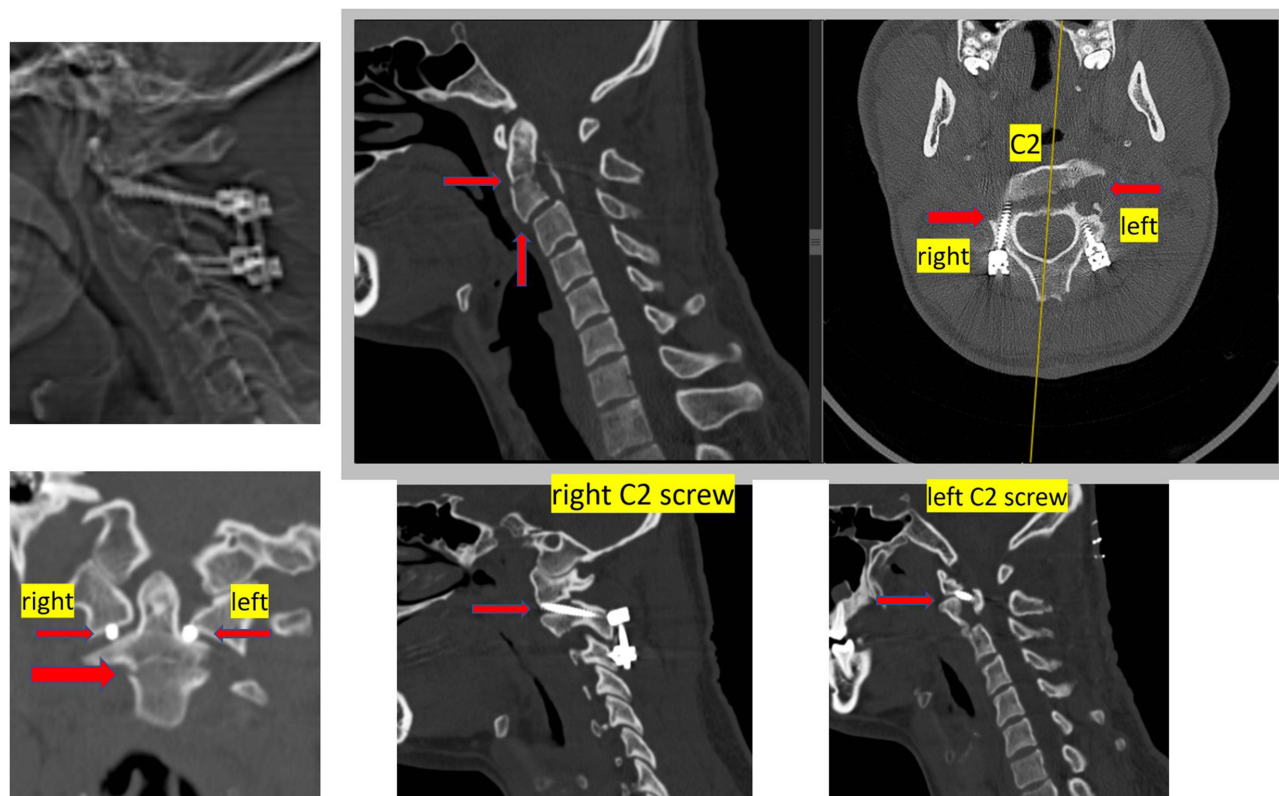
## Introduction

Hangman's fracture, also known as traumatic spondylolisthesis of the axis, is characterized by a bilateral fracture of the C2 pars interarticularis.<sup>1,2</sup> Initially described by Schneider in 1965, this fracture pattern was associated with judicial hangings.<sup>3</sup> However, further research indicates that this specific pattern is observed in only approximately 10% of hangings-related injuries.<sup>4,5</sup> In this case report, we present an atypical Hangman's fracture resulting from a headlong dive into a swimming pool, causing impact with the pool's bottom. The patient had previously undergone surgery at another center. Our decision to perform a reoperation was primarily driven by the goal of restoring rotational head movements while maintaining cervical spine stability. This case represents a rare instance of an atypical Hangman's fracture and highlights the effectiveness of a fixation technique that provided the necessary stability for successful fusion. By employing this method, we successfully restored functional rotational movement of the head, significantly preserving the patient's quality of life, particularly given their age. It is important to note that the scientific literature lacks well-defined management protocols for

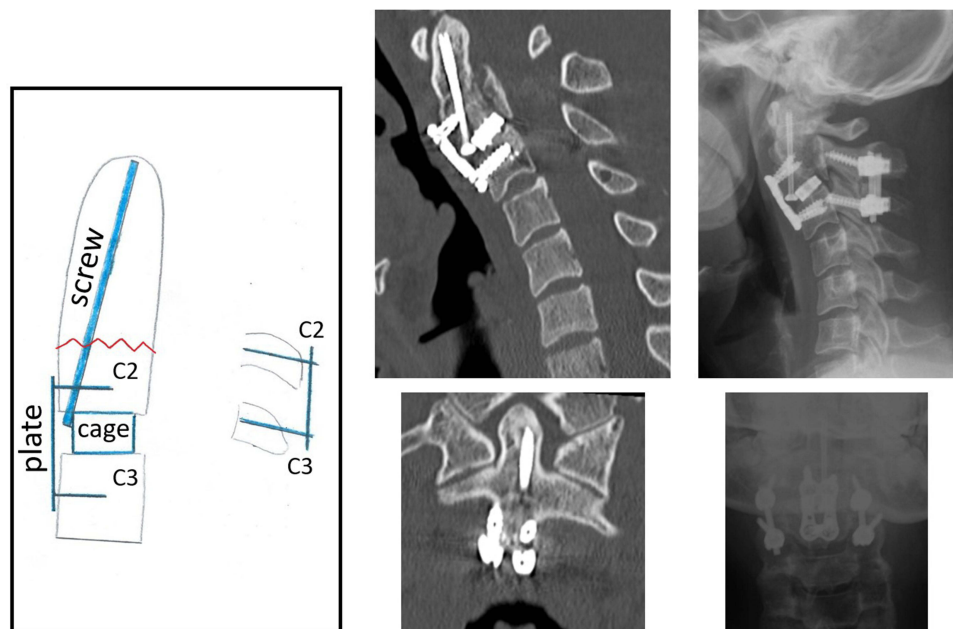
atypical Hangman's fractures, underscoring the need to present innovative solutions that ensure adequate stability and promote fusion while prioritizing patients' quality of life.

## Case Report

A 25-year-old patient presented for a neurosurgical consultation concerned about his health. His history included a headlong dive into a swimming pool during the holidays two weeks previously. The dive resulted in a fracture of the cervical spine. The patient underwent surgery where he was staying for his holidays. Posterior stabilization of the cervical spine was performed. The patient was wearing a cervical collar, and the surgical wound still had not healed, with the sutures not yet removed. The patient demonstrated no pareses and was able to move about on his own. He did not have detailed medical documentation or diagnostic examination reports for preoperative and postoperative periods. At discharge, he was given an incomplete postoperative CT of the cervical spine in the form of a few old-style films showing some of the views but without digital images. The discharge summary did not contain the necessary detailed description of the treatment provided, including no details about the instrumentation used. The hospital staff or the operators could not be contacted because they would not answer the phone or reply to e-mails and text messages. We decided that a new CT of the cervical spine should be obtained. It revealed status post atypical hangman's fracture of the cervical spine: a fracture of the C2 pars interarticularis on the left, dislocation of C2 against C3, fracture of the C2 vertebral body with detachment and anterior displacement of a part of the C2 vertebral body. The patient was operated on from a posterior approach. Posterior stabilization of C2-C3 was performed. The screws were correctly positioned in the lateral masses of C3. Within the C2 vertebra however, both screws were initially placed transpedicularly, but their ends did not reach the C2 vertebral body or lateral masses of C1 and extended into the left and right C1-C2 joint spaces. CT images of the status post initial surgery performed at another centre are shown in [Figure 1](#). Leaving this spinal stabilization in place made the



**Figure 1** CT images revealing status post the initial surgery performed at another centre. Red arrows point to key abnormalities seen on the CT scans that underlay our decision to perform revision surgery: C2-C3 displacement/instability, fracture of the C2 vertebral body with detachment and anterior displacement of a part of the C2 body, fracture of the C2 pars interarticularis on the right, and incorrect location of screws within C2, with their ends seen within C1-C2 joint spaces, making it impossible for the patient to perform rotational head movements.

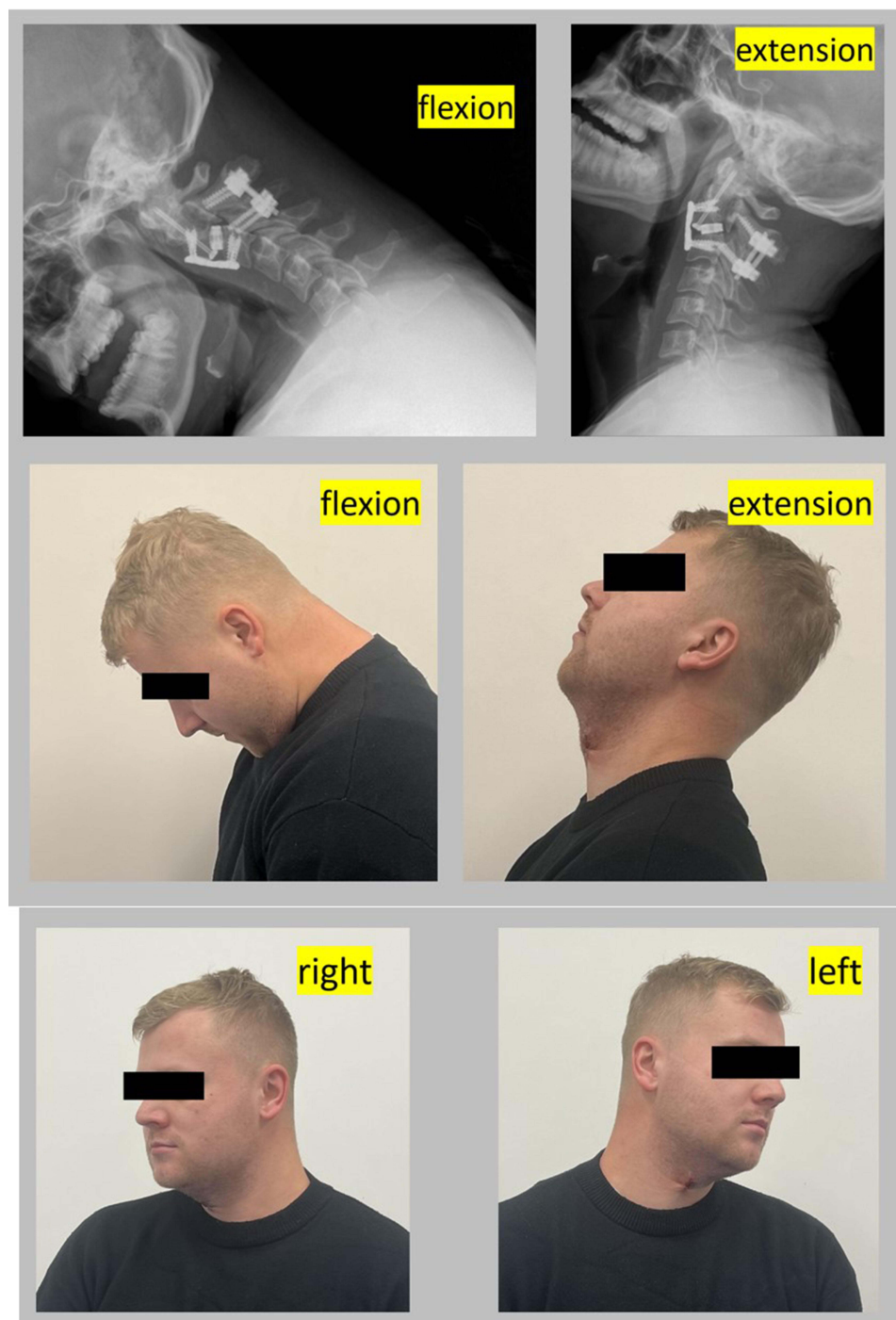


**Figure 2** Schematic of the surgery we performed and post-operative CT and X-ray images.

patient unable to perform rotational movements of the head as the screws were placed within the C1-C2 joints. Anterior stabilization to prevent C2 dislocation against C3 was also not performed, and appropriate spinal stability was not ensured. After analysing the spinal CT images, we decided to re-operate. Our intention was to restore rotational head movements while ensuring stability of the cervical spine. We decided to use both an anterior and posterior approach. [Figure 2](#) presents a schematic of the procedure and postoperative X-ray and CT images. The first stage of the procedure from a posterior approach consisted of the removal of the screws from C2 bilaterally, with the ends of the screws being within the C1-C2 joint spaces, followed by the placement, from the same approach, of shorter screws that ended within C2, thus not reaching the joint spaces and not blocking head rotation. Before the procedure, we did not know what type of screws (manufacturer) had been used originally. It was revealed intraoperatively that the screws were of a type that was also available at our hospital. We did not change the location of the screws within the C3 lateral masses as they were properly implanted. The C2-C3 screws were then joined with longitudinal rods bilaterally. In the second stage of the procedure, from an anterior approach, we performed a C2/C3 discectomy and placed a cage in the C2/C3 space, followed by the placement of a pressure screw throughout the length of the body of C2 and the odontoid process. Finally, we used a cervical plate fixated with 4 screws for C2-C3 stabilization. The postoperative period proceeded without any complications. Apart from minor pain associated with the surgical wound, no concerning symptoms such as dysphagia or voice hoarseness were observed. A follow-up CT scan revealed normal postoperative appearances matching the preoperative assumptions. The patient was discharged home in a good overall and neurological condition. A follow-up functional X-ray of the cervical spine at 8 weeks after the procedure also revealed normal postoperative appearances. At present, the patient has functional flexion/extension and rotational head movements and cervical spine stability is also preserved ([Figure 3](#)).

## Discussion

C2 fractures can be divided into three categories: 1) odontoid fractures, the most common; 2) hangman's fracture involving both pedicles/bilateral pars interarticularis fracture and 3) atypical fractures (non-odontoid, non-hangman's) involving the vertebral body, unilateral or complex.<sup>6,7</sup> Hangman's fractures account for 15–20% of all cervical spine fractures and are often a component of combined atlantoaxial injuries.<sup>1,2,8</sup> They are usually classified according to the scheme of Effendi et al<sup>9</sup> and its modification by Levine and Edwards.<sup>10</sup> Type I injuries are considered stable, whereas type II, IIA, and III injuries are unstable as they usually



**Figure 3** Functional radiograph of cervical spine and photographs of the patient at 8 weeks after the procedure showing intact flexion/extension and rotational head movements.

involve damage to the C2/C3 disc and anterior and posterior longitudinal ligaments.<sup>2,11–13</sup> Type I and II fractures, as classified by Levine and Edwards, can be managed conservatively through immobilization using various methods such as a hard collar, Minerva Jacket, Sternal Occipital Mandibular Immobilizer (SOMI) brace, or HALO vest.<sup>1,2</sup> However, fractures characterized by instability, including type II, type IIa, and type III fractures, have a success rate of less than 50% with conservative treatment (43% for type IIa and <40% for type III fractures) and therefore require surgical intervention.<sup>1,2</sup> Surgical treatment options include anterior access techniques, posterior access techniques, or a combination of both. The anterior approach commonly involves

anterior discectomy and fusion (ACDF) procedure. By sparing the atlanto-axial articulation and avoiding incorporation of the atlas, the anterior approach preserves some rotational movement of the head. Type IIa and III fractures are more likely to fail in flexion due to disruption of the C2-3 disc space and the posterior longitudinal ligament, and thus posterior stabilization is the preferred treatment approach. In the past, plate and wiring techniques were used for this purpose, but currently, the standard procedure is C2-C3 posterior cervical decompression and fusion (PCDF) using C2 pedicle and C3 lateral mass screws. It is worth noting that including C1 for stabilization can limit rotational movement of the head. For type III fractures, both anterior and posterior approaches have similar healing rates of 42.86% and 39.29%, respectively. Therefore, a combination of anterior and posterior approaches may be considered for patients with Levine-Edwards Type IIa and Type III fractures. In summary, unstable fractures require surgical intervention through anterior, posterior, or mixed anteroposterior approaches.<sup>1,2</sup> However, the surgical treatment of hangman's fractures remains poorly standardized, especially with regard to atypical fractures.<sup>8,14-17</sup> In the authors' perspective, the use of ACDF and PCDF techniques individually has certain drawbacks. ACDF, while preserving rotational head movements, may not provide sufficient stabilization, which can be life-threatening in cases of atypical fractures with potential spinal canal narrowing.<sup>1</sup> On the other hand, PCDF may offer stabilization but at the cost of limiting functional rotational head movements, significantly impacting quality of life. Therefore, it is important to explore solutions that combine the advantages of both ACDF and PCDF. In 2019, Soliman et al<sup>18</sup> presented two cases of patients with type I and type IIa hangman's fractures, respectively, who underwent unilateral insertion of a pressure screw guided by neuronavigation and fluoroscopy. This technique resulted in resolution of discomfort and achieved stable fusion during the follow-up period. Soliman suggested that this approach strikes a balance between effective stabilization and good quality of life for trauma patients.<sup>18</sup> This procedure may be effective in treating typical grade I and grade II fractures, where widening of the spinal canal is a potential mechanism. However, atypical fractures that narrow the spinal canal may require more complex forms of stabilization to ensure safety and promote fusion. Therefore, the authors emphasize the importance of knowledge sharing to develop common and effective recommendations and guidelines that ensure efficacy and improve patients quality of life.

The aim of the revision surgery we performed was to allow for rotational head movements of a stable cervical spine. Head rotation was made impossible by screws in the C1-C2 joint spaces that needed to be removed/repositioned. Apparently, the surgeons who performed the initial procedure had intended to achieve transpedicular stabilization of C2 by anchoring the ends of the screws in the C2 vertebral body or they might have been thinking to perform C1-C2 transarticular fixation. They subsequently connected the C2 screws using longitudinal rods to the screws introduced (correctly) into the lateral masses of C3. To restore head rotation, we removed the C2 screws and placed shorter screws via the same pathway that did not extend as far as the joint spaces. We decided not to change the trajectory of screw placement and not use a transpedicular approach to place them in the C2 vertebral body as the new approach might have caused damage to the C2 pedicular bone and the screws would not be stably anchored in bone. In the second stage, we performed an anterior discectomy at C2/C3 and implanted a cage. Before placing a C2-C3 plate, we additionally mounted a pressure screw as is done in cases of type II odontoid fractures.<sup>19,20</sup> Our patient had not sustained this type of fracture, and there was a C2 body fracture, but we decided to use this method to ensure superior conditions for healing to promote bony union. We believe that stabilization with a C2-C3 cervical plate alone in the setting of a co-existing C2 body fracture just superior to this site could generate forces impeding bone union within the fractured C2 body. Accordingly, we introduced a pressure screw throughout the C2 vertebral body and odontoid process and only after that did we place a C2-C3 cervical plate secured with 4 screws. [Figure 2](#) presents a schematic of the procedure and X-ray and CT images following the surgery. After the surgery, the patient was able to rotate his head with preserved cervical spine stability. This case history highlights the complexity of planning the therapeutic process. It underscores the significance of taking into account not only technical aspects but also the patient's future quality of life.

## Limitations

Undoubtedly, the case presented here serves only as a proposed approach for managing a complex atypical hangman's fracture. In any clinical scenario, treatment decisions should be based on patient-specific factors, neurological status, and current scientific evidence regarding the efficacy of different treatment modalities. It is important to acknowledge that our case has limitations, including the relatively short follow-up period and the potential burden of the proposed treatment, which may be challenging for elderly patients.

## Conclusion

When deciding to operate on a patient with hangman's fracture, especially an atypical fracture, we should consider the patient's quality of life postsurgery. Our goal in every case should be to preserve a range of motion as close as possible to the physiological range, while not impairing spinal stability.

## Data Sharing Statement

Data, anonymized images/DICOM files supporting the results of this study, can be assessed on request to the corresponding author.

## Consent for Publication

Written informed consent was obtained from the patient for publication of this case report and any accompanying images.

## Funding

This research received no external funding.

## Disclosure

The authors declare no conflict of interest.

## References

1. Turtle J, Kantor A, Spina NT, France JC, Lawrence BD. Hangman's Fracture. *Clin Spine Surg*. 2020;33(9):345–354. doi:10.1097/BSD.0000000000001093
2. Li XF, Dai LY, Lu H, Chen XD. A systematic review of the management of hangman's fractures. *Eur Spine J*. 2006;15(3):257–269. doi:10.1007/S00586-005-0918-2
3. Schneider RC, Livingston KE, Cave AJ, Hamilton G. "Hangman's fracture" of the cervical spine. *J Neurosurg*. 1965;22(2):141–154. doi:10.3171/JNS.1965.22.2.0141
4. James R, Nasmyth-Jones R. The occurrence of cervical fractures in victims of judicial hanging. *Forensic Sci Int*. 1992;54(1):81–91. doi:10.1016/0379-0738(92)90083-9
5. Rayes M, Mittal M, Rengachary SS, Mittal S. Hangman's fracture: a historical and biomechanical perspective. *J Neurosurg Spine*. 2011;14(2):198–208. doi:10.3171/2010.10.SPINE09805
6. Robinson AL, Möller A, Robinson Y, Olerud C. C2 Fracture subtypes, incidence, and treatment allocation change with age: a retrospective cohort study of 233 consecutive cases. *Biomed Res Int*. 2017;2017:1–7. doi:10.1155/2017/8321680
7. Starr JK, Eismont FJ. Atypical hangman's fractures. *Spine*. 1993;18(14):1954–1957. doi:10.1097/00007632-199310001-00005
8. Prost S, Barrey C, Blondel B, et al. Hangman's fracture: management strategy and healing rate in a prospective multi-centre observational study of 34 patients. *Orthop Traumatol Surg Res*. 2019;105(4):703–707. doi:10.1016/J.OTSR.2019.03.009
9. Effendi B, Roy D, Cornish B, Dussault RG, Laurin CA. Fractures of the ring of the axis. A classification based on the analysis of 131 cases. *J Bone Joint Surg Br*. 1981;63-B(3):319–327. doi:10.1302/0301-620X.63B3.7263741
10. Levine AM, Edwards CC. The management of traumatic spondylolisthesis of the axis. *JBJS*. 1985;67(2):217–226. doi:10.2106/00004623-198567020-00007
11. Murphy H, Schroeder GD, Shi WJ, et al. Management of hangman's fractures: a systematic review. *J Orthop Trauma*. 2017;31(4):S90–S95. doi:10.1097/BOT.0000000000000952
12. Ge C, Hao D, He B, Mi B. Anterior cervical discectomy and fusion versus posterior fixation and fusion of C2-3 for unstable hangman's fracture. *J Spinal Disord Tech*. 2015;28(2):E61–E66. doi:10.1097/BSD.0000000000000150
13. Goel A, Hawaldar A, Shah A, et al. Hangman's fracture: a clinical review based on surgical treatment of 15 cases. *Neurosurg Rev*. 2022;45(1):595–606. doi:10.1007/S10143-021-01556-8
14. ElMiligui Y, Koptan W, Emran I. Transpedicular screw fixation for type II Hangman's fracture: a motion preserving procedure. *Eur Spine J*. 2010;19(8):1299–1305. doi:10.1007/S00586-010-1401-2/METRICS
15. Sawarkar D, Agrawal M, Singh PK, et al. Evolution to pedicle reformation technique in surgical management of hangman's fracture. *World Neurosurg*. 2021;149:e481–e490. doi:10.1016/J.WNEU.2021.02.001
16. Seo HY, Ko JH, Park JB, Kim SK, Hwang ZO. Anterior C2-3 fusion surgery alone for highly displaced Hangman's fracture with severe angulation of C2-3 of more than 30°. *Clin Neurol Neurosurg*. 2021;206:106701. doi:10.1016/J.CLINNEURO.2021.106701
17. Duggal N, Chamberlain RH, Perez-Garza LE, Espinoza-Larios A, Sonntag VKH, Crawford NR. Hangman's fracture: a biomechanical comparison of stabilization techniques. *Spine*. 2007;32(2):182–187. doi:10.1097/01.BRS.0000251917.83529.0B
18. Soliman MAR, Kwan BYM, Jhavar BS. Minimally invasive unilateral percutaneous transfracture fixation of a hangman's fracture using neuronavigation and intraoperative fluoroscopy. *World Neurosurg*. 2019;122:90–95. doi:10.1016/J.WNEU.2018.10.140
19. Anderson LD, D'Alonzo RT. Fractures of the odontoid process of the axis. *JBJS*. 1974;56(8):1663–1674. doi:10.2106/00004623-197456080-00017
20. Godlewski B, Radek M, Radek A. Unorthodox technique of simultaneous reposition of an odontoid process fracture from a posterior pharyngeal wall approach and direct screw fixation from a submandibular approach. *Ortop Traumatol Rehabil*. 2009;11(1):61–67.

### International Medical Case Reports Journal

Dovepress

### Publish your work in this journal

The International Medical Case Reports Journal is an international, peer-reviewed open-access journal publishing original case reports from all medical specialties. Previously unpublished medical posters are also accepted relating to any area of clinical or preclinical science. Submissions should not normally exceed 2,000 words or 4 published pages including figures, diagrams and references. The manuscript management system is completely online and includes a very quick and fair peer-review system, which is all easy to use. Visit <http://www.dovepress.com/testimonials.php> to read real quotes from published authors.

Submit your manuscript here: <https://www.dovepress.com/international-medical-case-reports-journal-journal>