

Transversely Sectioned Mini-Punch Grafting: A Novel Technique for Effective Treatment of Hairline Vitiligo

Qiaochu Zhou¹, Wei Wang², Qi Yu¹, Jinhui Wang¹, Wenzheng Zhu¹

¹Department of Dermatology, Wenzhou Hospital of Integrated Traditional Chinese and Western Medicine, Affiliated Hospital of Integrated Traditional Chinese and Western Medicine of Shanghai University, Wenzhou, Zhejiang, People's Republic of China; ²Department of Gynecology, Wenzhou Hospital of Integrated Traditional Chinese and Western Medicine, Affiliated Hospital of Integrated Traditional Chinese and Western Medicine of Shanghai University, Wenzhou, Zhejiang, People's Republic of China

Correspondence: Wei Wang, Wenzhou Hospital of Integrated Traditional Chinese and Western Medicine, Affiliated Hospital of Integrated Traditional Chinese and Western Medicine of Shanghai University, 75Jinxiu, Wenzhou, 325000, People's Republic of China, Tel +8613968900070, Fax +8657788980818, Email w2wangwei@126.com

Objective: Hairline vitiligo is a special area. Hairy areas within the hairline often require repigmentation and regrowing hair shafts. The face and forehead outside the hairline do not require regrowing hair shafts, only repigmentation. To tackle this issue, we modified the conventional mini-punch grafting with a combined application of mini-punch grafting and follicular hair transplant.

Methods: Five patients with localized hairline stable vitiligo aged 26–32 years old had a history of nonsurgical treatments for at least 3 months and without progress. The grafts were transversely sectioned. The intact half follicles were preserved below the cross-section. Sectioned grafts were placed into the chambers for transplanting with forceps.

Results: The treatment using transversely sectioned mini-punch grafting with the patient was performed for all five patients, and the results were satisfactory. In the area of the forehead outside the hairline with the sectioned mini-punch grafting above the cross-section, hair loss and repigmentation were observed. In the area of the hairy areas within the hairline, growing hair shafts and repigmentation were observed, without hair loss.

Conclusion: Our report can help to manage hairline vitiligo or hairy areas vitiligo. This method can be considered a potential method for the treatment of hairline vitiligo, thus providing a simple solution to complex problems.

Keywords: vitiligo, punch grafting, mini-punch grafting, skin punch

Introduction

Vitiligo is a multifactorial depigmentation disease. The most effective vitiligo therapies include topical steroids, calcineurin inhibitors, phototherapy, and surgery.¹ The causes of vitiligo development and repigmentation are not fully understood. Vitiligo's immunological pathogenic mechanism includes the destruction of melanocytes, oxidative stress, immune response, abnormalities in the immune inflammatory microenvironment, and dermal fiber components.^{2,3} Nonsurgical treatments are not always effective for many patients with refractory vitiligo. Refractory vitiligo is resistant to these multimodal treatments and is a complex problem.

For surgical therapy of depigmentation illnesses like vitiligo, many autologous melanocytes are necessary.⁴ Vitiligo is associated with pigment degradation in skin melanocyte cells.⁵ The autologously transplanted dermis-derived cells contribute to the synthesis of melanin.⁶ Tissue grafting techniques and cellular grafting techniques have been used.⁷ The hair follicle and mini punch techniques are among the tissue grafting techniques available.⁸ A trichiasis electrolyzer, combined with a single hair follicle transplant, was an effective treatment for vitiligo-associated leukotrichia.⁹ Some studies have suggested that punch grafting may offer the highest likelihood of repigmentation.¹⁰ It has been also shown that a randomized comparison of excimer laser versus narrow-band ultraviolet B phototherapy after punch grafting in

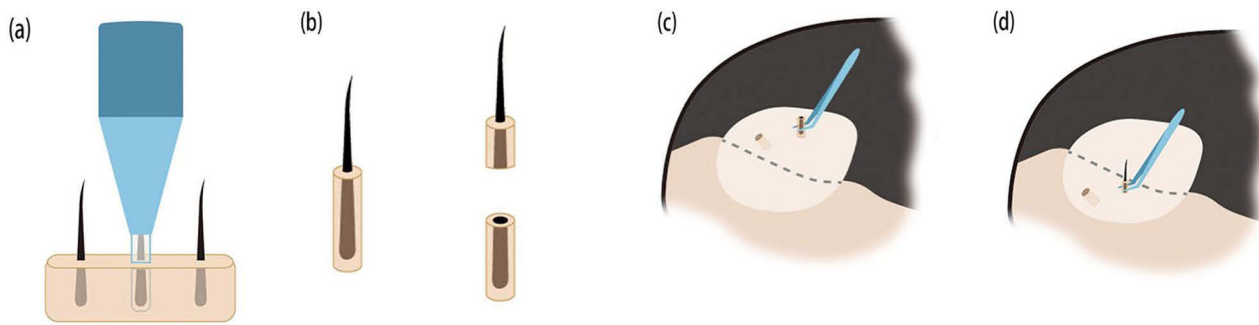


Figure 1 Schematic drawing illustrating transversely sectioned mini-punch grafting. (a) Mini-punch grafts extracted from donor sites similar to follicular unit extraction. (b) The grafts transversely sectioned. (c) The intact half follicles placed in the recipient sites of the hairy areas within the hairline. (d) The sectioned mini-punch grafts with the half hair follicles removed to place in the recipient sites of the forehead outside the hairline.

stable vitiligo patients suggests that ultraviolet radiation stimulates melanocyte migration into the vitiliginous skin, increasing repigmentation.¹¹

One of the major treatment methods for hairy areas or vitiligo on the hairline is mini-punch grafting. However, hairline vitiligo is a special area. Hairy areas within the hairline often require repigmentation and regrowing hair shafts. The face and forehead outside the hairline do not require regrowing hair shafts, only repigmentation. The donor sites for hairy areas within the hairline were the scalp region, and for the face and forehead, the postauricular region served as a donor site outside the hairline. This step in two different ways for mini-punch grafting is time-consuming and increased adverse events. To tackle this issue, we modified the conventional mini-punch grafting with a combined application of mini-punch grafting and hair follicular grafting (Figure 1a–d). In such cases, the transversely sectioned mini-punch grafting might be advantageous.

Methods

Five patients with localized hairline stable vitiligo aged 26–32 years old had a history of nonsurgical treatments for at least 3 months and without progress. Patients with active vitiligo that is progressing, infections at the transplant recipient's site, and a history of conditions such as keloids or infectious illnesses were excluded. The treatment using transversely sectioned mini-punch grafting was performed for all five patients. The technique was approved by the ethical committee of Wenzhou Hospital of Integrated Traditional Chinese and Western Medicine.

The technique of a typical case as an example was described as follows. A male patient aged 30 had a 3-year history of hairline vitiligo (Figure 2a). Despite the fact that the patient had undergone topical immunosuppressants, phototherapy, and 308nm light treatment, there were no obvious improvements in his symptoms. The vitiligo lesion has no progression. The patient has no family history of similar conditions. There were no lesions in other areas. In a similar manner to follicular unit extraction, punch grafts were performed by loading 0.8 mm punches into the handpiece of the equipment FUEPK-7000 (LeadM, Korea). The donor site was the scalp region. Following adequate skin preparation and local anesthesia, the skin was removed to create chambers for transplanting at 4–5 mm intervals, and some grey hairs were extracted from the hairline vitiligo. The grafts were transversely sectioned, parallel to the epidermal surface (Figure 2b). The intact half follicles were preserved below the cross-section. Above the cross-section, the sectioned mini-punch grafts were with the half hair follicles removed. Sectioned grafts were placed into the chambers for transplanting with forceps (Figure 2c). The intact half follicles were placed in the recipient sites of the hairy areas within the hairline. Correspondingly, the sectioned mini-punch grafts with the half hair follicles removed were placed in the recipient sites of the forehead outside the hairline. Neither donor nor recipient sites had the infection, scarring, or cobblestone appearance. The scabs dropped within 7–12 days. Repigmentation begins in approximately 3–4 weeks, the next stage of subsequent treatments can be initiated. Three weeks after surgery, in the area of the forehead outside the hairline with the sectioned mini-punch grafting above the cross-section, hair loss and repigmentation were observed. In the area of the hairy areas within the hairline, growing hair shafts and repigmentation were observed, without hair loss (Figure 2d). The

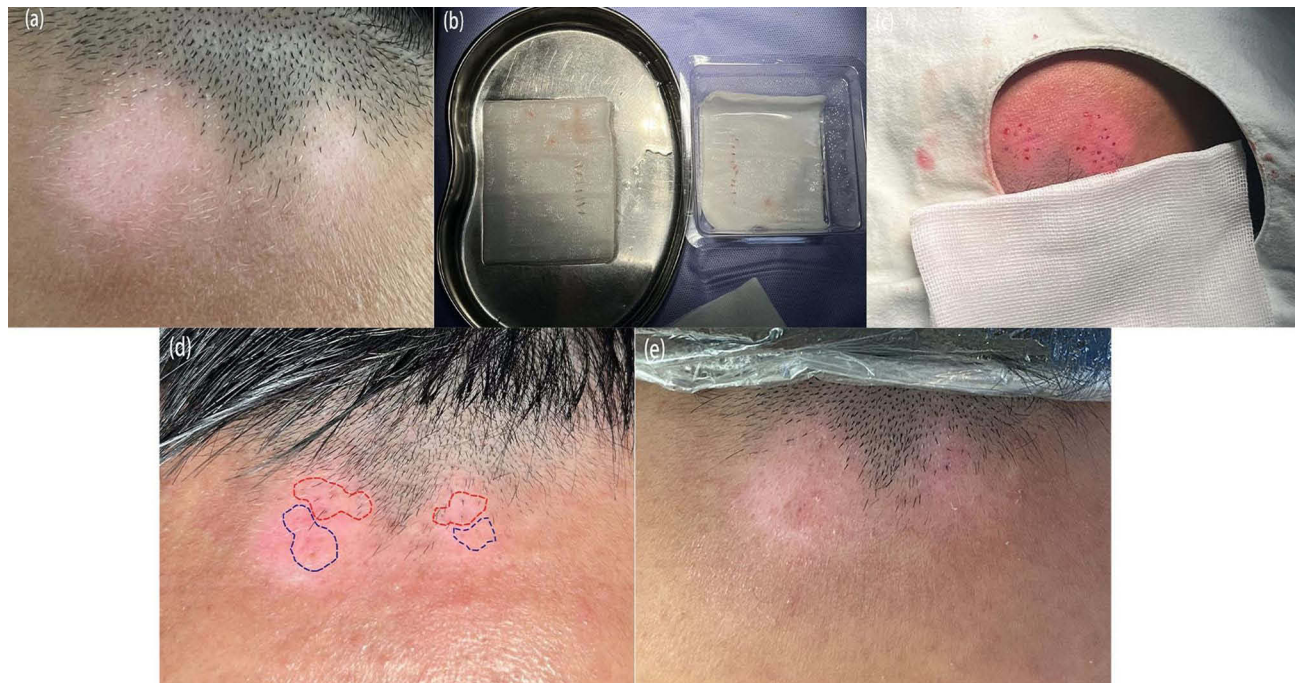

Figure 2 A case of hairline vitiligo. (a) Preoperative view. (b) Place the sectioned grafts separately. (c) The intact half follicles to the hairy areas within the hairline, and the sectioned mini-punch grafts with the half hair follicles removed to the forehead outside the hairline. (d) Hair loss and repigmentation were observed in the area of the forehead outside the hairline (the blue dashed circles). In the area of the hairy areas within the hairline, growing hair shafts and repigmentation were observed, without hair loss (the red dashed circles). (e) Followed up with calcipotriol and betamethasone ointment. Significant improvement after 7 weeks of the sectioned mini-punch grafting.

patient was followed up with calcipotriol and betamethasone ointment, and significant improvement after 7 weeks (Figure 2e).

Results and Discussion

The results of the treatment using transversely sectioned mini-punch grafting were satisfactory for all five patients. Follow-up was for 3 months or longer. The sites had good outcomes without complications. Cobblestone appearance was not observed. All patients were satisfied with the repigmentation of vitiligo and followed up with a treatment of excimer light (308 nm) or calcipotriol and betamethasone ointment.

Mini-punch grafting has built its advantage as easy and fast.¹² Melanocytes migrate from the graft edge to recolonize and reconstruct the area.¹³ Mini-punch grafting has been evaluated in a variety of ways and more studies have been conducted over the years.¹⁴ In the direction of hair follicle transplantation, testing the soundness of this approach experimentally using transversely sectioned hair follicles.¹⁵ A study to compare the cosmetic efficacy of the transplantation of follicles with intact and non-intact hair bulbs in the treatment for vitiligo showed that single follicle transplantation was an alternative effective choice.¹⁶

In our study, the intact half follicles were preserved below the cross-section. The use of the sectioned mini-punch grafts above the cross-section took advantage of mini-punch grafting, and the use of the sectioned mini-punch grafts below the cross-section was considered as hair follicle transplantation. The supply of one hair follicle completed the transplantation for two purposes. This technique combined the advantages of mini-punch grafting and hair follicle transplantation, reduced operative time, steps of the procedure, and areas and parts of the donor site. The technique is an effective, safe, and inexpensive method of surgical repigmentation. It is the sample size that limits the technique. The sectioned mini-punch grafting and other treatments followed up may be difficult in the absence of uniform evaluation criteria. The color match needs to be evaluated separately at different stages of treatment. The evaluation criteria may be considering color match, growing hair shafts or hair loss, and the complications of both the donor and the recipient areas,

all taken together. The study with the subsequent treatments needs further examination such as reflectance confocal microscopy, and combination therapy may need to be explained further.

Conclusion

Our report can help to manage hairline vitiligo or hairy areas vitiligo. This method can be considered a potential method for the treatment of hairline vitiligo, thus providing a simple solution to complex problems. However, more abundant evidence and research are needed to indicate the efficacy of the transversely sectioned mini-punch grafting for hairline vitiligo or hairy areas vitiligo.

Ethical Approval

All procedures were performed in accordance with the Helsinki Declaration and the approval has been granted by the ethics committee of Wenzhou Hospital of Integrated Traditional Chinese and Western Medicine (2022007).

Informed Consent

Written informed consent was obtained from the patient for publishing all photographic materials.

Disclosure

The authors report no conflicts of interest in this work.

References

1. Shahbazi A, Zargar SJ, Aghdami N, Habibi M. The story of melanocyte: a long way from bench to bedside. *Cell Tissue Bank*. 2023. doi:10.1007/s10561-023-10081-5
2. Hirobe T, Enami H. Reduced elastin fibers and melanocyte loss in vitiliginous skin are restored after repigmentation by phototherapy and/or autologous minigraft transplantation. *Int J Mol Sci*. 2022;23(23):15361. doi:10.3390/ijms232315361
3. Zhang M, Xia T, Lin F, et al. Vitiligo: an immune disease and its emerging mesenchymal stem cell therapy paradigm. *Transpl Immunol*. 2023;76:101766. doi:10.1016/j.trim.2022.101766
4. Xie Y, Xu Z, Shi W, Mei X. Biological function and application of melanocytes induced and transformed by mouse bone marrow mesenchymal stem cells. *Regen Ther*. 2022;21:148–156. doi:10.1016/j.reth.2022.06.007
5. Nilforoushzadeh MA, Nouri M, Alavi S, et al. Combination of epidermal keratinocyte-melanocyte cells suspension and microneedling: safe surgical approach in vitiligo. *J Cosmet Dermatol*. 2022;21(10):4669–4676. doi:10.1111/jocd.14987
6. Erdoğan A, Mutlu HS, Solakoğlu S. Autologously transplanted dermis-derived cells alleviated monobenzene-induced vitiligo in mouse. *Exp Dermatol*. 2022;31(9):1355–1363. doi:10.1111/exd.14603
7. Kawakami T. Surgical procedures and innovative approaches for vitiligo regenerative treatment and melanocytorrhagy. *J Dermatol*. 2022;49(4):391–401. doi:10.1111/1346-8138.16316
8. Ezz-Eldawla R, Abu El-Hamd M, Saied SM, Hassanien SH. A comparative study between suction blistering graft, mini punch graft, and hair follicle transplant in treatment of patients with stable vitiligo. *J Dermatolog Treat*. 2019;30(5):492–497. doi:10.1080/09546634.2018.1528329
9. Wu Y, Dai Y, Wang T, Jin H, Peng J, Xu A. The application of electrolysis of depigmented hair using a trichiasis electrolyzer combined with single hair follicle transplantation for the treatment of vitiligo-associated leukotrichia. *Dermatol Ther*. 2022;35(5):e15400. doi:10.1111/dth.15400
10. McCrary MR, Gibbs DC, Alharthi M, Krueger LD. Utilization of our toolkit: a systematic review and meta-analysis of surgical therapies in vitiligo treatment. *Dermatol Surg*. 2022;48(8):815–821. doi:10.1097/DSS.0000000000003503
11. Linthorst Homan MW, Spuls PI, Nieuweboer-Krobotova L, et al. A randomized comparison of excimer laser versus narrow-band ultraviolet B phototherapy after punch grafting in stable vitiligo patients. *J Eur Acad Dermatol Venereol*. 2012;26(6):690–695. doi:10.1111/j.1468-3083.2011.04147.x
12. Lahiri K. Evolution and evaluation of autologous mini punch grafting in vitiligo. *Indian J Dermatol*. 2009;54(2):159–167. doi:10.4103/0019-5154.53195
13. Billingham RE, Silvers WK. Studies on the migratory behavior of melanocytes in Guinea pig skin. *J Exp Med*. 1970;131(1):101–117. doi:10.1084/jem.131.1.101
14. Mokhtar M, El-Ashmawy AA, Mostafa WA, Gamei MM. Clinical and dermoscopic evaluation of follicular unit transplantation vs. Mini-Punch grafting in the repigmentation of resistant and stable vitiligo: a comparative study. *J Cosmet Dermatol*. 2022;21(11):5837–5851. doi:10.1111/jocd.15127
15. Rapisio E, Filippi F, Levi G, Nordström RE, Santi P. Follicular bisection in hair transplantation surgery: an in vitro model. *Plast Reconstr Surg*. 1998;102(1):221–226. doi:10.1097/00006534-199807000-00036
16. Chen Y, Yan J, Chen X, et al. Comparative study between follicular unit transplantation with intact and non-intact hair bulb in treatment for stable vitiligo. *J Dermatolog Treat*. 2022;33(2):818–821. doi:10.1080/09546634.2020.1782320

Clinical, Cosmetic and Investigational Dermatology

Dovepress

Publish your work in this journal

Clinical, Cosmetic and Investigational Dermatology is an international, peer-reviewed, open access, online journal that focuses on the latest clinical and experimental research in all aspects of skin disease and cosmetic interventions. This journal is indexed on CAS. The manuscript management system is completely online and includes a very quick and fair peer-review system, which is all easy to use. Visit <http://www.dovepress.com/testimonials.php> to read real quotes from published authors.

Submit your manuscript here: <https://www.dovepress.com/clinical-cosmetic-and-investigational-dermatology-journal>