

# Tofacitinib for the Treatment of Psoriasiform Dermatitis Caused by IL-17 Inhibitors: A Case Report

Nan Luo , Lingyuan Zhong, Nana Luo , Qiuyue Wang, Tianhao Li, Pingsheng Hao 

Department of Dermatology, Hospital of Chengdu University of Traditional Chinese Medicine, Chengdu, People's Republic of China

Correspondence: Pingsheng Hao; Tianhao Li, Department of Dermatology, Hospital of Chengdu University of Traditional Chinese Medicine, No. 39 Shi-er-qiao Road, Chengdu, Sichuan, 610075, People's Republic of China, Tel +86-13881965024; +86-13880986337, Fax +86-28-87732407, Email hpswl@126.com; litanhao\_doctor@163.com

**Abstract:** Psoriasis is a recurring systemic disease that can be treated with biologics to some effect. However, precisely targeting inflammatory mediators may disrupt immune system homeostasis and lead to new conditions. Here, we report a case of psoriasiform dermatitis (PsoD) caused by IL-17 inhibitors (IL-17i) namely secukinumab treatment for psoriasis. This case proposes an effective use of Janus kinase inhibitor (JAKi) tofacitinib to confront lesions induced by IL-17i. This is the first case report of PsoD caused by secukinumab treated with tofacitinib.

**Keywords:** tofacitinib, Janus kinase inhibitor, psoriasiform dermatitis, Th1-Th2 balance, IL-17 inhibitors

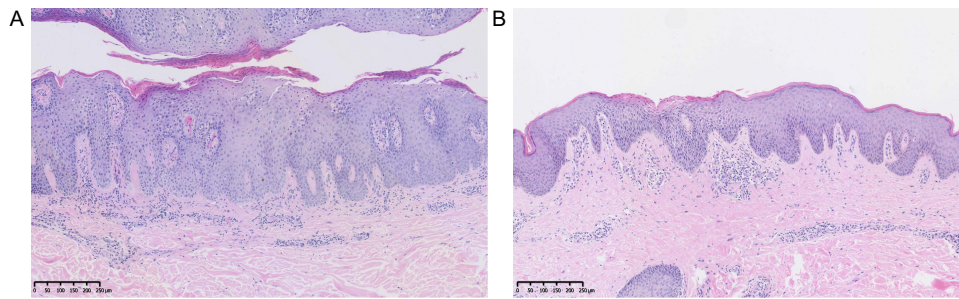
## Introduction

Psoriasis is an inflammatory-immune chronic disease that has been treated by biologics with immediate efficacy. However, its high targeting of one inflammatory mediator may break the immune system homeostasis by multiple cytokines, resulting in new diseases or other clinical and immunological responses. Herein, we report a case on treating PsoD caused by IL-17i via a JAKi tofacitinib. With this case, we aim to offer clinicians a potentially optimal choice to face the Th1-Th2 imbalance likely caused by IL-17i.<sup>1</sup>

## Case Description

A 28-year-old male with psoriasis, which had failed to respond to topical agents, acitretin, and UV light for 3 years, cleared completely 4 weeks after starting on IL-17i, secukinumab. The patient had a biopsy of the back lesions before using secukinumab and was diagnosed with psoriasis (Figure 1A). At this point, plasma concentrations of cytokine: IFN- $\gamma$ : 109.72 pg/mL (normal range < 7.42 pg/mL), IL-17A: 5.64 pg/mL (normal range < 2.90 pg/mL). However, after 8 months of secukinumab treatment, he developed erythema, lichenification, and intense itching. They were mainly on the trunk and in skin folds such as the groin and axillary (Figure 2A1–D1). During this period, the patient did not use any other medication.

Laboratory test results were as follows: cytokine detection: IL-4: 3.85 pg/mL (normal range < 2.80 pg/mL), IL-6: 317.54 pg/mL (normal range < 5.30 pg/mL), IL-10: 1.15 pg/mL (normal range < 4.91 pg/mL). Inguinal skin cells were repeatedly cultured, with only the growth of *Staphylococcus aureus* but no fungus. No abnormality was found in the hemogram, hepatic and renal function, hemostasis, humoral immunity, autoimmune antibody profile, and T-SPOT.TB test. The skin tissues of the groin were embedded in paraffin for hematoxylin-eosin (H&E) staining. The biopsy specimens showed: (i) epidermal hyperkeratosis with mild focal parakeratosis; (ii) acanthosis with spongiosis; (iii) lymphocytes and little eosinophils infiltrating around the small vessels (Figure 1B). It represents an overlapping histopathological feature of psoriasis and dermatitis. The patient has no family history of psoriasis, atopic dermatitis, or eczema. Eventually, the disease was diagnosed as PsoD.



**Figure 1** Histopathology (H&E) of skin. **(A)** A biopsy of the back lesions before using secukinumab describes features of psoriasis, including epidermal hyperkeratosis and acanthosis with elongation of the rete ridges. **(B)** Skin biopsy pathology of the groin after 8 months of secukinumab treatment illustrates epidermal hyperkeratosis, spongiosis, and a little eosinophil.

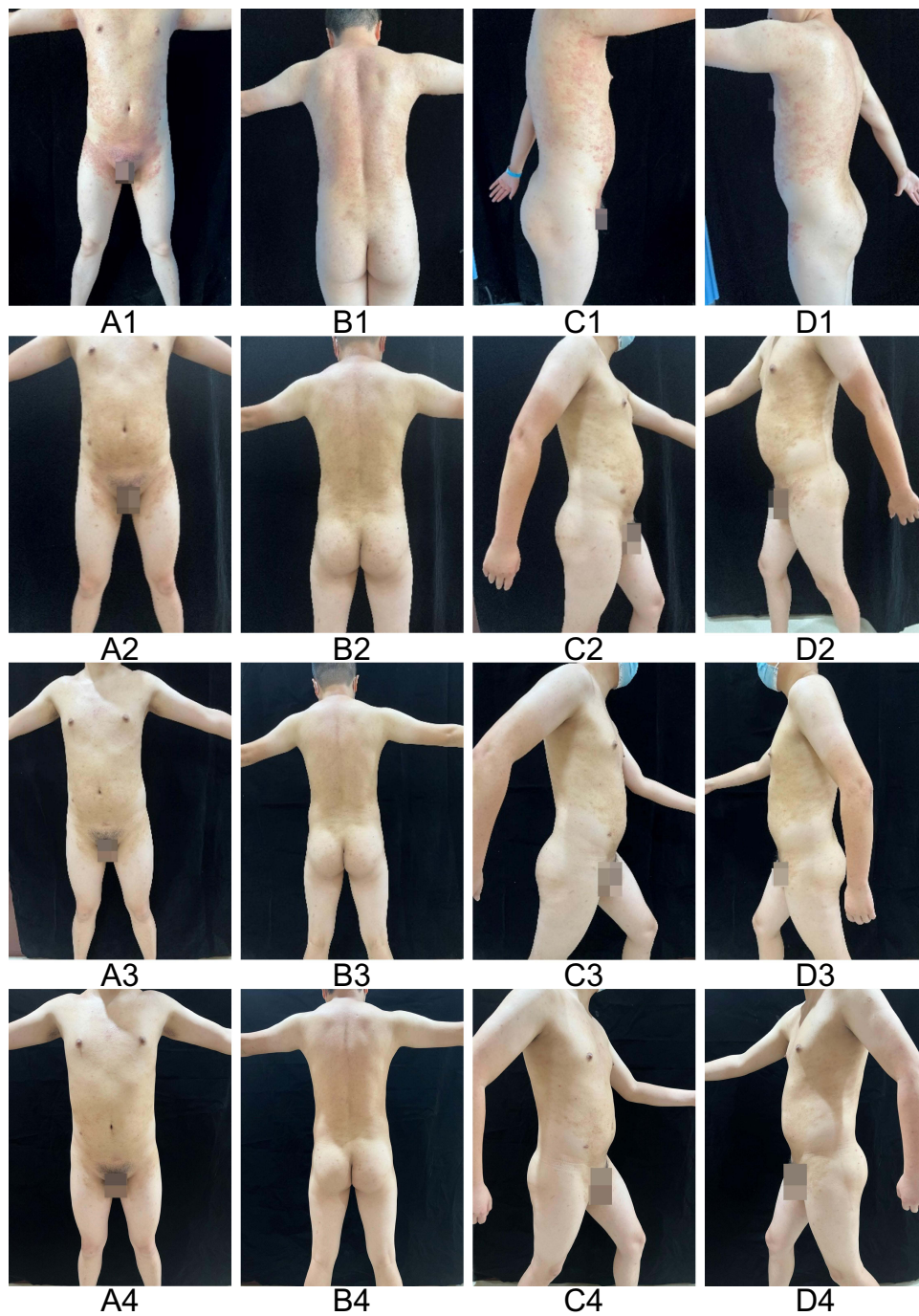
We stopped secukinumab and started to use systemic therapy, which included glycyrrhizic acid, vitamin C, calcium gluconate, rupatadine fumarate, ebastine, and methotrexate. However, the patient's symptoms did not improve significantly. We then treated him with tofacitinib and discontinued all other treatments. Then, the patient started follow-up in the clinic once a week due to work. One week later, the lesions became smaller, lighter, and pruritus-free (Figure 2A2–D2). Referring to the dosage of tofacitinib in treating immune-mediated inflammatory diseases,<sup>2</sup> we use tofacitinib for six weeks, including 5mg bid for the first four weeks and 5mg qd for the last two weeks. After six weeks, the patient's lesions remained only hyperpigmented, without new lesions (Figure 2A3–D3). We rechecked the blood cytokine and found no abnormalities. Three months after stopping secukinumab treatment, the patient relapsed psoriasis on the scalp. We successfully relieved the lesions with topical 0.005% calcipotriene for 2 weeks. In 3 months of follow-up after discontinuation of tofacitinib, we observed no adverse effects or recurrence of PsoD (Figure 2A4–D4). The patient was very satisfied with both tofacitinib and calcipotriene treatment. The timeline of this case report is shown in Figure 3.

## Discussion

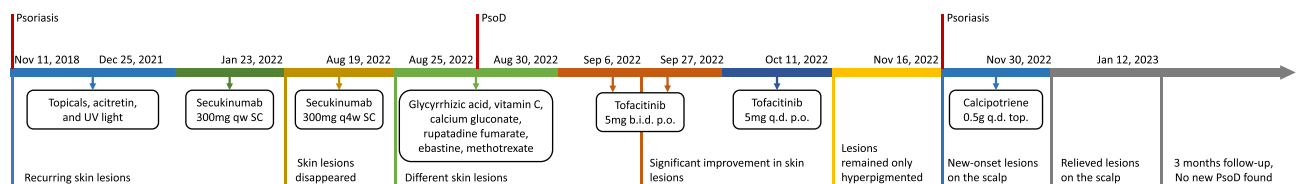
No single and accurate guide has been used to diagnose PsoD. Currently, PsoD is considered a skin disease characterized by redness and irritation, mainly in thickened, red skin and flaky, silvery-white patches or scales. Eczema is a common inflammatory skin disease characterized by pruritus and pleomorphic skin lesions (such as erythema, blisters, lichenification, etc.). The skin lesions after scratching often show overlapping clinical manifestations, resulting in a confusing diagnosis. Histopathology is the gold standard for differentiating them. When the course of eczema is prolonged, acanthosis and focal parakeratosis can also occur. Eczema is characterized by the spongiotic tissue reaction pattern, whereas PsoD is hyperkeratosis and parakeratosis, with irregular acanthosis and mild spongiosis.<sup>3</sup>

Biologics have made significant progress in treating psoriasis, but targeting a single cytokine appears to lead to diminished efficacy and new diseases such as opportunistic infections, tuberculosis, eczema, etc. Because of immunogenicity, biologics are more prone to immune-related adverse events than small-molecule drugs.<sup>4</sup>

It was reported that patients with psoriasis developed Th2-dominant atopic dermatitis and dyshidrotic eczema after secukinumab treatment.<sup>5,6</sup> Parker et al described the development of PsoD in children with atopic dermatitis following the use of dupilumab.<sup>7</sup> Ishiuchi et al reported the aggravation of atopic dermatitis symptoms by ustekinumab in patients with psoriasis.<sup>8</sup> In a retrospective review of 51 patients with psoriasis, the adverse event of eczema occurring with adalimumab 40 mg every other week was 2, or about 3.9%.<sup>9</sup> These lead us to venture the inference that the interconversion of the two classes of disease is most likely related to the Th1/Th2 bias caused by biologics. In this case, the patient developed PsoD on secukinumab, which may be related to anti-IL-17A treatment blocking the Th1/17 pathway, leading to an imbalance in the Th1-Th2 immune response and toward the Th2 pathway, which plays a dominant role in PsoD.<sup>3</sup> In cytokine detection, a decrease in Th1 (IFN- $\gamma$ ), an increase in Th2 (IL-4, IL-6, and IL-10), and a decrease in Th17 (IL-17A) also support our hypothesis. Additionally, anti-IL-17A treatment may induce overexpression of other isoforms (eg, IL-17C),<sup>10</sup> which appears to trigger an autocrine cycle to stimulate keratinocytes and may be involved in Th2- and Th17-mediated inflammatory skin inflammation that occurs in PsoD. In immune defense, IL-17

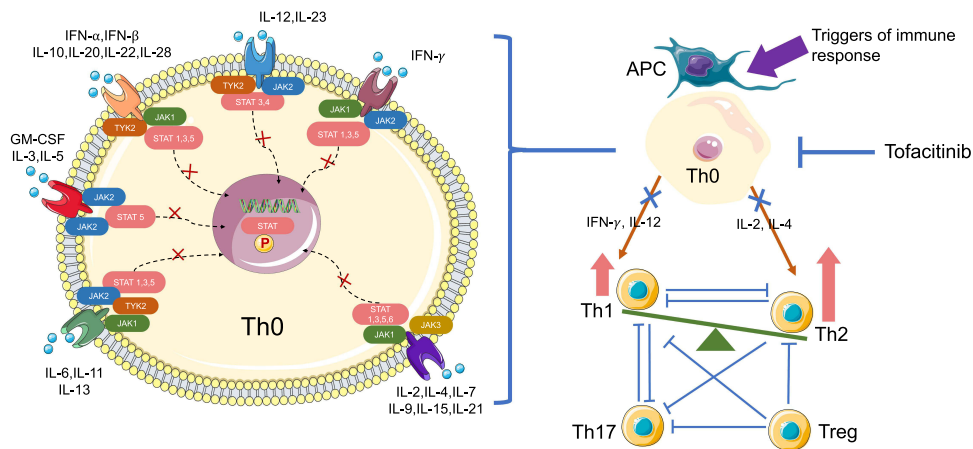


**Figure 2** Skin lesions change during tofacitinib treatment. (A1–D1) Before tofacitinib treatment. (A2–D2) After one week’s treatment. (A3–D3) After six weeks of treatment. (A4–D4) In 3 months of follow-up after discontinuation of tofacitinib.



**Figure 3** Timeline of the pathological/skin lesion diagram, diagnosis, and their management during the treatment.

**Abbreviations:** PsoD, psoriasisiform dermatitis; UV, Ultraviolet; b.i.d., twice daily (bis in die); q.d., every day (quaque die); qw, once a week; q4w, once every 4 weeks; SC, subcutaneous; p.o., by mouth or orally (per os); top., topical.



**Figure 4** Potential mechanism of tofacitinib for the treatment of PsO caused by secukinumab. JAKs phosphorylate tyrosine residues on the cytokine receptors, leading to the recruitment and phosphorylation of STATs. Phosphorylated STATs dimerize and translocate to the nucleus, where they promote gene transcription. Tofacitinib binds to JAK, prevents downstream gene transcription, and differentially reduces cytokines production to regulate the differentiation of Th0 to Th cells to varying degrees. In this case, Tofacitinib restores the Th1-Th2 balance by inhibiting T cell differentiation and suppressing Th2 more than Th1 in the treatment of Th2-dominant PsO. In this process, different Th cell subsets interacted with each other.

**Abbreviations:** JAK, Janus kinase; STAT, signal transducer and activator of transcription; TYK, tyrosine kinase; P, phosphorylation; IL, interleukin; IFN, interferon; GM-CSF, granulocyte macrophage colony stimulating factor; APC, antigen-presenting cell; Th0, naive T cell; Th, helper T cell; Treg, regulatory T cell; red arrows, inhibitory.

also plays a crucial role by inducing and enhancing the infiltration of neutrophils into infected tissue sites, however, anti-IL-17A treatment may block this process.<sup>11,12</sup>

The Janus kinase/signal transducer and activator of the transcription (JAK/STAT) pathway play an important role. Different combinations of JAK and STAT regulate the proliferation and differentiation of T cells toward Th1 / Th2 / Th17 / regulatory T cells (Tregs) by binding cytokines to specific cell surface receptors.<sup>13</sup> Tofacitinib, the first generation of the pan-JAKi, reduces the production of most cytokines and the differentiation of naïve T (Th0) cells. Tofacitinib is predominantly a JAK1/JAK3 inhibitor, with some activity against JAK2 and less activity against tyrosine kinase 2 (TYK2). So tofacitinib has a greater inhibitory effect on JAK1/JAK3 binding  $\gamma$ -chain cytokines, such as IL-2, IL-4, IL-7, IL-9, IL-15, and IL-21. In contrast, tofacitinib blocked IFN- $\gamma$ , which binds JAK1/JAK2, and IL-12, which binds JAK2/TYK2, to a relatively lesser extent. In peripheral blood from patients with rheumatoid arthritis, the inhibitory potency of tofacitinib also varied for different cytokines. In CD4+ T cells, the average inhibition was 60% for IL-2, 53% for IL-4, 49% for IFN- $\gamma$ , and only 19% for IL-10.<sup>14</sup> In addition, T cell differentiation is also influenced by several cytokines. Th1 cell differentiation is mainly driven by IFN- $\gamma$  and IL-12; Th2 cell differentiation is mainly driven by IL-2 and IL-4; Th17 cell differentiation is mainly driven by TGF- $\beta$  and IL-6; Treg differentiation is mainly driven by TGF- $\beta$  and IL-12.<sup>15</sup> And tofacitinib is mainly a JAK1/JAK3 inhibitor, suggesting that its inhibition of Th2 via IL-2 and IL-4 is most likely greater than that of Th1 via IFN- $\gamma$  and IL-12. In this case, tofacitinib successfully treated PsO, and the most likely reason is that tofacitinib may have restored the Th1-Th2 balance by inhibiting T cell differentiation to varying degrees and eliminating Th cell bias (Figure 4).

Tofacitinib has also been studied to treat Th17-dominant palmoplantar pustulosis combined with Th1-dominant rheumatoid arthritis by modulating Th cell differentiation,<sup>16</sup> which is where its use could be expanded. In addition, long-term usage of tofacitinib may induce infections, cytopenias, and thromboembolism. These are standard lines we need to draw in rational clinical utilization. As a case report, it has some limitations. First, it lacks evidence-based medical evidence; second, the mechanism of tofacitinib for the treatment of PsO induced by IL-17i is stuck in theoretical analysis, and more clinical evidence is needed to support the idea, and further basic research is necessary.

## Conclusion

Administration of IL-17i leads to PsO, and its mechanism may be related to the Th1-Th2 imbalance caused by secukinumab. Tofacitinib, a small molecule JAKi, is one of the possible options for related diseases. Nevertheless, the safety of tofacitinib requires more clinical cases and basic research.

## Abbreviations

PsoD, psoriasisiform dermatitis; IL-17i, IL-17 inhibitors; JAKi, Janus kinase inhibitor; UV, Ultraviolet; Th cell, T helper cell; JAK/STAT, Janus kinase/signal transducer and activator of transcription; Tregs, regulatory T cells.

## Data Sharing Statement

The data that support the findings of this study are available from the corresponding author (Pingsheng Hao) upon request.

## Ethical Approval and Consent to Participate

The study was approved by the Ethics Committee of Hospital of Chengdu University of Traditional Chinese Medicine. Written informed consent was obtained from the patient for the publication of all the images and data included in this article. Ethical review and approval were not required to publish the case details in accordance with the institutional requirements.

## Consent to Publish

The patient has consented to the submission of the case report to the journal.

## Acknowledgments

First and foremost, thanks to the Sichuan Provincial Health Commission for providing financial support. Secondly, I would like to thank Dr. Tianhao Li for his guidance. Finally, I would like to pay the highest respect to my mentor, Pingsheng Hao, for his excellent advice and respectful teaching.

## Author Contributions

Pingsheng Hao serves as the primary corresponding author for this paper, while Tianhao Li acts as the secondary corresponding author. All authors made a significant contribution to the work reported, whether that is in the conception, study design, execution, acquisition of data, analysis and interpretation, or in all these areas; took part in drafting, revising or critically reviewing the article; gave final approval of the version to be published; have agreed on the journal to which the article has been submitted; and agree to be accountable for all aspects of the work.

## Funding

This work was supported by the Program of Health Commission of Sichuan Province (Grant No. Chuan-2021-505). And preparation and development of medicated bath Wupi effervescent tablets for senile skin pruritus.

## Disclosure

The authors report no conflicts of interest in this work.

---

## References

- Berger A. Science commentary: Th1 and Th2 responses: what are they? *BMJ*. 2000;321(7258):424. doi:10.1136/bmj.321.7258.424
- Nash P, Kerschbaumer A, Dörner T, et al. Points to consider for the treatment of immune-mediated inflammatory diseases with Janus kinase inhibitors: a consensus statement. *Ann Rheum Dis*. 2021;80(1):71–87. doi:10.1136/annrheumdis-2020-218398
- Cohen JN, Bowman S, Laszik ZG, North JP. Clinicopathologic overlap of psoriasis, eczema, and psoriasisiform dermatoses: a retrospective study of T helper type 2 and 17 subsets, interleukin 36, and  $\beta$ -defensin 2 in spongiotic psoriasisiform dermatitis, sebopsoriasis, and tumor necrosis factor  $\alpha$  inhibitor-associated dermatitis. *J Am Acad Dermatol*. 2020;82(2):430–439. doi:10.1016/j.jaad.2019.08.023
- Shankar G, Shores E, Wagner C, Mire-Sluis A. Scientific and regulatory considerations on the immunogenicity of biologics. *Trends Biotechnol*. 2006;24(6):274–280. doi:10.1016/j.tibtech.2006.04.001
- Bose R, Beecker J. Dyshidrotic eczema in two patients on secukinumab for plaque psoriasis: a case report. *SAGE Open Med Case Rep*. 2020;8:2050313x20904561. doi:10.1177/2050313X20904561
- Mendes Roncada EV, Brambilla VR, Freitas Filitto B, Genta MP, Morgado de Abreu MAM. Atopic dermatitis as a paradoxical effect of secukinumab for the treatment of psoriasis. *Case Rep Dermatol*. 2021;13(2):336–339. doi:10.1159/000513467
- Parker JJ, Sugarman JL, Silverberg NB, et al. Psoriasisiform dermatitis during dupilumab treatment for moderate-to-severe atopic dermatitis in children. *Pediatr Dermatol*. 2021;38(6):1500–1505. doi:10.1111/pde.14820

8. Ishiiji Y, Umezawa Y, Asahina A, et al. Exacerbation of atopic dermatitis symptoms by ustekinumab in psoriatic patients with elevated serum immunoglobulin E levels: report of two cases. *J Dermatol*. 2018;45(6):732–734. doi:10.1111/1346-8138.14295
9. Chiu HY, Wang TS, Chang CY, Tsai TF. The effectiveness and safety of Adalimumab in the treatment of non-reimbursed patients with mild-to-moderate psoriasis. *J Eur Acad Dermatol Venereol*. 2012;26(8):991–998. doi:10.1111/j.1468-3083.2011.04199.x
10. Chang SH, Reynolds JM, Pappu BP, Chen G, Martinez GJ, Dong C. Interleukin-17C promotes Th17 cell responses and autoimmune disease via interleukin-17 receptor E. *Immunity*. 2011;35(4):611–621. doi:10.1016/j.immuni.2011.09.010
11. Joulia R, Guerrero-Fonseca IM, Girbl T, et al. Neutrophil breaching of the blood vessel pericyte layer during diapedesis requires mast cell-derived IL-17A. *Nat Commun*. 2022;13(1):7029. doi:10.1038/s41467-022-34695-7
12. Liu R, Lauridsen HM, Amezcua RA, et al. IL-17 promotes neutrophil-mediated immunity by activating microvascular pericytes and not endothelium. *J Immunol*. 2016;197(6):2400–2408. doi:10.4049/jimmunol.1600138
13. O’Shea JJ, Murray PJ. Cytokine signaling modules in inflammatory responses. *Immunity*. 2008;28(4):477–487. doi:10.1016/j.immuni.2008.03.002
14. Palmroth M, Kuuliala K, Peltomaa R, et al. Tofacitinib suppresses several JAK-STAT pathways in rheumatoid arthritis in vivo and baseline signaling profile associates with treatment response. *Front Immunol*. 2021;12:738481. doi:10.3389/fimmu.2021.738481
15. Zhu J, Yamane H, Paul WE. Differentiation of effector CD4 T cell populations (\*). *Annu Rev Immunol*. 2010;28:445–489. doi:10.1146/annurev-immunol-030409-101212
16. Koga T, Sato T, Umeda M, et al. Successful treatment of palmoplantar pustulosis with rheumatoid arthritis, with tofacitinib: impact of this JAK inhibitor on T-cell differentiation. *Clin Immunol*. 2016;173:147–148. doi:10.1016/j.clim.2016.10.003

Journal of Inflammation Research

Dovepress

## Publish your work in this journal

The Journal of Inflammation Research is an international, peer-reviewed open-access journal that welcomes laboratory and clinical findings on the molecular basis, cell biology and pharmacology of inflammation including original research, reviews, symposium reports, hypothesis formation and commentaries on: acute/chronic inflammation; mediators of inflammation; cellular processes; molecular mechanisms; pharmacology and novel anti-inflammatory drugs; clinical conditions involving inflammation. The manuscript management system is completely online and includes a very quick and fair peer-review system. Visit <http://www.dovepress.com/testimonials.php> to read real quotes from published authors.

Submit your manuscript here: <https://www.dovepress.com/journal-of-inflammation-research-journal>