

# The Influence of Carboxytherapy on Scar Reduction

Anna Stolecka-Warzecha<sup>1</sup>, Łukasz Chmielewski<sup>2</sup>, Anna Deda<sup>3</sup>, Aleksandra Śmich<sup>1</sup>, Agata Lebedowska<sup>1</sup>, Sławomir Wilczyński<sup>1</sup>

<sup>1</sup>Department of Basic Biomedical Science, Faculty of Pharmaceutical Sciences in Sosnowiec, Medical University of Silesia, Katowice, Poland; <sup>2</sup>Department of Motion Organ Reconstruction Surgery, Provincial Specialist Hospital Megrez, Tychy, Poland; <sup>3</sup>Department of Cosmetology, Faculty of Pharmaceutical Sciences in Sosnowiec, Medical University of Silesia, Katowice, Poland

Correspondence: Anna Stolecka-Warzecha, Department of Basic Biomedical Science, Faculty of Pharmaceutical Sciences in Sosnowiec, Medical University of Silesia, Kasztanowa 3, Sosnowiec, 41-205, Poland, Tel +48 603 069 908, Email [astolecka@sum.edu.pl](mailto:astolecka@sum.edu.pl)

**Introduction:** Although it is not a new method, a carboxytherapy, which is based on intradermal or subcutaneous administration of controlled doses of CO<sub>2</sub>, is gaining more and more recognition among aesthetic medicine doctors, dermatologists and cosmetologists around the world. The consequence of applying carbon dioxide directly into tissues is associated with an immediate expansion of blood vessels, improvement of local blood supply, and, thus, tissue metabolism. It does also support natural regenerative processes. Oxygen and growth factors released from blood, within the area which undergoes treatment, stimulate fibroblasts to produce collagen and formation of new blood vessels also known as neovascularization. In addition to biochemical mechanisms, CO<sub>2</sub> injection into the dermis or subcutaneous tissue leads to a mechanical effect exerted by pressure and flow of CO<sub>2</sub> which is injected. It is of particular importance in scar treatments.

**Methods:** Twelve mature scars were subjected to the carboxytherapy which was performed in people aged 23–45 years. A small amount of heated, medical CO<sub>2</sub> was injected till the moment a scar turns white. The applied flow rate equalled 100 mL/min (cc/min). Before and after a series of four treatments, the level of hydration, elasticity and colour of the skin were measured. A structured-light 3D scanner was used to determine an exact morphology of the examined scars. The 3D scanning device is seen as a sensitive and precise method of qualitative and quantitative assessment of a morphology of scars.

**Results:** The results of the measurements performed showed a reduction in the surface of the analyzed changes, as well as proved the ability of CO<sub>2</sub> to rebuild collagen fibres. The decrease in value of parameters, which have been obtained thanks to the kutometric examination, indicates softening and loosening of connective tissue. It does confirm the effectiveness of carboxytherapy.

**Keywords:** carboxytherapy, scar, 3D scanner, cutometer

## Introduction

Scars are one of the most common aesthetic defects and a frequent cause evoking significant, psychological discomfort. For the time being, non-invasive methods used for scar reduction cannot solve the nature of the problem, while the use of invasive procedures, such as ablative lasers, is often associated with a long period of convalescence and emergence of numerous complications.<sup>1</sup> A carboxytherapy, which is based on intradermal or subcutaneous administration of controlled doses of CO<sub>2</sub>, is gaining more and more recognition among aesthetic medicine doctors, dermatologists and cosmetologists all over the world.<sup>2</sup> The beginning of a therapy based on carbon dioxide dates back to 1932, when CO<sub>2</sub> was used for medical purposes for the first time in the French health spa Royat.<sup>2–5</sup> Initially, this technique was used to treat circulatory disorders, as well as to support wound healing. Currently, it is widely applied in the therapy of psoriasis, ischemic heart disease, chronic venous insufficiency, Reynaud syndrome and migraines. Besides. It also has to be borne in mind that this method can also serve as a procedure to reduce scars and stretch marks.<sup>3</sup> Mechanical action of CO<sub>2</sub> induces an inflammatory process followed by a migration of fibroblasts to the area which is treated, as well as it stimulates a synthesis of collagen and other proteins of connective tissue. Ultimately, it leads to an increases in skin

elasticity. Previous works which tackled the subject of carboxytherapy showed an increase in skin elasticity occurring after a series of treatments, by approximately 55.5%.<sup>6</sup> In this respect, studies carried out by Paolo<sup>6</sup> in Brazil were important. They prove intensive reconstruction and thickening of collagen fibres as a result of intradermal injections of CO<sub>2</sub>, and, thus, confirm the use of this gas for reconstruction of collagen.<sup>6-8</sup> The consequence of administering carbon dioxide directly into tissues is immediate expansion of blood vessels resulting in improvement of local blood supply, and, thus, tissue metabolism. In addition, it also supports natural regenerative processes.<sup>8</sup> In the area which undergoes treatment, oxygen and growth factors released from blood<sup>1</sup> stimulate fibroblasts to produce collagen, as well as to form new blood vessels, ie, a process known as neovascularization.

Controlled injections of carbon dioxide into tissues provoke an acute inflammatory reaction characterized by peripheral vasodilatation and stimulation of cutaneous microcirculation, which increases local blood flow. A local increase in concentration of CO<sub>2</sub> and H<sup>+</sup> ions [hydrogen] in extracellular fluid causes immediate relaxation of smooth muscles [also translated as involuntary muscles] of blood vessels, which results in their temporary extension. It leads to better oxygenation and overall improvement of metabolism in tissues, and it constitutes one of the main mechanisms of carboxytherapy effects.<sup>2-5,8</sup> In addition, two reactions, ie, hypoxia and inflammation, resulting from administration of CO<sub>2</sub> into tissues, are considered a strong stimulus inducing neovascularization.<sup>10</sup>

The process of neovascularization may be stimulated by CO<sub>2</sub>, which leads to release of local growth factors (which are capable of exciting angiogenesis), ie, a vascular endothelial growth factor A (VEGF-A) and fibroblast growth factor (FGF).<sup>9-11</sup>

Daniela D'Arcangelo et al<sup>12</sup> demonstrated that acidifying tissues as a result of the increase in CO<sub>2</sub> concentration inhibits proliferation, migration and differentiation of endothelial cells into structures resembling capillaries, as well as it protects these cells from apoptosis. In hypoxic conditions due to carboxytherapy, the regulation of VEGF-A transcription is mediated by the binding of another transcription factor called the HIF-1 transcription factor. In addition, local lowering of the body's pH induced expression of VEGF-A and fibroblast growth factor (FGF); however, this mechanism was not dependent on HIF-1.<sup>13</sup>

It is suggested that a phenomenon of neovascularization of blood vessels depends on time. In practice, it means that there is a need to wait at least 7 days after the infusion of CO<sub>2</sub> in order to be able to see an increase in endothelial cell proliferation. Neovascularization occurs on condition that the pH of the tissue returns to its normal range.<sup>12</sup>

Despite the fact that there has not been any research which would support a hypothesis of mechanical CO<sub>2</sub> interaction, there is a large number of reports confirming the influence of mechanical forces on fibroblasts, keratinocytes and skin melanocytes. These cells, and in particular fibroblasts, are able to respond to mechanical signals through expression of many genes, as well as they are able to "convert" mechanical impulses into a series of biological responses leading to changes, eg, in connective tissue known for building scars.<sup>14</sup>

Fibroblasts release cytokines and growth factors. Besides the FGF mentioned earlier, they do also release the connective tissue growth factor (CTGF), which induces a process of collagen synthesis and proliferation of these cells. The ensuing changes include also growth and differentiation of keratinocytes as a result of keratinocyte growth factor (KGF) secreted by fibroblasts. Moreover, mechanical effect also stimulates a production of VEGF-A, which is the main regulator of the process of neof ormation of vascular and lymphatic vessels.<sup>15</sup>

Scar tissue can be defined as fibrous connective tissue developed in the place of an earlier injury which is formed as the final stage of a natural process of wound healing. The process itself can last, with phases of remodelling, up to several years. A collagen system is reorganized in the process of maturation stage, and in practice collagen fibres locate themselves along the line of the greatest skin tension. The scar which is being formed has a different structure from the normal skin structure, and its morphological image is determined by development of changes occurring within the area of an injured place. In the newly formed scar, capillaries grow in between collagen fibres and can persist up to 6 months from the moment of traumatization. A convex, red coloured structure gradually fades and turns into a white, flattened scar, as well as it is characterized by greater resistance to mechanical factors. However, it differs from the unaltered skin as it does not have appendages and has a different composition of collagen. Scar tissue approximately consists of 80% of type III collagen and 20% of type I collagen, while older scars and normal skin have an opposite proportion of these fibers (80% of type I and 20% of type III). The ensuing changes are regarded as normal. In turn, a disturbed course of natural wound healing may result in overgrowth of scars or formation of a keloid.<sup>16-18</sup>

The carboxytherapy, ie, a carbon dioxide therapy, constitutes an effective solution which enables to quickly and safely reduce visibility of scars. The associated side effects do not occur, or are minor. The most common complications include small bruises, observed in the areas of needle insertions, which eventually disappear after a few days without leaving any traces.<sup>3,5,19–21</sup>

## Materials and Methods

The study included 12 mature scars which had been formed at least 12 months before the carboxytherapy. The scars under study were identified in 10 volunteers aged 23–45.

Post-traumatic, post-operative scars and structures resulting from a scarring process occurring due to inflammatory acne vulgaris were analyzed. Table 1 shows a location and properties of all scars which were examined. None of the changes under consideration belonged to the keloid group (keloid scar).

In the case of long linear scars (B4, B7 and B8), parameters of hydration, chromophore concentration and elasticity were determined at several points along the long axis of the given scar (OX).

The statistical analysis was carried out using STATISTICA 13 software. The Wilcoxon signed-rank test was used for statistical analysis. Significance was set at  $p$  less than 0.05.

A prerequisite for qualifying volunteers to participate in the examination was exclusion of any kind of contraindications to implement the carboxytherapy. In addition, while undergoing the examination, the group was not subjected to any other methods aiming at reduction of evaluated scars. Carboxytherapy treatments were performed in the professional aesthetic medicine teaching hospital. The assessment of scars was carried out in the Department of Basic Biomedical Sciences at the Medical University of Silesia.

## Ethics Statement

The authors confirm that the ethical policies of the journal, as noted on the journal's author guidelines page, have been adhered to and the appropriate ethical review committee approval has been received. The study was conducted in accordance with the Declaration of Helsinki. The research obtained a positive opinion of the Ethics Committee of the SUM No. PCN/CBN/0022/KB1/27/III/16/17/21 on 29 June 2021. All participants were informed of the purpose of the study and signed a voluntary consent to participate in the study.

**Table 1** Indication, Location and Properties of the Analyzed Scars

| Indication | Location                 | Properties                              |
|------------|--------------------------|---|
| B1         | Back middle part         | Post-traumatic, slightly convex         |
| B2         | Acne scars on the cheeks | Atrophic of boxcar type                 |
| B3         | Abdomen left part        | Postoperative, hypertrophied            |
| B4         | Along the spine          | Post-traumatic, hypertrophied           |
| B5         | Left knee                | Post-traumatic, atrophic                |
| B6         | Right shoulder           | Post-traumatic, hypertrophied           |
| B7         | Forehead                 | Convex, posttraumatic, compact          |
| B8         | Abdomen Middle part      | Postoperative, slightly convex wyniosła |
| B9         | Lumbar spine             | Post-traumatic, atrophic                |
| B10        | Left buttock             | Post-traumatic, slightly convex         |
| B11        | Right shoulder blade     | Post-traumatic, hypertrophied           |
| B12        | Left shoulder            | Post-traumatic, atrophic                |

## Carboxytherapy

Certified medical carbon dioxide coming from the “LAPAROS” company was administered intradermally to the area of scars using the Carboxytherapy Dual MC4 device. This device was made available for research by SC Beauty Group sp. z o. o. company. The apparatus was calibrated to measure the dose of CO<sub>2</sub> in millilitres (cc) and allowed to control pressure and a rate of flow of the injected gas. Additionally, it was equipped with a microbiological filter and gas heating function in order to minimize unpleasant sensations which accompany the treatment. Needles of the following category and size, ie, 30G x 1/2 “, ø0.3 x 13mm (BD Microlance), were applied to perform injections. According to the standard procedure, a small amount of heated CO<sub>2</sub> was administered until a scar turns white. The flow rate equalled 100 cc/min which, in practice, does not exceed 1/10 of the maximum dose of 3000 mL of CO<sub>2</sub> that can be possibly injected during a single carboxytherapy treatment. The study included 4 sessions of treatments in total and was performed in 14-day intervals.

## Characterization of the Scars According to Physical Parameters

Features of the skin, such as the lubrication of the skin, hydration, elasticity, blood supply, extensibility, etc., can be measured in two ways: organoleptic and instrumental. Instrument measurements enable a broader and, above all, more accurate spectrum of skin properties identification.

The skin parameters, ie, a level of hydration, elasticity and colour were measured before the first treatment and 4–7 days after completing a series of four carboxytherapy procedures. Additionally, the alginate casts were made in order to identify morphometric parameters of scars.

The corneometer (Corneometer CM 825, Courage + Khazaka Electronic GmbH, Köln, Germany) was used to measure hydration of a thoroughly cleaned surface of the scar. This device measures the electrical capacity of the epidermis to determine its water content. An increase or decrease in the hydration of the stratum corneum causes proportional changes in electrical capacity, which are recorded by the device. The better the conductivity and the lower the resistance, the more water the stratum corneum contains. The results were interpreted in relative units in the following range: 0–130. Obtaining higher values indicates greater hydration of the skin.<sup>9</sup>

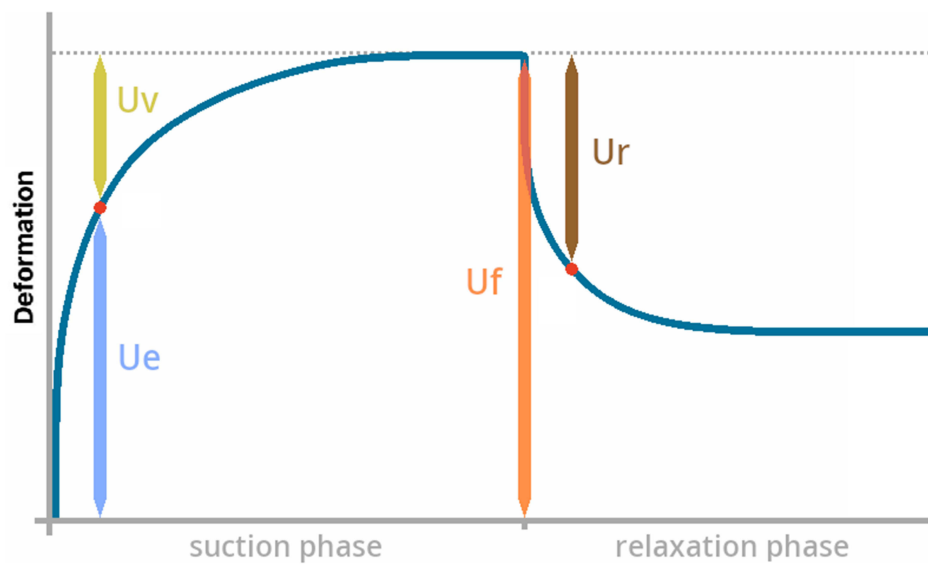
The mexameter (Mexameter MX 18, Courage + Khazaka Electronic GmbH, Köln, Germany) was used for examination of colors of scars before and after a series of carboxytherapy treatments. This device consists of a probe emitting light of a specific wavelength, which is absorbed by the chromophores present in the skin: melanin and hemoglobin, and a receiver measuring the amount of reflected radiation. Greater absorption indicates a darker skin color: higher concentration of melanin and hemoglobin.<sup>9</sup>

The cutometer (Cutometer MPA 580 Courage + Khazaka Electronic GmbH, Köln, Germany) was used in order to determine quantitative changes in biomechanical properties of scars, ie, elasticity and viscoelasticity. Its operation mechanism bases on the suction and expansion of the skin by the measuring probe. The resistance of the sucked skin and its ability to return to the starting position are assessed.<sup>9</sup>

All measurements were performed in a room with an ambient temperature of 20–21°C and air humidity of 55–66%. The probe, applied perpendicularly to the scar surface, sucked the skin with a negative pressure of 450 mbar. In a single measurement cycle, alternately sucking and extending the skin within the scar, lasting 2 seconds, was performed in 3 repetitions. The collected data were processed using the CutometerQ software (Courage+Khazaka Electronic GmbH, Köln, Germany) and visualized in the form of curves corresponding to the biomechanical properties of the skin.<sup>9</sup>

The analysis of biomechanical properties of scars which have been examined consisted in determining the following parameters (Figure 1): immediate (U<sub>e</sub>) and delayed (U<sub>v</sub>) skin distension; gross elasticity of the skin (U<sub>f</sub>), ie, the highest point of the curve; immediate retraction (U<sub>r</sub>).

A structured-light 3D scanner (Steinbichler Comet L3D, Neubeuern, Germany) was used to assess morphology of scar casts (made from alginate mass) in order to determine morphometric parameters of scars prior to the therapy and after a series of 4 carboxytherapy treatments. The resolution of the CCD matrix of the 3D scanner’s camera was 1600×1200 pixels. Measurement time was less than 1.5 s. The 3D scanning system, which was applied, is equipped with a replaceable optical head with a field of vision of 100x75x60 mm volume. Its point resolution is 60 µm with measurement accuracy of less than 8 µm. According to the calibration data, the measurement error of a single point was 4 µm. The data obtained in the form of a set of points was analyzed



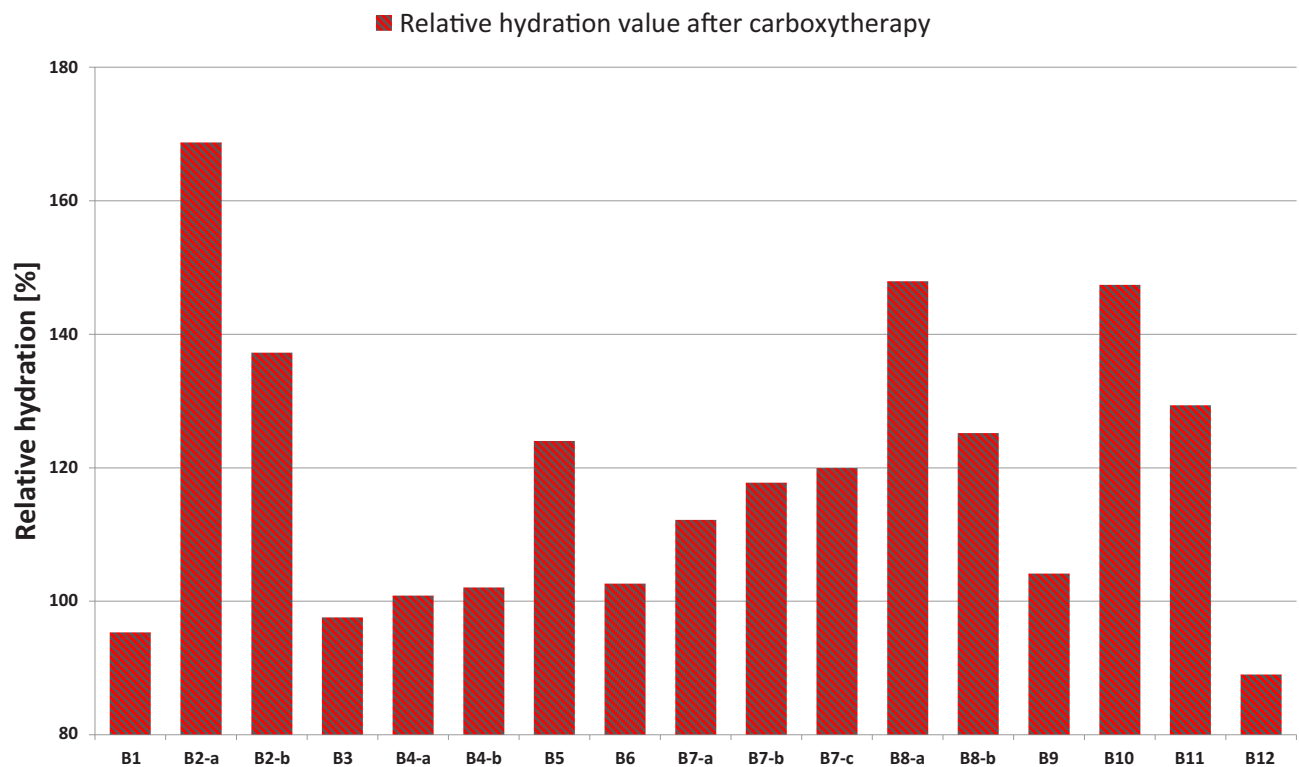
**Figure 1** Skin parameters within the area of scars measured with the use of the cutometer.

in Inspect Plus program, Steinbichler, Germany. During the analysis, a long axis (OX) was determined for each scar which has been examined. Deviations indicating effectiveness of the therapy were calculated within the axis mentioned above.

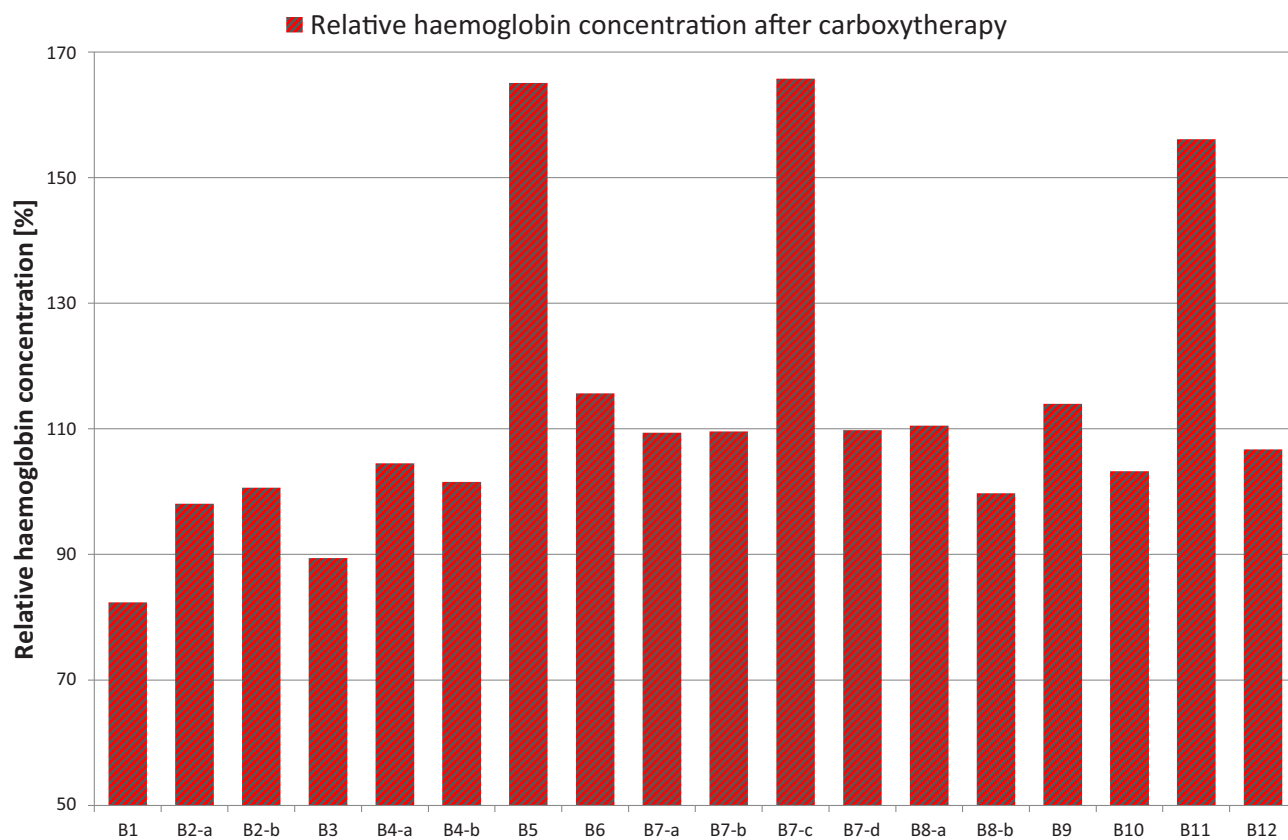
## Results

### Hydration Measurement

The average value of hydration of the scare surface before and after applying carboxytherapy increased by 18%. The highest increase in the degree of hydration was observed in the postacne scars on B2 cheeks and B10 scar, where the increase in hydration



**Figure 2** Hydration level of the analyzed scars after carboxytherapy.



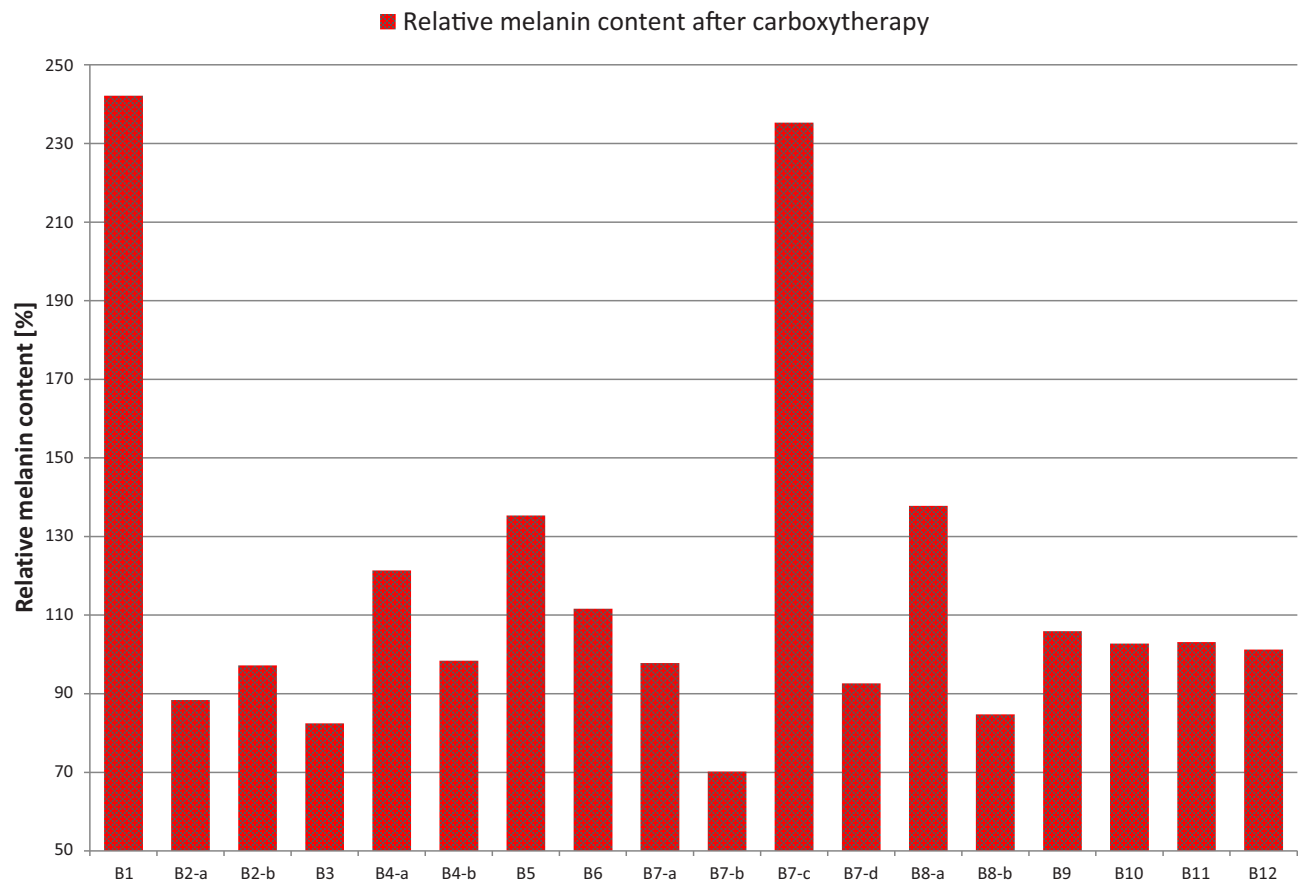
**Figure 3** Hemoglobin concentration in the analyzed scars after carboxytherapy.

reached 68% and 47%, respectively (Figure 2). The smallest increase in hydration was related to scars B4 and B6 and it reached 0.8% and 2%, respectively. In addition, in three cases (B1, B3, B12) there was a slight decrease in hydration which equalled 5%, 3% and 12%, respectively. In the remaining scars, the increase in water content ranged from 6% to 37%.

## Colour Measurement

Before a series of treatments, haemoglobin concentration in the analysed scars was on average  $324.94 \pm 75.80$ , as indicated (relative units). The difference in the concentration of hemoglobin in skin before and after an initiation of carboxytherapy equalled 13.4%. In two extreme cases (B5, B11), in which the biggest effect of carbon dioxide was also visually observed, concentration of haemoglobin increased the most, ie, by 65% and 56% (Figure 3). Similarly, a large increase equalling 64% occurred in B7 scar. The increase in haemoglobin concentration in the range of 6–12% was the effect of administration of CO<sub>2</sub> to the areas of the following scars: B6, B8, B9 and B12. Taking into consideration B1 and B3 scars, haemoglobin content was decreased by 18% and 12%, respectively. Slight changes in haemoglobin concentration after completion of the therapy were observed in cases of B2, B4 and B10 scars.

Most of the scars analyzed were characterized by a relatively low concentration of melanin (paleness of scar). The average difference in concentration of melanin before and after administration of CO<sub>2</sub> to scars was 17%. After completion of the therapy, the highest increase in concentration of melanin reached 142% and was observed in B1 scar, and within the measurement area of B7 scar where the increase in melanin concentration reached as much as 135% (Figure 4). On the other hand, in the second fragment of B7 scar a decrease in colour by 30% was observed. Lightening of surface, after the application of carboxytherapy, also occurred in cases of: B2, B3 and B7 scars. Small differences, within the range of 1–11%, were demonstrated in B6 and B9–B12 scars. In addition, an increase in pigment concentration was also observed in the case of B4 by 21 and in the case of B5 by 35%.



**Figure 4** Melanin content in scars under analysis after carboxytherapy.

## Elasticity Measurement

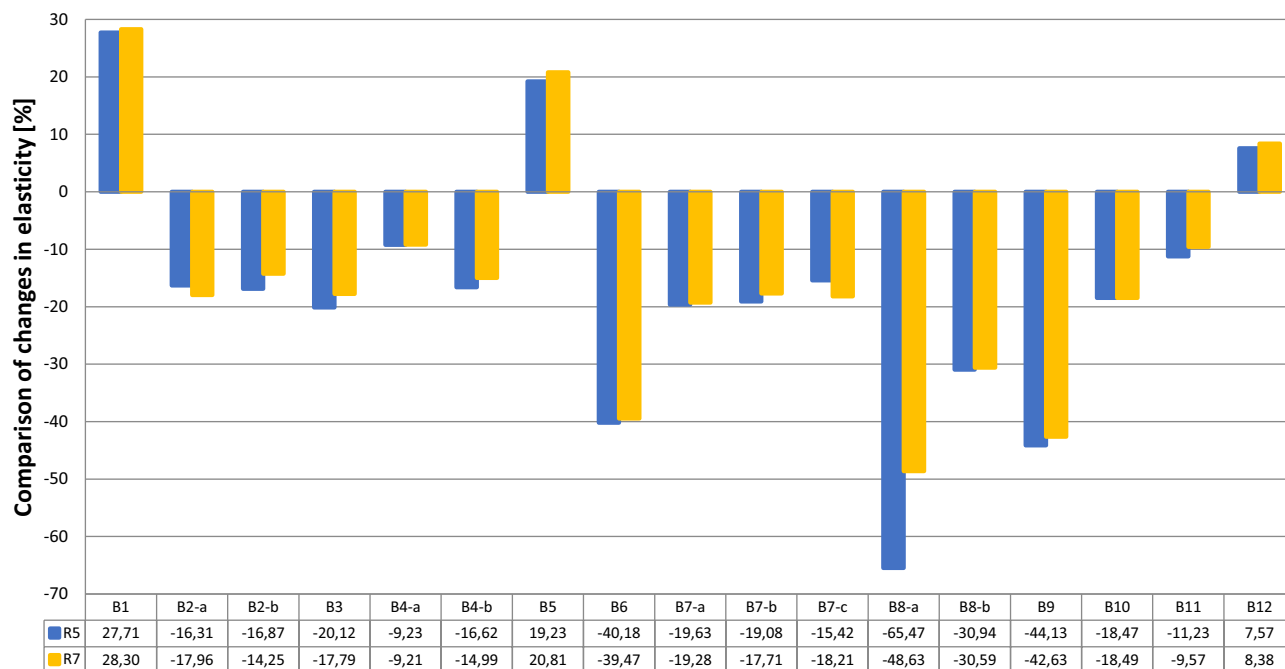
On the basis of the collected data in CutometerQ program, R5 and R7 parameters were determined which best characterize biomechanical properties of scars. The first one (R5) is net elasticity ( $U_r/U_e$ ), ie, elastic recovery ratio after applying the stimulus leading to extension of skin. After application of carboxytherapy, a decrease in R5 parameter was noted for all of the scars which have been analyzed. The decrease, on average, equalled  $16.07 \pm 22.47\%$ . The greatest reduction in elasticity, reaching 65%, was observed for B8 scar, while for B6 and B9 scars the changes were over 40%. The increase in R5 parameter was registered in the case of the following scars: B1, B5 and B12 and it ranged from 7.57% to 27.71%. Taking into account the remaining scars, they were characterized by decrease in elasticity which is understood as a reduction of R5 parameter within the following range: 11.23–20% (Figure 5).

R7 parameter, ie, viscoelasticity ( $U_r/U_f$ ), is equal to the ratio of immediate recovery to the total deformation [also known as relative elastic recovery]. The R5 and R7 values are clearly correlated with each other and it does occur in each scar which has been analysed.

In both cases (R5 and R7), the more the value which was obtained deviated from 1 (100%), the less elastic the scar is. The average decrease in R7 parameter, amounting to  $14.3 \pm 20.57\%$ , was registered for all of the scars which have been examined. After four administrations of CO<sub>2</sub>, the most reduced viscoelasticity was observed in B8 scar (decrease by 48.63%) and B6 and B9 scars, in which this value changed successively by 39.47 and by 42.63%. The increase in viscoelasticity of scars B1, B5 and B12 was bigger by about 1% than the values defined by parameter R5.

## The Evaluation of Scar Morphology Using a 3D Scanner

The use of the Steinbichler Comet L3D system enabled to precisely model the analyzed scars both before and after a series of treatments performed in the Inspect Plus program with accuracy of 4 $\mu$ m in relation to a single point.



**Figure 5** Comparison of changes of R5 and R7 parameters before and after carboxytherapy.

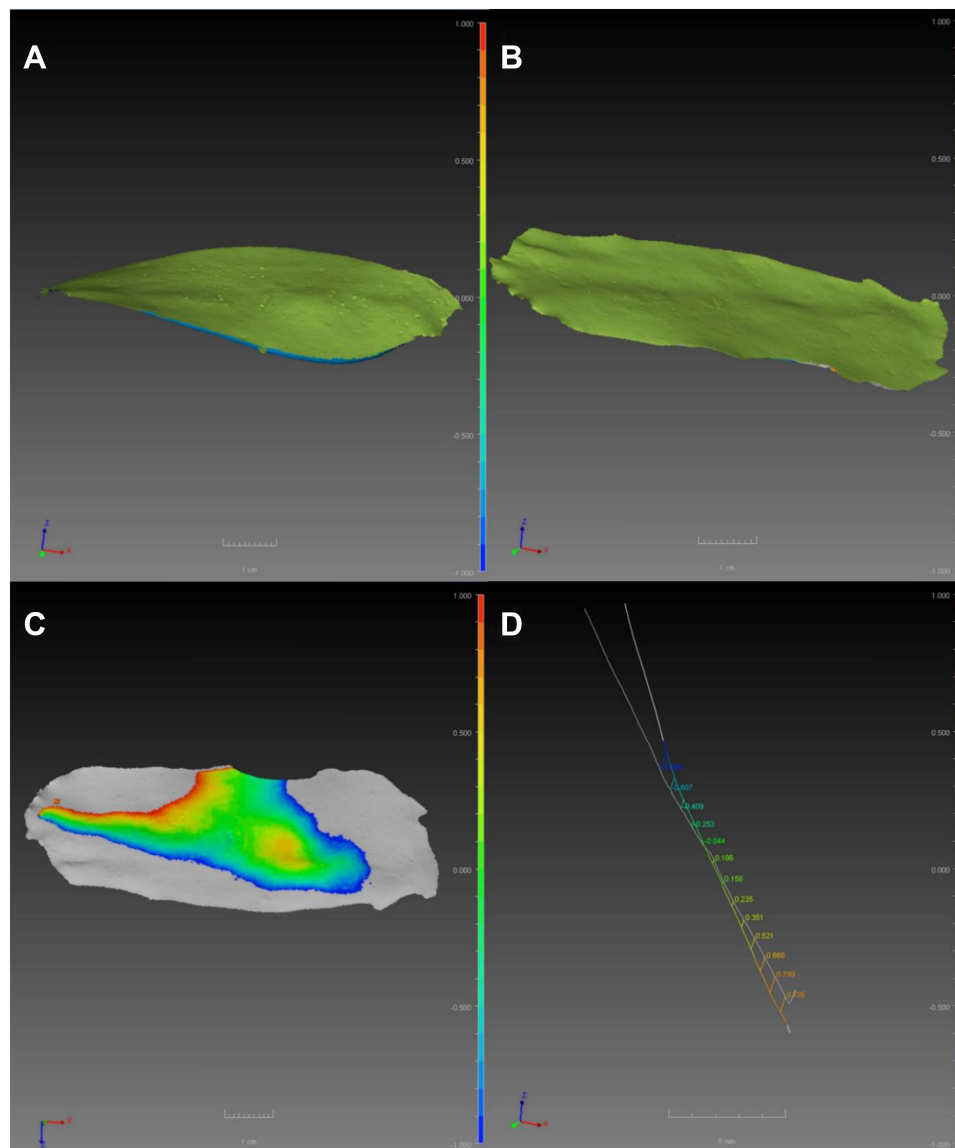
Determination of the long axis (OX) for each scar enables to superimpose two reconstructions of the same scar in order to depict the effects of the therapy in quantitative terms in the form of determined deviations towards the OX axis. In addition, after overlapping the above mentioned reconstructions before and after completion of carboxytherapy, areas characterized by the highest variability were marked with red and blue colors.

The biggest, average difference in height with respect to the OX axis, which reached 0.547 mm, was observed for the scar located on the shoulder blade (B11). A similar value, reaching 0.474 mm, was observed in the case of scar on the back (B1). On the other hand, the smallest difference of the OX height equalling 0.098 mm was determined for B5 located on the knee. Taking into account the long scar situated along the spine (B4), the average difference of height towards the OX equalled 0.241 mm, similar to B8 on the abdomen and B6 on the shoulder, where it was 0.221 mm and 0.197 mm, respectively.

In turn, the highest maximum differences in height in relation to the OX axis, equalling 0.908 and 0.867 mm, were recorded for both scars located on the back – B1 and B4, respectively. Significant changes in scar height, exceeding 0.7 mm, referred to B1 and B6 scars. In the case of scars on the shoulder blade (B11) and spine (B1), their size was almost identical and amounted to 0.54 mm. Smaller, maximum differences in height with respect to the OX axis, amounting to 0.229 mm and 0.347 mm, respectively, were observed, among others, for scars on the shoulder (B6) and knee (B5).

When considering twelve cases, in most of them the scar volume was reduced after application of CO<sub>2</sub>. The most convex scars were noticeably flattened, and flattening reached up to 1 mm. In turn, volume of atrophic scars usually decreased from the edges towards the central part. An exemplification of this effect is the scar presented in Figure 6A–D. A comparison of the scar located on the spine (B9) is shown before and after the therapy in the form of the deviations from the OX axis. The average deviation with respect to the OX axis equalled 0.45 mm. The largest difference in this case, visible on the edges of the scar, reached about 1 mm. The smallest difference, 0.044 mm, was observed in the central part of the scar (Figure 6D).

The analysis of scar morphometry (Figure 7), running along the spine (B4) indicates the average deviation in the OX axis equalling 0.284 mm. The largest effect that has been defined, reaching 0.584 mm, was also on the edge of the scar, while deviation up to 0.019 mm was located closer to the middle part (Figure 8). Additionally, this scar was characterized by a vast area of variability, including undamaged skin, as illustrated by Figure 9.




**Figure 6** Reconstruction of B9 scar prior to carboxytherapy (A); reconstruction of B9 scar after the end of a series of carboxytherapy treatments (B); the area of variation occurring after the overlap of both reconstructions (before and after therapy) (C); changes in morphometric parameters of the scar in relation to OX axis (D).

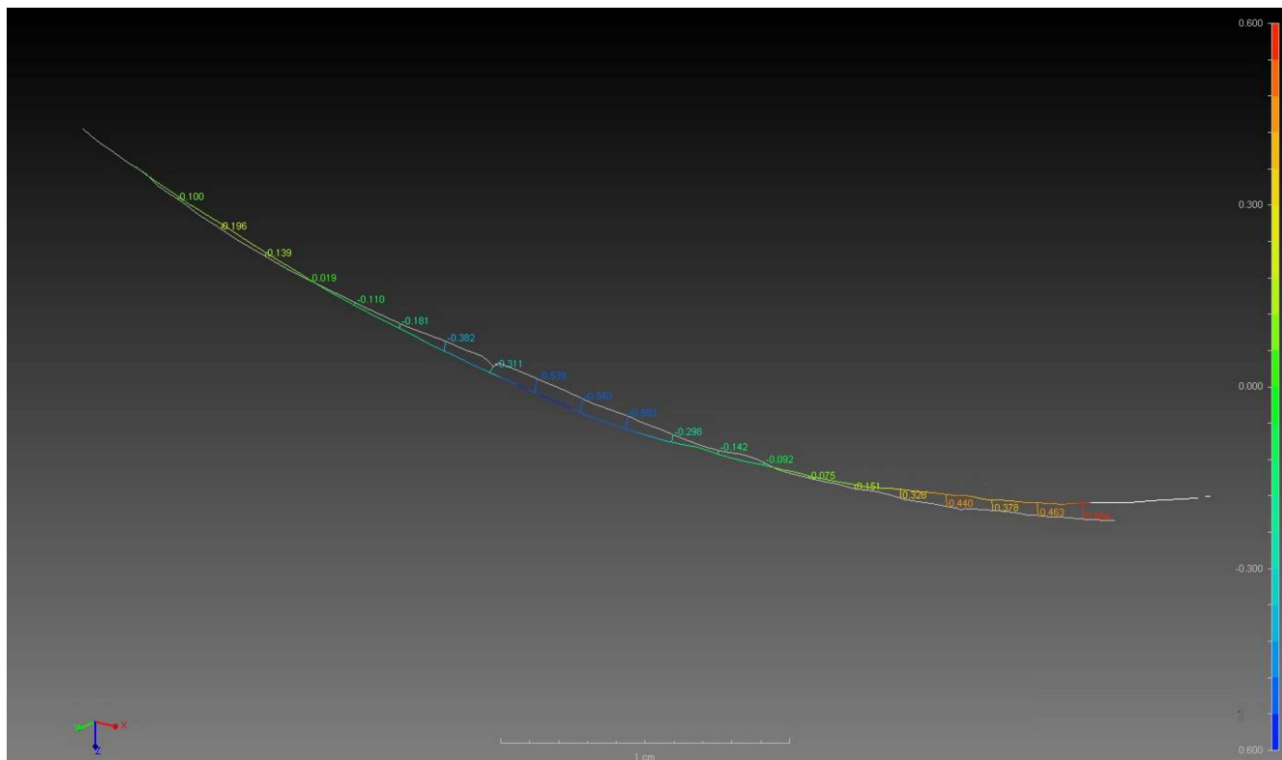
The last presented example is a small scar (about 1.5 cm long) on the shoulder (B6) which was visibly flattened. Figure 10 shows its reconstruction process before undertaking the therapy (a) and after the series of carboxytherapy procedures (b). In this case, after overlapping and comparison of both reconstructions, the average deviation was 0.188 mm (Figure 11). After the therapy, volume of B6 scar decreased almost uniformly over the entire surface, which is described by approximate values of all calculated deviations with respect to the OX axis. Nevertheless, the greatest variability of morphometric parameters, amounting to 0.343–0.327 mm, was determined in the central part of B6 scar (Figure 12).

## Statistical Analysis

The use of carboxytherapy had a significant effect on the hydration of the scar surface ( $p = 0.004$ ) (Figure 13). Before carboxytherapy, the median (Me) and quartile range (25–75%) of hydration level were, respectively: Me 40.7, 25–75% 32.4–54.6, while after carboxytherapy, respectively: Me 49.1, 25–75% 38.8–64.3.



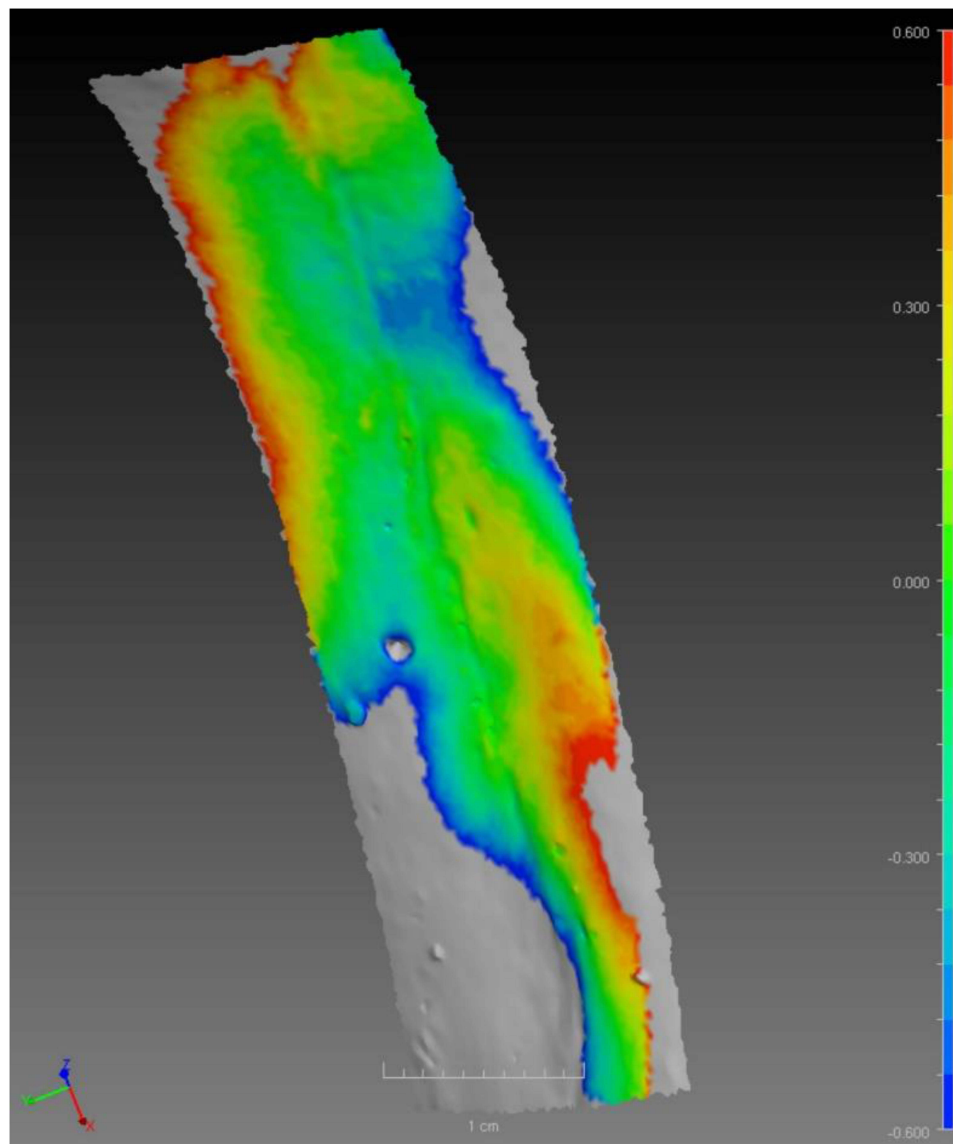
**Figure 7** Reconstruction of B4 scar before (A) and after (B) carboxytherapy.



**Figure 8** Changes in morphometric parameters of B4 scar in relation to the OX axis.

Carboxytherapy treatments did not have a statistically significant effect on the melanin content of the scar surface (Figure 14).

The scar hemoglobin concentration increased significantly after carboxytherapy ( $p = 0.019$ ) (Figure 15). The median and quartile range hemoglobin concentration before carboxytherapy were respectively: Me 330.0, 25–75% 278.0–377.0, while after carboxytherapy, respectively: Me 351.0, 25–75% 317.0–404, 0.




**Figure 9** Area of variation of B4 scar.

The use of carboxytherapy significantly influenced R5 ( $p = 0.001$ ) (Figure 16) and R7 ( $p = 0.002$ ) (Figure 17) parameters of elasticity. The median and quartile range of the R5 parameter before carboxytherapy were, respectively: Me 0.035, 25–75% 0.026–0.056, and after carboxytherapy, respectively: Me 0.026, 25–75% 0.021–0.040. The median and quartile range of the R7 parameter before carboxytherapy were, respectively: Me 0.034, 25–75% 0.025–0.052, while after carboxytherapy, respectively: Me 0.025, 25–75% 0.020–0.038.

The mean scar height is reduced by carboxytherapy (Figure 18) ( $p < 0.001$ ). Before carboxytherapy, the median and quartile range of the scar height were, respectively: Me 1.453, 25–75% 1.012–2.006, and after carboxytherapy, respectively: Me 1.221, 25–75% 0.766–1.762.

## Discussion

It should be noted that so far, none of publications have specified the impact of the influence of carboxytherapy on scar reduction. Wound healing is an extremely important process which aims to restore skin functions and its structure. However, it is not synonymous with full regeneration, as it usually occurs with formation of scar tissue in the area of skin being lost. The appearing scar is a permanent, unesthetic defect and its removal, by means of traditional methods, is



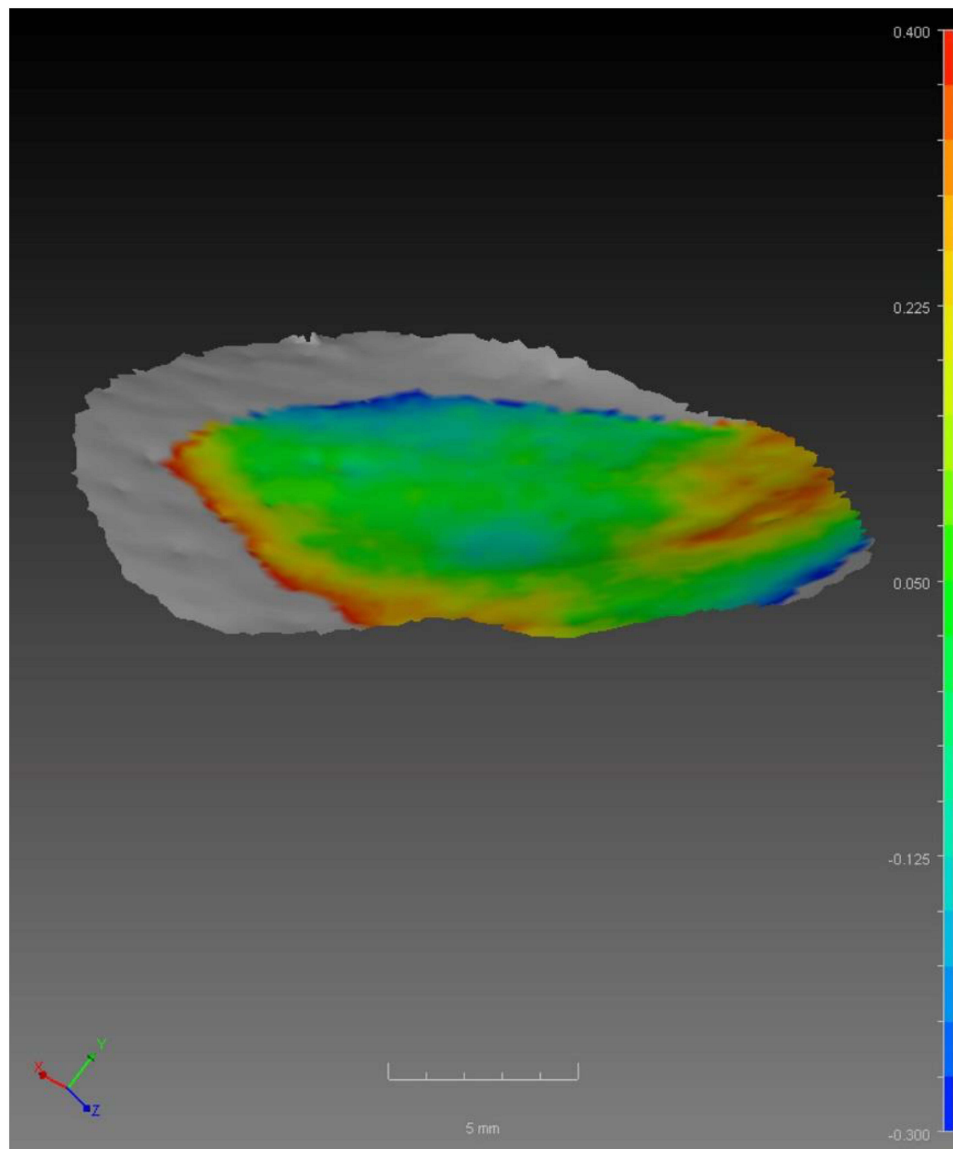
**Figure 10** Reconstruction of B6 scar before (A) and after (B) completion of the therapy.

extremely difficult or practically impossible. Carboxytherapy, ie, a carbon dioxide therapy, is an effective solution which enables to reduce visibility of scars safely and quickly. The scientific literature indicates high safety level of carboxytherapy, which has been confirmed in the course of this research. The treatment is accompanied by a feeling of smarting in the area of scars. It lasts only few seconds and is a completely natural reaction of the body to CO<sub>2</sub> injection.

Placement of collagen fibres in healthy skin is symmetrical. On the other hand, in the case of scars, the collagen fibres are arranged in the stochastic way, making it hard and resistant to deformation. Draaijers et al<sup>22</sup> used a cutometer to measure flexibility of scars, regarding it as a reliable apparatus for measuring biomechanical properties of scars. Due to measurements performed with the cutometer, mentioned above, two parameters defining elasticity of scars, namely R5 and R7, were determined in this work. It also has to be mentioned that there is a strong correlation occurring in between these two parameters. The first of them (R5) is an indicator of elasticity, which is defined as the ability of the skin to restore itself to the previous shape after deformation. In turn, R7, also referring to elasticity, determines the immediate maximum deformation of the skin. In the case of skin which is undamaged, the higher the value of both parameters, the more tense the skin is. However, when taking into account a rigid structure of scars, an increase in R5 and R7 parameters would mean an increase in their hardness, and such a result could suggest a failure of the applied therapy. After completion of the series of treatments the decrease in both values, observed in the most cases of scars under analysis, indicates softening and loosening of the connective tissue. The results achieved confirm the effectiveness of the carboxytherapy. This is confirmed by the statistical analysis which showed that the use of carboxytherapy significantly influenced R5 and R7 parameters of elasticity.

Hydration of skin was measured within the area of scars in the course of the studies which were carried out. The measurements showed a slight increase in hydration after completion of the therapy. Statistical analysis showed that carboxytherapy treatment had a significant effect on the hydration of the scar surface. However, this change cannot be regarded as unequivocally important as the used corneometer was designed for the capacitive measurement of hydration of the stratum corneum. Additionally, the presence of the stratum corneum within the examined scars was not verified in the course of the ongoing studies.


A natural response to CO<sub>2</sub> injections into tissues is an immediate vasodilatation and increased blood flow. As illustrated by numerous studies, a carboxytherapy is a method which induces a formation of new capillaries<sup>5,23</sup> In practice, such methods are rare. Neovascularization is a complex and long-lasting process occurring as a result of hypoxia, and appearing at least one week after adjusting the tissue pH. In contrast to red, fresh scars, mature scars are characterized by much weaker vascularity, and therefore a proliferation of endothelial cells is more difficult.<sup>18,24</sup> The



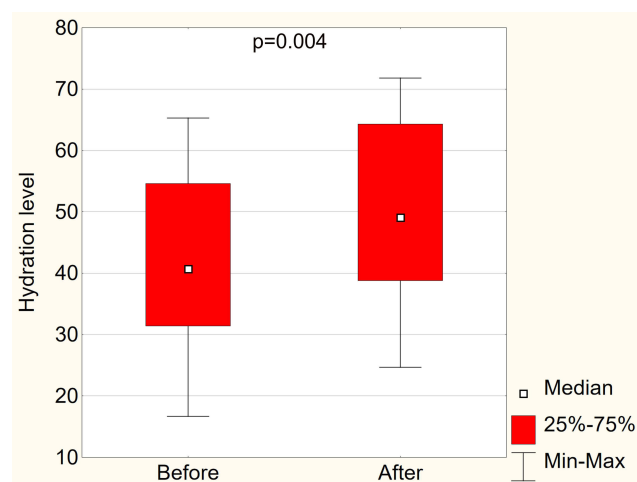
**Figure 11** Area of changeability of B6 scar.

mexameter, measuring skin haemoglobin content, was used in order to estimate changes occurring within blood vessels. The device was used to examine the scars under study. In most of the scars which were analyzed, there was a slight increase in haemoglobin concentration occurring after completion of the therapy. According to the statistical results, the scar hemoglobin concentration increased significantly after carboxytherapy. It might be an indicator of an initiation process of new blood vessels formation or a slight increase of the skin flow in the area below the scar. However, this measurement technique is not able to determine a factual state of newly formed vessels. In addition, a relatively small increase in haemoglobin concentration could have been influenced by the test protocol which envisaged only four treatments. The neovascularization process, according to literature data, requires a bigger number of treatments and can be observed, at the earliest, several months after starting the therapy.<sup>3,4,23</sup>

Scars which are fully developed are lighter than the surrounding skin, which is associated with reduced content of melanin.<sup>16,17</sup> Intensification of blood flow and release of oxygen molecules by haemoglobin, occurring as a result of infusion of carbon dioxide in the tissue, stimulates the production of melanin, resulting in repigmentation. Reducing visibility of scars under the influence of carboxytherapy, besides loosening their consistency, can also be described understood as the progression in which the colour of the scar starts to resemble, more and more, the colour of normal



**Figure 12** Changes in morphometric parameters of B6 scar in relation to the OX axis.



**Figure 13** Hydration level before and after carboxytherapy.

skin. It is a gradual process and is best observed in the case of flat scars, as their structure has partially preserved functions of healthy skin. The results of pigmentation measurements, performed by mexameter, and the statistical analysis did not show significant differences in melanin concentration before and after the treatment. A slight increase in melanin concentration may be associated with poor pigmentation of scars prior to the therapy. Such a small amount of melanin may indicate a deficiency of melanocytes. In turn, it means a lack of precursors which could be stimulated by CO<sub>2</sub> in the course of carboxytherapy. A surprising fact is a phenomenon of lightening some of the scars which was noticed after the first treatment. It is assumed that the pressure of the injected CO<sub>2</sub> may, to the greater extent, contribute to this effect.

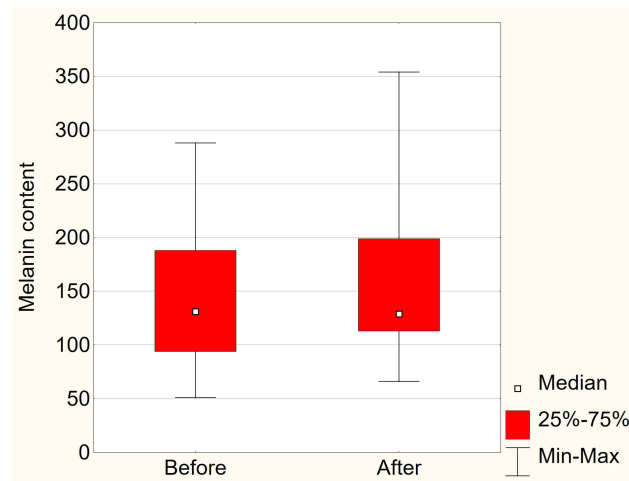


Figure 14 Melanin content before and after carboxytherapy.

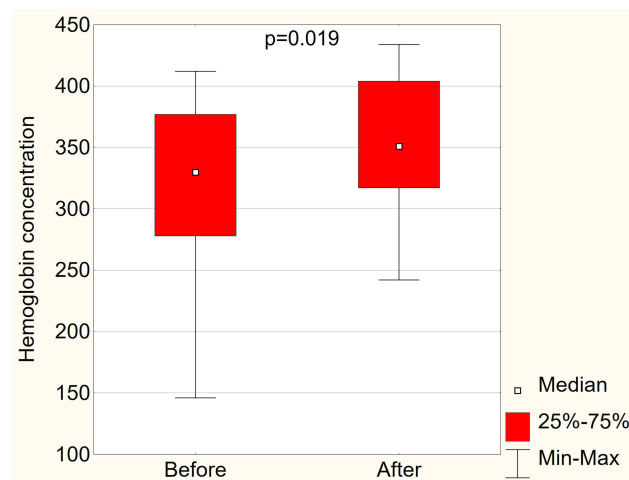


Figure 15 Hemoglobin concentration before and after carboxytherapy.

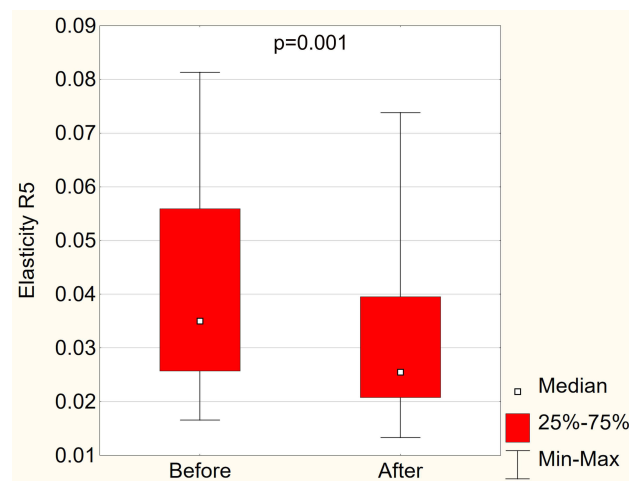
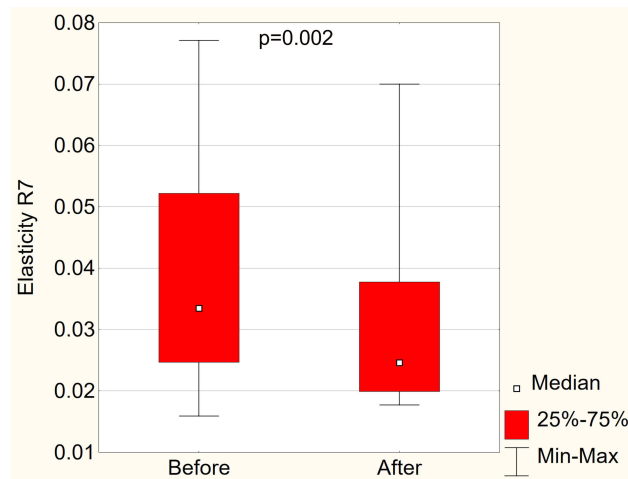
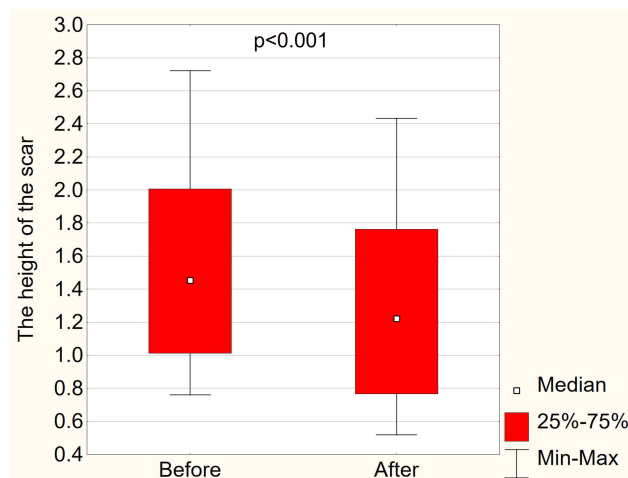


Figure 16 R5 elasticity parameter before and after carboxytherapy.



**Figure 17** R7 elasticity parameter before and after carboxytherapy.



**Figure 18** The height of the scar before and after carboxytherapy.

Using carboxytherapy to reduce scars, we can achieve different, slightly unpredictable results as each single scar is different and responds to the applied therapy individually. The effects depend on the structure of the scar itself, the tissues placed beneath it, as well as they are dependent on both depth and age of the scar, its location and individual response of the given patient. A significant correlation occurring among pigmentation, vascularity, elasticity and convex structure of scars, which had been earlier proved by Sarov and Stewart,<sup>25</sup> can be regarded as the confirmation of the hypothesis mentioned above.

An assessment of scar morphology has been based so far on qualitative features. Subjective scales used for this purpose, exemplified by Vancouver or Manchester, are dependent on observers and include following factors such as convex structure, thickness, elasticity, a surface area, texture, pigmentation and scar tissue vascularization. However, they are used to identify only significant differences occurring among the features of particular scars, and all other individual attributes are evaluated equally. As a consequence, many distinct scars may be found in the same category as a result of inaccurate categorisation.

The 3D analysis used in this work is an objective, non-invasive, repeatable and precise method of evaluation of morphometric parameters of scars, which allows to perform both qualitative and quantitative estimation of variability of the examined structures. The results which have been achieved clearly illustrate a reduction in scar volume after four

carboxytherapy procedures. The statistical analysis confirmed the effectiveness of this technique in scar reduction. The mean scar height was significantly reduced by carboxytherapy.

A healing process starts when growth factors are secreted as a result of activation of inflammation. The growth factors, mentioned above, stimulate an inflow of cells from the edge of wound to the damaged area.<sup>18</sup> During carboxytherapy an area which undergoes the treatment is acidified as a result of dissolution of CO<sub>2</sub> in tissue fluids and formation of carbonic acid. This local reduction of pH to around 6 is enough to induce inflammation, which leads to the release of agents stimulating fibroblasts to a synthesis of proteins. While performing a 3D analysis, the biggest morphometric changes of scars were observed at their edges. It can be justified by the fact that a reconstruction process, just as healing mechanisms, progresses from the edges of scars.

In the available literature, there are research results regarding the effects of carboxytherapy in the case of atrophic and hypertrophic scars. In the case of linear hypertrophic and atrophic scars treatment, carboxytherapy brings positive effects, but sometimes we have to be careful, as in the treatment of large hypertrophic scars on the chest in a teenager,<sup>26</sup> where carboxytherapy did not improve these scars, and even the author observed a slight deterioration.

Performing more treatments would most likely result in an increase of effectiveness towards the central part of the scar. The reduction of scar volume also indicates a reorganization of the collagen fibre system, which, in turn, additionally confirms the area of variability going beyond the scar borders. The area of variability which is mentioned above is determined after overlapping of two reconstructions.

The research also has some limitations. The number of tested samples is too small, and the tests were carried out only in one research centre. However, this research project can be treated as preliminary research, and its extension is planned in the future.

## Conclusion

In conclusion, carboxytherapy is a quantitatively verified method of skin regeneration, which might be used as an effective instrument for scar removal. The results of the research carried out in this work confirm the ability of CO<sub>2</sub>, demonstrated earlier by other authors, to stimulate a synthesis and reconstruction of collagen, thus reducing a surface of scars. The precise values, illustrating the effects of the therapy, can be obtained as a result of the use of modern, three-dimensional scanning techniques. Thanks to the techniques applied, it is possible to optimize parameters of the treatment and maximize its effect while, at the same time, minimizing potential adverse effects.

## Acknowledgments

This study has been financially supported by Medical University of Silesia, grant no. PCN-1-166/N/1/0.

## Disclosure

The authors report no conflicts of interest in this work.

## References

1. Behrangi E, Goodarzi A, Roohaninasab M, Sadeghzadeh-Bazargan A, Nobari NN, Ghassemi M. A review of scar treatment related to acne and burn. *J Crit Rev.* 2020;7(4):714–722.
2. Kołodziejczak A, Podgórna K, Rotsztein H. Is carboxytherapy a good alternative method in the removal of various skin defects? *Dermatol Ther.* 2018;31(5):e12699. doi:10.1111/dth
3. Prendergast PM, Shiffman MA. *Aesthetic Medicine: Art and Techniques*. Berlin, Heidelberg: Springer-Verlag; 2011.
4. Ferreira JC, Haddad M, Tavares SA. Increase in collagen turnover induced by intradermal injection of carbon dioxide in rats. *J Drugs Dermatol.* 2008;7(3):201–206.
5. Varlaro V, Manzo G, Mugnaini F, et al. Carboxytherapy: effects on microcirculation and its use in the treatment of severe lymphedema. A review. *Acta Phleb.* 2007;8(2):79–91.
6. Paolo F, Nefer F, Paola P, Nicolò S. Periorbital area rejuvenation using carbon dioxide therapy. *J Cosmet Dermatol.* 2012;11(3):223–228. doi:10.1111/j.1473-2165.2012.00633.x
7. Kippenberger S, Loitsch S, Guschel M, et al. Mechanical stretch stimulates protein kinase B/Akt phosphorylation in epidermal cells via angiotensin II type 1 receptor and epidermal growth factor receptor. *J Biol Chem.* 2005;280(4):3060–3067. doi:10.1074/jbc.M409590200
8. Irie H, Tatsumi T, Takamiya M, et al. Carbon dioxide-rich water bathing enhances collateral blood flow in ischemic hindlimb via mobilization of endothelial progenitor cells and activation of NO-cGMP system. *Circulation.* 2005;111(12):1523–1529. doi:10.1161/01.CIR.0000159329.40098.66

9. Pinheiro NM, Crema VO, Millan BM, Carvalho FA, Mendonça AC. Comparison of the effects of carboxytherapy and radiofrequency on skin rejuvenation. *J Cosmet Laser Ther.* 2015;17(3):156–161. doi:10.3109/14764172.2014.1003238
10. Ferrara N, Gerber HP, LeCouter J. The biology of VEGF and its receptors. *Nat Med.* 2003;9(6):669–676.
11. Oliveira SMD, Rocha LB, da Cunha MTR, Cintra MMM, Pinheiro NM, Mendonça AC. Effects of carboxytherapy on skin laxity. *J Cosmet Dermatol.* 2020;19(11):3007–3013. doi:10.1111/jocd.13337
12. D’Arcangelo D, Facchiano F, Barlucchi LM, et al. Acidosis inhibits endothelial cell apoptosis and function and induces basic fibroblast growth factor and vascular endothelial growth factor expression. *Circ Res.* 2000;86(3):312–318. doi:10.1161/01.RES.86.3.312
13. Pezzuto A, Carico E. Role of HIF-1 in cancer progression: novel insights. A Review. *Curr Mol Med.* 2018;18(6):343–351. doi:10.2174/1566524018666181109121849
14. Guerra RR, Kriazhev L, Hernandez-Blazquez FJ, Bateman A. Progranulin is a stress-response factor in fibroblasts subjected to hypoxia and acidosis. *Growth Factors.* 2007;25(4):280–285. doi:10.1080/08977190701781222
15. Wang J, Thampatty BP, Lin JS, Im HJ. Mechanoregulation of gene expression in fibroblasts. *Gene.* 2007;391(1–2):1–15. doi:10.1016/j.gene.2007.01.014
16. Lee GS. Quality survey on efficacy of carboxytherapy for localized lipolysis. *J Cosmet Dermatol.* 2017;16(1):21. doi:10.1111/jocd.12257
17. Zhu Z, Ding J, Tredget EE. The molecular basis of hypertrophic scars. *Burns Trauma.* 2016;4:2. doi:10.1186/s41038-015-0026-4
18. Wong T, McGrath JA, Navsaria H. The role of fibroblasts in tissue engineering and regeneration. *Br J Dermatol.* 2007;156(6):1149–1155. doi:10.1111/j.1365-2133.2007.07914.x
19. Brandi C, D’Aniello C, Grimaldi L, et al. Carbon dioxide therapy in the treatment of localized adiposities: clinical study and histopathological correlations. *Aesthetic Plast Surg.* 2001;25(3):170–174. doi:10.1007/s002660010116
20. Lee G. Carbon dioxide therapy in the treatment of cellulite: an audit of clinical practice. *Aesthetic Plast Surg.* 2010;34(2):239–243. doi:10.1007/s00266-009-9459-0
21. Eldsouky F, Ebrahim HM. Evaluation and efficacy of carbon dioxide therapy (carboxytherapy) versus mesolipolysis in the treatment of cellulite. *J Cosmet Laser Ther.* 2018;20(5):307–312. doi:10.1080/14764172.2017.1400175
22. Draaijers LJ, Tempelman FR, Botman YA, et al. The patient and observer scar assessment scale: a reliable and feasible tool for scar evaluation. *Plast Reconstr Surg.* 2004;113(7):1960–1965. doi:10.1097/01.PRS.0000122207.28773.56
23. DiPietro LA. Angiogenesis and wound repair: when enough is enough. *J Leukoc Biol.* 2016;100(5):979–984. doi:10.1189/jlb.4MR0316-102R
24. Pym K, Davies K, Jimenez G, Malloy L, Twyman L. Identifying and managing problem scars. *Br J Nurs.* 2006;15(2):78–82. doi:10.12968/bjon.2006.15.2.20367
25. Fearmonti R, Bond J, Erdmann D, Levinson H. Review of scar scales and scar measuring devices. *Eplasty.* 2010;10:354–363.
26. Koutná N. Carboxytherapy in aesthetic medicine. In: *Aesthetic Medicine*. Berlin, Heidelberg: Springer; 2012:547–576.

## Clinical, Cosmetic and Investigational Dermatology

Dovepress

### Publish your work in this journal

Clinical, Cosmetic and Investigational Dermatology is an international, peer-reviewed, open access, online journal that focuses on the latest clinical and experimental research in all aspects of skin disease and cosmetic interventions. This journal is indexed on CAS. The manuscript management system is completely online and includes a very quick and fair peer-review system, which is all easy to use. Visit <http://www.dovepress.com/testimonials.php> to read real quotes from published authors.

Submit your manuscript here: <https://www.dovepress.com/clinical-cosmetic-and-investigational-dermatology-journal>