




# Successful Treatment in a Child with Refractory Periungual Warts by Local Hyperthermia: A Case Report

Lingyun Du , Zhiqiang Cao , Zhaoyang Liu, Xia Zhu, Chunhong Zhang 

Department of Dermato-Venereology, The Second Hospital of Shandong University, Jinan, People's Republic of China

\*These authors contributed equally to this work

Correspondence: Chunhong Zhang, Department of Dermato-Venereology, The Second Hospital of Shandong University, Jinan, People's Republic of China, Tel +86-531-85875027, Fax +86-531-88962544, Email aliu133@163.com

**Abstract:** Periungual wart is a kind of verruca vulgaris that occurs alongside or underlying the nails, which is challenging to treat and prone to recurrence, seriously affecting the quality of patients' life. We report a 6-year-old boy with periungual warts who had experienced various treatments with no improvement and even worsening. Therefore, we tried to treat the patient with local hyperthermia which uses a patented device that has an infrared emission source. The heat generated by infrared rays acts on the local skin surface. The mechanism of this therapy may be to establish a specific immune response against human papillomavirus-infected tissues, thereby facilitating the clearance of human papillomavirus at irradiated and non-irradiated sites. Local hyperthermia has the advantages of non-contact, safety, noninvasive, less pain, and so on. After 5 treatments, the irradiated periungual warts completely cleared after 2 weeks. The unirradiated sites were almost cured after 7 weeks. This case suggests that local thermotherapy has shown great advantages in the treatment of these refractory periungual warts and offers a new and effective therapy in patients with periungual warts.

**Keywords:** child, local hyperthermia, periungual warts, refractory warts

## Introduction

Periungual wart (PW) is a type of verruca vulgaris that grows in special regions, including nearby or underlying the nails, making it more challenging to treat.<sup>1</sup> Traditional treatments for PW include cryotherapy, salicylic acid therapy, photodynamic therapy, antiviral drugs, and herbal treatments.<sup>2</sup> However, these treatments have certain disadvantages, such as cryotherapy and photodynamic therapy, which can produce great pain, and oral medications that have certain side effects. Local hyperthermia is currently applied to skin diseases associated with human papillomavirus (HPV) infection, such as common warts and condyloma acuminata.<sup>3</sup> It has the advantages of being non-contact, non-invasive, leaving no scarring, and less painful. Local hyperthermia uses a patented (Patent No.: US8,246,668 B2) device<sup>4</sup> that has an infrared emission source. The heat generated by infrared rays acts on the local skin surface. The mechanism of this therapy may be to establish a specific immune response against human papillomavirus-infected tissues, thereby facilitating the clearance of human papillomavirus at irradiated and non-irradiated sites.<sup>5</sup> Therefore, hyperthermia is particularly suitable for patients with multiple warts and intolerance of pain. We report a 6-year-old boy with refractory periungual warts which cleared out after 7 weeks by thermotherapy and had not relapsed after the 12-week follow-up.

## Case Report

On July 1, 2022, a 6-year-old boy came to our hospital for warts on his hands. The child was diagnosed with PW two years ago and he had no history of immune system disorders. Various treatments were tried during this period, including herbal infusion, cryotherapy, topical medications such as imiquimod, 2% diphenylcyclopropanone gel, chlorhexidine acetate, fluorouracil, and oral thymidine. However, warts had no obvious improvement. (Table 1) Most treatments had adverse events or side effects. For

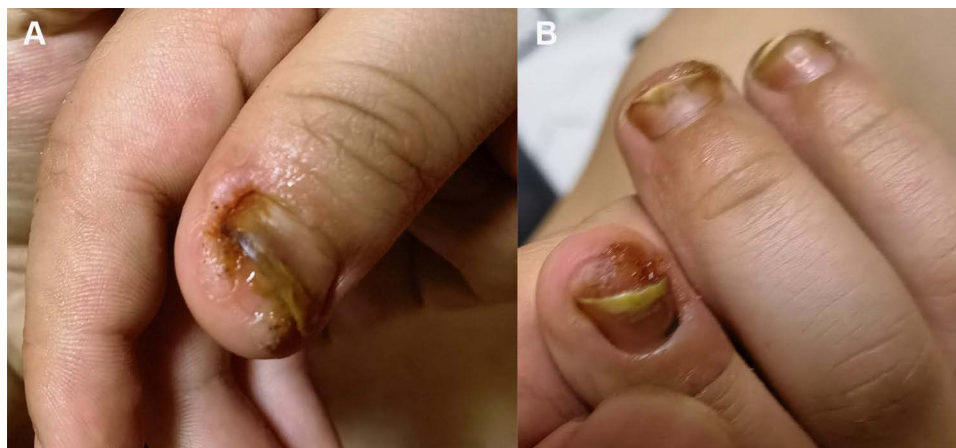**Table 1** The Patient's Treatment Journey Over Two Years

Date	Skin Lesions	Treatments	Duration	Adverse Effects	Results
2020-12	1 wart	Topical tincture of iodine; Topical herbal infusions	1 M	None	Ineffective
2021-01	3 warts	Herbal infusion; Cut off warts; Topical IMQ	5 M	Blisters	Ineffective; Warts increase
2021-06	5 warts	2% diphenylcyclopropanone gel; Herbal infusion; Cut off warts	2 M	None	Ineffective; Warts increase
2021-12	8 warts; Yellow Nails	Oral thymine; 2% diphenylcyclopropanone gel; Herbal infusion; Cut off warts	1 M	None	Ineffective;
2022-01	9 warts; Yellow Nails	Cryotherapy; Topical fluorouracil; Herbal infusion; Cut off warts	2 M	Severe pain	Reduced only in cryotherapy areas
2022-03	10 warts; Yellow Nails; Thick Nails	Chinese herbal ointment	1.5 M	Deformed and blackened nails	Deterioration; Develops deep into the nails
2022-05	10 warts; Yellow Nails; Thick Nails; Deformed Nails	Chlorhexidine acetate	1 M	Ulceration; Inflammation; Infiltration	Warts increase; Spreads under the fingernails
2022-07	10 warts; Yellow Nails; Thick Nails; Deformed Nails	Local hyperthermia	1.5 M	Mild pain	Almost all warts have disappeared

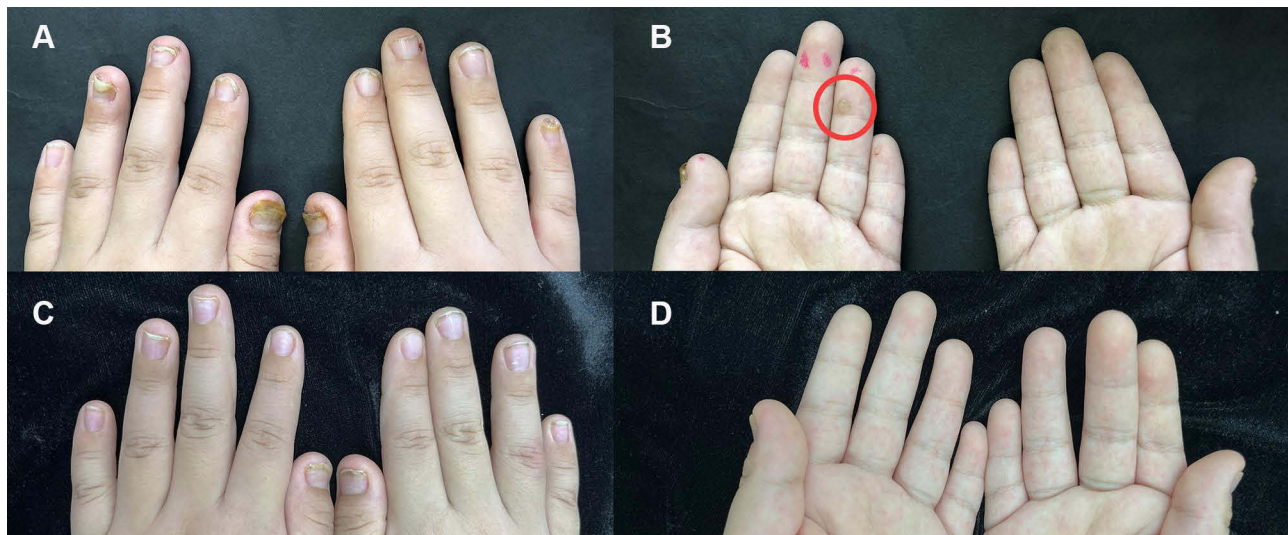
**Abbreviations:** M, month(s); IMQ, imiquimod.

example, the skin of fingers developed crucial redness, blisters, and oozing due to the application of chlorhexidine acetate (Figure 1A and B). Although cryotherapy reduced the size of warts, the child gave up the treatment owing to unbearable pain. Dermatologic examinations at our hospital revealed 10 warts around the nails, under the nails, and on the fingers. Warts under the nails caused the presentation of thick, yellow, and deformed nails (Figure 2A and B).

Since the patient responded worse to the above treatments, we opted for hyperthermia, a method using a patented device (Factory No. WRY-V01-19003, Liaoning Yanyang Medical Equipment Co. Ltd.) that derives its energy from a halogen tungsten lamp (>90% wavelength between 760–2300 nm, peak wavelength 1200 nm).<sup>5</sup> The heat generated by infrared rays acts on the local skin surface. A target lesion with an area of 0.25 cm<sup>2</sup> was selected on the palm side of a finger (Figure 2B) and irradiated with infrared light at 44 °C for 30 minutes. We used a 3+2+n cycle treatment method, that is, three consecutive treatments in the first week, two consecutive treatments after 10 days, and then once a week. There was no other treatment method. In our case, after 5 treatments on days 1, 2, 3, 14, 15, respectively, the irradiated PW completely cleared. The unirradiated sites were almost cured through 10 treatments after 7 weeks, and the color and shape of the nails returned to normal (Figure 2C and D). During the treatment, the patient experienced mild pain but without any discomfort. After 12 weeks of follow-up, there was no recurrence of PWs.



**Figure 1** Before this visit, the child's nails had become red, oozing, and blistered due to topical chlorhexidine acetate. (A and B).



**Figure 2** Treatment of periungual warts in the patient with local hyperthermia. (A and B) Warts around the nails, under the nails, and on the fingers before treatments (red circle indicates irradiated target lesion) (C and D) After 10 treatments, almost all warts disappeared, and nails were almost back to normal condition.

## Discussion

PW presents as keratotic papules with rough, hard surfaces around or under the nails, which can also involve the nails, making them yellow, thickened, and deformed.<sup>2</sup> Patients with PW usually have no obvious symptoms of discomfort, but this disease deeply affects the psychological health and social activities of patients, especially in children. Traditional treatments for PW include cryotherapy, salicylic acid therapy, photodynamic therapy, antiviral drugs, and herbal treatments. Compared to common warts, PW grows in a special location and tends to spread under the nails, making them hard to treat, with a high recurrence rate.<sup>1,2</sup>

In this case, the 6-year-old child was diagnosed with refractory PWs based on clinical manifestations and had tried many treatments on PWs but with no effect and even worsened, manifested by an increased number of warts, blisters, and exudation at the lesions. This patient did not respond well to conventional treatments and had a large number of warts, so we tried hyperthermia. PWs had almost completely subsided after 7 weeks.

Local hyperthermia is used to treat common warts and condyloma acuminatum caused by HPV infection.<sup>3,4,6,7</sup> It has the advantages of being non-contact, non-invasive, leaving no scarring, and less painful. During the treatment, we observed that irradiation of only one target lesion results in the regression of other unirradiated warts. When the irradiation wart subsided, this treatment was close to success. In addition, some studies have shown that local hyperthermia has a higher clearance rate for warts and a lower recurrence rate than cryotherapy,<sup>8</sup> which is particularly suitable for treating PW in children and pregnant women.

It has been shown that higher temperature increases the number of apoptotic keratocytes in warts,<sup>9</sup> which may be one of the mechanisms of local hyperthermia for common warts. Local hyperthermia decreases enzymes and molecules related to keratinocyte differentiation in wart tissue, such as KRT5, KRT27, KRT75, KRT76, and H2AFY2, and inhibits proteins involved in cellular metabolism, such as GALT, H6PD, EXOSC4, and EXOSC6; conversely, it promotes the expression of proteins involved in antiviral processes, such as OAS1, MX1, BANF1, CANX.<sup>10</sup> In addition, local hyperthermia also promotes the maturation of Langerhans cells and induces a systemic anti-HPV immune response, thus leading to the regression of lesions at unirradiated sites as well.<sup>11</sup>

Jiang et al reported a case of periungual warts in a 9-year-old child successfully treated with local hyperthermia.<sup>4</sup> Differently, our patient has more severe manifestations with fast development and numerous warts, involving multiple areas of the hands, including around and underlying the nails, and many fingers. Importantly, he had no response to almost all treatments and there were many adverse effects. The warts were finally cured by local hyperthermia and the adverse effects are only mild and bearable pain. Nevertheless, it is undeniable that hyperthermia has certain disadvantages. For example, the price and time spent are higher

than cryotherapy, and it can be observed clinically that hyperthermia is ineffective for some patients, but the accurate efficiency needs to be obtained through huge clinical observation trials and statistical analysis. It should be noted that this single case report has some limitations. More clinical and basic studies are needed to confirm this treatment outcome and further explore the therapeutic mechanism. However, for patients who have not responded to conventional treatment, especially children with multiple PWs who cannot tolerate pain, local hyperthermia has great advantages.

## Conclusion

We successfully cured a case of refractory PWs in a 6-year-old patient using local hyperthermia. Our case suggests that local hyperthermia may be considered for children with PW, especially in patients who have failed to respond to multiple conventional treatments. In addition, further studies, including randomized controlled trials, need to be conducted in the future to evaluate the value of local hyperthermia in PW.

## Informed Consent

This child's guardian had signed an informed consent form for publication of this study and accompanying images before the article was submitted. Institutional approval was not required to publish the case details.

## Acknowledgments

The authors gratefully acknowledge the financial support from the National Science Foundation of China (No.81973856).

## Disclosure

The authors report no potential conflicts of interest in this work.

## References

1. Souza BCE, Ribeiro CP, Swiczar BCC, Pires MC. Diphenciprone as a therapeutic alternative to exuberant periungual warts. *An Bras Dermatol*. 2018;93(2):305–307. doi:10.1590/abd1806-4841.20187200
2. Nofal A, Alakad R, Fouda I, Fawzy MM. Intralesional antigen immunotherapy in the treatment of periungual warts. *J Cutan Med Surg*. 2021;25(3):286–292. doi:10.1177/1203475420988859
3. Yang Y, Zhang L, Zhang Y, et al. Local hyperthermia at 44°C is effective in clearing cervical high-risk human papillomaviruses: a proof-of-concept, randomized controlled clinical trial. *Clin Infect Dis*. 2021;73(9):1642–1649. doi:10.1093/cid/ciab369
4. Jiang F, Shao J, Chen L, Yang N, Liu J, Li Z. Successful treatment of periungual warts with local hyperthermia: report of two cases. *J Dermatolog Treat*. 2022;33(4):2380–2382. doi:10.1080/09546634.2021.1961995
5. Huo W, Li GH, Qi RQ, et al. Clinical and immunologic results of local hyperthermia at 44 °C for extensive genital warts in patients with diabetes mellitus. *Int J Hyperthermia*. 2013;29(1):17–20. doi:10.3109/02656736.2012.758874
6. Hu LT, Qi RQ, Huo W, et al. Local hyperthermia combined with topical imiquimod cleared extensive and recalcitrant common warts on the scalp. *Eur J Dermatol*. 2015;25(4):366–367. doi:10.1684/ejd.2015.2585
7. Wang T, Zhou W, Man X, Li W. Local hyperthermia as a good treatment option for hands and feet warts in children: case series report. *Dermatol Ther*. 2022;e15936. doi:10.1111/dth.15936
8. Zhao SN, Huo W, An Q, et al. A multi center real world observation to evaluate the efficacy of cryotherapy versus local hyperthermia for the treatment of plane warts. *Dermatol Ther*. 2022;35(5):e15403. doi:10.1111/dth.15403
9. Wang X, Gao XH, Li X, et al. Local hyperthermia induces apoptosis of keratinocytes in both normal skin and condyloma acuminata via different pathways. *Apoptosis*. 2009;14(5):721–728. doi:10.1007/s10495-009-0344-8
10. Sun YZ, Li JF, Wei ZD, et al. Proteomic and bioinformatic analysis of condyloma acuminata: mild hyperthermia treatment reveals compromised HPV infectivity of keratinocytes via regulation of metabolism, differentiation and anti-viral responses. *Int J Hyperthermia*. 2019;36(1):383–393. doi:10.1080/02656736.2019.1578420
11. Li X, Gao XH, Jin L, et al. Local hyperthermia could induce migrational maturation of Langerhans cells in condyloma acuminatum. *J Dermatol Sci*. 2009;54(2):121–123. doi:10.1016/j.jdermsci.2008.12.004

Clinical, Cosmetic and Investigational Dermatology

Dovepress

Publish your work in this journal

Clinical, Cosmetic and Investigational Dermatology is an international, peer-reviewed, open access, online journal that focuses on the latest clinical and experimental research in all aspects of skin disease and cosmetic interventions. This journal is indexed on CAS. The manuscript management system is completely online and includes a very quick and fair peer-review system, which is all easy to use. Visit <http://www.dovepress.com/testimonials.php> to read real quotes from published authors.

Submit your manuscript here: <https://www.dovepress.com/clinical-cosmetic-and-investigational-dermatology-journal>