






Ingestion of Metallic Materials Found in the Stomach and First Part of the Duodenum of a Schizophrenic Man: Case Report

Telila Mesfin ¹, Yohannes Tekalegn ², Mudesir Aman³, Girma Geta ⁴, Adugna Ketema⁴, Fekata Defere ¹, Dejene Girma¹, Mesfin Tsegaye¹, Takele Mengistu¹, Kenbon Seyoum ⁴

¹Department of Medicine, Madda Walabu University Goba General Hospital, Goba, Oromia, Ethiopia; ²Department of Public Health, Madda Walabu University Goba General Hospital, Goba, Oromia, Ethiopia; ³Department of Surgery, Madda Walabu University Goba General Hospital, Goba, Oromia, Ethiopia; ⁴Department of Midwifery, Madda Walabu University Goba General Hospital, Goba, Oromia, Ethiopia

Correspondence: Kenbon Seyoum, Tel +251915821035, Email kbseyoum8@gmail.com

Introduction: Foreign body ingestion causes a serious health problems like bleeding, abscess formation, septicemia, perforation, and obstruction of the esophagus, stomach and the intestine. In adults, foreign body ingestion is more common in the elderly, individuals with mental illness or who have an intellectual disability, alcohol poisoning, prison inmates, and drug traffickers.

Case Presentation: We present a 22 year old male patient who presented with abdominal distension and vomiting of ingested matter of two to three episodes per day of one month duration. He is a known schizophrenic patient for the past three years and has been on follow up at a nearby hospital. He swallowed metallic nails in an attempt to kill himself. On abdominal examination there was distension, and epigastric tenderness. His plain abdominal x-ray showed multiple radiopaque foreign body in the stomach. Similarly, abdominal ultrasound showed thickened gastric wall and multiple linear foreign bodies in the stomach. Then, with the impression of gastric outlet obstruction secondary to foreign body in the stomach, laparotomy plus gastrotomy plus foreign body removal and repair were done under general anesthesia. Dilated stomach, palpable mass on distal stomach and first part of duodenum, and adhesion between stomach, abdominal wall and liver was found intra operatively.

Conclusion: Passage of curved metal through the throat is a rare case. Mentally ill individuals need close follow up and physiological consultation.

Keywords: foreign body ingestion, metal, Schizophrenia

Introduction

An ingested foreign body is anything (including food) that comes from outside the body and ingested to the mouth and gastrointestinal tract (GI).¹ Inedible collections or undigested material in the GI tract is known as bezoars.² Ingestion of a foreign body is a common occurrence in children between 6 months and 6 years of age, but in adults it can be accidentally swallowed with food.³ In adults, foreign body ingestion is more common in the elderly, individuals with mental illness or who have an intellectual disability, alcohol poisoning, prison inmates, and drug traffickers.^{1,4} Foreign bodies stuck in the areas of anatomical narrowing may require endoscopic or surgical intervention, however the majority of foreign bodies that pass the esophagus will exit the GI tract without incidence.^{5,6}

Foreign body ingestion causes a serious health problems like bleeding, abscess formation, septicemia, perforation, and obstruction of the esophagus, stomach and the intestine.^{1,5,7} These complications can be related to clinical manifestations such as nausea, vomiting and severe constipation based on the location and severity of obstruction and perforation.⁸ Ingested foreign materials are most of the time associated with medical disorders, anatomic abnormalities, gastric motility disorders.⁹

Case Presentation

We present a 22 year old male patient who presented with abdominal distension and vomiting of ingested matter of two to three episodes per day of one month duration. He has significant weight loss. He is a known schizophrenic patient for the past three years and has followed up at a nearby hospital, after which he has been off his medication for the past two months. He swallowed metallic nails in an attempt to kill himself. On presentation his vital signs were, blood pressure 110/70, pulse rate 128, respiratory rate 20, axillary temperature 36.5 and oxygen saturation 92%. On abdominal examination there was distension, epigastric tenderness and no signs of fluid collection. On admission his blood tests were, white blood count 15,000, hemoglobin 14 gm/dl, platelet 138,000 and granulocytes 77%. Serum electrolytes, random blood sugar and organ function tests (liver and renal) were in normal range. On the other hand, his plain abdominal x-ray showed multiple radiopaque foreign body namely nail in the stomach (Figure 1). Similarly, abdominal ultrasound showed thickened gastric wall and multiple linear foreign bodies in the stomach.

Eventually, with the impression of complete gastric outlet obstruction secondary to foreign body in the stomach, laparotomy plus gastrotomy plus foreign body removal and repair were done under general anesthesia (Figure 2). Intraoperative findings were dilated stomach, palpable mass on distal stomach and first part of duodenum, and adhesion between stomach, abdominal wall and liver. Subsequently, gastrotomy was made proximal to the foreign body area. Foreign bodies consisting of sixty curved, and straight nails of various sizes, needle and wire were removed with sponge forceps (Figure 3). Gastrotomy incision was repaired with two layers. Abdominal cavity was washed with warm normal saline. The abdominal incision was closed with two layers. The patient was then transferred to surgical ward with stable vital signs and put on antibiotics. Postoperative hematocrit was 36%. The patient was discharged after four days of hospital stay and linked to psychiatric department for further evaluation.

Discussion

Accidental and intentional ingestion of foreign bodies usually occurs in children, but anyone such as prisoners and drug traffickers can be affected.^{6,8,10} Most foreign bodies pass through the gastrointestinal tract and are passed into the feces within less than a week without surgical intervention.^{6,8} Foreign body size is predictive of passage through the alimentary tract.⁶ For example, blunt objects under 6 cm and smaller than 2.5 cm diameter are likely to easily pass.¹¹

Few studies have reported the ingestion of sharp and blunt metallic materials by the mentally ill, and prisoner individuals. These individuals present with various gastrointestinal symptoms ranging from mild to severe cramps.^{5-7,12} Mentally ill, or psychiatric patients frequently exhibit respiratory distress, choking, vomiting, unwillingness to eat, drooling, wheezing, and blood-stained saliva.¹² Similar to this, the current case was also presented with vomiting of ingested matter for the last one month.

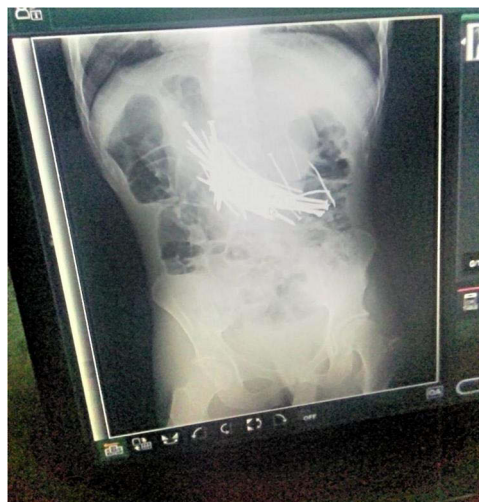

Figure 1 Plain abdominal x-ray showing multiple metallic nails in the stomach and first part of the duodenum.

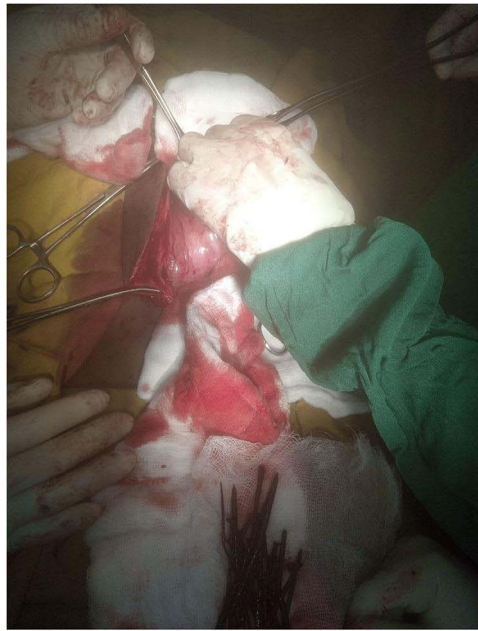

Figure 2 Intraoperative procedure showing removal of metallic nails.



Figure 3 Showing metallic nails of various sizes and shapes after removal.

Factors like hallucination may cause ingestion of foreign materials in the schizophrenic individuals.⁸ We present the known schizophrenic patient who presented with abdominal distension after ingestion of curved and straight metal nails of various sizes. The study reported that mentally ill individual ingest foreign bodies caused by hallucination,⁸ but in our case the patient ingested the metals in an attempt to kill himself. The intraoperative finding revealed sixty curved and straight nails, needle and wires. The available literature has shown that the maximum number of ingested foreign body is 158.¹³

Foreign body impaction can happen at anatomically narrowed areas such as the lower esophageal sphincter, ileocaecal valve, and anus, physiologically angled areas such as the duodenum's curvature, or pathologically strict places.¹⁰ As indicated in the current situation, curved nail can also pass the lower esophagus. Areas affected by eosinophilic esophagitis, Crohn's disease, or areas of prior surgical anastomosis can also be a possible areas of foreign body impaction.

Computed tomography scanning and diagnostic endoscopy are the preferred diagnostic modalities.¹⁴ But, plain abdominal radiograph is used most of the time as the initial method of diagnosing. Barium study can also be used to identify and estimate their size.² In current case, plain abdominal radiography was used to diagnose what is in the abdomen and laparotomy was done to remove them.

Conclusion

Case reports of metallic nail ingestion are not uncommon; however, passage of a curved nail through the esophagus is rarely reported. The current case highlights maintaining a high index of suspicion for foreign body ingestion in mentally ill patients with signs of proximal bowel obstruction. In the setting of full thickness gastric inflammatory changes, adhesion to adjacent organs is plausible as was seen in this patient. Close follow up of mentally ill patient is important.

Data Sharing Statement

Data on the case clinical information, informed consent form, and images are available for review from the corresponding author upon request.

Ethical Approval

No ethical approval is required for this case report.

Consent

Written informed consent was taken from the patient's parent for publication of his condition and accompanying images, because the patient is mentally incompetent.

Disclosure

The authors declare that there are no conflicts of interest.

References

1. BMJ. Foreign body ingestion; 2022. Available from: <https://bestpractice.bmj.com/topics/en-gb/1050>. Accessed August 13, 2022.
2. Eng K, Kay M. Review: gastrointestinal bezoars: history and current treatment paradigms. *Gastroenterol Hepatol*. 2012;8:776–778.
3. Ambe P, Weber SA, Schauer M, Knoefel WT. Swallowed foreign bodies in adults. *Dtsch Arztebl Int*. 2012;109:869–875.
4. Triadafilopoulos G. *Ingested Foreign Bodies and Food Impactions in Adults*. Saltzman JR, Ed. UpToDate; 2020.
5. Mohammed AA. Ingestion of huge number of metallic nails impacted in the stomach and cecum in a mentally abnormal woman: case report. *Int J Surg Case Rep*. 2020;70:60–63. doi:10.1016/j.ijscr.2020.04.019
6. Pagacz M, Bao P, Moreno JCA, Howard L. Nail biting as a cause of appendicitis. *Case Rep Surg*. 2020;2020:1–3. doi:10.1155/2020/3930905
7. Aihole JS, Rawat A. Fate of sharp metallic foreign bodies. *Indian Pediatr*. 2019;56:146.
8. Yıldız İ, Koca YS, Barut İ. A swallowed metal nail entrapped in the right psoas muscle. *Ulus Travma ve Acil Cerrahi Derg*. 2016;22:399–401. doi:10.5505/tjtes.2015.66814
9. Khan S, Jiang K, Ping Zhu L, et al. Upper gastrointestinal manifestation of bezoars and the etiological factors: a literature review. *Gastroenterol Res Pract*. 2019;2019:1–13. doi:10.1155/2019/5698532
10. Bisharat M, O'Donnell ME, Gibson N, et al. Foreign body ingestion in prisoners - The Belfast experience. *Ulster Med J*. 2008;77:110–114.
11. Cho EA, Lee DH, Hong HJ, et al. An unusual case of duodenal perforation caused by a lollipop stick: a case report. *Clin Endosc*. 2014;47:188–191. doi:10.5946/ce.2014.47.2.188
12. Vats M, Ramasamy S, Neogi S, Tudu SK. Ingestion of nine metallic nails with corrosive: what happened next? *BMJ Case Rep*. 2017;2017:1–5. doi:10.1136/bcr-2017-222338
13. Sabah D. 158 metal objects found in woman's stomach in eastern Turkey. Chronic ischaemic mitral regurgitation. Current treatment results and new mechanism-based surgical approaches☆; 2022.
14. Bekkerman M, Sachdev AH, Andrade J, Twersky Y, Iqbal S. Endoscopic management of foreign bodies in the gastrointestinal tract: a review of the literature. *Gastroenterol Res Pract*. 2016;2016:8520767. doi:10.1155/2016/8520767

International Medical Case Reports Journal

Dovepress

Publish your work in this journal

The International Medical Case Reports Journal is an international, peer-reviewed open-access journal publishing original case reports from all medical specialties. Previously unpublished medical posters are also accepted relating to any area of clinical or preclinical science. Submissions should not normally exceed 2,000 words or 4 published pages including figures, diagrams and references. The manuscript management system is completely online and includes a very quick and fair peer-review system, which is all easy to use. Visit <http://www.dovepress.com/testimonials.php> to read real quotes from published authors.

Submit your manuscript here: <https://www.dovepress.com/international-medical-case-reports-journal-journal>