




Superior Rectus Transposition Surgery: Safety, Efficacy, and Place in Therapy

Mohammad Reza Akbari, Babak Masoomian , Motahharez Sadeghi ,
Arash Mirmohammadsadeghi 

Eye Research Center, Farabi Eye Hospital, Tehran University of Medical Sciences, Tehran, Iran

Correspondence: Arash Mirmohammadsadeghi, Farabi Eye Hospital, Ghazvin Square, Tehran, Iran, Tel +989127927992, Fax +982155409095, Email a1sadeghi@yahoo.com

Abstract: Abduction limitation in esotropic Duane retraction syndrome (DRS), esotropic Mobius syndrome, and sixth nerve palsy is one of the difficult-to-manage problems in strabismus surgery. The procedure of superior rectus transposition (SRT) was introduced by Johnston et al. In this procedure, the superior rectus (SR) muscle is disinserted and sutured adjacent to the insertion of lateral rectus (LR) muscle. The purpose of this review is to explore literature about efficacy and safety of SRT and its usage in strabismus surgery.

Keywords: superior rectus transposition, transposition surgery, abducens nerve diseases/surgery, abducens nerve diseases/therapy

Introduction

Abduction limitation in esotropic Duane retraction syndrome (DRS), esotropic Mobius syndrome, and sixth nerve palsy is one of the difficult-to-manage problems in strabismus surgery.^{1,2} Recession of the medial rectus (MR) muscle can improve abnormal head posture and primary position esotropia (ET) in these cases, but it has minimal effect on abduction limitation.¹ A variety of transposition techniques were described in the literature that can improve abduction in the above disorders.² Vertical rectus transposition (VRT) is an effective procedure in improving abduction limitation.² However, when combined with MR recession, risk of anterior segment ischemia increased, especially in older patients with vascular problems.² There are some techniques tailored to reduce such complications, such as doing VRT and MR recession in separate steps, partial tendon transposition, ciliary-sparing transposition, vertical rectus transposition without tenotomy, and single muscle transposition (superior or inferior rectus).²

The procedure of superior rectus transposition (SRT) was introduced by Johnston et al (Johnston SC et al. IOVS 2006;47:ARVO E-Abstract 2475). In this procedure, the superior rectus (SR) muscle is disinserted and sutured adjacent to the insertion of lateral rectus (LR) muscle.³ The first published case series on SRT was the article of Mehendale et al, which reported the effectiveness of this procedure to treat DRS and sixth nerve palsy.³ The purpose of this review is to explore the literature about efficacy and safety of SRT and its usage in strabismus surgery.

Materials and Methods

The search was done in Google Scholar, Pubmed, and Scopus from 2006 to 2022 with the key words of “superior rectus transposition” or “SRT” or “transposition surgery” or “abducens nerve diseases/surgery” or “abducens nerve diseases/therapy”. Forward and backward search was also performed using references and citations of the found articles. Case reports and review articles were also included. In this search, we found 29 articles and 2 E-abstracts on the subject of SRT.^{3–31} Full texts of all articles (except one) and abstract of a Spanish article were studied.

Results

Our review was divided into the following parts:

1. Indications and contraindications
2. SRT technique
3. Amount and technique of MR recession
4. Unilateral SRT with or without MR recession
5. Adjustable techniques of SRT
6. Bilateral SRT with MR recession in sixth nerve palsy
7. Bilateral SRT with MR recession in DRS
8. SRT in Mobius syndrome
9. SRT as reoperation in DRS
10. Management of residual ET after SRT and MR recession
11. Comparison with other surgeries
12. SRT for treatment of exotropia (XT) or adduction limitation

Indications and Contraindications

SRT can be used for surgical treatment of unilateral or bilateral esotropic DRS, esotropic Mobius syndrome, and sixth nerve palsy.⁴ Among sixth nerve palsy cases, the best candidates for SRT are cases with no LR force and abduction limitation of -4 or higher.⁵ There are rare reports of nasal SRT in the treatment of XT.⁶

Negalur et al mentioned some absolute and relative contraindications for SRT, such as exotropia in adduction or severe globe retraction.⁴ In our opinion, there is no absolute contraindication for SRT use in esotropic DRS, esotropic Mobius syndrome, and sixth nerve palsy. As will be mentioned in the next parts of the article, the change in globe retraction is minimal after SRT.^{7,8} Similarly, the induced adduction limitation after SRT is minimal.⁵ The sole relative contraindication in our practice is presence of preoperative intorsion in fundus or double Maddox rod testing.⁴ Since SRT can induce incyclotorsion, the cases with preoperative intorsion are at risk of postoperative torsional diplopia.^{9–11} Therefore, although we prefer use of SRT in some circumstances, no other contraindications to its use exists in our practice.

SRT Technique

Fornix or limbal incision was used to expose the SR muscle.⁴ The attachments between SR muscle and levator palpebrae and superior oblique muscle were dissected.⁵ The SR muscle was then sutured with 6/0 polyglactin 910 sutures.⁵ It was then detached, and re-attached to the sclera along the spiral of Tillaux, adjacent to lateral rectus (LR) muscle insertion.⁵ An augmentation suture with 6/0 polyester was used in most studies.⁴ The augmentation suture was passed through the sclera, 6–12 mm posterior to the insertion of LR, incorporating one-third or one-fourth of the SR width.⁵

In some studies, SR and LR were tied together, with no scleral pass.^{3,10} The dual augmentation suture, in which scleral augmentation suture is coupled with LR-to-SR suture, described for the cases that underwent VRT,³² can also be used for SRT.

In another study, augmentation suture was used only for ET >40 PD.¹² Another study performed ciliary-sparing technique and 2–4 mm SR resection for SRT.¹³

Amount and Technique of MR Recession

The indication of adding MR recession to SRT procedure was different between the studies. Some studies performed SRT and MR recession in all cases.^{3,5,14} One study performed SRT alone (without MR recession) in the cases with negative or mildly positive forced duction testing for MR muscle.¹⁵ Two studies performed MR recession in the cases of positive forced duction testing for MR muscle.^{16,17} In the study of Agarwal et al, in DRS cases, SRT alone was performed for primary position ET <20 PD and MR recession was added for ET >20 PD.

The amount of MR recession in different studies was between 3 and 10 mm.^{3–13} Primary position deviation, amount of MR contracture, and diagnosis (DRS or sixth nerve palsy) were factors that determined the amount of MR recession.^{5,12,14–17} For example, in the study of Akbari et al, for preoperative far ET of 45 PD, 5 mm recession, for ET of 50–90 PD, 5.5–6 mm recession, and for ET >90 PD, 7 mm recession were performed.⁵ In the same study, in the DRS group, 4 mm MR recession was performed for all cases.⁵

The MR recession was performed using limbal or fornix incision and fixed, adjustable, or hemi-hang-back 6/0 polyglactin 910 sutures.^{3–13}

Unilateral SRT With or Without MR Recession

Summary of studies on unilateral SRT with or without medial rectus recession on patients with DRS and sixth nerve palsy is shown in Table 1.^{3,5,9,10,12,14–17} The studies on bilateral SRT, Mobius syndrome, and studies that compared SRT with other surgeries are described in the next parts.

Effect on Improvement of ET and Abduction

In the DRS cases, the mean effect of unilateral SRT alone on improvement of ET was about 8 PD.¹⁵ The mean effect of unilateral SRT with MR recession on improvement of ET was in the range 21–31 PD in different studies (Table 1).^{3,5,9,10,12,14,16,17}

In the sixth nerve palsy cases, the mean effect of unilateral SRT alone on improvement of ET was about 19 PD.¹⁵ The mean effect of unilateral SRT with MR recession on improvement of ET was in the range 33–60 PD in different studies (Table 1).^{3,5,9,10,12,14,16,17}

In the DRS cases, the mean effect of unilateral SRT alone on improvement of abduction limitation was about 0.8 units.¹⁵ The mean effect of unilateral SRT with MR recession on improvement of ET was in the range 1.3–2 units in different studies (Table 1).^{3,5,9,10,12,14,16,17}

In the sixth nerve palsy cases, the mean effect of unilateral SRT alone on improvement of abduction limitation was about 1 unit.¹⁵ The mean effect of unilateral SRT with MR recession on improvement of ET was in the range 1.8–3 units in different studies (Table 1).^{3,5,9,10,12,14,16,17}

Limitation of Adduction

There were mild adduction limitation (–1 to –2) after the SRT surgery, but these limitations did not induce symptoms or consecutive exotropia (XT).⁵

Induced Torsion

The main purpose of 3 articles was evaluation of torsional shift after SRT.^{9–11} SRT can cause intorsional shift in fundus and double Maddox rod testing.^{9–11} However, most cases do not have torsional diplopia.^{9–11} There are rare reported cases of persistent torsional diplopia after SRT, like the Velez et al and Merino et al studies.^{9,18}

Induced Vertical Deviation

Vertical deviations were induced in 7–23% of cases that underwent unilateral SRT, with or without MR recession (Table 1).^{3,5,9,10,12,14–17} Both hypertropia and hypotropia were seen in the eye that underwent SRT.^{3,5,9,10,12,14–17} Most induced vertical deviations are insignificant and asymptomatic.^{3,5,9,10,12,14–17}

However, there were some reported significant vertical deviations after SRT.^{17,18} In the study of Farid et al, 2 cases that underwent SRT needed reoperation due to significant vertical deviation.¹⁷ Merino et al reported a case in which vertical and torsional deviation and diplopia were induced after SRT with MR recession.¹⁸ The induced deviation in this case was treated with removal of augmented suture and SR recession.¹⁸

Over- or Under-Correction and Reoperation

Reoperation was done on 0–38% of the cases that underwent SRT, with or without MR recession (Table 1).^{3,5,9,10,12,14–17} Most reoperations were due to under-corrections, especially in large-angle sixth nerve palsy cases.^{3,5,9,10,12,14–17} Consecutive XT was rare and seen only in 2 cases in 9 studies of Table 1.^{3,5,9,10,12,14–17}

Table 1 Summary of Studies on Unilateral Superior Rectus Transposition (SRT), with or Without Medial Rectus Recession (MRc) on Patients with Duane Retraction Syndrome (DRS) and Sixth Nerve Palsy

Study	Sample Size and Target Cases	Type of Surgery	Amount of MRc (mm)	Mean Amount of Esotropia Improvement (Prism Diopters)	Mean Amount of Abduction Limitation Improvement	Induced Vertical Deviation	Induced Torsion	Eso- or Exo-Shift	Over- or Under-Correction and Reoperation
Mehendale et al ³ 2012	10 DRS 7 sixth nerve palsy	SRT + adjustable MRc	After adjust: 0–8 Mean: 5	33.9	1.6	2 sixth nerve palsy cases Mean 10 ± 2.8 PD	Postop intorsion in 3 cases Mean: 4° No torsional diplopia	No data	3 reoperation: one for over-correction 2 for under-correction
Velez et al ⁹ 2014	4 DRS 7 sixth nerve palsy	SRT with or without MRc	No data	32.5	1.4	One case: 14 PD vertical deviation	Double Maddox rod: 1°–8° of intorsional shift One case: torsional diplopia Objective torsion: One case new intorsion	No data	No data
Patil-Chhablani et al ¹⁴ 2016	13 sixth nerve palsy	SRT + MRc 2 cases: bilateral SRT + MRc	4.5–6.5	45.5	1.9	One case: hypotropia of 4 D	One case: 15° intorsion and diplopia in the early postop visit No symptom in final follow-up	No data	Two cases: large residual esotropias (≥20 PD)
Agarwal et al ¹² 2018	9 DRS 10 sixth nerve palsy	4 DRS cases: SRT 14 cases: SRT + MRc 1 DRS case: bilateral SRT + left MRc	DRS cases: 3.5 Sixth nerve palsy cases: adjustable MRc of 5–8	23.9 for DRS 45.4 for sixth nerve palsy	2 for DRS 1.8 for sixth nerve palsy	No induced vertical deviation in primary position	No torsional diplopia	DRS cases: 6.7 PD exoshift (esotropia correction) from 1 to 6 months Sixth nerve palsy cases: 10.7 PD exoshift (esotropia correction) from 1 to 6 months	No data

Akbari et al ¹⁵ 2018	11 DRS 11 sixth nerve palsy	SRT	-	7.8 for DRS 19.2 for sixth nerve palsy	0.8 for DRS 1 for sixth nerve palsy	Asymptomatic hypotropia of 2–4 PD in: 4 DRS cases 3 sixth nerve palsy cases	DRS: 3.8° Sixth nerve palsy: 3.4° induced objective torsion No torsional diplopia	No data	No data
Liu et al ¹⁶ 2019	13 sixth nerve palsy	11 cases: SRT + MRc 2 cases: SRT	6	51.4	1.5	2 cases: one eliminated with IRT surgery	No torsional diplopia, no objective torsion	No data	7 cases residual esotropia. 5 cases underwent IRT
Escuder et al ¹⁰ 2020	37 DRS 32 sixth nerve palsy	SRT with or without MRc	No data	35 PD improvement in median for DRS 40 PD improvement in median for sixth nerve palsy	No data	7% developed symptomatic vertical diplopia	12 demonstrated postoperative torsion: Of the 12, 9 (75%) with postoperative intorsional shift No torsional diplopia	No data	No data
Akbari et al ⁵ 2021	16 DRS 8 sixth nerve palsy	SRT + MRc	4 for DRS 5–7 for sixth nerve palsy	21.6 for DRS 59.7 for sixth nerve palsy	1.3 for DRS 3 for sixth nerve palsy	Asymptomatic hypotropia of 1–4 PD in: 3 DRS cases 1 sixth nerve palsy cases Asymptomatic hypertropia of 4 PD in: 1 DRS case	DRS: 5.3° Sixth nerve palsy: 8° induced objective torsion No torsional diplopia	Eso-drift at distance or near in 7 patients with DRS and 4 patients with sixth nerve palsy	No reoperation
Farid et al ¹⁷ 2021	11 DRS 10 sixth nerve palsy	18 cases: SRT + MRc 3 cases: SRT	4–5.5	31.1 for DRS 33.8 for sixth nerve palsy	2 for DRS 2.6 for sixth nerve palsy	5 cases of significant induced hypertropia >4 PD	No subjective torsional diplopia	No data	One over-correction (DRS) 3 under-corrections (sixth nerve palsy)

Eso- or Exodrift

The study of Akbari et al showed some eso-shift during postoperative follow-up in the cases that underwent SRT with MR recession.⁵ However, the study of Yang et al showed small exo-drift and the study of Agarwal et al showed larger exo-drift during postoperative follow-up in these cases.^{12,19} It seems that some cases show a shift toward ET and the others show a shift toward XT in the postoperative follow-up period.

Pre- and postoperative photos of a case with sixth nerve palsy after brain tumor surgery that underwent unilateral SRT without MR recession are demonstrated in Figure 1. Pre- and postoperative photos of a case with traumatic sixth nerve palsy that underwent unilateral SRT with MR recession are demonstrated in Figure 2. Pre- and postoperative photos of a case with esotropic DRS that underwent unilateral SRT with MR recession are demonstrated in Figure 3.

Adjustable Techniques of SRT

Two forms of adjustable techniques for SRT were described in the literature.^{20,21}

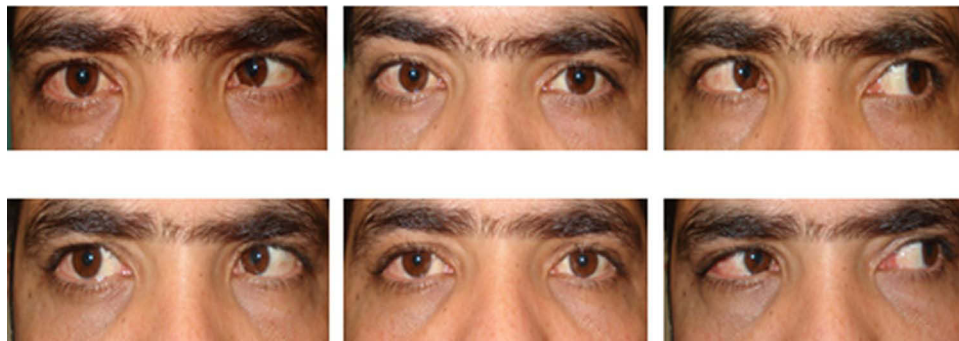

Figure 1 Pre- (up) and postoperative (down) photos of a case with sixth nerve palsy after brain tumor surgery that underwent unilateral SRT without MR recession.

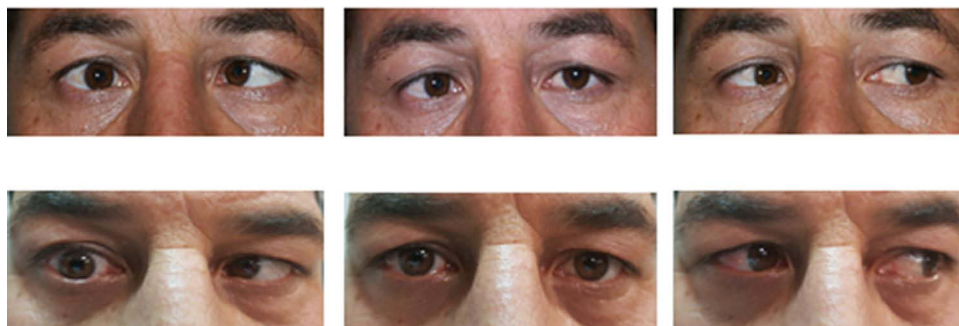

Figure 2 Pre- (up) and postoperative (down) photos of a case with traumatic sixth nerve palsy that underwent unilateral SRT with MR recession.

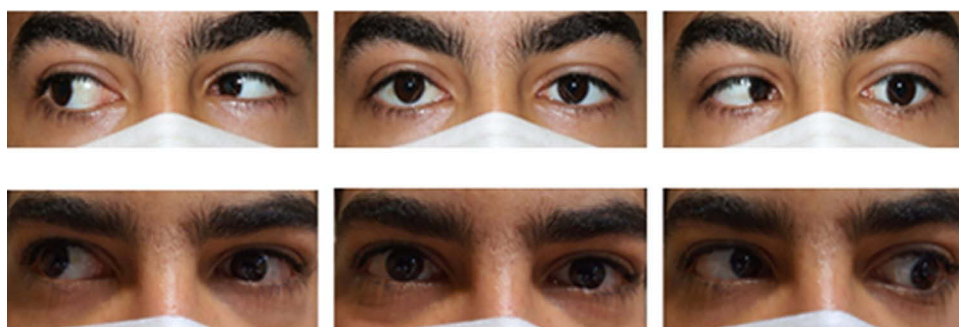

Figure 3 Pre- (up) and postoperative (down) photos of a case with esotropic DRS that underwent unilateral SRT with MR recession.

Adjustable SRT and Adjustable Augmented Suture

Velez and Pineles introduced a technique in which both SR muscle and augmented sutures were placed on an adjustable suture.²⁰ The suture used was an absorbable suture.²⁰ Induced vertical deviation was managed by loosening augmented suture.²⁰ Horizontal over-correction was managed by severing augmented suture and, if insufficient, loosening SR sutures.²⁰ The technique was performed on one case of sixth nerve palsy, and there is no published result of other cases managed with this technique.²⁰

Adjustable Graded Augmentation

Technique

Dagi et al introduced this technique in which 2 or 3 augmented sutures (6/0 polyester or polyglactin 910) were placed between SR and LR muscle bellies.²¹ Torsion was monitored intra-operatively, using Mendez ring.²¹ Induced torsion or vertical deviations were managed by cutting most distal suture.²¹ Horizontal over-correction was managed by cutting most distal suture or adjusting MR recession.²¹

Results

In the study of Dagi et al, 8 cases, including 4 cases of sixth nerve palsy, 3 DRS, and 1 Mobius, were included.²¹ With adjustable augmentation suture and 3–7 mm MR recession, 7 of 8 cases had orthotropic alignment with minimal head tilt or turn.²¹ One case was under-corrected due to scars of previous surgery.²¹

Bilateral SRT with MR Recession in Sixth Nerve Palsy

Dai et al reported a case with sixth nerve palsy that underwent bilateral SRT with bilateral MR recession (each 10 mm).²² In the Patil-Chhablani et al study, 2 of 13 cases with sixth nerve palsy underwent bilateral SRT with bilateral MR recession.¹⁴

Effect on Improvement of ET and Abduction

In the report of Dai et al, ET improved from 100 PD preoperatively to orthotropia after the operation.²² The preoperative abduction limitation was –5 in both eyes that decreased to –1 in both eyes postoperatively.²²

In the 2 cases of the Patil-Chhablani et al study, the amount of esotropia correction after the surgery was 70 and 90 PD.¹⁴ The amount of postoperative improvement in abduction was in the range 1–3 units.¹⁴

Induced Vertical Deviation or Torsion

No induced vertical deviation or fundus torsion was found after surgery for these cases.^{14,22}

Bilateral SRT with MR Recession in DRS

Only one study was found that exclusively used bilateral SRT with unilateral or bilateral MR recession.⁷ Sachdeva et al reported 4 esotropic DRS cases that underwent the procedure.⁷

Effect on Improvement of ET and Abduction

After the operation, only one of these cases had residual esotropia and the others were orthotropic.⁷ The median preoperative distance and near ET were 40 PD, and the median postoperative distance and near esotropia were 4 PD and 3 PD, respectively.⁷ The median preoperative abduction limitation was –4 that improved to –3 postoperatively.⁷

Induced Vertical Deviation or Torsion

No induced vertical deviation was found after the above procedure.⁷

Effect on Globe Retraction

In the above study, only 2 cases showed significant postoperative change in globe retraction.⁷ One case showed improvement, and the other case showed worsening of retraction.⁷

SRT in Mobius Syndrome

Three articles were found about SRT in Mobius syndrome.^{23–25} The first 2 studies underwent bilateral SRT and bilateral MR recession on 3 cases and 1 case, respectively.^{23,24} In the first study, 4 mm MR recession was performed after adjustment for all 3 cases.²³ In the second study, MR recession was performed near equator.²⁴ The third study underwent unilateral SRT with 7 mm bilateral MR recession.²⁵

Effect on Improvement of ET and Abduction

In the study of Warkad et al, the mean ET improved from preoperative amount of 70.8 PD to 6 months postoperative amount of 2.5 PD.²³ The mean abduction limitation improved from preoperative amount of -4.8 to 6 months postoperative amount of -3.5 .²³

In the case report of Zheng et al, preoperative ET was 25 PD.²⁴ Two months after the operation, there was no horizontal deviation.²⁴ Abduction limitation improved from preoperative amount of -5 to postoperative amount of -3 .²⁴

In the case report of Mehta et al, preoperative ET was 60 PD.²⁵ Three months after the operation, there was no horizontal deviation.²⁵ Abduction limitation improved from preoperative amount of -5 to postoperative amount of -3 .²⁵

Induced Vertical Deviation or Torsion

In the case report of Mehta et al, there was 12 PD left hypertropia preoperatively that changed to small right hypertropia 3 months after the operation.²⁵ The other two studies did not report any change in vertical deviations postoperatively.^{23,24}

Eso- or Exo-Drift

In the study of Warkad et al, the mean postoperative deviations showed an eso-drift.²³ One month after the operation, the mean deviation was 3.3 PD XT that changed to ET of 2.5 PD, 6 months after the operation.²³

SRT as Reoperation

Only one study was found that used SRT as a reoperation.⁸ Magli et al used SRT as a reoperation after unilateral or bilateral MR recession for 20 unilateral esotropic DRS cases.⁸

Effect on Improvement of ET and Abduction

In their study, the mean postoperative improvement in ET was 10.8 PD at distance and 9.4 PD at near.⁸ However, only 30% of cases showed significant improvement in abduction.⁸

Induced Vertical Deviation or Torsion

Slight increase in fundus torsion was found in the above study, but the patients had no torsional diplopia postoperatively.⁸ No induced vertical deviation was found postoperatively in the above study.⁸

Effect on Globe Retraction

In the above study, only 2 cases showed significant postoperative change in globe retraction.⁸ One case showed improvement, and the other case showed worsening of retraction.⁸

Figure 4 shows pre- and postoperative photos of a case with bilateral sixth nerve palsy due to brain tumor. The patient previously underwent right MR recession and Nishida procedure on the right eye. He had 30 PD residual ET in primary position and -5 limitation of abduction in the left eye. He underwent SRT and 5 mm MR recession in the left eye. Postoperatively, he was orthotropic in primary position, and limitation of abduction improved to -2 .

Figure 5 shows pre- and postoperative photos of a case with left traumatic sixth nerve palsy. The patient previously underwent left MR recession and Nishida procedure on the left eye. He had 30 PD residual ET in primary position and -5 limitation of abduction in the left eye. He underwent SRT (on previously transposed SR by Nishida procedure) and MR marginal myotomy in the left eye. Postoperatively, he was orthotropic in primary position, and limitation of abduction improved to -2 .

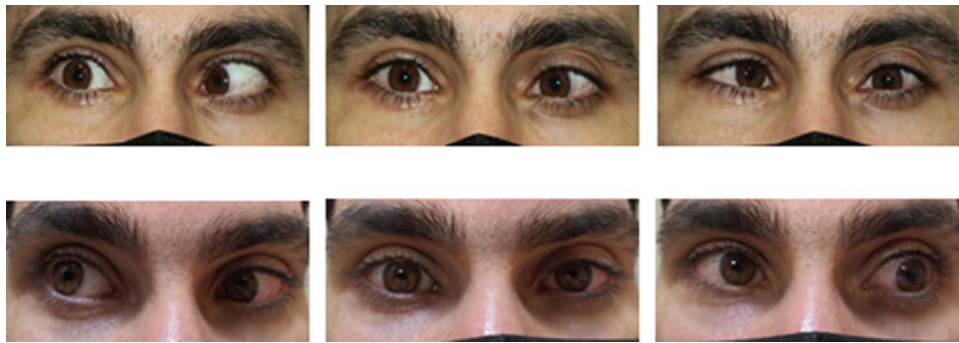

Figure 4 Pre- (up) and postoperative (down) photos of a case with bilateral sixth nerve palsy due to brain tumor. The patient previously underwent right MR recession and Nishida procedure on the right eye. He had 30 PD residual esotropia in primary position and -5 limitation of abduction in the left eye. He underwent SRT and 5 mm MR recession in the left eye. Postoperatively, he was orthotropic in primary position and limitation of abduction improved to -2 .

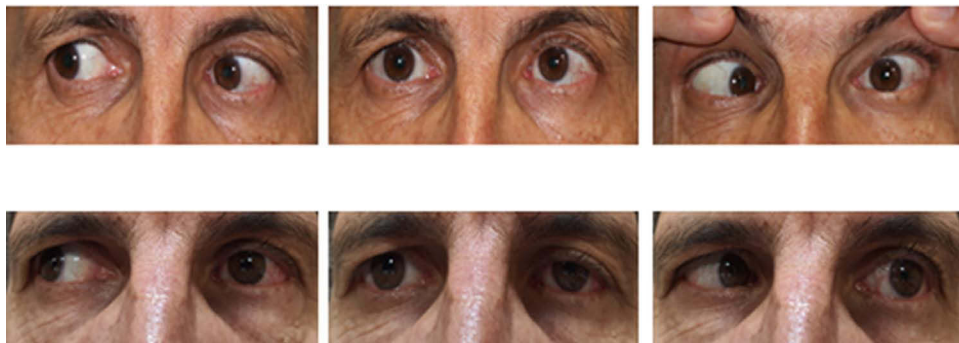

Figure 5 Pre- (up) and postoperative (down) photos of a case with left traumatic sixth nerve palsy. The patient previously underwent left MR recession and Nishida procedure on the left eye. He had 30 PD residual ET in primary position and -5 limitation of abduction in the left eye. He underwent SRT (on previously transposed SR by Nishida procedure) and MR marginal myotomy in the left eye. Postoperatively, he was orthotropic in primary position and limitation of abduction improved to -2 .

Management of Residual ET After SRT and MR Recession

Residual ET after SRT and MR recession is a problematic situation, because there is risk of anterior segment ischemia with operation of third rectus muscle. Yao et al performed inferior rectus belly transposition (modified Nishida procedure) for 3 cases with sixth nerve palsy and residual ET after SRT and MR recession.²⁶ All cases had acceptable alignment after the operation.²⁶ Hypertropia in one case was corrected with inferior rectus belly transposition.²⁶ There was no induced vertical deviation or torsion in the other two cases.²⁶

In the study of Liu et al on cases with sixth nerve palsy, 5 cases with residual ET after SRT and MR recession underwent inferior rectus transposition (IRT).¹⁶ The mean residual ET of 40 PD in these cases improved to a mean of 8 PD by IRT.¹⁶ No sign of anterior segment ischemia was seen in these cases.¹⁶

Figure 6 shows pre- and postoperative photos of a case with left sixth nerve palsy. The patient previously underwent left MR recession and SRT on the left eye. She had 14 PD residual ET in primary position and -4 limitation of abduction in the left eye. She underwent IRT in the left eye. Postoperatively, she had no horizontal deviation in primary position and limitation of abduction improved to -2 . Left hypertropia of 6 PD was induced by the procedure.

Comparison with Other Surgeries

Esotropic DRS

MR Recession versus SRT

In a randomized clinical trial, Abdallah et al compared MR recession with SRT (with or without MR recession) for esotropic DRS cases.²⁷ The mean amount of esotropia improvement was similar between the groups (19.8 PD in the SRT group and 21.6 PD in the MR recession group), but the mean improvement in abduction was greater in the SRT group

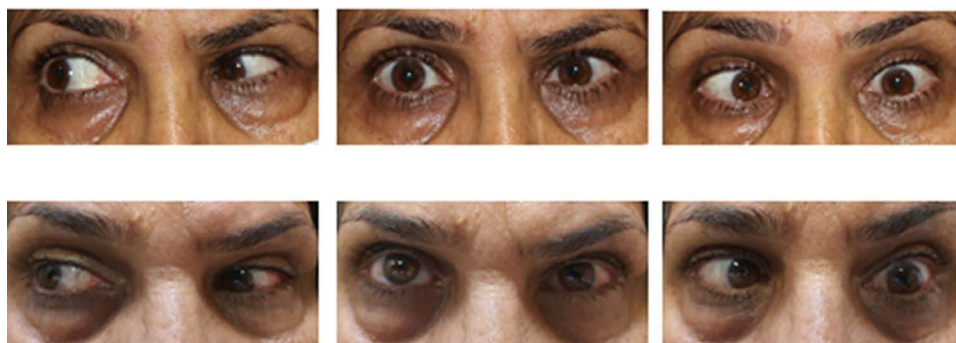

Figure 6 Pre- (up) and postoperative (down) photos of a case with left sixth nerve palsy. The patient previously underwent left MR recession and SRT on the left eye. She had 14 PD residual ET in primary position and -4 limitation of abduction in the left eye. She underwent IRT in the left eye. Postoperatively, she had no horizontal deviation in primary position and limitation of abduction improved to -2 . Left hypotropia of 6 PD was induced by the procedure.

(0.8 units) than in the MR recession group (0.3 units).²⁷ On the other hand, vertical deviation was induced postoperatively in 2 cases in the SRT group.²⁷

Tibrewal et al performed a similar study on DRS cases.²⁸ The results of the study of Tibrewal et al were partly similar to the Abdallah et al study: similar esotropia improvement in both groups and better abduction improvement in SRT group.^{27,28} However, there was no induced vertical deviation or subjective torsion in the SRT cases.²⁸

The study of Yang et al with the same design had an additional finding: small exo-drift in the SRT group and small eso-drift in the MR recession group.¹⁹

IRT versus SRT

The procedure of IRT was introduced by Velez et al.³³ In their report on 5 sixth nerve palsy cases that underwent IRT (with or without MR recession), mean correction of ET was 27 PD and mean improvement in abduction was 1 unit.³³ In another article, Farid et al performed IRT and MR recession on 11 cases with chronic sixth nerve palsy.³⁴ The mean correction of ET was 35.9 PD and mean improvement in abduction was 2.2 units.³⁴ The results of the above articles were comparable to the results of SRT and MR recession on sixth nerve palsy cases (see above).

Sener et al performed a study to compare the effect of IRT and SRT in esotropic DRS cases.¹³ They performed MR recession in some cases.¹³ The effect of SRT and IRT in improvement of ET was the same between the two groups (22.8 PD for SRT and 19.5 PD for IRT).¹³ Similarly, the mean improvement in abduction was the same between the two groups (1.4 unit improvement for SRT and 1.3 unit improvement for IRT).¹³ They recommended that SRT is a slightly better option for cases with more abduction limitation in elevation and A-pattern.¹³ Conversely, IRT is a slightly better option for cases with more abduction limitation in depression and V-pattern.¹³

Sixth Nerve Palsy

VRT versus SRT and MR Recession

Lee and Lambert compared VRT with SRT and 5–7 mm MR recession in the cases of sixth nerve palsy.²⁹ The amounts of postoperative improvement in ET and abduction limitation were approximately similar between the two groups (36.4 PD and 45.4 PD improvements in ET and 1.6 and 0.7 unit improvements in abduction in the SRT and VRT group, respectively).²⁹ However, the cases in the VRT group needed more additional procedures (botulinum toxin injection or reoperation).²⁹

Modified Vertical Muscle Belly Transposition (Modified Nishida Procedure) versus SRT

Yao et al compared SRT with modified vertical muscle belly (no split–no tenotomy) transposition in the cases with sixth nerve palsy.³⁰ MR recession, with the amounts of 4.5–10 mm, was performed in both groups.³⁰ The postoperative improvement in ET was significantly greater in the muscle belly transposition group (57.8 PD) than in the SRT group (44.6 PD), but the mean improvement in abduction was similar between the two procedures (2.3 units improvement in both groups).³⁰ In another study, Yao et al recommended that modified vertical muscle belly transposition is a better alternative than SRT for sixth nerve palsy cases with ET >60 PD.³¹

SRT for the Treatment of XT or Adduction Limitation

Kodsi reported a case with infantile XT that had residual XT after recession of both lateral recti and had fibrous and fatty MR in both eyes.⁶ SRT was performed on both eyes in this case.⁶ Ten months after bilateral SRT, XT improved from preoperative amounts of 45 PD to 10 PD.⁶ No fundus torsion was found postoperatively in this case.⁶ There was an postoperative exo-drift in this case.⁶ Two weeks after the operation, he was orthotropic.⁶ However, at 6 and 10 months visits, 10 PD intermittent XT was found.⁶

Schneider et al performed nasal SRT, with or without recession, in 2 cases of DRS type 3 and both abduction and adduction limitation. One of the cases was orthotropic, and the other had 10 PD XT in primary position. They concluded that the procedure improved binocular field of vision (Schneider JL et al. IOVS 2010;51:ARVO E-Abstract 3012).

Discussion

The present review summarized all studies on the subject of SRT. The following points and recommendations can be derived from the mentioned studies:

Unilateral SRT, without MR recession, can correct about 8 PD of ET in DRS and 19 PD of ET in sixth nerve palsy cases. Therefore, its use should be limited to small angle ET in DRS and moderate angle ET in sixth nerve palsy.

Unilateral SRT with MR recession can correct about 20–30 PD of ET in DRS and 30–60 PD of ET in sixth nerve palsy cases. Therefore, in DRS cases with ET >30 PD and sixth nerve palsy cases with ET >60 PD, operations other than SRT should be considered.

SRT, with or without MR recession, can improve abduction limitation from 1 to 3 units in DRS, sixth nerve palsy, and Mobius cases. Therefore, SRT is an effective procedure in improving abduction limitation in all of these disorders.

Adjustable techniques may help to prevent induced vertical deviation or over-correction. However, due to low risk of symptomatic vertical deviation with SRT and low rate of over-correction in the published studies (Table 1), using adjustable sutures is a matter of debate.

There is low risk of torsional diplopia after SRT surgery. However, we recommend preoperative objective or subjective torsional evaluation. In the cases with preoperative intorsion, SRT is not a good option.

In the follow-up period after SRT, there is eso-shift in some cases and exo-shift in some other cases. Therefore, reoperation for residual ET or consecutive XT after SRT should be delayed for several months.

In the cases that underwent bilateral or unilateral SRT and bilateral MR recession, the maximum amount of ET correction was 100 PD in sixth nerve palsy cases, 68 PD in Mobius cases, and 37 PD in the cases of DRS.

For residual ET after SRT and MR recession, inferior rectus belly transposition or IRT can be performed with good results.

SRT and IRT can be used interchangeably to treat esotropic DRS and sixth nerve palsy cases.

It seems that SRT, with or without MR recession, can be a better alternative to treat DRS cases than isolated MR recession, because SRT had better abduction improvement. However, there is a small risk of inducing vertical deviation with SRT.

SRT and MR recession can be a good alternative for VRT for cases of sixth nerve palsy. VRT cases may need more additional procedures in the future.

For moderate amounts of ET in sixth nerve palsy cases (<60 PD), SRT and modified Nishida procedure (both with MR recession) can be used interchangeably, but, for ET >60 PD, modified Nishida procedure is a better option.

There were only 3 case reports for SRT in XT or adduction limitation. It seems that some form of augmentation, such as SR resection, should be done for nasal SRT. In addition, the possibility of increasing globe retraction in exotropic DRS should be considered.

Conclusion

SRT is an effective and relatively safe procedure for the treatment of unilateral or bilateral esotropic DRS, esotropic Mobius syndrome, and sixth nerve palsy. The strabismus surgeon should know its limitations to perform best management for these cases.

Disclosure

The authors report no conflicts of interest in this work.

References

1. Akbari MR, Manouchehri V, Mirmohammadsadeghi A. Surgical treatment of Duane retraction syndrome. *J Curr Ophthalmol*. 2017;29(4):248–257. doi:10.1016/j.joco.2017.08.008
2. Akbari MR, Masoomian B, Mirmohammadsadeghi A, Sadeghi M. A review of transposition techniques for treatment of complete abducens nerve palsy. *J Curr Ophthalmol*. 2021;33(3):236–246. doi:10.4103/joco.joco_42_21
3. Mehendale RA, Dagi LR, Wu C, Ledoux D, Johnston S, Hunter DG. Superior rectus transposition and medial rectus recession for Duane syndrome and sixth nerve palsy. *Arch Ophthalmol*. 2012;130(2):195–201. doi:10.1001/archophthalmol.2011.384
4. Negalur M, Sachdeva V, Kekunnaya R. Superior Rectus Transposition in the management of duane retraction syndrome: current Insights. *Clin Ophthalmol*. 2022;16:201–212. doi:10.2147/OPTH.S284608
5. Akbari MR, Masoumi A, Mirmohammadsadeghi A. Superior rectus transposition and medial rectus recession for treatment of duane retraction syndrome and sixth nerve palsy. *J Binocul Vis Ocul Motil*. 2021;71(2):45–49. doi:10.1080/2576117X.2021.1879985
6. Kods SR. Bilateral superior rectus transposition for congenital exotropia associated with anomalous medial rectus muscles. *J AAPOS*. 2015;19(5):462–463. doi:10.1016/j.jaaapos.2015.04.010
7. Sachdeva V, Jain M, Badakere A, Kekunnaya R. Bilateral augmented superior rectus transposition with medial rectus recession for bilateral esotropic Duane retraction syndrome. *J AAPOS*. 2021;25(2):116–119. doi:10.1016/j.jaaapos.2020.11.006
8. Magli A, Rombetto L, Esposito Veneruso P. Reoperation in esotropic Duane retraction syndrome: long-term motor outcome of superior rectus transposition. *Eur J Ophthalmol*. 2021;31(2):722–726. doi:10.1177/1120672119897889
9. Velez FG, Oltra E, Isenberg SJ, Pineles SL. Assessment of torsion after superior rectus transposition with or without medial rectus recession for Duane syndrome and abducens nerve palsy. *J AAPOS*. 2014;18(5):457–460. doi:10.1016/j.jaaapos.2014.06.008
10. Escuder AG, Kazlas MA, Heidary G, Hunter DG, Zurakowski D, Dagi LR. Incidence of symptomatic vertical and torsional diplopia after superior rectus transposition for esotropic Duane syndrome and abducens nerve palsy. *J AAPOS*. 2020;24(5):270.e1–270.e5. doi:10.1016/j.jaaapos.2020.05.014
11. Bansal S, Green EKY. Risk of torsion in superior rectus transposition surgery augmented with posterior scleral fixation sutures. *Strabismus*. 2021;29(4):209–215. doi:10.1080/09273972.2021.1987927
12. Agarwal R, Sharma M, Saxena R, Sharma P. Surgical outcome of superior rectus transposition in esotropic Duane syndrome and abducens nerve palsy. *J AAPOS*. 2018;22(1):12–16.e1. doi:10.1016/j.jaaapos.2017.10.004
13. Sener EC, Yilmaz PT, Fatihoglu ÖU. Superior or inferior rectus transposition in esotropic Duane syndrome: a longitudinal analysis. *J AAPOS*. 2019;23(1):21.e1–21.e7. doi:10.1016/j.jaaapos.2018.10.010
14. Patil-Chhablani P, Kothamasu K, Kekunnaya R, Sachdeva V, Warkad V. Augmented superior rectus transposition with medial rectus recession in patients with abducens nerve palsy. *J AAPOS*. 2016;20(6):496–500. doi:10.1016/j.jaaapos.2016.07.227
15. Akbari M, Shomali S, Mirmohammadsadeghi A, Fard MA. Augmented superior rectus transposition procedure in Duane retraction syndrome compared with sixth nerve palsy. *Graefes Arch Clin Exp Ophthalmol*. 2018;256(5):983–987. doi:10.1007/s00417-017-3885-5
16. Liu Y, Wen W, Zou L, et al. Application of SRT plus MR recession in supra-maximal esotropia from chronic sixth nerve palsy. *Graefes Arch Clin Exp Ophthalmol*. 2019;257(1):199–205. doi:10.1007/s00417-018-4102-x
17. Farid MF, Daifalla AEM, Awwad MA. Augmented superior rectus muscle transposition in management of defective ocular abduction. *BMC Ophthalmol*. 2021;21(1):50. doi:10.1186/s12886-020-01779-1
18. Merino P, Gómez de Liaño P, Ah Kim Y. Complications of augmented superior rectus transposition in Duane syndrome. Complicaciones de la transposición aumentada de recto superior en el síndrome de Duane. *Arch Soc Esp Oftalmol*. 2017;92(4):175–177. doi:10.1016/j.oftal.2016.07.003
19. Yang S, MacKinnon S, Dagi LR, Hunter DG. Superior rectus transposition vs medial rectus recession for treatment of esotropic Duane syndrome. *JAMA Ophthalmol*. 2014;132(6):669–675. doi:10.1001/jamaophthalmol.2014.358
20. Velez FG, Pineles SL. Adjustable posterior fixation suture technique in adjustable superior rectus transposition. *J Binocul Vis Ocul Motil*. 2018;68(4):154–155. doi:10.1080/2576117X.2018.1529452
21. Dagi LR, Elhusseiny AM. Adjustable graded augmentation of superior rectus transposition for treatment of abducens nerve palsy and Duane syndrome. *J AAPOS*. 2020;24(5):268.e1–268.e7. doi:10.1016/j.jaaapos.2020.05.013
22. Dai S, Bhambhani V, Raoof N. Bilateral superior rectus transposition and medial rectus recession for bilateral sixth nerve palsy. *Am J Ophthalmol Case Rep*. 2018;9:96–98. doi:10.1016/j.ajoc.2018.01.022
23. Warkad VU, Hunter DG, Dagi AF, et al. Impact of adding augmented superior rectus transpositions to medial rectus muscle recessions when treating esotropic moebius syndrome. *Am J Ophthalmol*. 2022;237:83–90. doi:10.1016/j.ajo.2021.11.006
24. Zheng Y, Donahue SP. Bilateral superior rectus transposition with bilateral medial rectus recession for möbius syndrome. *J Pediatr Ophthalmol Strabismus*. 2017;54:e81–e82. doi:10.3928/01913913-20170907-09
25. Mehta R, Suma G, Gupta R. Augmented superior rectus transposition surgery for vertical strabismus in moebius syndrome. *Nepal J Ophthalmol*. 2016;8(16):182–185. doi:10.3126/nepjoph.v8i2.17017
26. Yao J, Xia W, Wu L, Wang X, Jiang C, Zhao C. Inferior rectus belly transposition for residual esotropia after augmented superior rectus transposition and medial rectus recession in patients with chronic abducens nerve palsy: a case series. *J AAPOS*. 2020;24(2):110–113. doi:10.1016/j.jaaapos.2019.12.006
27. Abdallah MEI, Eltoukhi EM, Awadein AR, Zedan RH. Superior rectus transposition with medial rectus recession versus medial rectus recession in esotropic duane retraction syndrome. *J Pediatr Ophthalmol Strabismus*. 2020;57(5):309–318. doi:10.3928/01913913-20200506-02
28. Tibrewal S, Sachdeva V, Ali MH, Kekunnaya R. Comparison of augmented superior rectus transposition with medial rectus recession for surgical management of esotropic Duane retraction syndrome. *J AAPOS*. 2015;19(3):199–205. doi:10.1016/j.jaaapos.2015.02.006
29. Lee YH, Lambert SR. Outcomes after superior rectus transposition and medial rectus recession versus vertical recti transposition for sixth nerve palsy. *Am J Ophthalmol*. 2017;177:100–105. doi:10.1016/j.ajo.2017.02.019

30. Yao J, Xia W, Wang X, et al. Outcomes of modified vertical rectus belly transposition versus augmented superior rectus transposition for chronic abducens nerve palsy. *J AAPOS*. 2021;25(1):7.e1–7.e6. doi:10.1016/j.jaapos.2020.09.010
31. Yao J, Jiang C, Wang X, et al. Effect of modified vertical rectus belly transposition vs augmented superior rectus transposition plus medial rectus recession for chronic sixth nerve palsy: a randomized clinical trial. *JAMA Ophthalmol*. 2022;10:1001. doi:10.1001/jamaophthalmol.2022.2856
32. Farid MF. Dual-augmented transposition of vertical recti in chronic abducens palsy. *Am J Ophthalmol*. 2019;197:59–64. doi:10.1016/j.ajo.2018.09.028
33. Velez G, Chang MY, Pineles SL. Inferior rectus transposition: a novel procedure for abducens palsy. *Am J Ophthalmol*. 2017;177:126–130. doi:10.1016/j.ajo.2017.02.021
34. Farid MF, Khater AA, Elbarky AM. Augmented inferior rectus transposition with medial rectus recession in treatment of chronic unilateral sixth nerve palsy. *BMC Ophthalmol*. 2022;22(1):337. doi:10.1186/s12886-022-02552-2

Clinical Ophthalmology

Dovepress

Publish your work in this journal

Clinical Ophthalmology is an international, peer-reviewed journal covering all subspecialties within ophthalmology. Key topics include: Optometry; Visual science; Pharmacology and drug therapy in eye diseases; Basic Sciences; Primary and Secondary eye care; Patient Safety and Quality of Care Improvements. This journal is indexed on PubMed Central and CAS, and is the official journal of The Society of Clinical Ophthalmology (SCO). The manuscript management system is completely online and includes a very quick and fair peer-review system, which is all easy to use. Visit <http://www.dovepress.com/testimonials.php> to read real quotes from published authors.

Submit your manuscript here: <https://www.dovepress.com/clinical-ophthalmology-journal>