

Rhino-Orbital Mucormycosis After COVID-19 Recovery: A Case Report

Ana Filipa Moleiro ^{1,2}, Ana Maria Cunha ¹, Rodrigo Vilares-Morgado ^{1,2}, António José Cruz³, Ana Isabel Almeida ⁴, Fernanda Peixoto¹, Fernando Falcão-Reis^{1,2}, Jorge Meira¹, Vítor Leal¹

¹Department of Ophthalmology, Centro Hospitalar e Universitário de São João, Porto, Portugal; ²Department of Surgery and Physiology, Faculty of Medicine of University of Porto, Porto, Portugal; ³Department of Infectious Diseases, Centro Hospitalar e Universitário de São João, Porto, Portugal; ⁴Department of Neuroradiology, Centro Hospitalar e Universitário de São João, Porto, Portugal

Correspondence: Ana Filipa Moleiro, Department of Ophthalmology, Centro Hospitalar e Universitário de São João, Alameda Prof. Hernâni Monteiro, Porto, 4200-319, Portugal, Tel +351 915689259, Email anafomoleiro@gmail.com

Abstract: The pandemic caused by SARS-CoV-2 remains a health care concern, despite vaccination programs. Mucormycosis, especially rhino-orbital-mucormycosis, has been described as a severe complication of COVID-19. Although it has been described mostly in India and other developing countries, few cases in the western world have also been described. We present a case of rhino-orbital-mucormycosis after recovery from severe COVID-19 in Portugal. A 75-year-old diabetic and obese man presented with right proptosis associated with right eye pain and low vision one month after recovery from severe COVID-19. Considering the most probable etiology for this clinical picture, anti-fungal therapy with liposomal amphotericin B was promptly initiated, followed by endoscopic sinus debridement. However, due to persistent and progressive infection, and after a multidisciplinary revision of the case, orbital exenteration was performed. One year after surgery, the patient is stable, without clinical or imagological signs of relapse of the disease. Although the evolution of the pandemic, along with vaccination programs, led to a lower incidence of severe COVID-19 disease, there are still patients presenting with severe COVID-19, requiring intensive care and at risk for serious complications. This case illustrates the importance of being aware of the development of post-COVID-19 mucormycosis and the need for close surveillance of patients recovering from severe COVID-19. COVID-19 prompt diagnosis and multidisciplinary approach are essential for a timely intervention achieving better survival while minimizing morbidity.

Keywords: Mucorales, SARS-CoV-2, orbit, fungal infections, exenteration

Introduction

The COVID-19 pandemic remains a health care concern, despite vaccination programs and the growing herd immunity. Indeed, vaccination programs had allowed an important control of the severity of the disease, with asymptomatic or mild disease in most patients nowadays.^{1,2} However, despite great control of the disease, the infection continues to spread worldwide, with some patients still experiencing extensive pneumonia, hypoxemic respiratory failure, shock, multiorgan failure, and eventually death.³

Indeed, emerging variants have evolved,⁴ with important consequences. This is particularly relevant since viral variants may evolve with harmful susceptibility to the immunity established with the existing COVID-19 vaccination.⁴ The new variants have shown to be more transmissible, present evasive immunological features, and also to be more predisposed to re-infection.⁴ Actually, evidence shows that the new delta variant of SARS-CoV-2 caused a higher hospital admission than the previous alpha variant.⁵ Also, a review of the health system impacts of the more recent SARS-CoV-2 variants concluded that there is a trend toward an increased risk of severe outcomes including hospitalization and mortality in the new variants of concern cases compared to wild-type SARS-CoV-2 cases.⁶

Therefore, although we still do not completely understand the pathogenesis and consequences of SARS-CoV-2 infection, it poses a continuous challenge as different disease complications keep emerging, especially with the increasing number of variants.

COVID-19 infection is frequently associated with the onset of secondary infections, especially in the most severe cases.⁷ Indeed, various authors suggest that patients with COVID-19 may have a higher risk of secondary co-infections than patients with other viral or bacterial infections.⁸ Furthermore, it seems that this higher risk is not related to pre-existing risk factors but to SARS-CoV-2 infection per se. Although bacteria are the most frequent agents in these patients, they are also at increased risk of fungal infections, which cause important morbidity and mortality.^{7,8}

Recently, with the outbreaks of COVID-19, the Indian subcontinent has witnessed a dramatic rise in mucormycosis, with a predominance of the rhino-orbital form.⁷

Rhino-orbital mucormycosis is a rare life-threatening infection caused by fungi of the Mucorales order.^{9,10} These agents are ubiquitous, occurring naturally in the environment, the body surface, and orifices, causing infection mostly in immunocompromised patients.¹⁰ The major risk factors identified for mucormycosis are diabetes mellitus (DM), especially with poor metabolic control, hematologic or solid malignancies, solid or hematopoietic transplants, severe neutropenia, primary or acquired immunodeficiencies or corticosteroid and other immunosuppressive therapies.^{9,10}

Classically, the route of dissemination involves inoculation via paranasal sinus and nasopharynx with subsequent spread to the orbit and potentially to the intracranial cavity.¹⁰ This is an invasive and necrotizing infection, characterized by an impressive invasion of the vascular lamina, and consecutive inflammation, tissue infarction, and necrosis.⁷ Therefore, due to its aggressiveness, mucormycosis is characterized by a rapid progression with high mortality, when not timely managed.⁹

Rhino-orbital mucormycosis can present with variable symptoms, including runny nose, unilateral or bilateral facial swelling, orofacial pain, low to high-grade fever, headache, blurred vision, proptosis, and, more rarely, loosening of teeth, destruction of periodontal tissue and appearance of black necrotic eschar in the palate, buccal vestibule or the maxillary alveolus along with the formation of oro-nasal communications.¹⁰

The increase of COVID-19-associated mucormycosis (CAM) in India has been associated with the high prevalence of poorly controlled DM.¹¹ However, different factors seem to contribute to this entity in COVID-19 patients, such as corticosteroid therapy and the immune dysregulation induced by the disease itself.¹² Indeed, a complicated interaction of variables, such as type-2 DM with or without diabetic ketoacidosis (DKA), chronic kidney disease (CKD), prior pulmonary issues, use of immunosuppressive medications, nosocomial infection sources, and immune system modifications caused by COVID-19, associated with the use of high-dose corticosteroids itself may result in reduced immune responses, allowing opportunistic fungal infections.¹³ Furthermore, interleukin (IL) dysregulation including an increase in IL-1 and IL-6 as well as in tumor necrosis factor-alpha (TNF-alpha), associated with lymphopenia with decreased levels of CD4 and CD8 T cells, may also contribute to susceptibility to secondary infections.¹³

Although this severe complication of SARS-CoV-2 infection is more frequent in India and other developing countries, few cases in the western world have also been described.¹⁴ The present paper aims to describe a case of a Portuguese patient with rhino-orbito-mucormycosis after recovery from severe COVID-19 disease and to discuss its implications.

Case Report

A 75-year-old man, with a previous history of obesity and type 2 DM with adequate metabolic control with oral anti-diabetics (glycated hemoglobin 5.9%), was admitted to our hospital, due to severe COVID-19. During hospitalization, he experienced several complications, including bacterial pulmonary coinfection and progression to bilateral organizing pneumonia, requiring invasive mechanical ventilation and temporary tracheostomy; right pneumothorax; kidney dysfunction with the need for renal function therapy replacement; right radial artery thrombosis associated with arterial catheter.

During the 48-day-long stay in the Intensive Care Unit, the patient required large spectrum antibacterial therapy (including vancomycin and piperacillin/tazobactam with therapeutic escalation to ertapenem and posteriorly to colistin associated with meropenem) and high-dose corticosteroid therapy (prednisolone at a dose of 2mg/Kg/day) with tapering doses over weeks. DM decompensation ensued with blood glucose levels reaching 300 mg/dL, reasonably controlled under insulin therapy.

After a total of 55 days of hospitalization, the patient was transferred to a rehabilitation unit for treatment of critical illness myopathy. At this moment, he was stable, with no need for ventilation or oxygen therapy. Blood glucose levels were consistently under 180 mg/dL, and glycated hemoglobin level was 5.4%, with insulin therapy.

One month later, the patient presented at the Ophthalmology Emergency Room complaining of swelling, pain, diplopia, and low visual acuity of the right eye (OD), with less than 24 hours of evolution.

At the ophthalmologic evaluation, best-corrected visual acuity (BCVA) was counting fingers on the OD and 20/50 (Snellen scale) on the left one (OS). Complete ophthalmoplegia of the OD with normal OS movements were evident, as well as right proptosis. Both pupils were reactive with no relative afferent pupillary defect. Slit-lamp evaluation revealed a leucoma and dense cataract on OD, with a nuclear cataract and no other remarkable findings on OS. Fundoscopy showed mild pallor of the right optic nerve and no relevant findings on OS. Orbital magnetic resonance imaging (MRI) identified an enlargement of the right orbital fissure, accompanied by contrast capture in the right orbital apex and orbital fat. Thickening of the right optic nerve sheath and contrast capture of ipsilateral inferior rectus muscle were also present (Figure 1). Furthermore, there was hypersignal on repetition time (TR) ponderations in the right sphenoidal sinus, frontoethmoidal recess, and an inflammatory thickness of ethmoidal cells and maxillary sinus mucosa.

The patient was immediately started on high-dose liposomal amphotericin B (10 mg/Kg), less than 24 hours after presentation. At 48 hours, surgical debridement was performed by Otorhinolaryngology (ORL), using an endoscopic bilateral nasosinusual approach with anterior and posterior bilateral ethmoidectomy, maxillary antrostomy, and sphenoidotomy was performed with concomitant right orbital endoscopic decompression. Both microbiological and pathological

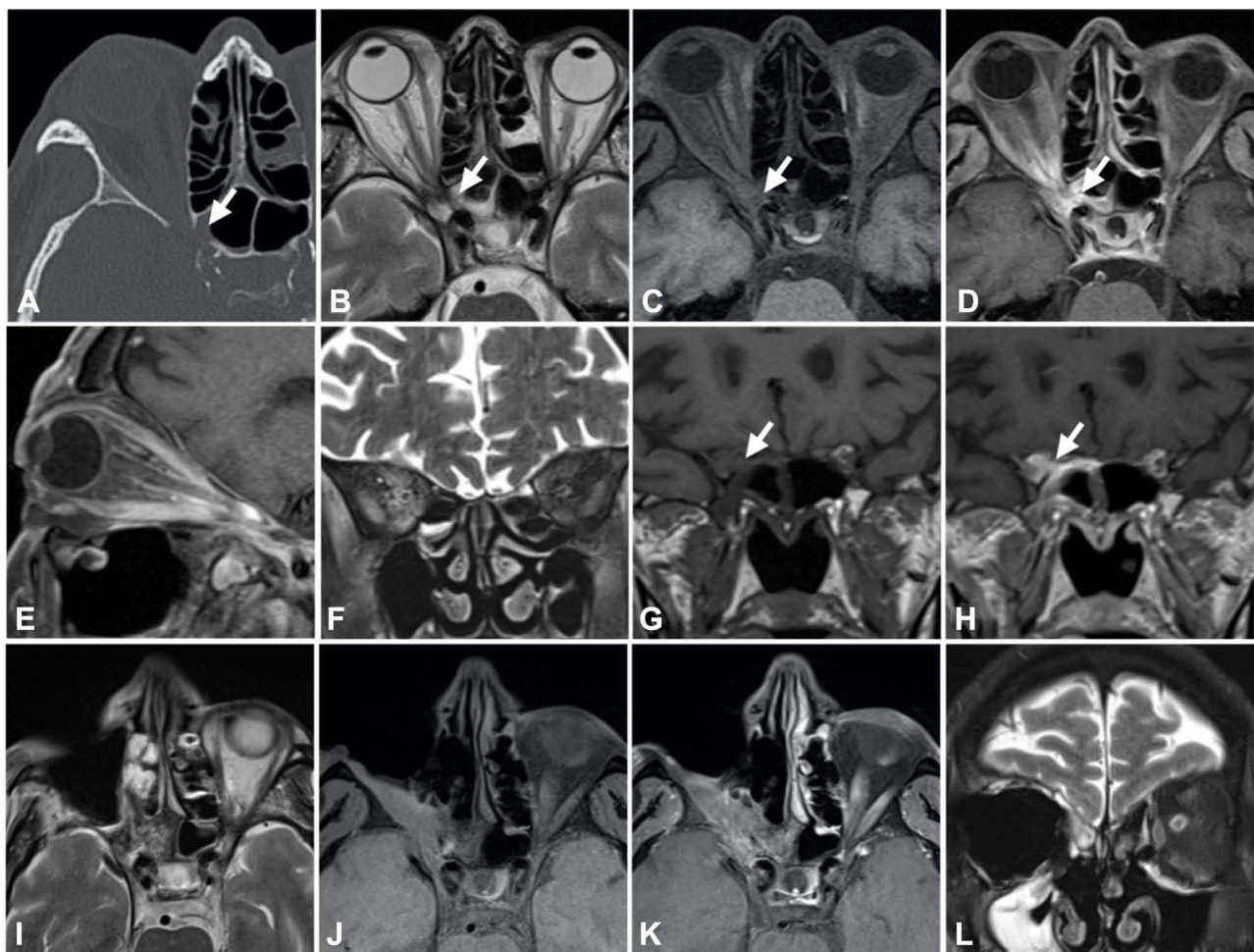


Figure 1 Orbit Computed Tomography (A) and Magnetic Resonance Imaging (B–H) at presentation depicted a defect on the lateral wall of the right sphenoid sinus (arrows in (A–D) and in (G) and (H)), that was partially opacified by hyperintense content on T2 weighted-images (B). It was observed an enlargement of the right orbital fissure and optic canal, with abnormal contrast enhancement that extended to the ipsilateral cavernous sinus, orbital apex and orbital fat, accompanied by right inferior rectus muscle enlargement and enhancement. Thickening of the right optic nerve and nerve sheath enhancement were also present. Post-operative Orbit Magnetic Resonance Imaging (I–L) showed right orbit exenteration, without abnormal enhancement in the orbital compartment and remaining focal enhancement of tissues around the anterior clinoid process and adjacent to the defect on the lateral wall of the right sphenoid sinus.

analyses of the samples removed during surgery were inconclusive, with negative fungal cultures, negative Polymerase Chain Reaction (PCR) for *Aspergillus spp* and Mucorales, and no signs of fungal structures in PAS and Grocott staining. Due to renal toxicity, antifungal therapy was switched to isavuconazole after 19 days. Twenty-two days after the first complaints, the patient had dubious light perception, complete ophthalmoplegia, an increase in OD proptosis, and de novo right afferent pupillary defect. Sequential orbital MRI showed persistence of contrast enhancement in the right orbital apex with involvement of the orbital fat, optic nerve, and inferior rectus muscle, more pronounced than in the previous exam, without progression beyond the superior orbital fissure. Therefore, after a multidisciplinary discussion, including Ophthalmology, Infectious Diseases, Neuroradiology, and Neurosurgery and considering clinical aggravation despite medical therapy and a first surgical debridement, the decision was to perform right orbit exenteration with lid sparing, which took place on the following day (Figure 2). Once again, laboratory examination of the specimen could not provide a definite diagnosis as specific fungal staining, fungal culture, and pan fungal and Mucorales-specific PCR were all negative.

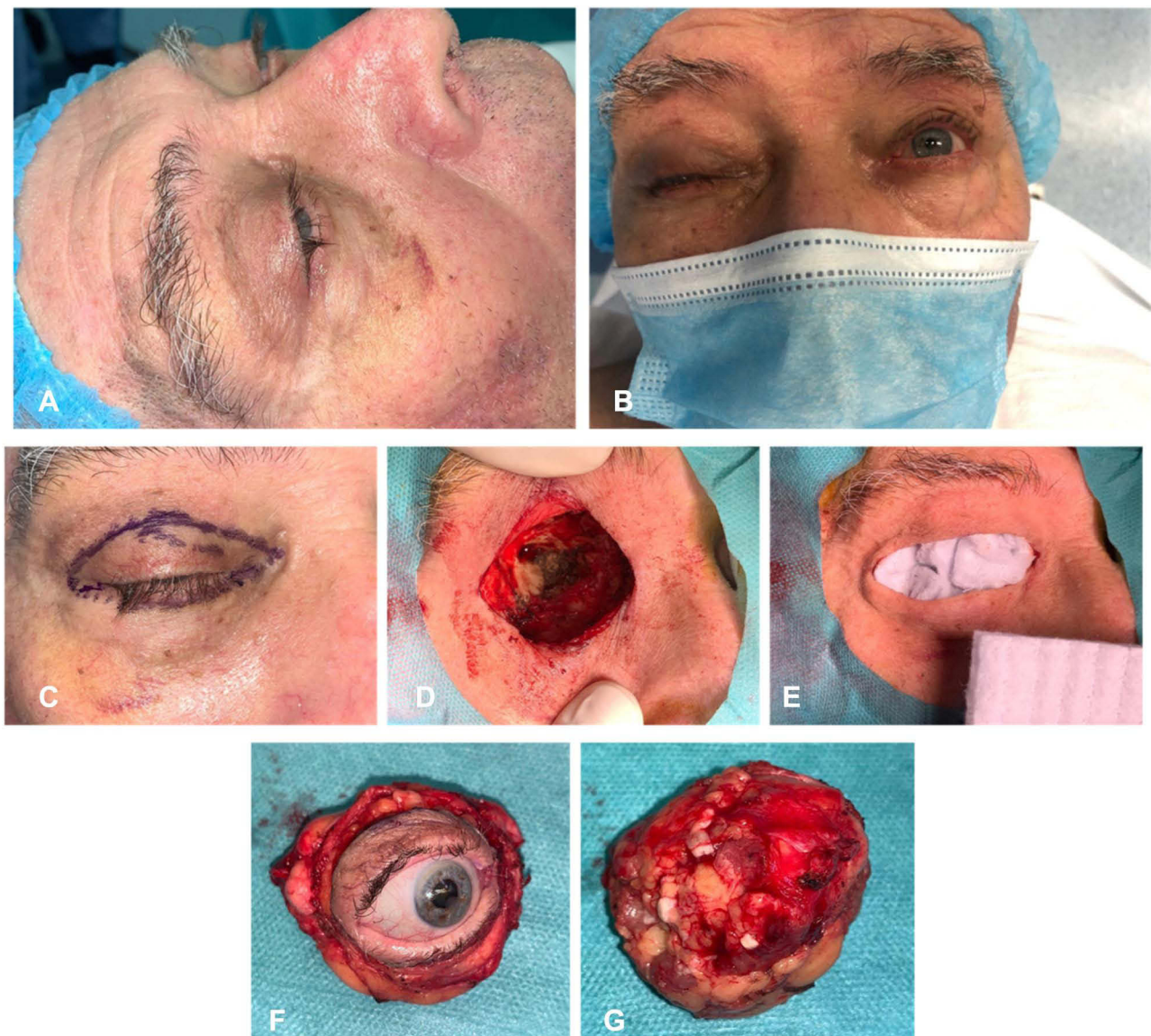

Figure 2 Intra-operative evaluation of the patient. Lateral (A) and anterior (B) evidence of right orbit proptosis and inflammatory signs. Demarcation of the surgical site, with lid-sparing (C). Intra-operative surgical locus (D) and post-operative care with calcium alginate dressing (E). Anterior (F) and posterior (G) aspects of the surgical piece.

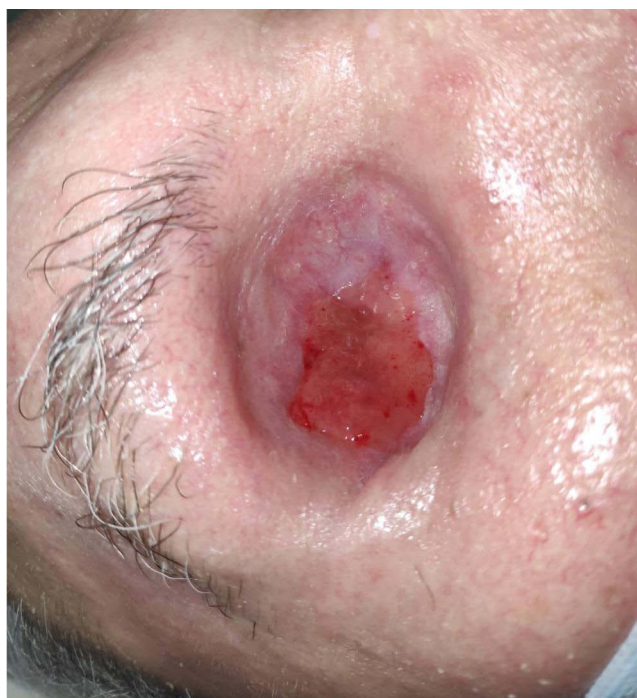

Figure 3 Wound Aspect during the follow-up. Wound healing with partial epithelization at 7 months post-surgery.

After surgery, intravenous isavuconazole was maintained for one more month with a subsequent switch to oral therapy (200 mg/day). Blood glucose levels were always kept under 180 mg/dL with insulin therapy for the duration of the stay in the ward.

One year after exenteration, under continuous antifungal treatment, the patient is stable and shows no clinical or imaging signs of relapse. The wound had both a good healing and a good cosmetic result (Figure 3). Considering the favorable evolution, isavuconazole was stopped and the patient is now under active surveillance, waiting for the placement of an orbital prosthesis.

Discussion

Mucormycosis has emerged as a potentially lethal complication of the severe COVID-19. The exact mechanism for mucormycosis development in COVID-19 patients is unclear so far, although several studies reviewed the main risk factors involved.¹⁵

DM is a known risk factor for severe COVID-19, being also associated with increased mortality. DM induces a dysregulation of the innate immune system by impairing phagocytic function. Furthermore, impaired dendritic cell responses delay the timely activation of adaptive immune responses. Concomitantly, COVID-19 itself favors DM development or worsening, including DKA.^{11,13,15,16}

High dose of steroids, acute distress respiratory syndrome, mechanical ventilation, and long-standing oxygen therapy are other consistent findings of patients with CAM.^{7,8} Steroids induce both immunosuppression and muscle catabolism and atrophy, contributing to immune dysregulation,^{7,16} besides contributing to hyperglycemia and DM worsening.¹³

Furthermore, specific pathophysiologic features of COVID-19 may promote secondary fungal infections. SARS-CoV-2 infection is characterized by immune dysregulation with T cell lymphopenia and innate immunity impairment. Also, thrombotic phenomena causing direct vascular endothelial damage may facilitate fungal invasion, as well as high levels of ferritin and iron, activation of hepcidin, and upregulation of GRP78 receptors.^{7,16}

Most described CAM cases occurred during active SARS-CoV-2 infection. Although less frequently, a few studies have demonstrated the occurrence of CAM in the recovery phase.¹⁶ Garg et al evaluated ten COVID-19 recovered patients with mucormycosis. The authors hypothesize that uncontrolled DM and prolonged use of corticosteroids may act

as culprits of rhino-orbital mucormycosis in these patients.¹⁷ Therefore, the risk for fungal infection may be increased not only during SARS-CoV-2 infection but also thereafter, suggesting long-term immune dysregulation.

Due to its severity and grade of invasion, early diagnosis and timely approach are crucial for a good outcome. Diagnosis is mainly based on clinical presentation and evolution, grounded by imaging examination with computerized tomography (TC) or MRI. Definitive diagnosis relies on microbiological and pathological studies.^{9,18} However, negative fungal stains and culture are frequent.¹⁸ Indeed, several studies reveal a very low rate of positive results, mostly due to the fragility of the Mucorales structures and the difficulty in its handling and growth *in vitro*.¹⁹ Therefore, in the context of strong clinical suspicion, neither the diagnosis should be excluded nor the therapeutic approach should be delayed or withheld, even with negative results.^{15,18}

The treatment approach to Mucormycosis is always challenging and should be multimodal.^{15,18} Antifungal therapy is the mainstay of therapy and should be implemented as soon as possible. Lipid formulations of amphotericin B are the drug of choice in most centers, with isavuconazole showing good results and stronger recommendation as an alternative in recent years.^{17,18,20}

Due to angioinvasion, blood vessel thrombosis, and tissue extensive necrosis, the drug bioavailability in the infection site is severely reduced, making medical therapy frequently insufficient.²⁰ These characteristics of the disease, along with its rapid progression through contiguous structures, warrant urgent surgical intervention, which must be a priority and clearly improve outcomes and significantly decrease mortality.^{16,18} Therefore, patients should be prepared and prioritized for diagnostic and source control surgery, even in the slightest suspicion of mucormycosis.²¹ The extension of the debridement should be decided on a case-by-case basis, considering the clinical signs and symptoms, the radiological extent of the disease and the general condition of the patient, particularly his/her potential to tolerate radical or recurrent invasive procedures.¹⁸ Orbital exenteration, the most invasive procedure, constitutes an aggressive surgery that aims to remove completely the fungal infection locus, preventing intra-cranial invasion. However, due to the aggressiveness of the surgery and the substantial morbidity it entails, this approach requires long and close postoperative care, and should always be the result of a very judicious multidisciplinary decision process (12).

In this work, we present a case of a 75-year-old diabetic patient with right orbital mucormycosis after severe COVID-19 infection, managed in an intensive care unit with a high corticosteroid dose, and invasive ventilation. Several risk factors concur to explain the development of this complication in this patient, suggesting a multifactorial origin for the infection, which is in line with the literature. Besides DM and severe COVID-19, the consequent physical debility may have also contributed to CAM development due to its impact on immune dysregulation. Actually, low muscle mass is known to induce immune dysregulation, which may justify the development of fungal invasion in already susceptible patients.²²

Although prompt antifungal treatment was provided, infection progressed leading to the need for surgical debridement as the only definite treatment, a decision that, as pointed out above, was the result of a thoughtful multidisciplinary consensus, in which the patient should be included.²¹ Gupta et al tried to describe an algorithm for risk assessment in patients with CAM and considered orbit invasion as a surrogate for extensive disease, adversely affecting the prognosis and indicating the need for more invasive procedures.¹⁸ In our patients, orbit exenteration in association with endoscopic debridement and medical therapy resulted in a good outcome, with effective infection control.

This case illustrates the need for a regular and attentive follow-up of patients during and after severe COVID-19 recovery. Mucormycosis is a very rare and destructive disease and early diagnosis is a crucial factor for a better outcome. Special attention should be paid to the initial symptoms, such as, in the case of the rhino-orbital form, headache, facial pain over the paranasal sinuses, dental pain, facial swelling, or nasal stuffiness or crusting, especially in patients recovered from severe COVID-19 with main risk factors for CAM.^{16,18}

In addition to prompt diagnosis, optimal management of CAM can only be achieved by a coordinated and interdisciplinary approach. A multidisciplinary team, preferentially in reference and experienced centers, is essential for a timely intervention to achieve better survival while minimizing morbidity.

The recent success of vaccination programs has made it possible to significantly reduce the number of severe COVID-19 cases. Indeed, most infections are now mild and managed at home. Nevertheless, some patients still develop severe disease, and the need for intensive care unit admission is still a reality. Furthermore, the increasing number of SARS-CoV-2 variants sustains the possibility of new outbreaks of the disease in the near future, which makes the awareness of the possible complications of the disease all the more important. Finally, a well-coordinated public health effort, with broad and effective

vaccination programs, is still required to stay ahead of the inevitable emergence of new variants that might severely expedite the pandemic's progression.

Conclusion

In conclusion, mucormycosis is an emerging problem associated with severe COVID-19, being a devastating condition with a poor prognosis. This case illustrates the need for awareness of this entity and close surveillance of severe COVID-19 patients not only during active disease but also during the first months after recovery.

Statement of Ethics

Written informed consent was obtained from the patient for publication of the detailed case, including images. No institutional approval was required to publish the case details.

Disclosure

The authors report no conflicts of interest in this work.

References

1. Coccia M. Optimal levels of vaccination to reduce COVID-19 infected individuals and deaths: a global analysis. *Environ Res.* 2022;204(Pt C):112314. doi:10.1016/j.envres.2021.112314
2. Liang LL, Kuo HS, Ho HJ, Wu CY. COVID-19 vaccinations are associated with reduced fatality rates: evidence from cross-county quasi-experiments. *J Glob Health.* 2021;11:05019. doi:10.7189/jogh.11.05019
3. World Health Organization. Weekly epidemiological update on COVID-19, 8 June 2022; 2022.
4. Chavda VP, Patel AB, Vaghasiya DD. SARS-CoV-2 variants and vulnerability at the global level. *J Med Virol.* 2022;94(7):2986–3005. doi:10.1002/jmv.27717
5. Twohig KA, Nyberg T, Zaidi A, et al. Hospital admission and emergency care attendance risk for SARS-CoV-2 delta (B.1.617.2) compared with alpha (B.1.1.7) variants of concern: a cohort study. *Lancet Infect Dis.* 2022;22(1):35–42. doi:10.1016/S1473-3099(21)00475-8
6. Dol J, Boulos L, Somerville M, et al. Health system impacts of SARS-CoV-2 variants of concern: a rapid review. *BMC Health Serv Res.* 2022;22(1):544. doi:10.1186/s12913-022-07847-0
7. Ravani SA, Agrawal GA, Leuva PA, Modi PH, Amin KD. Rise of the Phoenix: mucormycosis in COVID-19 times. *Indian J Ophthalmol.* 2021;69(6):1563–1568. doi:10.4103/ijoo.IJO_310_21
8. Chiurlo M, Mastrangelo A, Ripa M, Scarpellini P. Invasive fungal infections in patients with COVID-19: a review on pathogenesis, epidemiology, clinical features, treatment, and outcomes. *New Microbiol.* 2021;44(2):71–83.
9. Roden MM, Zaoutis TE, Buchanan WL, et al. Epidemiology and outcome of zygomycosis: a review of 929 reported cases. *Clin Infect Dis.* 2005;41(5):634–653. doi:10.1086/432579
10. Janjua OS, Shaikh MS, Fareed MA, et al. Dental and oral manifestations of COVID-19 related mucormycosis: diagnoses, management strategies and outcomes. *J Fungus.* 2021;8(1):44. doi:10.3390/jof8010044
11. Hussain S, Baxi H, Riad A, et al. COVID-19-Associated Mucormycosis (CAM): an updated evidence mapping. *Int J Environ Res Public Health.* 2021;18(19):10340. doi:10.3390/ijerph181910340
12. Bayram N, Ozsaygılı C, Sav H, et al. Susceptibility of severe COVID-19 patients to rhino-orbital mucormycosis fungal infection in different clinical manifestations. *Jpn J Ophthalmol.* 2021;65(4):515–525. doi:10.1007/s10384-021-00845-5
13. Chavda VP, Apostolopoulos V. Mucormycosis - an opportunistic infection in the aged immunocompromised individual: a reason for concern in COVID-19. *Maturitas.* 2021;154:58–61. doi:10.1016/j.maturitas.2021.07.009
14. Muthu V, Rudramurthy SM, Chakrabarti A, Agarwal R. Epidemiology and pathophysiology of COVID-19-associated mucormycosis: India versus the rest of the world. *Mycopathologia.* 2021;186(6):739–754. doi:10.1007/s11046-021-00584-8
15. Yasmin F, Najeeb H, Naem A, et al. COVID-19 associated mucormycosis: a systematic review from diagnostic challenges to management. *Diseases.* 2021;9(4). doi:10.3390/diseases9040065
16. Kumar A. Mucormycosis in COVID-19 recovered patients. *J Med Virol.* 2021;94(4):1272.
17. Garg R, Bharangar S, Gupta S, Bhardwaj S. Post covid-19 infection presenting as rhino-orbital Mycosis. *Indian J Otolaryngol Head Neck Surg.* 2021;1–8. doi:10.1007/s12070-021-02722-6
18. Gupta NK, Kapre M, Gupta H, et al. Risk based decision algorithms for management of COVID-19 associated rhino-orbital mucormycosis. *Indian J Otolaryngol Head Neck Surg.* 2021. 1–8. doi:10.1007/s12070-021-02692-9
19. Lackner M, Caramalho R, Lass-Flörl C. Laboratory diagnosis of mucormycosis: current status and future perspectives. *Future Microbiol.* 2014;9(5):683–695. doi:10.2217/fmb.14.23
20. Cornely OA, Alastruey-Izquierdo A, Arenz D, et al. Global guideline for the diagnosis and management of mucormycosis: an initiative of the European Confederation of medical mycology in cooperation with the Mycoses study group education and research consortium. *Lancet Infect Dis.* 2019;19(12):e405–e421.
21. Ulas B, Kursun E, Turunc T, Demiroglu YZ, Pelit A. Scoring system evaluation for orbital exenteration in patients with rhino-orbito-cerebral mucormycosis. *J Fr Ophthalmol.* 2021;45:47–52. doi:10.1016/j.jfo.2021.07.008
22. Dobner J, Kaser S. Body mass index and the risk of infection - from underweight to obesity. *Clin Microbiol Infect.* 2018;24(1):24–28. doi:10.1016/j.cmi.2017.02.013

International Medical Case Reports Journal

Dovepress

Publish your work in this journal

The International Medical Case Reports Journal is an international, peer-reviewed open-access journal publishing original case reports from all medical specialties. Previously unpublished medical posters are also accepted relating to any area of clinical or preclinical science. Submissions should not normally exceed 2,000 words or 4 published pages including figures, diagrams and references. The manuscript management system is completely online and includes a very quick and fair peer-review system, which is all easy to use. Visit <http://www.dovepress.com/testimonials.php> to read real quotes from published authors.

Submit your manuscript here: <https://www.dovepress.com/international-medical-case-reports-journal-journal>