

Spontaneous development of macular ischemia in a case of racemose hemangioma

Dimitrios Panagiotidis
Dimitrios Karagiannis
Ioannis Tsoumpris

Second Ophthalmology Department
of Athens University, Attikon Hospital,
Athens, Greece

Purpose: To report a rare case of racemose hemangioma which developed spontaneous macular ischemia.

Methods: A 32-year-old healthy Caucasian lady presented complaining of recent deterioration of vision in her left eye. At presentation, her best corrected visual acuity (BCVA) was 20/20 in her right eye and counting fingers in her left eye (LE). Fundus examination and fluorescein angiography were performed. The patient had regular follow-up appointments over a period of 8 years.

Results: Fundus examination and fluorescein angiography revealed findings consistent with arteriovenous communications of the retina or racemose hemangioma, in the posterior pole of the LE with the presence of macular ischemia. Complete and systemic examination was unremarkable, excluding the possibility of Wyburn-Mason syndrome. Eight years after presentation, findings and BCVA in the LE have remained stable, with no extension of the retinal ischemia or development of neovascularization.

Conclusion: Although extensive retinal ischemia has been reported to result in complications such as retinal or iris neovascularization, in our case the macular ischemia has not expanded further over a period of 8 years. However, due to this macular ischemia the patient unfortunately lost her central vision.

Keywords: racemose hemangioma, macular ischemia, retinal ischemia

Introduction

Racemose hemangioma is rare. The development of extensive retinal ischemia including macular ischemia resulting in rubeosis has been reported. We describe a case of racemose hemangioma which spontaneously developed macular ischemia alone, resulting in poor visual acuity. This finding has remained stable over a follow-up period of 8 years with no further complication.

Case report

A 32-year-old healthy Caucasian lady presented complaining of recent deterioration of vision in her left eye (LE). At presentation, her best corrected visual acuity (BCVA) was 20/20 in her right eye and counting fingers in her LE. The anterior segment and intraocular pressures were normal in both eyes. Fundus examination and fluorescein angiography revealed findings consistent with arteriovenous communications of the retina or racemose hemangioma, in the posterior pole of the LE with the presence of macular ischemia (Figures 1 and 2). There were no other signs of peripheral ischemia. Complete and systemic examination including MRI scan was unremarkable,

Correspondence: Dimitrios A Karagiannis
Second Ophthalmology Department
of Athens University, Attikon Hospital
Eleftherotrias 49B str, Kifissia 14562,
Athens, Greece
Tel +30 694 597 3800
Fax +30 210 882 8471
Email dimitrioskaragiannis@doctors.org.uk

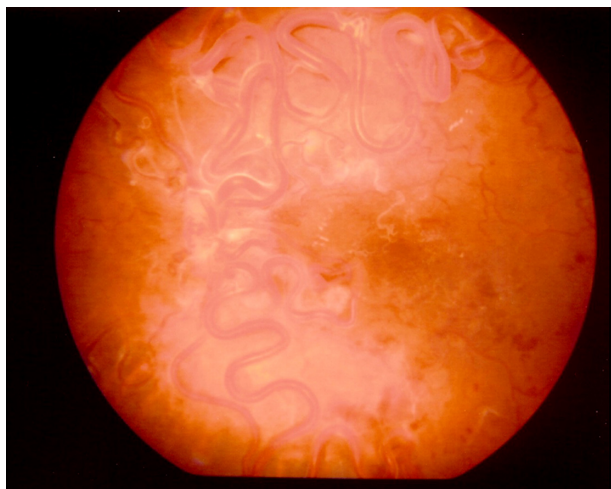


Figure 1 Color fundus picture of the left eye at presentation showing the retinal racemose angioma. The optic disc is obscured by vessels. The retinal vessels in the macular area are white indicating ischemia. Findings remained stable over the 8 year follow-up period.

excluding the possibility of Wyburn-Mason syndrome with arteriovenous malformations of the optic nerve and midbrain. There was no family history of note. Eight years after initial presentation, findings and BCVA in the LE have remained stable, with no extension of the retinal ischemia or development of neovascularization.

Comment

Congenital unilateral arteriovenous malformations of the retinal vasculature are rare. The lesions have been reported either to remain static or regress¹⁻² or to enlarge gradually.

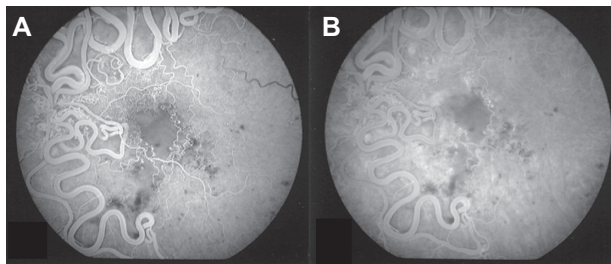


Figure 2 Early (A) and late (B) phases of fundus fluorescein angiography of the left eye showing macular ischemia and extensive arteriovenous communications and dilated intertwined vessels. There are small hemorrhages and exudates and white (sheathed) vessels in the macular area.

Vision may be affected directly due to macular involvement or by producing hemorrhage or exudation.^{3,4} Based on Archer et al the angioma in our case was grade 3, although there were no systemic findings.⁵ We present a case of racemose hemangioma which spontaneously developed macular ischemia. Although extensive retinal ischemia has been reported to result in complications such as retinal or iris neovascularization,¹ in our case the macular ischemia has not expanded further over a period of 8 years. However, due to this macular ischemia the patient unfortunately lost her central vision. The etiology of the ischemia is unclear. It has been postulated that either an enlarged malformation using part of the blood supply of the retina may cause ischemia, or there was a partial thrombosis which caused circulatory stasis within the lesion.^{6,7}

Disclosure

The authors report no conflict of interest in this work.

References

1. Bloom PA, Laidlaw A, Easty DL. Spontaneous development of retinal ischaemia and rubeosis with retinal racemose angioma. *Br J Ophthalmol.* 1993;77(2):124–125.
2. Rundles WZ, Falls HF. Congenital arteriovenous (racemose) aneurysm of the retina: report of 3 cases. *Arch Ophthalmol.* 1951;46(4):408–418.
3. Meyer CH, Rodriguez EB, Mennel S, Klinqmuller V, Kroll P. Functional and anatomical investigations in racemose hemangioma. *Acta Ophthalmol Scand.* 2007;85(7):764–771.
4. Yang C, Liu YL, Dou HL, Lu XR, Qian F, Zhao L. Unilateral hemi-central retinal vein obstruction associated with retinal racemose angioma. *Jpn J Ophthalmol.* 2009;53(4):435–436.
5. Archer DB, Deutman A, Ernest JT, Krill AE. Arteriovenous communications of the retina. *Am J Ophthalmol.* 1973;75(2):224–241.
6. Traboulsi EI. Neovascular glaucoma and ischemia. *J Clin Neuroophthalmol.* 1986;6(2):126.
7. Mansour AM, Wells CG, Jampol LM, Kalina RE. Ocular complications of arteriovenous malformations of the retina. *Arch Ophthalmol.* 1989;107(2):232–236.

Clinical Ophthalmology

Publish your work in this journal

Clinical Ophthalmology is an international, peer-reviewed journal covering all subspecialties within ophthalmology. Key topics include: Optometry; Visual science; Pharmacology and drug therapy in eye diseases; Basic Sciences; Primary and Secondary eye care; Patient Safety and Quality of Care Improvements. This journal is indexed on

Submit your manuscript here: <http://www.dovepress.com/clinical-ophthalmology-journal>

Dovepress

PubMed Central and CAS, and is the official journal of The Society of Clinical Ophthalmology (SCO). The manuscript management system is completely online and includes a very quick and fair peer-review system, which is all easy to use. Visit <http://www.dovepress.com/testimonials.php> to read real quotes from published authors.