

# Fully Endoscopic 360° Decompression for Central Lumbar Spinal Stenosis Combined with Disc Herniation: Technical Note and Preliminary Outcomes of 39 Cases

Shengwei Meng<sup>1,\*</sup>, Derong Xu<sup>1,\*</sup>, Shuo Han<sup>1</sup>, Guanghui Li<sup>1</sup>, Yan Wang<sup>1</sup>, Yanqing Shen<sup>2</sup>, Kai Zhu<sup>1</sup>, Antao Lin<sup>1</sup>, Ruiting Wang<sup>3</sup>, Xuexiao Ma<sup>1</sup>, Chuanli Zhou<sup>1</sup>

<sup>1</sup>Department of Spinal Surgery, The Affiliated Hospital of Qingdao University, Qingdao, Shandong, People's Republic of China; <sup>2</sup>Operating Room, Affiliated Hospital of Qingdao University, Qingdao, Shandong, People's Republic of China; <sup>3</sup>Medical Insurance Audit Department, Affiliated Hospital of Qingdao University, Qingdao, Shandong, People's Republic of China

\*These authors contributed equally to this work

Correspondence: Chuanli Zhou; Xuexiao Ma, Department of Spinal Surgery, The Affiliated Hospital of Qingdao University, No. 59 Haier Road, Qingdao, Shandong, 266000, People's Republic of China, Tel +86 1866 1809796; +86 1866 1807895, Email justin\_5257@hotmail.com; maxuexiaospinal@163.com

**Purpose:** To evaluate the outcomes, feasibility, and safety of endoscopic unilateral laminectomy, bilateral decompression and discectomy (Endo-ULBDD) for central lumbar spinal stenosis (CLSS) combined with disc herniation (DH).

**Methods:** This study includes 39 patients diagnosed with CLSS combined with DH who met the inclusion criteria and underwent surgery for Endo-ULBDD from April 2020 to March 2021. The mean age of the patients, operation time, hospitalization time, time in bed, and complications were recorded. Patients were followed up for at least 12 months. Visual analog scale (VAS) scores for low-back and lower-limb pain and Oswestry Disability Index (ODI) scores were evaluated preoperatively, before discharge, and at 3, 6, and 12 months postoperatively. To evaluate clinical effectiveness 12 months postoperatively, the modified MacNab criteria were used.

**Results:** The mean age of the patients was 59.9 years, the mean operation time was 82.1 minutes, the mean hospitalization time was 3.7 days, and the mean time in bed was 20.9 hours. The mean VAS scores of low-back and lower-limb pain improved from 5.9 and 7.2 to 2.0 and 1.6, respectively ( $P < 0.05$ ). The ODI score improved from 56.0 to 16.7 ( $P < 0.05$ ). The overall excellent-good rate of the modified MacNab criteria was 89.7%. Two kinds of complications occurred in 4 patients (10.3%), including 1 patient whose inferior articular process was excessively removed and 3 patients who suffered from postoperative dysesthesia. No other severe complications were noted.

**Conclusion:** Endo-ULBDD is a safe, feasible, efficient, and minimally invasive approach to treating CLSS combined with DH.

**Keywords:** endoscopic spinal surgery, laminectomy, discectomy, lumbar spinal stenosis, intervertebral disc displacement

## Introduction

Lumbar spinal stenosis (LSS) and lumbar disc herniation (LDH) are the two most common degenerative diseases of the lumbar spine. Patients with LSS often experience weakness, tiredness, or heaviness of the legs after walking a short distance and must stop to rest, which is referred to as neurogenic claudication.<sup>1</sup> In addition, this is the most common symptom of central lumbar spinal stenosis (CLSS).<sup>2</sup> However, the common symptoms and signs of LDH include lower-limb sciatica, paresthesia, and weakness of muscle strength in the distribution of one or more roots of the lumbar and sacral nerve.<sup>3</sup> Thus, both diseases can severely affect patients' daily lives. When patients' symptoms are not effectively alleviated after regular conservative treatment or when pain becomes unbearable, surgery may be recommended.<sup>1,3</sup>

Currently, percutaneous endoscopic lumbar discectomy and decompression, includes transforaminal and interlaminar approach. The transforaminal approach is most suited for discectomy and foraminal stenosis (through foraminoplasty) – not as well suited for central stenosis. However, the interlaminar approach is most effective for central and lateral recess decompression and is not effective in addressing foraminal or extraforaminal pathology, including disc herniations.<sup>4,6</sup> In most cases, CLSS is caused by a combination of facet arthropathy and ligamentous hypertrophy, with or without disc bulge. In some cases, CLSS is accompanied by DH. However, achieving thorough treatment of CLSS combined with DH using a percutaneous endoscopic spine system remains difficult. Currently, the most widely used surgical method for this pathological type of LSS is open lumbar spinal decompression and interbody fusion. Disadvantages of conventional open surgery include severe trauma, increased bleeding, slow recovery, more complications, and high cost. Endoscopic unilateral laminectomy and bilateral decompression (Endo-ULBD) is another minimally invasive surgery for CLSS that gained popularity.<sup>6</sup> However, Endo-ULBD is not suitable for patients diagnosed with CLSS combined with DH, especially for those who require bilateral resection of DH.

Thus, in our clinical work, we tried a fully endoscopic 360° decompression technique, endoscopic unilateral laminectomy, bilateral decompression and discectomy (Endo-ULBDD), to treat patients diagnosed with CLSS combined with DH. This paper reports our technical notes of Endo-ULBDD and the preliminary outcomes of 39 cases.

## Materials and Methods

### Participants

From April 2020 to March 2021, we treated 46 patients diagnosed with CLSS combined with DH using Endo-ULBDD and 39 of them met the inclusion criteria. All procedures were authorized by the ethics committee of our institution. The written informed consent was received from all patients. We protected the privacy and vital interests of patients, as required by the Declaration of Helsinki.

The inclusion criteria were as follows: (1) diagnosis of CLSS combined with DH; (2) consistent symptoms, signs, and imaging findings; (3) complaints of neurogenic claudication and bilateral lower-limb pain or numbness with or without low-back pain and treated nonsurgically for more than 3 months with limited therapeutic effect or no therapeutic effect with conservative treatment; (4) understanding the details of the surgery, including the mechanism of operation, possible outcomes, potential risks, and complications; (5)  $\geq 12$ -month follow-up after surgery.

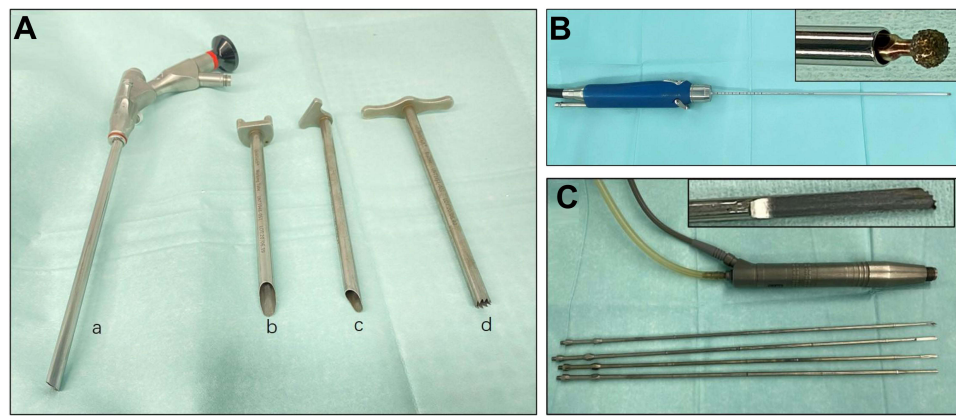
Exclusion criteria were patients (1) with severe cauda equina syndrome; (2) with peripheral nerve disease, such as diabetic peripheral neuropathy; (3) with dynamic instability or grade II or higher spondylolisthesis;<sup>7,8</sup> (4) who could not be anesthetized or had inoperable medical disease; and (5) who were uncooperative.

### Surgical Technique

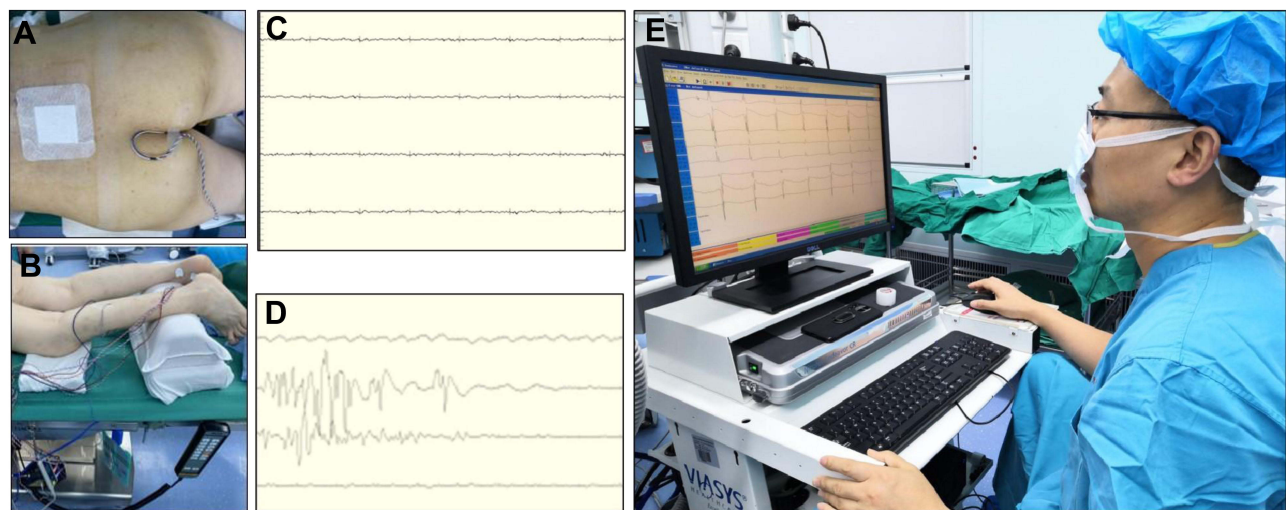
We performed all operations using the Endo-surgi Plus system (Shanghai Maoyu Medical (Group) Co., LTD, China) with an endoscopic high-speed diamond bur or piezosurgery. The spinal endoscope and special instruments used in the surgery are shown in [Figure 1](#). To prevent bleeding, tranexamic acid (1 g) was used preoperatively. Monitoring the intraoperative nerve function was necessary, especially the cauda equina and contralateral traversing nerve root, to prevent neurologic deficits ([Figure 2A–E](#)).

### Skin Marking and Working Cannula Placing

All patients were placed in the prone position on a radiolucent table after receiving general anesthesia. We adjusted the operation table to maintain the target intervertebral space perpendicular to the ground. The entry point of the skin was marked with C-arm fluoroscopy assistance and was located at the inner upper margin of the inferior pedicle, which was also called the original point ([Figure 3A and B](#)). The structures of the original point in the visual field of the endoscope included the interlaminar window, inferior articular process, inferior margin of the cranial lamina, and superior margin of the caudal lamina. After disinfection and draping, the puncture needle was inserted into the original point with the assistance of C-arm fluoroscopy ([Figure 3C](#)). Next, we injected 20 mL  $2 \times 10^{-6}$  g/mL epinephrine for a single segment into the surrounding soft tissue along the puncture path and onto the bone surface to reduce bleeding. Thereafter, we made an approximately 1-cm transverse incision through the skin, subcutaneous tissue, and deep fascia. Subsequently,



**Figure 1** Endoscope of Endo-surgi Plus system and special instruments used in the operation. (A-a) An endoscope, (A-b) a U-shaped cannula (outer working cannula), (A-c) a T-shaped cannula (inner working cannula), and (A-d) a full-visualized trepan. (B) An endoscopic high-speed diamond bur and (C) an endoscopic piezosurgery.

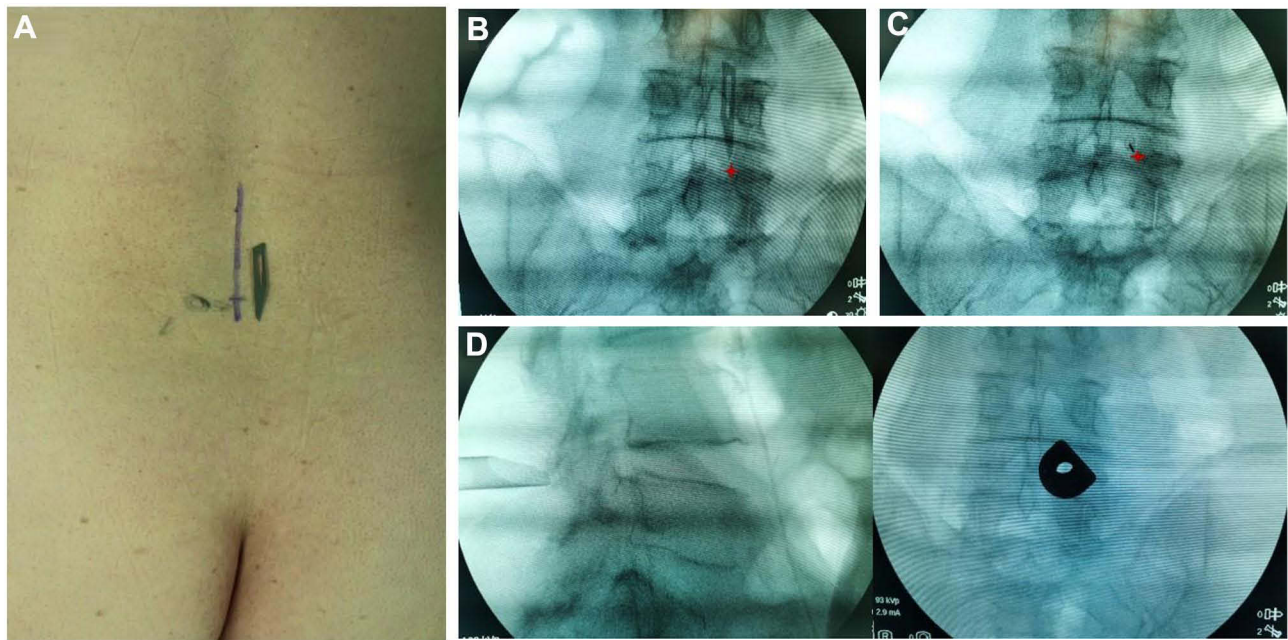


**Figure 2** Intraoperative nerve monitoring. (A and B) The stimulation of cauda equina and bilateral L5 nerve roots were recorded by electrode needles that were inserted in anal sphincter and bilateral tibialis anterior and extensor digitorum longus, respectively. The detection mode was to be set to Free-EMG. (C) The normal Free-EMG should be a linear resting waveform. (D) The stimulation of the L5 nerve roots were detected. (E) The electrophysiologist was watching the Free-EMG waveform closely. All persons have provided informed consent for the images to be published. EMG indicates Electromyography.

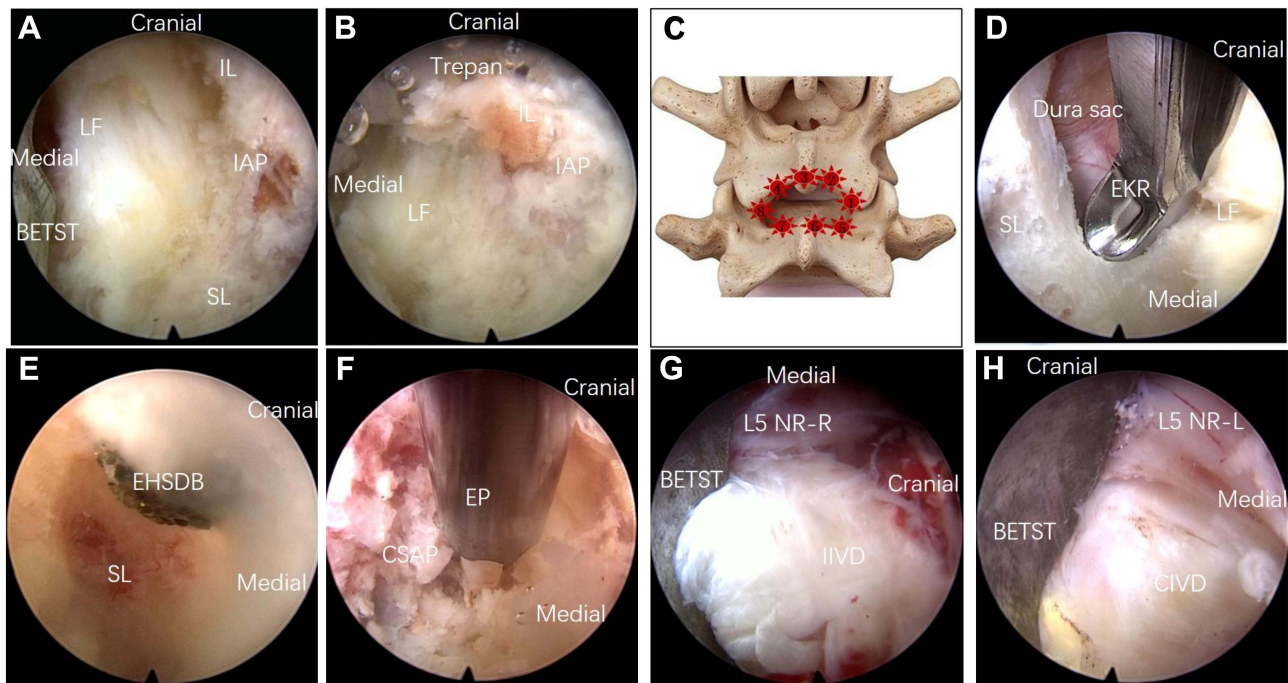
a tapered cannulated obturator was advanced until its tip reached the original point, as observed on the C-arm fluoroscopy posteroanterior view. After blunt dissection of soft tissue attached to the laminae with cannulae Nos. 2 and 3, a U-shaped cannula was introduced through the cannula and docked (Figure 3D).

### Dorsal Decompression of Spinal Canal

A T-shaped cannula and well-connected spinal endoscope were inserted into the U-shaped cannula in sequence. Next, the soft tissue on the surface of the vertebral laminae, inferior articular process, and ligamentum flavum was cleaned with grasp pincers and radiofrequency electrodes under an endoscope to expose the bony anatomical structures (Figure 4A). After the bony anatomical structures were clearly confirmed under endoscope, the T-shaped cannula was withdrawn. Then, to expose the proximal attachment of the ligamentum flavum, the inner margin of the inferior articular process was partly resected using the full-visualized trepan that was out of the endoscope (Figure 4B, Supplementary Figure 1). The bone rotating along with the full-visualized trepan indicated that it had been resected successfully. Next, the second, third, fourth, fifth, sixth, seventh, and eighth trephine were performed along the inferior margin of the cranial lamina and the superior margin of the caudal lamina in turn (Figure 4C), and the extent of decompression depends on the degree of LSS. In addition, an endoscopic Kerrison rongeur was used to remove bone that could not be removed using the full-visualized trepan or to trim



**Figure 3** Location of skin entry point and placement of U-shaped cannula. (A–C) The entry point was marked and puncture was performed with C-arm fluoroscopy assistance. (D) The final position of U-shaped cannula was determined on posteroanterior and lateral view of C-arm fluoroscopy.



**Figure 4** Key steps of decompression and discectomy process. (A) The structures of original point. (B) Laminoplasty with the full-visualized trepan. (C) Laminoplasty in this order. The contralateral decompression with an endoscopic (D) Kerrison rongeur or (E) high-speed diamond bur or (F) piezosurgery. Exposure of (G) ipsilateral and (H) contralateral herniated disc.

**Abbreviations:** IL, inferior lamina (of the upper lumbar spine); SL, superior lamina (of the lower lumbar spine); LF, ligamentum flavum; IAP, inferior articular process; SAP, superior articular process; BETST, bevel-end of T-shaped tube; EKR, endoscopic Kerrison rongeur; EHSDB, endoscopic high-speed diamond bur; CSAP, contralateral superior articular process; IIVD, ipsilateral intervertebral disc; CIVD, contralateral intervertebral disc.

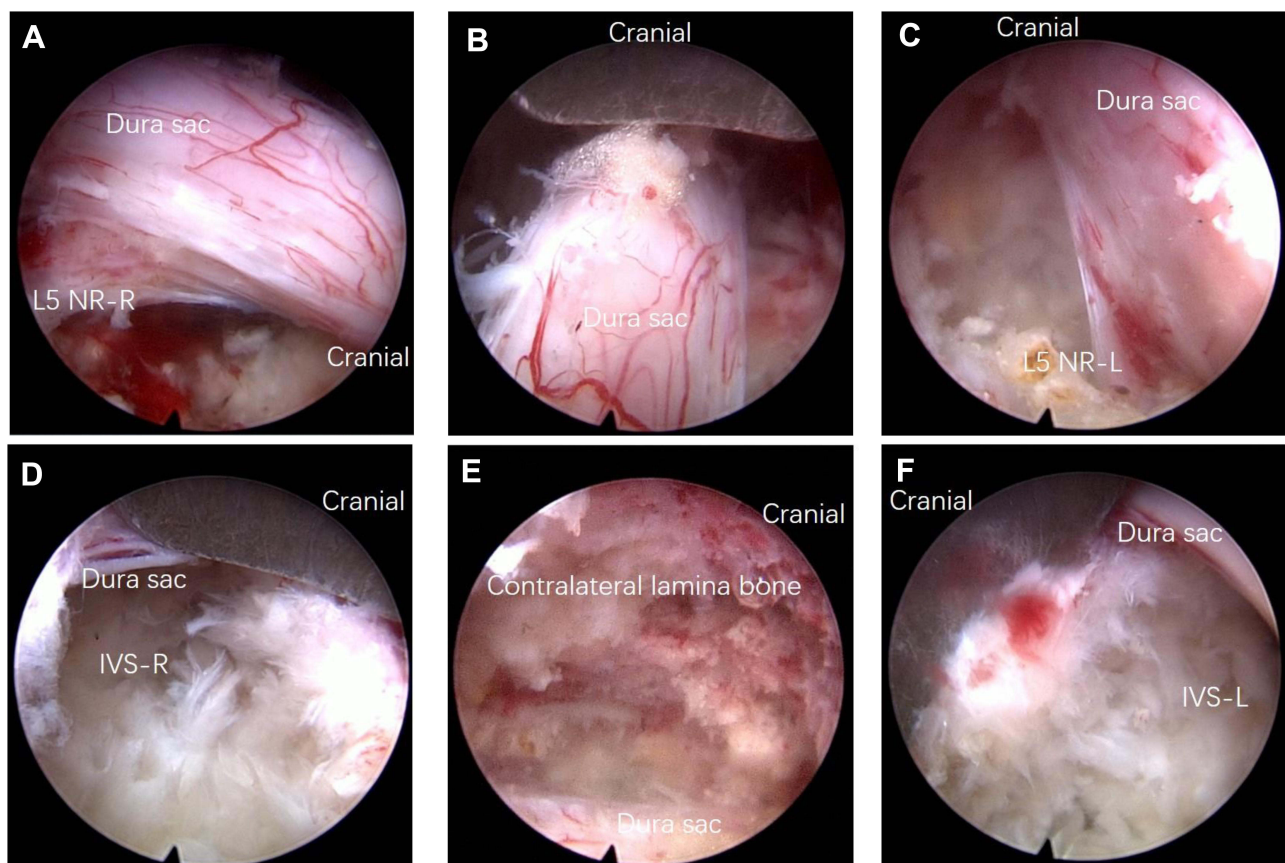
the smaller parts of the peripheral bone (Figure 4D). To decompress the lateral recess, an endoscopic high-speed diamond bur (Figure 4E) or endoscopic piezosurgery (Figure 4F) could also be used to remove residual bone or the medial facet joint and the superior articular process, which was especially suitable for the contralateral side. Attachment points of the ligamentum flavum on both the cranial and caudal laminae were completely exposed. Next, the proliferative ligamentum flavum was resected to decompress the dural sac and the bilateral nerve roots dorsally.

### Ventral Decompression Through Bilateral Discectomy

On the ipsilateral side, the T-shaped cannula was advanced through the shoulder of the traversing nerve root, into the epidural space lateral to the traversing nerve root, with the rotating and retracting U-shaped cannula and T-shaped cannula. The traversing nerve root was protected and gently retracted medially while rotating and retracting the T-shaped cannula. The main part of the herniated disc was identified (Figure 4G) and resected meticulously. In addition, to prevent recurrence, degenerative and loose nucleus pulposus of the intervertebral space was removed. Next, the U-shaped cannula and T-shaped cannula were withdrawn dorsally and rotated over the dorsal side of dural sac into the epidural space lateral to the contralateral traversing nerve root. Furthermore, the contralateral traversing nerve root was carefully moved medially and protected by rotating the T-shaped cannula (Figure 3H) to thoroughly remove the residual herniated disc.

### Confirmation of 360° Decompression and End of the Operation

After we confirmed 360° decompression of both the dural sac and nerve roots (Figure 5A–F), further epidural hemostasis as well as annuloplasty were performed with radiofrequency electrodes. The working cannula and the endoscope were withdrawn without placing a drainage tube. Lastly, the incision was sutured.



**Figure 5** 360° decompression of dural sac and nerve roots. (A) Ipsilateral and (C) contralateral decompression of L5 nerve roots and dural sac. (B) Dorsal decompression of dural sac and (E) clear exposure of contralateral lamina bone. Intervertebral space was exposed clearly from (D) ipsilateral and (F) contralateral side after bilateral discectomy.

**Abbreviations:** L5 NR-R, right L5 nerve root; L5 NR-L, left L5 nerve root; IVS-R, right side of intervertebral space; IVS-L, left side of intervertebral space.

## Outcome Assessment

All included patients were assessed before surgery, before discharge, and at 3, 6, and 12 months after surgery. Functional outcomes were evaluated using the Oswestry Disability Index (ODI).<sup>9</sup> A visual analog scale (VAS) was used for scoring the degree of low-back and lower-limb pain. Clinical effectiveness was assessed with modified MacNab criteria at 12 months after the operation.<sup>10</sup> Before discharge, radiologic outcomes were evaluated using magnetic resonance imaging (MRI) and computed tomography (CT).

## Statistical Analysis

We performed all statistical analyses of clinical data using SPSS (version 24.0; SPSS Inc., Chicago, IL, USA). All data of pre- and postoperative VAS and ODI scores are presented as means  $\pm$  standard deviations and were analyzed using the paired *t*-test if the data are normally distributed or were analyzed using Wilcoxon signed-rank test. We set the statistical significance at  $P < 0.05$ .

## Results

### Demographic Characteristics and Patient Outcomes

After the inclusion and exclusion criteria were applied, 39 patients were enrolled in this study. Table 1 presents the patient details.

### Clinical Results

The excellent-good rate of patients assessed with the modified MacNab criteria was 89.7%. 4 patients demonstrated fair results and required pain medication treatment. Table 2 lists the outcome details. An improvement was found in both low-back pain and lower-limb pain VAS scores and it was much more significant for the latter. Also, the ODI improved significantly. There was a significant difference between the pre- and postoperative scores of DOI, low back pain VAS, and lower limb pain VAS at different time points (before discharge, 3 months, 6 months, and 12 months after operation;  $P < 0.05$ ). There was difference in before discharge and 3 months after surgery compared with 12 months after surgery ( $P < 0.05$ ). Details are presented in Table 3 and Figure 6A–C.

**Table 1** Demographic Findings of the Study Patients  
(n = 39)

| Characteristic                     | Mean $\pm$ SD or n    |
|------------------------------------|-----------------------|
| Age (yrs)                          | 59.9 $\pm$ 9.4        |
| BMI (kg/m <sup>2</sup> )           | 25.3 $\pm$ 4.5        |
| Sex, male: female                  | 18:21                 |
| Side of the surgery, left: right   | 17:22                 |
| Levels involved, L3-4: L4-5: L5-S1 | 5:22:12               |
| Low back pain                      | 34                    |
| Neurogenic claudication            | 36                    |
| Lower limb pain                    | 31 (Left); 35 (Right) |
| Lasegue's test (+)                 | 19 (Left); 17 (Right) |
| Paresthesia in lower limb          | 22 (Left); 19 (Right) |
| Lower limb weakness                | 5 (Left); 7 (Right)   |
| Duration of surgery (min)          | 82.1 $\pm$ 12.3       |
| Blood loss (mL)                    | 14.5 $\pm$ 5.9        |
| Time in bed (h)                    | 20.9 $\pm$ 6.1        |
| Hospitalization time (day)         | 3.7 $\pm$ 1.1         |
| Follow-up period (mo)              | 14.1 $\pm$ 2.6        |

**Abbreviations:** BMI, body mass index; SD, standard deviation; n, number of patients.

**Table 2** Modified MacNab Outcomes of 12 Months After Operation (n=39)

| Outcomes  | Description  | n (%)     |
|-----------|--|-----------|
| Excellent | Complete relief of symptoms                                    | 21 (53.8) |
| Good      | Marked improvement but occasional pain                         | 14 (35.9) |
| Fair      | Improved functional capacity and the need for pain medications | 4 (10.3)  |
| Poor      | Unimproved symptoms or worsening                               | 0 (0)     |

**Abbreviation:** n, number of patients.

**Table 3** Mean Change of Outcome Measurement (Mean  $\pm$  SD)

| Outcome Measurement | Pre-op         | Before Discharge | 3 mo Post-Op     | 6 mo Post-Op    | 12 mo Post-Op   |
|---------------------|----------------|------------------|------------------|-----------------|-----------------|
| Low back pain VAS   | 5.9 $\pm$ 0.6  | 2.6 $\pm$ 1.0*§  | 2.1 $\pm$ 0.5*§  | 1.9 $\pm$ 0.8*  | 2.0 $\pm$ 0.6*  |
| Lower limb pain VAS | 7.2 $\pm$ 0.9  | 2.3 $\pm$ 0.5*§  | 1.8 $\pm$ 0.8*§  | 1.6 $\pm$ 0.5*  | 1.6 $\pm$ 0.7*  |
| ODI                 | 56.0 $\pm$ 4.2 | 27.6 $\pm$ 5.7*§ | 22.6 $\pm$ 3.5*§ | 16.3 $\pm$ 4.3* | 16.7 $\pm$ 4.8* |

**Notes:** \*P<0.05 versus preoperative data. § P< 0.05 versus the 12 months after operation.

**Abbreviations:** VAS, visual analogue scale; SD, standard deviation; ODI, Oswestry Disability Index; mo, month; op, operation.

## Complications

4 patients (10.3%) experienced complications. 1 presented with worse lower-back pain than before surgery and could not perform heavy housework. Postoperative CT showed excessive removal of the inferior articular process, which might have caused iatrogenic lumbar instability of L4-5 (Figure 7A–D). 3 patients experienced transient postoperative dysesthesia, which was relieved at 3-month follow-up with physical and neurotrophic drug treatment. No severe complications occurred, such as cauda equina injury, nerve injury, dural tear or cerebrospinal fluid leakage.

## Representative Cases

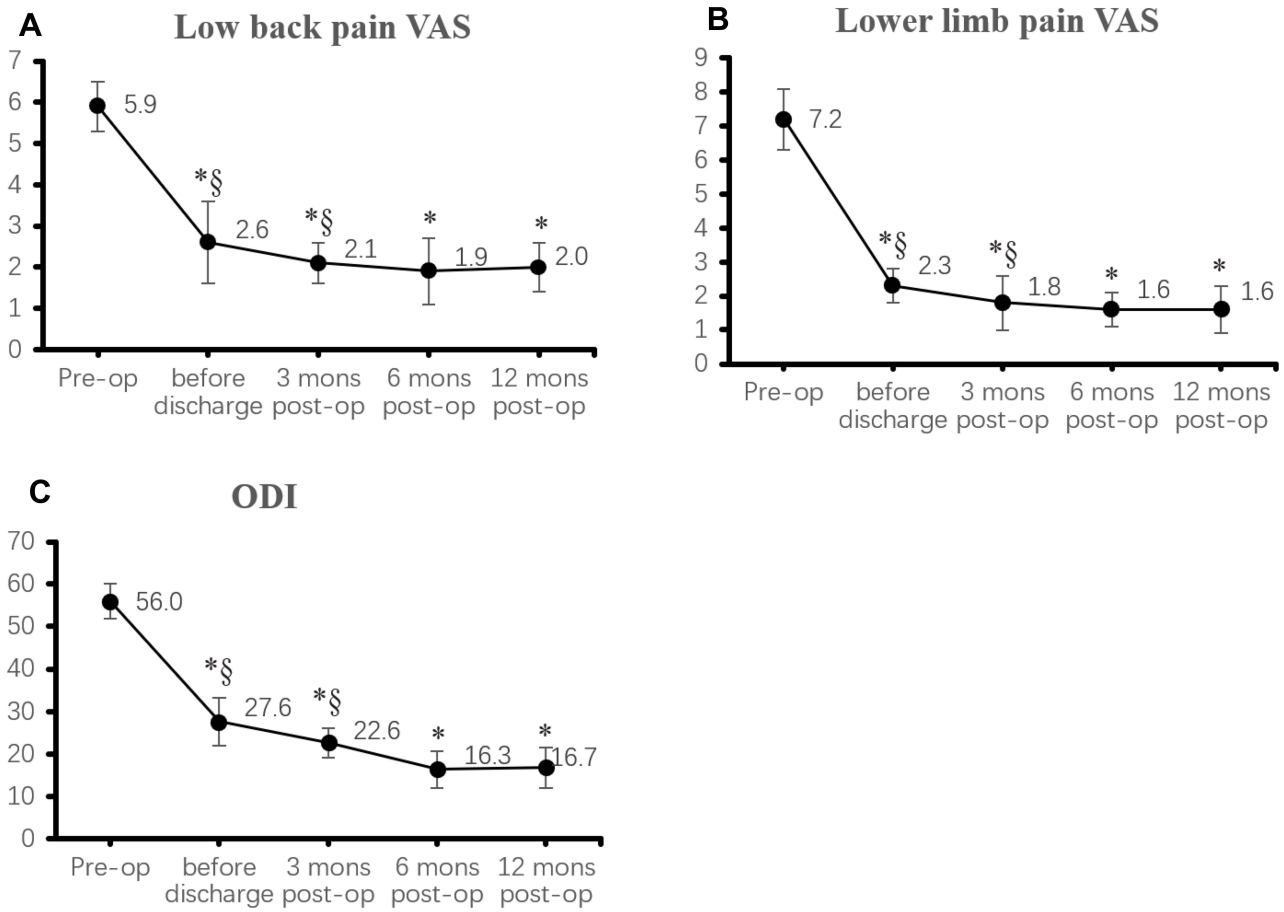
A representative case was presented in Figure 8.

## Discussion

Recent development in endoscopic techniques broadened the indications for endoscopic spinal surgery, from percutaneous endoscopic lumbar discectomy to percutaneous endoscopic lumbar spinal canal decompression and percutaneous endoscopic lumbar interbody fusion.<sup>4,5,11–14</sup> Surgeons and patients widely accepted endoscopic spine surgery due to its advantages of less invasive, less bleeding, rapid recovery, short hospitalization time, and low cost compared with the conventional open approach for posterior lumbar interbody fusion. Therefore, endoscopic spinal surgery has become an important approach for treating LDH and LSS. However, endoscopically managing the pathological type of CLSS combined with DH is difficult.

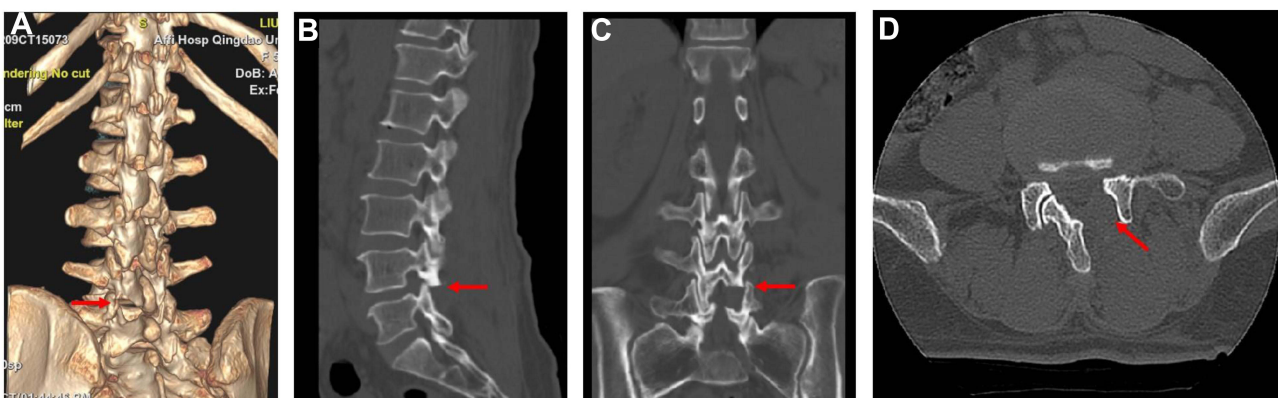
To our knowledge, our study is the first to report a 360° decompression technique for CLSS combined with DH, which differs from the 360° decompression technique for thoracic spinal stenosis reported by Shen.<sup>15</sup> Encouragingly, the clinical outcomes of 1-year follow-up were satisfactory and demonstrated that Endo-ULBDD is a feasible, safe, efficient, and minimally invasive approach for treating CLSS combined with DH.

To date, only a few studies reported techniques for managing LSS combined with DH. Xiong et al reported 270° spinal canal decompression using the TESSYS-ISEE technique, and Wu et al reported a U-route transforaminal percutaneous endoscopic lumbar discectomy to treat LSS combined with DH.<sup>17,18</sup> In addition, hybrid interlaminar endoscopic lumbar decompression was reported to treat patients with unilateral radiculopathy diagnosed with LSS combined with DH.<sup>16</sup> Although all of the techniques



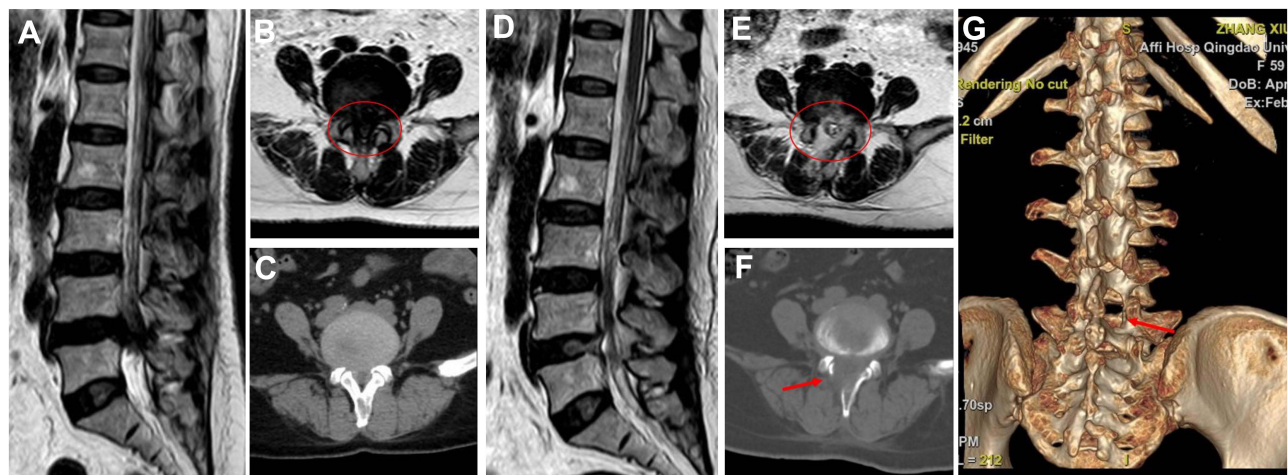
**Figure 6** Comparison of (A) VAS scores of low back pain, (B) VAS scores of lower limb pain and (C) ODI scores at different time points. \*P<0.05 versus Pre-operation group. § P< 0.05 versus the 12 months after operation.

**Abbreviations:** VAS, visual analogue scale; ODI, Oswestry Disability Index; mo, month; op, operation.



**Figure 7 (A–D)** Postoperative CT scans images of one patient. The red arrow indicated that the inferior articular process of L4 vertebra was over resected in (A–D). (A) 3 dimensional reconstruction image; (B) sagittal view; (C) coronal view; (D) Axial view.

**Abbreviation:** CT, computed tomography.



**Figure 8** A 59-year female patient diagnosed with CLSS combined with DH at the L4-5 level underwent an Endo-ULBDD. (A–C) Preoperative MRI and CT. The red circle in (B) indicated severe CLSS. (D–F) Postoperative MRI and CT. The red circle in (E) indicated 360° decompression of spinal canal. (F and G) The red arrow indicated that the inferior articular process of L4 vertebra was partly preserved. (A and D) sagittal view; (B and C), (E and F) axial view; G 3 dimensional reconstruction. **Abbreviations:** MRI, magnetic resonance imaging; CT, computed tomography.

mentioned above were used to treat LSS combined with DH and achieved satisfactory results, they were suitable only for patients with unilateral, not bilateral, lower-limb radiculopathy. However, in our study, all subjects demonstrated CLSS combined with DH, and most presented with a history of neurogenic claudication and bilateral lower-limb radiculopathy. Thus, to achieve satisfactory clinical efficacy, both ventral and dorsal spinal canal decompression should be conducted.

We achieved 360° decompression of the lumbar spinal canal using our Endo-ULBDD technique with the Endo-surgi Plus system under intraoperative cauda equina and nerve root monitoring. First, we resected the ipsilateral cranial and caudal partial lamina, medial facet joint, and outer layer of the ligamentum flavum. The inner layer of the ligamentum flavum was initially left as far as possible to protect the dural sac; then, contralateral bony decompression was performed in the same manner. Second, the inner layer of the ligamentum flavum was resected completely to obtain further dorsal decompression of the dural sac and the nerve roots. The above two steps were identical to those of Endo-ULBD and Endo-ULBDD is based on the Endo-ULBD technique.<sup>6</sup> The space between the dorsal wall of the bony spinal canal and the underlying dural sac was sufficient. Therefore, rotating the T-shaped cannula into the epidural space lateral to the traversing nerve root through the shoulder of the traversing nerve root to resect the herniated disc ventrally was safe. Subsequently, we performed contralateral discectomy more meticulously in the same manner. However, in this procedure, we paid more attention to the dural sac and nerve root and gently retracted the traversing nerve root or dural sac using the bevel end of the T-shaped cannula to protect the neural structures. In addition, the electrophysiologist was reminded to focus on the change in the free electromyography waveform. At times, the stimulation of the nerve could be detected while retracting the traversing nerve root or dural sac using the bevel end of the T-shaped cannula. Throughout the procedure, we maintained a clear visual field in cases of missing orientation and dural tear or nerve injury. The interlaminar technique was based on the principle of the conventional open surgical approach. The learning curve of the interlaminar technique is flatter than that of the transforaminal technique;<sup>19</sup> thus, this technique was also easy to be mastered by surgeons with experience in conventional open surgery. However, when resecting a herniated disc through the shoulder of the traversing nerve root, we must be meticulous.

Xiong et al reported an excellent-good rate of 90.7%, a mean decrease of ODI of 44.8 points, and a mean decrease in the VAS for lower limb and low back of 6.3 and 2.9 points, respectively.<sup>17</sup> Wu et al reported an excellent-good rate ranging from 88.75–93.42% in the first 2 postoperative years.<sup>18</sup> In our study, the excellent-good rate of the modified MacNab criteria was 89.7%. In addition, the average decrease in VAS score for lower limb and low back was 5.6 and 3.9 points, respectively, and the average decrease in ODI score was 39.3 points. Although our short-term clinical outcomes

were satisfactory and comparable with those of other studies, long-term clinical outcomes must be observed in the future.<sup>17,18</sup>

Satisfactory clinical outcomes are largely attributed to the design of the Endo-surgi Plus system. First, the working cannula includes an outer and an inner cannula. The outer cannula is a U-shaped cannula with a length of 151mm and an inner diameter of 9mm, and the inner cannula is a T-shaped cannula with a length of 168mm and an inner diameter of 7.6mm. Because of the larger inner diameter, the U-shaped cannula can match a 7.5-mm inner diameter full-visualized trepan, which is larger than the 6.5-mm inner diameter trepan of the TESSYS ISEE system. In addition, the U-shaped cannula can match a larger outer diameter Kerrison rongeur. Therefore, the efficiency of laminoplasty was greatly improved. Second, the U-shaped cannula was 17 mm shorter than the T-shaped cannula. When dealing with intervertebral space, the U-shaped cannula and the T-shaped cannula can be used together, or the T-shaped cannula can be used alone. Third, the Endo-surgi Plus system with a 4.7-mm inner diameter endoscope obtained a larger visual field than the TESSYS ISEE system with a 3.7-mm inner diameter endoscope. Collectively, the Endo-surgi Plus system not only achieves high efficiency of spinal canal decompression but also guarantees the safety of the dural sac and nerve roots.

3 patients in this study experienced postoperative dysesthesia, which is a common complication, but this was relieved at 3-month follow-up with physical and neurotrophic drug treatment.<sup>17,20,21</sup> A possible reason could be that the dural sac or nerve root was compressed or irritated by instruments during the operation, especially in the process of contralateral lateral recess decompression and discectomy via the shoulder of the nerve root.<sup>17</sup> In addition, 1 patient complained that her low-back pain worsened after surgery, especially when she got out of bed or twisted her body. We reviewed her postoperative CT scans and found that the left inferior articular process was over resected. Unfortunately, we could not obtain her dynamic lumbar radiography. A finite element model study revealed that spinal mobility, facet loading, and intradiscal pressure increased with > 30% facetectomy.<sup>22</sup> We speculated that destruction of the facet joint might have resulted in spinal instability and led to iatrogenic low-back pain. To reduce symptoms of low-back pain caused by iatrogenic lumbar instability, preservation of the facet joints or precise and limited intraoperative facetectomy would be helpful.<sup>23</sup> The limitations of the study are obvious. Our sample size was small, and potential risks and complications of this technique exist. This was an observational study with preliminary results, and future prospective randomized controlled studies with larger sample sizes should be conducted in order to obtain more convincing conclusions.

## Conclusion

Endo-ULBDD is a safe, feasible, efficient, and minimally invasive approach for treating CLSS combined with DH. And it further expands the surgical indications for the Single-channel spine endoscopy.

## Data Sharing Statement

The datasets generated and/or analyzed during the current study are not publicly available (due to the data is confidential patient data) but are available from the first author or corresponding author on reasonable request.

## Ethics Approval and Patient Consent

All procedures were approved by the ethics committee of the Affiliated Hospital of Qingdao University and approved number of IRB was QYFYWZLL26999. Written informed consent was received from all patients and/or their legal guardian(s) before the operation. All persons in [Figure 2](#) have provided informed consent for the images to be published.

## Acknowledgment

Thanks to all staffs of the Department of Spinal Surgery of the Affiliated Hospital of Qingdao University for their support for the study. Thanks to enago for providing English language touch-ups. Shengwei Meng and Derong Xu are co-first authors for this study.

## Author Contributions

All authors made substantial contributions to the work; agreed on the journal to which the article will be submitted; reviewed and agreed on all versions of the article before submission, during revision, the final version accepted for publication, and any significant changes introduced at the proofing stage and accounted for the contents of the article.

## Funding

This work was supported by the funds from the National Key Research and Development Program of China (2019YFC0121400), the National Natural Science Foundation of China (81871804), and the Natural Science Foundation of Shan Dong Province (ZR2021MH020).

## Disclosure

The authors declare that they have no conflict of interest.

## References

1. Porter RW. Spinal stenosis and neurogenic claudication. *Spine*. 1996;21(17):2046–2052. doi:10.1097/00007632-199609010-00024
2. Postacchini F. Lumbar spinal stenosis and pseudostenosis. Definition and classification of pathology. *Ital J Orthop Traumatol*. 1983;9(3):339–350.
3. Amin RM, Andrade NS, Neuman BJ. Lumbar disc herniation. *Curr Rev Musculoskelet Med*. 2017;10(4):507–516. doi:10.1007/s12178-017-9441-4
4. Pan M, Li Q, Li S, et al. Percutaneous endoscopic lumbar discectomy: indications and complications. *Pain Physician*. 2020;23(1):49–56.
5. Kim HS, Wu PH, Jang IT. Lumbar endoscopic unilateral laminotomy for bilateral decompression outside-in approach: a proctorship guideline with 12 steps of effectiveness and safety. *Neurospine*. 2020;17(Suppl1):S99–S109. doi:10.14245/ns.2040078.039
6. Komp M, Hahn P, Merk H, Godolias G, Ruetten S. Bilateral operation of lumbar degenerative central spinal stenosis in full-endoscopic interlaminar technique with unilateral approach: prospective 2-year results of 74 patients. *J Spinal Disord Tech*. 2011;24(5):281–287. doi:10.1097/BSD.0b013e3181f9f55e
7. Sapkas G, Mavrogenis AF, Starantzis KA, Soultanis K, Kokkalis ZT, Papagelopoulos PJ. Outcome of a dynamic neutralization system for the spine. *Orthopedics*. 2012;35(10):e1497–502. doi:10.3928/01477447-20120919-19
8. Wiltse LL, Newman PH, Macnab I. Classification of spondylolysis and spondylolisthesis. *Clin Orthop Relat Res*. 1976;117:23–29.
9. Fairbank JC, Pynsent PB. The Oswestry disability index. *Spine*. 2000;25(22):2940–2952. doi:10.1097/00007632-200011150-00017
10. Macnab I. Negative disc exploration. An analysis of the causes of nerve-root involvement in sixty-eight patients. *J Bone Joint Surg Am*. 1971;53(5):891–903. doi:10.2106/00004623-197153050-00004
11. Zhao XB, Ma HJ, Geng B, Zhou HG, Xia YY. Percutaneous endoscopic unilateral laminotomy and bilateral decompression for lumbar spinal stenosis. *Orthop Surg*. 2021;13(2):641–650. doi:10.1111/os.12925
12. Osman SG. Endoscopic transforaminal decompression, interbody fusion, and percutaneous pedicle screw implantation of the lumbar spine: a case series report. *Int J Spine Surg*. 2012;6:157–166. doi:10.1016/j.ijssp.2012.04.001
13. Zhang H, Zhou C, Wang C, et al. Percutaneous endoscopic transforaminal lumbar interbody fusion: technique note and comparison of early outcomes with minimally invasive transforaminal lumbar interbody fusion for lumbar spondylolisthesis. *Int J Gen Med*. 2021;14:549–558. doi:10.2147/IJGM.S298591
14. Xu D, Han S, Wang C, Zhu K, Zhou C, Ma X. The technical feasibility and preliminary results of minimally invasive endoscopic-TLIF based on electromagnetic navigation: a case series. *BMC Surg*. 2021;21(1):149. doi:10.1186/s12893-021-01148-9
15. Shen J, Telfeian AE. Fully endoscopic 360° decompression surgery for thoracic spinal stenosis: technical note and report of 8 cases. *Pain Physician*. 2020;23(6):E659–E663.
16. Chen KT, Choi KC, Song MS, Jabri H, Lokanath YK, Kim JS. Hybrid interlaminar endoscopic lumbar decompression in disc herniation combined with spinal stenosis. *Oper Neurosurg*. 2021;20(3):E168–E174. doi:10.1093/ons/opa360
17. Xiong C, Li T, Kang H, Hu H, Han J, Xu F. Early outcomes of 270-degree spinal canal decompression by using TESSYS-ISEE technique in patients with lumbar spinal stenosis combined with disc herniation. *Eur Spine J*. 2019;28(1):78–86. doi:10.1007/s00586-018-5655-4
18. Wu B, Tian X, Shi C, et al. Clinical outcomes of “U” route transforaminal percutaneous endoscopic lumbar discectomy in chronic pain patients with lumbar spinal stenosis combined with disc herniation. *Pain Res Manag*. 2021;2021:6657463. doi:10.1155/2021/6657463
19. Wagner R, Haefner M. Indications and contraindications of full-endoscopic interlaminar lumbar decompression. *World Neurosurg*. 2021;145:657–662. doi:10.1016/j.wneu.2020.08.042
20. Zhou C, Zhang G, Panchal RR, et al. Unique complications of percutaneous endoscopic lumbar discectomy and percutaneous endoscopic interlaminar discectomy. *Pain Physician*. 2018;21(2):E105–E112.
21. Wu K, Zhao Y, Feng Z, Hu X, Chen Z, Wang Y. Stepwise local anesthesia for percutaneous endoscopic interlaminar discectomy: technique strategy and clinical outcomes. *World Neurosurg*. 2020;134:e346–e352. doi:10.1016/j.wneu.2019.10.061
22. Ahuja S, Moideen AN, Dudhniwala AG, Karatsis E, Papadakis L, Varitis E. Lumbar stability following graded unilateral and bilateral facetectomy: a finite element model study. *Clin Biomech*. 2020;75:105011. doi:10.1016/j.clinbiomech.2020.105011
23. Zander T, Rohlmann A, Klöckner C, Bergmann G. Influence of graded facetectomy and laminectomy on spinal biomechanics. *Eur Spine J*. 2003;12(4):427–434. doi:10.1007/s00586-003-0540-0

Journal of Pain Research

Dovepress

### Publish your work in this journal

The Journal of Pain Research is an international, peer reviewed, open access, online journal that welcomes laboratory and clinical findings in the fields of pain research and the prevention and management of pain. Original research, reviews, symposium reports, hypothesis formation and commentaries are all considered for publication. The manuscript management system is completely online and includes a very quick and fair peer-review system, which is all easy to use. Visit <http://www.dovepress.com/testimonials.php> to read real quotes from published authors.

Submit your manuscript here: <https://www.dovepress.com/journal-of-pain-research-journal>