

Mycobacterium chelonae Infection After a Cat Bite: A Rare Case Report

Lei Zhang¹, Yixiong Li², Hao Yang¹, Yunzhu Mu¹, Jingjing Jiang¹, Xi Duan¹

¹Department of Dermatology, Affiliated Hospital of North Sichuan Medical College, Nanchong, Sichuan Province, People's Republic of China;

²Department of Anorectal, The First Affiliated Hospital of Chengdu Medical College, Chengdu, People's Republic of China

Correspondence: Xi Duan, Department of Dermatology, Affiliated Hospital of North Sichuan Medical College, 1 Maoyuan South Road, Shunqing District, Nanchong City, Sichuan Province, 637000, People's Republic of China, Tel +8618783983097, Email dancing@126.com

Abstract: We describe a 62-year-old woman with a 1-month-old unhealed cat bite wound caused by *Mycobacterium chelonae* presenting with persistent infection despite treatment with cefazolin and amoxicillin. This is the first reported case of *M. chelonae* infection caused by a cat bite. Cat bites are affected by the cat's food microbiome, so clinicians should consider the cat's diet if wounds are not responding as expected to first-line therapy.

Keywords: cat bite, *Mycobacterium chelonae*, wound infection

Introduction

Animal bites are a global health problem. They account for 5% of the total trauma seen in the emergency department.^{1,2} Most of the animal bites are caused by dogs (80–90%) and cats (5–15%).³ Cats' narrow sharp teeth inflict deeper puncture wounds than dogs do and carry a higher risk of infection. The infection rate for cat bites in the United States can be as much as 50%.^{3–5} The microbiology of cat bite wound infections shows a variety of microorganisms, including aerobic (eg, *Pasteurella*, *Streptococcus*, and *Staphylococcus*) and anaerobic (eg, *Fusobacterium*, *Porphyromonas*, and *Bacteroides*), which often reflect the oral flora of cats and may be affected by their food intake.^{4,6,7} In recent years, the practice of feeding raw meat to pets has increased significantly, which may change the nature of infected organisms.^{8,9} *M. chelonae* is classified as a rapidly growing non-tuberculous mycobacteria (NTM). It is ubiquitous in the environment and has been found in soil, water, and aquatic animals. *M. chelonae* prevalence has been reported as 0.2 cases per 100,000 persons, and it has been reported more frequently in invasive procedures or catheter-related infections.^{10,11} It is one of the most common pathogens of fish mycobacteriosis.^{12,13} The authors here report the first case of wound nonunion caused by *M. chelonae* infection after a bite by a cat with a long history of raw fish ingestion.

Case Presentation

A 62-year-old woman was admitted with a 1-month-old non-healing wound on the right leg and persistent erythematous nodules around the wound. One month prior to admission, she was bitten by a cat on her right leg. The patient immediately disinfected the wound with iodophor (0.5%) after being bitten but did not take other measures for dealing with the wound. Subsequently, skin redness, swelling, nodules and pain gradually appeared around the bite. She received a 7-day treatment regimen of cefazolin (1 g b.i.d. intravenous infusion) and amoxicillin (0.5 g t.i.d. oral) in another hospital, but it did not work. Three days prior to admission, the patient complained that after walking for a long time, the redness and swelling increased and the bite wound had a purulent secretion. Pressing around the wound caused her obvious pain. During the development of the disease, she complained of pain around the bite but did not have fever, nausea, vomiting, headache, abdominal pain or arthralgia. On admission, we performed a physical examination of the patient. The superficial lymph nodes of the whole body were not palpable. Edematous erythema of about 7 cm × 10 cm was seen on the inside of the right calf (Figure 1A), and two puncture wounds caused by two teeth of the cat could be

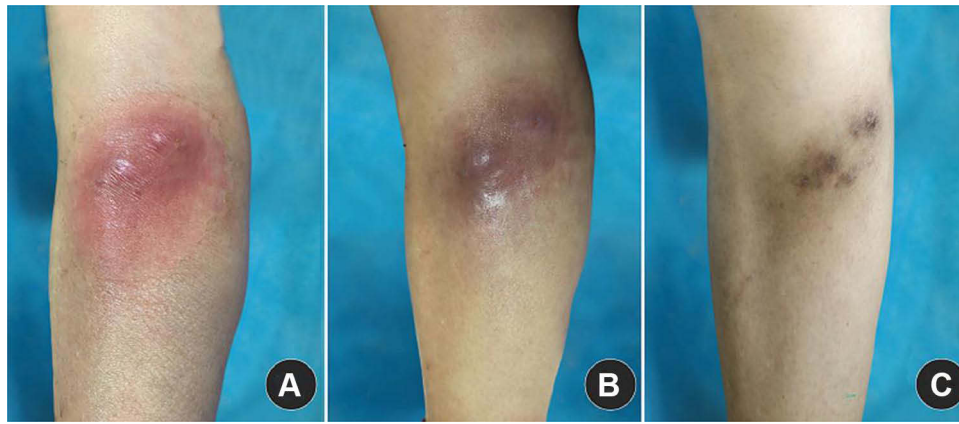


Figure 1 Clinical presentation of the patient. (A) Skin lesions on admission and at approximately (B) 3 months and (C) 6 months after treatment of the bacterial infection.

seen in the centre of the erythema. Local skin temperature was high, induration could be felt, and tenderness was obvious. Pus secretion could be seen at the bite wound after pressing the local area. Combined with the patient's medical history, we made a presumptive diagnosis of bacterial infection. After admission, a routine intravenous infusion of amoxicillin-clavulanate potassium (1.2 g, q 8 hr) for 5 days was selected to treat her lesions, but it was ineffective.

On admission, laboratory testing showed completely normal humoral and cellular immune function. The blood test revealed that white blood cells $10.63 \times 10^9/L$ (reference range 3.5 to $9.5 \times 10^9/L$), serum biochemistry and C-reactive protein were normal. On admission, we performed a skin biopsy of the erythematous area of the patient. Histopathological examination of erythema showed that the epidermis was generally normal, with neutrophils, histiocytes, lymphocytes and giant cells in the middle and deep dermis (Figure 2). After proper disinfection, pus was collected by pressing the wound and sent for culture. However, 2 days later, the laboratory reported that the bacterial culture was negative. We recommended that the laboratory extend the incubation time for identification of potential fastidious and/or slowly growing microorganisms. In order to eliminate colonized bacteria on the skin surface and environmental pollutants, we obtained the pus directly from the wound and sent it for culture for fungi and bacteria. The pus was cultured on a blood agar plate and placed in a carbon dioxide (5%) incubator for culture. The culture temperature was controlled at 35°C . After 4 days, these bacterial cultures were positive (Figure 3; white colonies on culture medium shown in panel a; positive acid-fast staining is shown in panel b). Matrix-assisted laser desorption/ionization (MALDI) identified *M. chelonae* with a confidence of 99.9%. At the same time, fungal cultures were negative. Partial sequences of the 16S-23S rRNA internal transcribed spacer (ITS) region and hsp65 geneTb11 were amplified from the strain,¹⁴ and amplicons were sequenced. Further molecular identification confirmed *M. chelonae* as the cause of the cat wound infection. The patient started taking levofloxacin 500 mg q.d. and clarithromycin 500 mg b.i.d. orally, based on

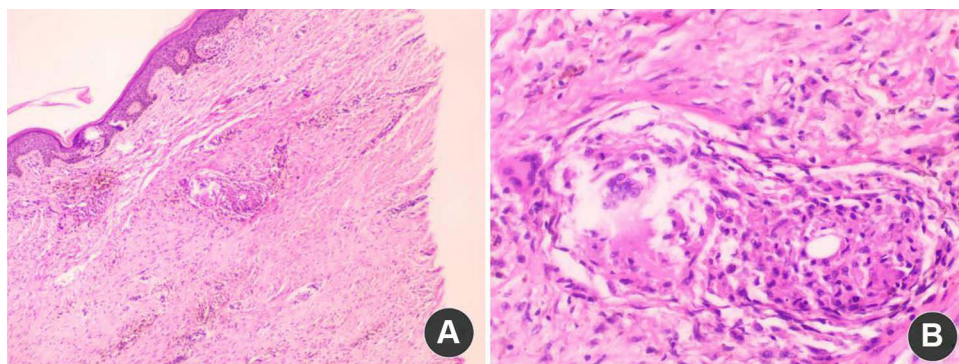


Figure 2 Histopathology of erythema. Photomicrograph showing the epidermis was generally normal, and neutrophils, histiocytes, lymphocytes and giant cells appeared in the middle and deep dermis. (A) hematoxylin-eosin $\times 40$, (B) hematoxylin-eosin $\times 100$.

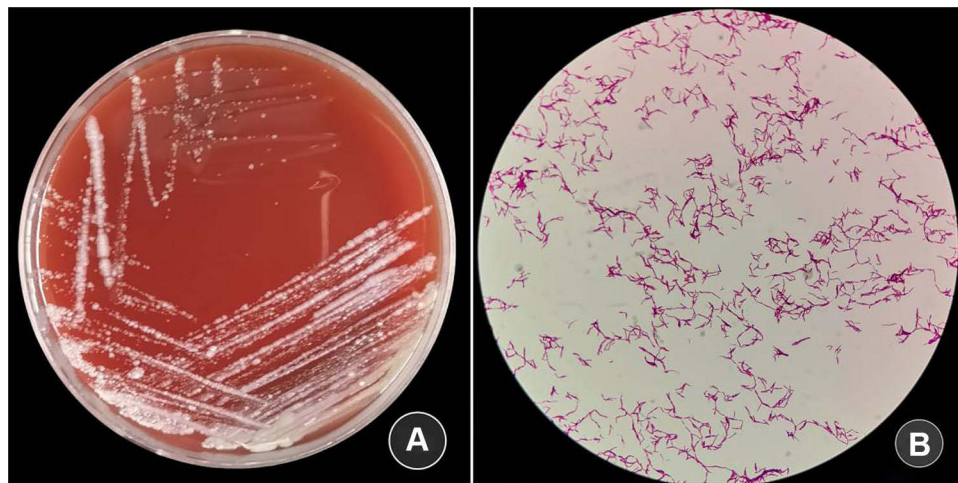


Figure 3 White colonies on culture medium are shown in (A) (blood agar plate), and positive acid-fast staining is shown in (B) (acid-fast stain, $\times 100$ magnification).

susceptibility results. The redness and swelling subsided after 3 months of treatment (Figure 1B). After 6 months' treatment, the wound healed and brown pigmentation was left locally (Figure 1C). During follow-up visits for the next 6 months, the patient remained stable.

Discussion

At present, cat bite infection caused by *M. chelonae* has not been previously reported, and we are reporting the first case. Actually, most cat bites have a complex mixture of microbes. Microorganisms recovered from infected cat bite wounds are most often from the skin of the patient and the mouth of the cat and may also be influenced by the microbiome of cats' ingested prey and other foods. *Pasteurella multocida* is the most common microorganism in infected wounds from cat bites, while *Streptococcus*, *Staphylococcus*, *Fusobacterium*, *Porphyromonas* and *Bacteroides* are also relatively common.^{6,15} However, such infections are often acute or subacute, and amoxicillin-clavulanate potassium is the first-choice drug. They are incompatible with the patient's chronic course and the ineffective treatment with amoxicillin-clavulanate potassium.⁵

Considering whether the infection of cat bite wound was related to the bacteria of cat food and the impact of the surrounding environment and whether there was any possibility of special infection, we investigated the cat's living environment. Interestingly, we found out that the cat lived in an aquatic product store where his owner is the manager and the patient is their neighbor. The owner often fed the cat the sick or dead aquatic animals in the store. We seriously suspect that the pathogen in the cat and patient came from aquatic products. NTM are known to infect a number of aquatic animals including fish and amphibians and cause one of the most common chronic diseases of aquatic animals.^{12,16} Based on the above research, we further extended the culture time and successfully obtained *M. chelonae*. Unfortunately, the cat was subsequently lost, so we could not test for *M. chelonae* directly from the cat's mouth. There has been a notable increase in the practice of feeding pets raw meat in recent years. These diets may be contaminated with bacteria and parasites, which may make such bite contaminations more likely or change the nature of infecting organisms.^{8,9} Clinicians should be aware of considering the animal's diet if bite wounds are not responding as expected to first-line therapy.

M. chelonae was first isolated from a sea turtle by Friedmann in 1903.¹⁰ It is ubiquitous in the environment and has been found in soil, water, and aquatic animals. *M. chelonae* can infect humans, cats, fish, etc, and is a confirmed zoonotic disease.¹⁷ It is one of the most common pathogens of fish mycobacteriosis.^{12,13} The bacterium is classified as a rapidly growing NTM; it will form smooth, moist and non-chromogenic white colonies within 7 days.^{10,18,19} The laboratory report of this patient was negative 2 days after the first pus bacterial culture. When we continued to culture the specimen, we got a positive result on the 4th day. When *Mycobacterium* infection is considered clinically, in order to eliminate the possibility of contamination, it is necessary to send several samples for multiple examinations. Some mycobacteria, including *M. chelonae*, grow well at 30°C, and the positive

rate can be increased by culturing at different temperatures (28–30°C, 35–37°C).²⁰ For slow-growing mycobacteria, such as *M. avium* or *M. bovis*, it is beneficial to extend the culture time.

M. chelonae has been identified as causing an increasing number of skin and soft tissue infections.²¹ Local infection is common after trauma and iatrogenic operation, and severe and extensive infection is more common in patients with immune deficiency.¹⁸ The authors report here the first case of *M. chelonae* infection caused by a cat bite. Once diagnosed, adequate antibiotic treatment is needed. *M. chelonae* can have an unpredictable resistance pattern, and sensitivity testing is recommended. Current studies have shown that most *M. chelonae* are sensitive to macrolides and aminoglycosides. Drug resistance may occur in long-term treatment, and a combination of drugs is often recommended.^{11,18} According to the results of drug sensitivity testing, the patient was treated with levofloxacin 500 mg q.i.d. combined with clarithromycin 500 mg b.i.d. for 6 months and recovered well.

Conclusion

This is the first reported case of *M. chelonae* infection caused by a cat bite. If a cat bite wound infection does not respond to conventional treatment, a specific infection may be present. Further investigation of prey ingested by cats and the cat's living environment is required. Skin infections caused by *M. chelonae* are increasing but may not be fully recognized by clinicians. Once suspected, a detailed patient history, histopathology of the lesions and microbial cultures are necessary.

Ethics Statement

The patient in this manuscript provided written informed consent to the publication of the case details. Institutional approval was not required to publish the case details.

Acknowledgments

We thank the patient and physicians for participating in our study. We thank Ya Gou for improving the language.

Funding

There is no funding to report.

Disclosure

The authors report no conflicts of interest in this work.

References

1. Parda-Peláez B, Sarmiento-García A. Microbiología de las infecciones causadas por mordeduras de perros y gatos en personas: Una revisión. [Microbiology of infections caused by dog and cat bites: a review]. *Revista Chilena de Infectología*. 2021;38(3):393–400. Spanish. doi:10.4067/S0716-10182021000300393
2. Jandl M, Oberleitner G, Endler G, et al. Management of bite wounds in children and adults – an analysis of over 5000 cases at a level I trauma centre. *Wien Klin Wochenschr*. 2016;128(9–10):367–375. doi:10.1007/s00508-015-0900-x
3. Szczypa K, Hryniewicz W. Epidemiologia, mikrobiologia i diagnostyka zakażeń po pogryzieniach przez psy i koty. [Epidemiology, microbiology and diagnostics of dog and cat bites related infections]. *Pol Merkur Lekarski*. 2015;39(232):199–204. Polish.
4. Oehler RL, Velez AP, Mizrachi M, et al. Bite-related and septic syndromes caused by cats and dogs. *Lancet Infect Dis*. 2009;9(7):439–447. doi:10.1016/S1473-3099(09)70110-0
5. Bula-Rudas FJ, Olcott JL. Human and animal bites. *Pediatr Rev*. 2018;39(10):490–500. doi:10.1542/pir.2017-0212
6. Goldstein EJC, Abrahamian FM, Schlossberg D. Diseases transmitted by cats. *Microbiol Spectrum*. 2015;3(5). doi:10.1128/microbiolspec.IOL5-0013-2015
7. Talan DA, Citron DM, Abrahamian FM, et al. Bacteriologic analysis of infected dog and cat bites. Emergency Medicine Animal Bite Infection Study Group. *New Engl J Med*. 1999;340(2):85–92. doi:10.1056/NEJM199901143400202
8. van Bree FPJ, Bokken GCAM, Mineur R, et al. Zoonotic bacteria and parasites found in raw meat-based diets for cats and dogs. *Vet Rec*. 2018;182(2):50. doi:10.1136/vr.104535
9. Davies RH, Lawes JR, Wales AD. Raw diets for dogs and cats: a review, with particular reference to microbiological hazards. *J Small Animal Pract*. 2019;60(6):329–339. doi:10.1111/jsap.13000
10. Behra PRK, Das S, Pettersson BMF, et al. Extended insight into the *Mycobacterium chelonae-abscessus* complex through whole genome sequencing of *Mycobacterium salmoniphilum* outbreak and *Mycobacterium salmoniphilum*-like strains. *Sci Rep*. 2019;9(1):4603. doi:10.1038/s41598-019-40922-x

11. Akram SM, Rathish B, Saleh D. *Mycobacterium chelonae* [updated 2021 Sep 20]. In: *StatPearls*. Treasure Island (FL): StatPearls Publishing; 2022. Available from: <https://www.ncbi.nlm.nih.gov/books/NBK430806/>. Accessed September 6, 2022.
12. Decostere A, Hermans K, Haesebrouck F. Piscine mycobacteriosis: a literature review covering the agent and the disease it causes in fish and humans. *Vet Microbiol*. 2004;99(3–4):159–166. doi:10.1016/j.vetmic.2003.07.011
13. Gauthier DT, Rhodes MW. Mycobacteriosis in fishes: a review. *Vet J*. 2009;180(1):33–47. doi:10.1016/j.tvjl.2008.05.012
14. Chimara E, Ferrazoli L, Ueky SY, et al. Reliable identification of mycobacterial species by PCR-restriction enzyme analysis (PRA)-hsp65 in a reference laboratory and elaboration of a sequence based extended algorithm of PRA-hsp65 patterns. *BMC Microbiol*. 2008;8:48. doi:10.1186/1471-2180-8-48
15. Aziz H, Rhee P, Pandit V, Tang A, Gries L, Joseph B. The current concepts in management of animal (dog, cat, snake, scorpion) and human bite wounds. *J Trauma Acute Care Surg*. 2015;78(3):641–648. doi:10.1097/TA.0000000000000531
16. Gcebe N, Michel AL, Hlokwé TM. Non-tuberculous *Mycobacterium* species causing mycobacteriosis in farmed aquatic animals of South Africa. *BMC Microbiol*. 2018;18(1):32. doi:10.1186/s12866-018-1177-9
17. Dibaj RH, Narimani ST, Narimani T. Identification and molecular characterization of mycobacteria isolated from animal sources in a developing country. *Acta Trop*. 2020;204:105297. doi:10.1016/j.actatropica.2019.105297
18. Uslu Ü, Böhm O, Hept F, Sticherling M. Skin and soft tissue infections caused by *Mycobacterium chelonae*: more common than expected? *Acta Derm Venereol*. 2019;99(10):889–893. doi:10.2340/00015555-3230
19. Jones RS, Shier KL, Master RN, Bao JR, Clark RB. Current significance of the *Mycobacterium chelonae-abscessus* group. *Diag Microbiol Infect Dis*. 2019;94(3):248–254. doi:10.1016/j.diagmicrobio.2019.01.021
20. Scott-Lang VE, Sergeant A, Sinclair CG, et al. Cutaneous *Mycobacterium chelonae* infection in Edinburgh and the Lothians, South-East Scotland, UK. *Br J Dermatol*. 2014;171(1):79–89. doi:10.1111/bjd.12901
21. Gonzalez-Santiago TM, Drage LA. Nontuberculous mycobacteria: skin and soft tissue infections. *Dermatol Clin*. 2015;33(3):563–577. doi:10.1016/j.det.2015.03.017

Clinical, Cosmetic and Investigational Dermatology

Dovepress

Publish your work in this journal

Clinical, Cosmetic and Investigational Dermatology is an international, peer-reviewed, open access, online journal that focuses on the latest clinical and experimental research in all aspects of skin disease and cosmetic interventions. This journal is indexed on CAS. The manuscript management system is completely online and includes a very quick and fair peer-review system, which is all easy to use. Visit <http://www.dovepress.com/testimonials.php> to read real quotes from published authors.

Submit your manuscript here: <https://www.dovepress.com/clinical-cosmetic-and-investigational-dermatology-journal>