

Facial Irritant Contact Dermatitis Caused by Pyraclostrobin

Qiuyue Wang^{1,2}, Nana Luo^{1,2}, Min Lei^{1,2}, Lingyuan Zhong^{1,2}, Chunxiao Li^{2,*}, Pingsheng Hao^{2,*}

¹School of Clinical Medicine, Chengdu University of Traditional Chinese Medicine, Chengdu, People's Republic of China; ²Department of Dermatology, Hospital of Chengdu University of Traditional Chinese Medicine, Chengdu, People's Republic of China

*These authors contributed equally to this work

Correspondence: Chunxiao Li; Pingsheng Hao, Department of Dermatology, Hospital of Chengdu University of Traditional Chinese Medicine, No. 39 Shi-er-qiao Road, Chengdu, 610075, Sichuan, People's Republic of China, Tel +86-18981937829; +86-13881965024, Fax +86-028-87732407, Email chunxiaolee@126.com; hpswl@126.com

Abstract: Contact dermatitis and facial contact dermatitis caused by pesticides are not uncommon in China. However, clinically, due to the wide variety of pesticides, they mainly appear in the form of case reports. We reported a 70-year-old male patient developed facial irritant contact dermatitis (ICD) due to pyraclostrobin which was sprayed on his face. Initially, he felt facial burning and tingling, and localized erythematous-edematous and scaly rash appeared on his face as well as front hairline scalp. During the outpatient visit, the main symptoms were a facial burning sensation, itching, and tingling. The patient's facial lesions improved after treatment. To better protect the skin of agricultural workers, preventive measures should be undertaken, such as personal protective equipment, gas masks, protective clothing and goggles, which are indispensable for manual pesticide spraying. Pyraclostrobin diluted according to the instructions is a potential source of ICD. Agricultural workers should undertake preventive measures during manual pesticide spraying. Safety education and publicity are particularly important. We need dermatologists to spread knowledge and agricultural workers to develop the right protective habits.

Keywords: irritant contact dermatitis, pyraclostrobin, pesticide exposure, pesticides, farming, case report

Introduction

Contact dermatitis caused by pesticides has rarely been reported in recent years. The use of pesticides has been dramatically reduced in agricultural production in China. However, we still occasionally encounter patients with irritant contact dermatitis caused by pesticide spraying. Due to improper protection, facial irritant contact dermatitis (ICD) is not unusual.

Case Report

A 70-year-old male patient developed facial ICD due to pyraclostrobin, Haisa[®] (Qingdao, China) (Figure 1A) sprayed on citrus two days before treatment. The patient accidentally sprayed pyraclostrobin solution (The concentration was 25ml 30% pyraclostrobin solution mixed with 50kg water) on his face. The way of spraying is through the water pipe (Figure 1B). At that time, he felt facial burning and tingling, and localized erythematous-edematous and scaly rash appeared on his face (Figure 2A) as well as front hairline scalp (Figure 2B). During the outpatient visit, the main symptoms were a facial burning sensation, itching, and tingling. This patient did not have any personal history of acute or chronic diseases. He is a farmer who has grown citrus and other crops for more than 20 years. He had used pyraclostrobin alone or pyraclostrobin-containing pesticide(s) for only one year before the spraying incident. Generally, it is sprayed once every 2–3 months in spring and autumn; once every month in summer. He denied any skin allergies associated with farming. When the spraying incident occurred, the patient recalled only the face and hairline were exposed to the air, while the rest of the body was covered with clothing.



Figure 1 Pesticide pyraclostrobin, Haisa (Qingdao, China, Active ingredient content: 30%; Suspending agent) having been sprayed on the patient's face (A). The patient is using his normal spraying equipment, in his normal protective equipment and clothing, spraying citrus (B).

Treatment methods included intramuscular injection of compound betamethasone injection (CBI) 1mL at the acupoint Zusanli (ST 36) and oral rupatadine fumarate tablets 10mg once a night. Fourth day after intramuscular injection of CBI, the patient's facial swelling and desquamation were significantly improved, and most of the erythema and papules disappeared. (Figure 2C) Complete improvement was observed without dermatitis recurrence at a 4-month follow-up.

Discussion

Pyraclostrobin (CAS no. 175013–18-0) is one of the most widely used agricultural fungicides in the world.¹ Since 2004, pyraclostrobin has been approved by the European Union for use as a fungicide or plant growth regulator. Pyraclostrobin belongs to the phycobilin family and acts at the level of complex III by inhibiting the fungal respiratory chain. It is a fungicide with preventive, therapeutic and eradication effects on a variety of fungal plant pathogens.² However, it may also endanger human or environmental health due to excessive and/or inappropriate use. Pyraclostrobin has the ability to prevent, treat and eradicate a variety of fungal and plant pathogens.² The study by Li et al³ have demonstrated the main

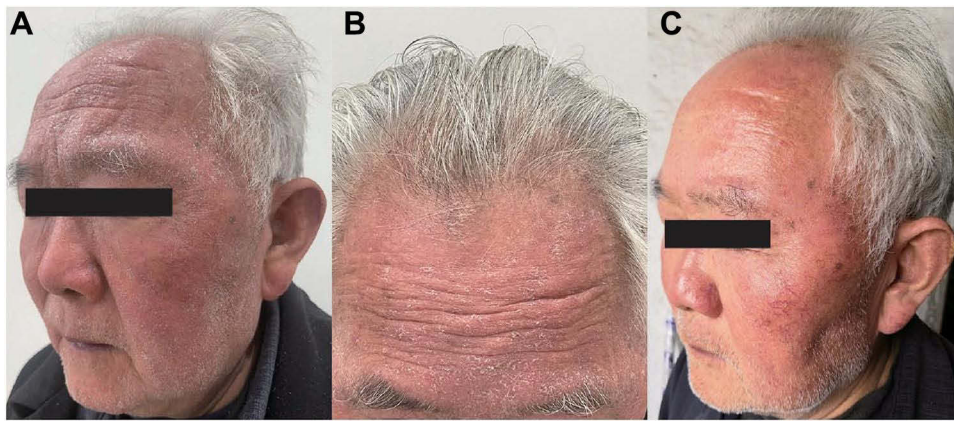


Figure 2 Erythematous-edematous and scaly rash on the face (A) and front hairline scalp (B). The fourth day after intramuscular injection of compound betamethasone injection (C).

toxicity routes and mechanisms of pyraclostrobin in fish under different exposure routes. The results showed that pyraclostrobin mainly entered fish through fish gills, and pyraclostrobin was observed in fish gills and hearts. Accumulation was highest and gill tissue showed the most severe damage. Symptoms due to pyraclostrobin have been reported as upper respiratory tract pain or irritation, chest pain, nausea, pruritis, skin redness, eye pain, weakness, headache, and dizziness.⁴

Contact dermatitis accounts for 95% of all occupational skin diseases.⁵ Divided into ICD and allergic contact dermatitis (ACD).⁶ ICD accounts for 80% of all contact dermatitis cases, is characterized by direct damage to the epidermal cells of the skin that triggers the innate immune system, resulting in an inflammatory skin response to various external stimuli.⁵ In contrast, ACD is characterized by a type IV delayed hypersensitivity response to the allergen. ICD usually presents as local dermatitis, which usually precedes ACD,⁷ and ICD is usually the main cause of occupational skin disease.⁸

The clinical symptoms of the patient we reported were mainly facial burning and tingling, and localized erythematous-edematous and scaly rash. Combining the patient's occupational environment and exposure to irritants, we diagnosed ICD. ICD caused by pesticide has rarely been reported. As a big agricultural country, this is not uncommon in China. The pesticide contact dermatitis has been reported in the past with spirotetramat,⁹ propiconazole, cypermethrin, isoproturon¹⁰ and 2-chloro-N-(2-ethoxyethyl)-N-(2-methyl-1-phenylprop-1-enyl) acetamide.¹¹ The irritation and sensitization of pesticides are still underestimated. Pesticide irritant contact dermatitis is more common than expected. It varies by regions and crop type.¹¹

When spraying pesticides, if workers do not pay attention to safety protection, it can cause chronic poisoning, acute poisoning, cancer, etc. Acute poisoning can be fatal and is the most obvious pesticide hazard. Long-term exposure to pesticides causes the accumulation of pesticides in the body, which can destroy the normal function of the nervous system. Small doses do not endanger human life but can reduce human immunity and cause diseases. To better protect the health and skin of farmers, preventive measures should be taken when spraying pesticides. The safety protection methods for spraying pesticides mainly include preparations for inspection before spraying, personal protective equipment (PPE), and selection of spraying time. PPE includes protective clothing, protective gloves, protective shoes, gas mask (with canister), protective glasses, etc. If workers do not have PPE, do not come into contact with pesticides with bare legs or short-sleeved clothes. Wear long-sleeved trousers, rubber shoes, rubber gloves and a gas mask. Where the skin is easily exposed, workers can apply the soap foam and rinse it with running water immediately after spraying to prevent pesticides from entering the body through the skin. It should be noted that when preparing and spraying pesticides, it is necessary to wear protective equipment, not only when spraying pesticides. Before spraying pesticides, carefully read the relevant instructions of pesticides, configuration methods, dispensing taboos, pay attention to the operation when dispensing, and do not spill them. Also check the spray device, whether the joints are firmly installed and there should be no leakage. Before spraying pesticides, notify nearby personnel (medical staff is the best), so that

poisoning accidents can be detected and rescued in time. If the skin is damaged, farmers cannot participate in the work of pesticide mixing and pesticide spraying.

The hazards of pesticides depend on the toxicity of the product and the duration of exposure. The severity of pesticide poisoning depends on several factors, including the chemical composition, formulation, route of entry into the body, amount ingested, and duration of exposure. Wearing PPE can significantly reduce the likelihood of skin, inhalation, eye, and oral exposure, which reduces the risk of pesticide poisoning. PPE not only protects agricultural producers, it also increases productivity. The farmers and ranchers should begin using PPE to protect themselves, their families, and employees when the work and its potential hazards require it. Controlling hazards at the source is the best way to protect farm workers. It is worth mentioning that the use of masks is crucial for the prevention of COVID-19 due to the global pandemic. Awareness of mask specifications should be raised in order to prevent skin side effects such as facial dermatoses, maskne and ICD.^{12,13} Non-PPE and non-SM masks should undergo more rigorous testing before they can be used.¹⁴ We cannot ignore the benefits of masks, which can prevent respiratory transmission of viruses, allergies and dermatitis brought on by the air.^{15,16}

Conclusion

To better protect the skin of agricultural workers, preventive measures should be undertaken, such as personal protective equipment, gas masks, protective clothing and goggles, which are indispensable for manual pesticide spraying. Pyraclostrobin diluted according to the instructions is a potential source of ICD. Agricultural workers should undertake preventive measures during manual pesticide spraying. Safety education and publicity are particularly important.

Consent Statement

Informed consent for publication of the case details and associated images was obtained from the patient was performed in accordance with the Helsinki Declaration. Institutional approval was not required to publish the case details.

Funding

This case report required no funding during its preparation. Hospital of Chengdu University of Traditional Chinese Medicine Scientific Research Capacity Enhancement “Hundred Talents Program”, (20B04) will support the study and the journal’s rapid service fee.

Disclosure

Chunxiao Li and Pingsheng Hao are co-correspondence authors for this study. The authors have no conflicts of interest to declare in this work.

References

1. Huang X, Yang S, Li B, et al. Comparative toxicity of multiple exposure routes of pyraclostrobin in adult zebrafish (*Danio rerio*). *Sci Total Environ*. 2021;777:145957. doi:10.1016/j.scitotenv.2021.145957
2. Dominguez AN, Emmert GE, Gil DM, Álvarez RMS. Experimental and theoretical vibrational study of the fungicide pyraclostrobin. *Spectrochim Acta A Mol Biomol Spectrosc*. 2021;259:119888. doi:10.1016/j.saa.2021.119888
3. Li H, Jing T, Li T, et al. Ecotoxicological effects of pyraclostrobin on tilapia (*Oreochromis niloticus*) via various exposure routes. *Environ Pollut*. 2021;285:117188. doi:10.1016/j.envpol.2021.117188
4. Centers for Disease Control and Prevention. Acute pesticide poisoning associated with pyraclostrobin fungicide—Iowa, 2007. *MMWR Morb Mortal Wkly Rep*. 2008;56(51–52):1343–1345.
5. Bains SN, Nash P, Fonacier L. Irritant Contact Dermatitis. *Clin Rev Allergy Immunol*. 2019;56(1):99–109. doi:10.1007/s12016-018-8713-0
6. Johansen JD, Bonefeld CM, Schwensen JFB, Thyssen JP, Uter W. Novel insights into contact dermatitis. *J Allergy Clin Immunol*. 2022. doi:10.1016/j.jaci.2022.02.002
7. Fonacier LS, Dreskin SC, Leung DY. Allergic skin diseases. *J Allergy Clin Immunol*. 2010;125(2 Suppl 2):S138–49. doi:10.1016/j.jaci.2009.05.039
8. Jacobsen G, Rasmussen K, Bregnhøj A, Isaksson M, Diepgen TL, Carstensen O. Causes of irritant contact dermatitis after occupational skin exposure: a systematic review. *Int Arch Occup Environ Health*. 2022;95(1):35–65. doi:10.1007/s00420-021-01781-0
9. Navarro-Triviño FJ, Linares-González L, Llamas-Molina JM, Ruiz-Villaverde R. Airborne allergic contact dermatitis caused by spirotetramat (Movento 150®). *Contact Dermatitis*. 2021. doi:10.1111/cod.13793
10. Sharma A, Mahajan VK, Mehta KS, et al. Pesticide contact dermatitis in agricultural workers of Himachal Pradesh (India). *Contact Dermatitis*. 2018;79(4):213–217. doi:10.1111/cod.13049
11. Madsen JT, Sherson DL, Kralund HR, Kyndi M, Baelum J, Andersen KE. Occupational allergic airborne contact dermatitis caused by pethoxamid - a new herbicide. *Contact Dermatitis*. 2016;74(5):315–316. doi:10.1111/cod.12540

12. Damiani G, Gironi LC, Kridin K, et al. Mask-induced Koebner phenomenon and its clinical phenotypes: a multicenter, real-life study focusing on 873 dermatological consultations during COVID-19 pandemics. *Dermatol Ther.* 2021;34(2):e14823. doi:10.1111/dth.14823
13. Damiani G, Gironi LC, Grada A, et al. COVID-19 related masks increase severity of both acne (maskne) and rosacea (mask rosacea): multi-center, real-life, telemedical, and observational prospective study. *Dermatol Ther.* 2021;34(2):e14848. doi:10.1111/dth.14848
14. Damiani G, Gironi LC, Pacifico A, et al. Masks use and facial dermatitis during COVID-19 outbreak: is there a difference between CE and non-CE approved masks? Multi-center, real-life data from a large Italian cohort. *Ital J Dermatol Venerol.* 2021;156(2):220–225. doi:10.23736/s2784-8671.21.06895-4
15. Mengi E, Kara CO, Alptürk U, Topuz B. The effect of face mask usage on the allergic rhinitis symptoms in patients with pollen allergy during the covid-19 pandemic. *Am J Otolaryngol.* 2022;43(1):103206. doi:10.1016/j.amjoto.2021.103206
16. Jefferson T, Del Mar CB, Dooley L, et al. Physical interventions to interrupt or reduce the spread of respiratory viruses. *Cochrane Database Syst Rev.* 2011;2011(7):Cd006207. doi:10.1002/14651858.CD006207.pub4

Clinical, Cosmetic and Investigational Dermatology

Dovepress

Publish your work in this journal

Clinical, Cosmetic and Investigational Dermatology is an international, peer-reviewed, open access, online journal that focuses on the latest clinical and experimental research in all aspects of skin disease and cosmetic interventions. This journal is indexed on CAS. The manuscript management system is completely online and includes a very quick and fair peer-review system, which is all easy to use. Visit <http://www.dovepress.com/testimonials.php> to read real quotes from published authors.

Submit your manuscript here: <https://www.dovepress.com/clinical-cosmetic-and-investigational-dermatology-journal>