

# Modified Perineal Reconstruction Combined with Anal Sphincter Repair for Obstetric Anal Sphincter Injuries

Xu Wang\*, Yi-Nan Liu\*, Di Sun, Si Chen, Bao-Lei Huang, Jian-Dong Tai

Department of Colorectal Surgery, The First Hospital of Jilin University, Changchun, 130000, People's Republic of China

\*These authors contributed equally to this work

Correspondence: Jian-Dong Tai, Department of Colorectal Surgery, the First Hospital of Jilin University, No. 1 of Xinmin Street, Chaoyang District, Changchun, 130000, People's Republic of China, Tel +86 431-88782291, Fax +86 431-85612352, Email taijmed@163.com

**Objective:** The aim of this study was to investigate the clinical effectiveness of modified perineal reconstruction combined with anal sphincter repair in the treatment of obstetric anal sphincter injuries (OASIS).

**Methods:** Twenty consecutive patients with an OASI who underwent modified perineal reconstruction combined with anal sphincter repair in the Department of Colorectal and Anal Surgery of the First Hospital of Jilin University from October 2015 to September 2017 were retrospectively enrolled in this study. Anal function was evaluated using the Williams grade, the Wexner score, anorectal manometry, and transrectal ultrasound.

**Results:** Differences in both the Williams grade and the Wexner score prior to operation and following surgery indicated that anal function had improved, and these differences were statistically significant ( $P < 0.05$ ). These indices also showed further improvement six months after surgery as compared with values at one month, and again, these differences were statistically significant ( $P < 0.05$ ). In addition, anorectal manometry at six months following surgery showed statistically significant differences in the maximum anal resting pressure, maximum anal systolic pressure, and anal defecation pressure as compared with values prior to operation ( $P < 0.05$ ). Postoperative endorectal ultrasound revealed that the anal sphincter presented with close imbricated overlapping.

**Conclusion:** Modified perineal reconstruction combined with anal sphincter repair in the treatment of female perineal defect is associated with a good clinical outcome, strengthening anal function, and reconstructing the perineum, and is a possible method for clinical treatment.

**Keywords:** modified perineal reconstruction, bilateral V-Y island flap, perineal laceration, fecal incontinence, anal function

## Introduction

Obstetric anal sphincter injuries (OASIS) are mainly caused by third- and fourth-degree perineal lacerations during pregnancy and vaginal delivery. The main clinical manifestations are incontinence of flatus and feces. In recent years, with increasing attention to postpartum quality of life for women, relevant reports show that the incidence of OASIS is 11%,<sup>1</sup> and 13–20% of these OASIS patients present with fecal incontinence. Most patients have long-term fecal incontinence, especially when they have loose stool, and this has a great impact on daily life and may seriously damage the physical and mental health of patients.<sup>2</sup> In addition, women with previous OASIS are at a higher risk of recurrence in the subsequent pregnancy.<sup>3</sup> Unsuccessful primary repair of fourth-degree obstetric trauma can lead to permanent communication between the rectum and the vagina, which, in association with full-thickness anal sphincter defects.<sup>4</sup> Therefore, the timely diagnosis and treatment of severe perineal laceration is paramount in OASIS. In the past, sphincter repair and perineal reconstruction were often performed to treat OASIS, but the curative results were not satisfactory.<sup>5</sup> Between October 2015 and September 2017, 20 patients with an OASI were treated with modified perineal

reconstruction combined with anal sphincter repair in the Department of Colorectal and Anal Surgery at the First Hospital of Jilin University. A good clinical outcome was achieved and the results are presented.

## Materials and Methods

Twenty consecutive patients with an OASI who underwent modified perineal reconstruction combined with anal sphincter repair in the Department of Colorectal and Anal Surgery of the First Hospital of Jilin University from October 2015 to September 2017 were retrospectively enrolled in this study, and the duration of clinical symptoms was 12–24 months (median, 18 months). This study was approved by the Ethics Committee of the First Hospital of Jilin University. Written informed consent was obtained from all participants. This study was conducted in accordance with the declaration of Helsinki.

## General Information

Inclusion criteria were as follows: (1) the patient complained of uncontrollable defecation, uncontrollable flatus, and/or vaginal and urinary tract irritation, (2) on perineal examination, the external orifice of the vagina expanded obviously, and the perineal body disappeared or remained small during digital rectal examination. When the patient was asked to perform defecation-like movements, anal atony was observed, (3) endorectal ultrasound revealed anal sphincter rupture, the opening angle was  $>90$  degrees, and the perineal body was broken or the rectovaginal septum was thin, (4) anorectal manometry revealed that anorectal pressure decreased significantly and anorectal pressure was abnormal, (5) patients who requested surgery after failure of conservative treatment, and (6) patients who were Williams grade C or above preoperatively.

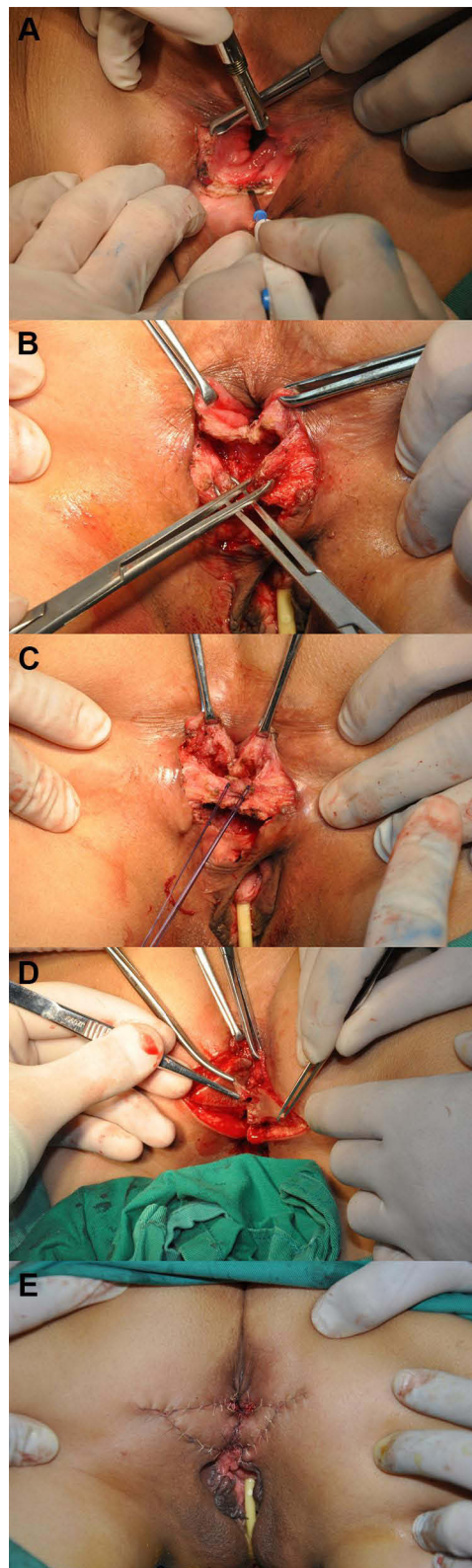
Exclusion criteria: (1) Patients with severe systemic disease and high risk of anesthesia, (2) Suffering from mental diseases or communication disorders, unable to cooperate with diagnosis and treatment, (3) Patients with a history of other perianal and vaginal operations.

## Surgical Methods

The patients were placed in the lithotomy or clasp-knife position and underwent spinal-epidural or intravenous inhalation general anesthesia. Surgical technique was as follows: (1) a horizontal incision of 3–5 cm was made at the rectovaginal septum (the actual distance was dependent on the opening angle of the anal sphincter). Two Allis forceps were used to clamp both the vaginal and anal sides to maintain moderate tension. Skin and subcutaneous tissues were incised to a depth of 2–3 cm (the actual distance was dependent on the rupture depth of the anal sphincter), and hemostasis was fully achieved during the separation, as shown in [Figure 1A](#), (2) find the ends of external anal sphincter at the incision site, and fully separate the two free ends. The dissected external anal sphincter was superimposed and closed 1.0–1.5 cm in a double-row buckle manner, as shown in [Figure 1B](#) (3) the anus was examined digitally, and the length of the sphincter was marked at the point where anal circumcision was appropriate, and 3–0 absorbable sutures (Vicryl, Johnson & Johnson) were used to create overlapping sutures, as shown in [Figure 1C](#), (4) due to perineal skin defects and high skin tension, the perineum was repaired using a bilateral V-Y advancement flap,<sup>6</sup> as shown in [Figures 1D](#) and [E](#), and a negative pressure suction tube was placed under the flap for continuous drainage. Attention should be paid to the risk of incision tearing and incision infection. Therefore, the patient should be forbidden to get out of bed for 3 days, while fasting for 3 days to reduce the number of defecation, and the diet should be mainly liquid and soft food within 1 week. Antibiotics were given 3 days after the operation, dressing was changed at the incision every day, and the healing was observed. Generally, the drainage tube can be removed two weeks after the operation when the incision has healed well and there is no obvious exudation.

## Assessment of Clinical Outcome

Both the Williams classification<sup>7</sup> and the Wexner score<sup>8</sup> were used to evaluate fecal continence before and after surgery. Anorectal manometry was used to analyze parameters such as maximum resting pressure, maximum systolic pressure, anal defecation pressure, and rectoanal inhibitory reflex before and after surgery, so as to evaluate anal function and the result of surgery. Transrectal ultrasound was used to visualize the anal sphincter after amputation and suture after surgery.



**Figure 1** Surgical steps of modified perineal reconstruction combined with anal sphincter repair. (A) Horizontal incision of rectovaginal septum; (B) looking for the broken external anal sphincter; (C) repair of external anal sphincter; (D) making V-Y advancement flap; (E) postoperative appearance.

## Statistical Methods

Data were analyzed using the statistical software SPSS 19.0. Measurement data were expressed as the mean  $\pm$  standard deviation ( $X \pm SD$ ), the paired sample *t*-test was used to compare two groups, and comparison among groups was carried out using one-way analysis of variance. Count data were expressed as a percentage (%) and were compared using the  $X^2$  test.  $P < 0.05$  was considered to be statistically significant.

## Results

Operation was successful for all 20 patients. The average operation time was 61 minutes (range, 42–79 minutes), and the average postoperative hospitalization period was 13 days (range, 8–17 days). Postoperative complications included four cases of incision pain (20%), one case of anal swelling and discomfort (5%), and one case of local necrosis of the flap (5%). For patients with incision pain, good control can generally be achieved with the administration of non-steroidal anti-inflammatory drugs (NSAIDs). In the case of local flap necrosis, this healed after two months of debridement and dressing changes: defecation function was not affected, and no serious complications such as infection or anal incontinence occurred following surgery in this patient.

Preoperative Subjective Williams score included 5 (25.0%) patients with grade C, 10 (50.0%) patients with grade D, and 5 (25.0%) patients with grade E. In the Subjective Williams score of patients one month after surgery, there were 4 (20.0%) grade A patients, 12 (60.0%) grade B patients, and 4 (20.0%) grade C patients. The Subjective Williams score of patients at 6 months postoperatively included 17 (85.0%) grade A patients and 3 (15.0%) grade B patients. Subjective Williams grades were better at one month following surgery as compared with grades recorded prior to surgery, and grades were also improved at six months following surgery as compared with those recorded at one month. All of these differences were statistically significant ( $P < 0.05$ , Table 1).

The subjective Wexner scores were  $1.35 \pm 0.99$  at one month following surgery and  $0.20 \pm 0.41$  after six months, as compared with the preoperative score of  $9.00 \pm 4.17$ . All these differences were statistically significant ( $P < 0.05$ , Table 2).

Comparison of objective anorectal dynamic testing prior to operation and at six months post-surgery identified statistically significant differences in the following parameters: (1) maximum anal resting pressure was  $34.05 \pm 5.75$  mmHg prior to surgery and  $59.90 \pm 5.10$  mmHg at six months post-surgery ( $P < 0.001$ ), (2) maximum anal systolic pressure was  $59.90 \pm 10.88$  mmHg and  $122.35 \pm 10.70$  mmHg ( $P < 0.001$ ), respectively, and (3) anal defecation pressure was  $30.75 \pm 6.93$  mmHg and  $51.30 \pm 4.61$  mmHg, respectively ( $P < 0.05$ , Table 3). Postoperative endorectal ultrasound revealed that the sphincter defect disappeared, the anal sphincter complex was intact, and local thickening of the external anal sphincter was seen at 12 o'clock.

**Table 1** Comparison of Williams Score Before and After Operation

Williams Score	Before Operation	One Month After Operation*	Six Months After Operation**	$\chi^2$	P
A	0 (0.0%)	4 (20.0%)	17 (85.0%)	72.838	<0.001
B	0 (0.0%)	12 (60.0%)	3 (15.0%)		
C	5 (25.0%)	4 (20.0%)	0 (0.0%)		
D	10 (50.0%)	0 (0.0%)	0 (0.0%)		
E	5 (25.0%)	0 (0.0%)	0 (0.0%)		

**Notes:** \*Compared with before operation, the difference was statistically significant,  $P < 0.05$ . \*\*Compared with one month after operation, the difference was statistically significant,  $P < 0.05$ .

**Table 2** Comparison of Wexner Score

	Before Operation	One Month After Operation*	Six Months After Operation**	F	P
Wexner score	$9.00 \pm 4.17$	$1.35 \pm 0.99$	$0.20 \pm 0.41$	74.155	<0.001

**Notes:** \*Compared with before operation, the difference was statistically significant,  $P < 0.05$ . \*\*Compared with one month after operation, the difference was statistically significant,  $P < 0.05$ .

**Table 3** Comparison of Anorectal Pressure Measurement Parameters

	Before Operation	Six Months After Operation	t	p
Maximum resting pressure (mmHg)	34.05±5.75	59.90±5.10	-24.342	<0.001
Maximum systolic blood pressure (mmHg)	59.90±10.88	122.35±10.70	-50.249	<0.001
Anal defecation pressure (mmHg)	30.75±6.93	51.30±4.61	-18.991	<0.001
Rectoanal inhibitory reflex index (mL)	8.40±1.39	8.55±1.28	-1.143	0.267

## Discussion

The internal and external anal sphincters, the levator ani muscle, the rectal wall, anal skin and its subcutaneous tissue, the pelvic fascia, and the perineal body are all integral to the maintenance of normal anal sphincter function,<sup>9</sup> and damage to any part will result in dysfunction. Anal continence is guaranteed by the anal sphincter complex, the action of puborectal muscle and the capacity of the rectal ampulla. Postpartum perineal laceration is one of the commonest causes of anal incontinence, with external anal sphincter injury being more common than injury to the internal anal sphincter. Perineotomy can reduce the incidence of internal sphincter injury, but it can increase the incidence of external sphincter injury, and severe cases are complicated with rectovaginal fistula and rectal prolapse. Both rectovestibular fistula repair using a thread-drawing procedure and transperineal operation, and perineal defect caused by infection, will similarly damage internal and external sphincters resulting in anal incontinence.

The core technique of modified perineal reconstruction consists of two parts: the repair of the anal sphincter and the reconstruction of the perineal body and its skin. To begin, the anal sphincter is correctly dissected and after confirmation, double suturing is performed. There are two kinds of suture methods: broken end anastomosis suture and broken end overlapping suture. Gynecologists prefer the former, but anorectal surgeons may choose the latter. Through the observation of the curative outcome of the overlapping repair method in 32 patients, Fernando<sup>10</sup> proposed that the objective examination indices and subjective sensation of patients were better using this method than the anastomosis method. Fitzpatrick<sup>11</sup> used a prospective randomized controlled method to compare the therapeutic effect of overlapping repair or anastomosis in 142 and 124 patients, respectively, and concluded that there was no significant difference between the two methods. In our department, overlapping repair was the technique used in all patients, and anal function was significantly improved after operation.

Regarding perineal reconstruction, in the past, S-shaped or Z-shaped perianal free flap transplantation has been used to treat anal incontinence. However, this operation is relatively complicated, and as the anus is not sterile, the free flap is at risk of infection. Also, when the blood supply from the subcutaneous tissue is compromised, the flap can become ischemic, and this can result in failure of normal growth and reduced resistance to infection, one of the main causes of necrosis of the free flap transplanted in the anus. In addition, the flap should be kept in a fixed position following transplantation. However, the flap cannot be kept fixed: when the anal sphincter contracts or defecation occurs, the anal flap will move easily, resulting in flap tension that may lead to necrosis. Therefore, in this study, the bilateral V-Y island flap advancement technique was used to complete perineal reconstruction. This does not completely cut off the blood supply to the skin graft, and at the same time reduces the skin flap tension, thus avoiding contracture and movement.

This study showed that at six months following surgery, the perineal body tissue was fully formed, and the anus closed well. There were statistically significant differences in the subjective Williams grade at one month post operation as compared with the grade recorded prior to surgery, and also at six months as compared to one month following surgery ( $P < 0.05$ ). There were also significant differences in subjective Wexner scores when comparing scores prior to surgery with those at both one month and six months following the operation. The results showed that after surgery, the anal subjective perception function of patients was significantly improved, and this was positively correlated with recovery time. At six months following surgery, the objective anorectal dynamic parameters had improved in comparison to those obtained prior to the operation, including a statistically significant difference in the maximum anal resting pressure before and after operation. This objective functional test further confirms the improvement of anal function seen.

One of the limitations was that the small sample size and lack of controls may weaken the generalisability of the results. Another limitation was the shorter follow-up period of 6 months. In the next study, a large sample size of patients should be included in a randomized, blind, prospective study to explore the effectiveness of the relevant treatment.

## Conclusion

In summary, modified perineal reconstruction results in a good clinical outcome in the treatment of female perineal defect, reconstructing the perineum, and strengthening anal function. The operation is simple, safe and effective, and is therefore a possible method for clinical treatment. However, for patients with perineal nerve injury, the curative effect has yet to be confirmed, and further study is required.

## Ethics Approval and Consent to Participate

This study was conducted with approval from the Ethics Committee of the First Hospital of Jilin University. This study was conducted in accordance with the declaration of Helsinki. Written informed consent was obtained from all participants.

## Funding

There is no funding to report.

## Disclosure

The authors report no conflicts of interest in this work.

## References

1. Meister MR, Rosenbloom JL, Lowder JL, Cahill AG. Techniques for repair of obstetric anal sphincter injuries. *Obstet Gynecol Surv.* 2018;73(1):33–39. doi:10.1097/OGX.0000000000000521
2. Lincová M, Neumannová H, Mikysková I, Zikán M. Obstetric anal sphincter injuries - review of our data between 2015–2017. *Ceska Gynekol.* 2019;84(1):18–22.
3. Barba M, Bernasconi DP, Manodoro S, Frigerio M. Risk factors for obstetric anal sphincter injury recurrence: a systematic review and meta-analysis. *Int J Gynaecol Obstet.* 2021. PMID: 34559892. doi:10.1002/ijgo.13950.
4. Spelzini F, Frigerio M, Manodoro S, Verri D, Nicoli E, Milani R. Repair of a traumatic cloaca after obstetric anal sphincter injury. *Int Urogynecol J.* 2016;27(3):495–497. PMID: 26520839. doi:10.1007/s00192-015-2866-7
5. Wexner SD, Bleier J. Current surgical strategies to treat fecal incontinence. *Expert Rev Gastroenterol Hepatol.* 2015;9(12):1577–1589. doi:10.1586/17474124.2015.1093417
6. La Padula S, Abbate V, Di Monta G, Schonauer F. Levator alae nasi muscle V-Y island flap for nasal tip reconstruction. *J Craniomaxillofac Surg.* 2017;45(3):432–435. doi:10.1016/j.jems.2016.12.019
7. Williams NS, Patel J, George BD, Hallan RI, Watkins ES. Development of an electrically stimulated neoanal sphincter. *Lancet.* 1991;338(8776):1166–1169. doi:10.1016/0140-6736(91)92031-V
8. Jorge JM, Wexner SD. Etiology and management of fecal incontinence. *Dis Colon Rectum.* 1993;36(1):77–97. doi:10.1007/BF02050307
9. Wang R, Lefevre R. Management of urinary and fecal incontinence in patients with complex regional pain syndrome. *Female Pelvic Med Reconstr Surg.* 2016;22(1):e14–6. doi:10.1097/SPV.0000000000000220
10. Fernando RJ, Sultan AH, Kettle C, Thakar R. Methods of repair for obstetric anal sphincter injury. *Cochrane Database Syst Rev.* 2013;12:CD002866.
11. Fitzpatrick M, Cassidy M, O'Connell PR, O'Herlihy C. Experience with an obstetric perineal clinic. *Eur J Obstet Gynecol Reprod Biol.* 2002;100(2):199–203. doi:10.1016/S0301-2115(01)00427-4

Therapeutics and Clinical Risk Management

Dovepress

Publish your work in this journal

Therapeutics and Clinical Risk Management is an international, peer-reviewed journal of clinical therapeutics and risk management, focusing on concise rapid reporting of clinical studies in all therapeutic areas, outcomes, safety, and programs for the effective, safe, and sustained use of medicines. This journal is indexed on PubMed Central, CAS, EMBase, Scopus and the Elsevier Bibliographic databases. The manuscript management system is completely online and includes a very quick and fair peer-review system, which is all easy to use. Visit <http://www.dovepress.com/testimonials.php> to read real quotes from published authors.

Submit your manuscript here: <https://www.dovepress.com/therapeutics-and-clinical-risk-management-journal>