

VYC-20L is Safe and Effective for Improving Volume and Aesthetic Appearance of the Nose in Chinese Adults

Dong Li¹, Jiaming Sun², Yuguang Zhang³, Xiaojun Wang⁴, Songlin Yang⁵, Candice Harvey⁶, Lijuan Zhang⁷

¹Department of Plastic Surgery, Peking University Third Hospital, Beijing, People's Republic of China; ²Department of Plastic Surgery, Union Hospital Tongji Medical College, Huazhong University of Science and Technology, Wuhan, People's Republic of China; ³Department of Plastic Surgery, Shanghai 9th People's Hospital, Shanghai, People's Republic of China; ⁴Department of Plastic Surgery, Peking Union Medical College Hospital, Beijing, People's Republic of China; ⁵Department of Plastic Surgery Shanghai 6th People's Hospital, Shanghai, People's Republic of China; ⁶Clinical Development, Allergan Aesthetics, an AbbVie Company, Marlow, UK; ⁷Clinical Development, Allergan Aesthetics, an AbbVie Company, Beijing, People's Republic of China

Correspondence: Dong Li, Peking University Third Hospital, No. 49 North Garden Road, Haidian District, Beijing, 100191, People's Republic of China, Tel +86 10 8226 6699, Fax +86 10 8226 6116, Email lidong9@sina.com

Purpose: Soft tissue filler injection is less invasive than surgical approaches for facial aesthetic improvement. This study evaluated the safety and effectiveness of the soft tissue filler VYC-20L (Juvéderm Voluma[®] XC) for improvement of volume and aesthetic appearance of the nose in Chinese subjects.

Patients and Methods: In a prospective, multicenter, no-treatment–controlled study in China, adult subjects were randomized 3:1 to receive VYC-20L (treatment group) or have optional treatment delayed by 24 weeks (control group). The treatment group received VYC-20L on day 1 plus optional touch-up at week 8 for suboptimal improvement. The primary effectiveness measure was mean change in nose area volume from baseline to week 24 by digital analysis of three-dimensional (3D) images. Multiple secondary effectiveness and safety measures were assessed.

Results: Of 164 subjects randomized, 162 were treated, and 157 comprised the modified intent-to-treat population (mean age, 31 years; 94% female). In the treatment group, mean VYC-20L volume injected was 1.18 mL (initial treatment) and 0.67 mL (touch-up; n = 46 [38.3%]). VYC-20L achieved significantly larger changes in nose area volume than control at week 24 (2.032 vs –0.005 cm³, respectively; *p* < 0.0001) and greater improvements on the Global Aesthetic Improvement Scale (investigator and subject), Nose Satisfaction Scale, and other 3D measures. No treatment-related adverse events occurred. Most injection site responses were mild/moderate, resolving within 14 days. Mean initial/touch-up treatment procedural pain ratings were less than 3 (0–10 scale; higher = worse pain).

Conclusion: VYC-20L is safe and effective for nose augmentation in Chinese adults.

Keywords: dermal fillers, hyaluronic acid, injections, nose, rhinoplasty

Introduction

The shape of the nose area in Asian individuals differs from that of white individuals, in that it is typically flatter, shorter, and wider.^{1,2} Many Asian individuals report a desire for structural definition and anterior projection of the nose to correct perceived deficiencies in facial aesthetic features.^{3,4} Thus, surgical augmentation rhinoplasty, the most common rhinoplasty procedure performed in Asian subjects,¹ is often used to enhance the appearance of the nose, but such procedures require general anesthesia and are associated with several potential complications, including scarring, implant displacement, prolonged swelling, asymmetry, and functional changes.^{5–8} Soft tissue fillers may provide an alternative to surgical augmentation rhinoplasty in some cases.^{7,9–12} Compared with surgical approaches, injection of a soft tissue filler is minimally invasive, and recovery times are typically shorter.²

The soft tissue filler VYC-20L (Juvéderm Voluma[®] XC; Allergan Aesthetics, an AbbVie Company, Dublin, Ireland) contains 20 mg/mL crosslinked hyaluronic acid (HA) in a physiologic buffer with 0.3% (w/w) lidocaine hydrochloride.

VYC-20L was developed to volumize the midface and was shown in clinical trials to provide correction of age-related volume deficits for up to 2 years.^{13,14} A retrospective analysis of the effects of VYC-20L injected in a diamond-shaped area (glabella, malar eminences, and chin) of the face in Asian women showed that treatment volumized the face to become more 3-dimensional (3D) and was well tolerated.¹⁵ VYC-20L has ideal properties for providing structure, shape, and support to the nose, as previously evaluated in a small study of Asian subjects.⁴

The objective of this study was to evaluate the safety and effectiveness of VYC-20L for the improvement of the volume and aesthetic appearance of the nose in Chinese adults.

Methods

Study Design

This was a prospective, multicenter, randomized, no-treatment–controlled study carried out at 5 study centers in China from February 2018 to December 2019 (NCT03430986). Study approval was obtained from the institutional review board affiliated with each site ([Supplementary Table 1](#)). Eligible subjects were randomized 3:1 to receive VYC-20L (treatment group) or to have optional treatment delayed by 24 weeks (control group). The study contained a control period (from randomization to 24 weeks after the last treatment [treatment group] or to 24 weeks after randomization [control group]) to compare effectiveness between groups and a post-control period (end of control period to 48 weeks after last treatment [treatment group] or to 24 weeks after last treatment [control group]) to collect long-term safety and effectiveness data.

Before randomization, 3D digital images (VECTRA M3; Canfield Scientific, Inc., Fairfield, NJ) were captured for all eligible subjects for use as baseline data in calculations of nose volume change and aesthetic improvement. The study protocol was approved by the Ethics Committee of each site. The study was conducted in compliance with the Declaration of Helsinki and Good Clinical Practice guidelines and ethical principles for clinical research, as well as in accordance with applicable local regulations.

Subjects

Eligible subjects were male or female Chinese adults aged ≥ 18 years who were either “dissatisfied” or “very dissatisfied” with their aesthetic appearance due to structural features of the nose based on assessment with the 5-point Nose Satisfaction Scale (NSS; -2 = very dissatisfied, -1 = dissatisfied, 0 = neutral, 1 = satisfied, 2 = very satisfied). Subjects required a total VYC-20L volume of 0.5 to 3.0 mL, and treatment to the nasal dorsum was mandatory for aesthetic improvement in the opinion of the treating investigator (TI). The TI confirmed that each subject had a reasonable treatment goal for aesthetic improvement, and subjects and TIs were aligned on treatment goals. All subjects were required to provide written informed consent.

Key exclusion criteria were prior or planned nasal surgery or filler injection; nasal trauma or residual deficiency, congenital deformity, or scarring impacting effectiveness evaluation; a small, shallow nose prohibiting accommodation of the required volume of filler; prior or planned receipt of implants or fat in the nose or adjacent area; prior or planned receipt of botulinum toxin, laser resurfacing, photomodulation, intense pulsed light, radiofrequency, dermabrasion, chemical peel, or procedures in the nose or adjacent area; active or history of recurring chronic sinusitis/rhinitis; inflammatory or infectious processes, an unhealed wound, or lesions in the nose area; and impaired cardiac, hepatic, or renal function.

Treatment

VYC-20L was injected into the nose using a 27G x ½-inch needle. Injection sites included the nasal dorsum, columella, and anterior nasal spine into the upper-periosteal (supraperiosteal and/or supraperichondrial) layer; injections were not permitted in nonmidline areas of the nose, nasal tip, and glabella area. The use of anesthesia (eg, ice packs, lidocaine cream, local anesthesia, nerve block) and antiseptics was permitted. The treatment group received initial treatment with VYC-20L on day 1 plus optional touch-up at week 8. If the subject and TI felt that improvement was not optimal at week 8, a touch-up treatment was performed. A total volume of at least 0.5 mL, but not exceeding 3.0 mL, of VYC-20L for initial and touch-up treatment combined was used. If the injected volume of the initial treatment was less than 0.5 mL,

touch-up was required at week 8 to meet the protocol-defined minimal injected volume. The control group had the option to receive treatment at week 24. Neither the TI nor the subject was blinded to treatment; however, the evaluating investigator (EI) was blinded to treatment.

Within the first 24 hours of treatment, subjects were to avoid strenuous exercise, extensive sun or heat exposure, and alcoholic beverages. Use of hyaluronidase was not permitted during the study, and no phototherapy or laser treatment was permitted for 3 months after the last study treatment. Follow-up visits for safety and effectiveness occurred at weeks 8, 16, and 24 after the last treatment in the control period and at weeks 36 and 48 in the postcontrol period (treatment group) and at weeks 8, 16, and 24 after randomization in the control period and at weeks 8, 16, and 24 after optional treatment (for those who chose optional treatment; control group).

Effectiveness Endpoints and Assessments

The primary effectiveness measure was mean change in nose area volume from baseline to week 24, based on digital analysis of 3D images (conducted by a blinded independent Canfield Scientific technician; [Figure 1](#)).

The 5-point Global Aesthetic Improvement Scale (GAIS) was used by the EI (live) and the subject (using a mirror) to rate improvement from baseline (-2 = much worse, -1 = worse, 0 = no change, 1 = improved, 2 = much improved). The treatment group's week 24 responder rate (ratings of improved or much improved) per the EI and per the subject were secondary effectiveness measures. Subjects assessed treatment satisfaction with the NSS (using a mirror). The treatment group's week 24 responder rate (ratings of satisfied or very satisfied) was a secondary effectiveness measure. Other effectiveness measures were dorsal height, dorsal width, nasofrontal angle, nasolabial angle, nasal root height, nasal length, and ala depth by 3D image analysis and subject response to the question, "Would you recommend the nose treatment to a friend?"

Safety Endpoints

Procedural pain was rated by the subject on an 11-point scale (0 = no pain to 10 = worst pain imaginable) immediately after receiving treatment. Injection site responses (ISRs) and their severity and duration were recorded by subjects in a 56-day posttreatment safety diary, starting on the day of treatment and touch-up. Reactions listed in the diary were those reported previously with HA soft tissue filler injections (redness, pain after injection, tenderness to touch, firmness, swelling, lumps/bumps, bruising, itching, discoloration). Adverse events (AEs) were recorded based on TI observation and inquiry at scheduled visits.

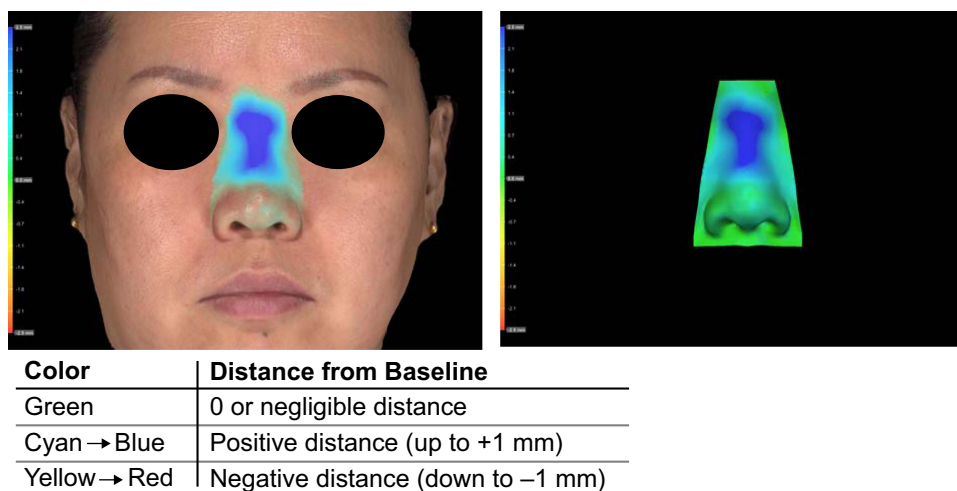


Figure 1 The primary effectiveness endpoint was the mean change in nose area from baseline to week 24 based on digital 3-dimensional (3D) imaging analysis (VECTRA M3). The VECTRA Analysis Module (VAM) generates a color-by-distance map, which represents the distance between the baseline and follow-up images quantified on a color scale of +1 mm to -1 mm. The volume change in the nose area is then calculated. For example, the representative subject (see [Figure 4A](#) for more details) with an overlay image before and after treatment showed a mean volume change of $+2.72 \text{ cm}^3$ in the nose area from baseline to week 24.

Statistical Analyses

The target number of randomized subjects was 160. The analysis population was the modified intent-to-treat (mITT) population: for the treatment group, the mITT included all randomized subjects who had at least 1 treatment and completed at least 1 effectiveness assessment; for the control group, the mITT included all randomized subjects who completed at least 1 effectiveness assessment. The VYC-20L initially treated population included all randomized subjects who received treatment in the control period with up to 48 weeks of follow-up. The safety population included all subjects who had at least 1 treatment.

Key outcomes were summarized with descriptive statistics; 2-sided 95% CIs were provided where appropriate. Least-square estimates and tests were based on a mixed-effects model for repeated measures with treatment, timepoint, and treatment-by-timepoint interaction as a fixed effect using an unstructured covariance matrix. Differences between treatment and control groups were also evaluated with a 2-sided, 2-group *t*-test (or Wilcoxon rank-sum test as appropriate) at the 5% significance level.

Results

Subjects

Of 179 individuals screened, 164 were randomized (treatment group, *n* = 122; control group, *n* = 42) and 162 were treated (treatment group, *n* = 120; control group, *n* = 42). The mITT and safety populations included 157 subjects (treatment group, *n* = 120; control group, *n* = 37). The study was completed by 95% of subjects in the treatment group and 79% of subjects in the control group. The mean subject age at baseline was 31 years, and 94% of subjects were female. Subject demographics and baseline characteristics are summarized in Table 1.

For subjects in the treatment group (*n* = 120), the mean volume of VYC-20L injected was 1.18 mL for initial treatment and 0.67 mL for the 46 subjects (38.3%) who elected to undergo touch-up treatment. Mean total volume (combined initial + touch-up) was 1.43 mL. Injection sites were the nasal dorsum (100%), columella (50.8%), and anterior nasal spine (48.3%). The mean volume of VYC-20L injected for initial and touch-up treatments combined was 1.18 mL in the nasal dorsum, 0.26 mL in the columella, and 0.25 mL in the anterior nasal spine.

For subjects in the control group who elected to undergo optional treatment after 24 weeks, the mean volume of VYC-20L injected was 1.02 mL for initial treatment (*n* = 31 subjects) and 0.55 mL for the 14 subjects (45.2%) who elected to undergo touch-up treatment. Mean total volume (combined initial + touch-up) was 1.27 mL. Injection sites were the nasal dorsum (100%), columella (25.8%), and anterior nasal spine (38.7%). The mean volume of VYC-20L injected for initial and touch-up treatments combined was 0.88 mL in the nasal dorsum, 0.26 mL in the columella, and 0.18 mL in the anterior nasal spine.

Table 1 Subject Demographic and Baseline Characteristics (mITT Population)

Characteristic	Treatment (<i>n</i> = 120)	Control (<i>n</i> = 37)	Total (<i>N</i> = 157)
Mean (SD) age, y	32.0 (10.4)	28.9 (6.0)	31.3 (9.6)
Age group, <i>n</i> (%)			
<30 y	64 (53.3)	24 (64.9)	88 (56.1)
30–39 y	33 (27.5)	10 (27.0)	43 (27.4)
40–49 y	10 (8.3)	3 (8.1)	13 (8.3)
≥50 y	13 (10.8)	0	13 (8.3)
Sex, <i>n</i> (%)			
Male	8 (6.7)	2 (5.4)	10 (6.4)
Female	112 (93.3)	35 (94.6)	147 (93.6)
Mean (SD) BMI, kg/m ²	21.57 (3.159)	21.21 (3.552)	21.48 (3.248)

Abbreviations: BMI, body mass index; mITT, modified intent-to-treat.

Effectiveness

Changes from baseline in nose area volume over time are shown in Figure 2. On the primary effectiveness endpoint, subjects treated with VYC-20L had significantly larger changes from baseline in nose area volume than controls at week 24 (least-squares mean change from baseline, 2.032 vs -0.005 cm^3 , respectively; $p < 0.0001$). The mean change from baseline in nose area volume for the treatment group was also significantly greater than that for the control group at weeks 8 and 16. In the postcontrol period, the mean change from baseline in nose area volume was 1.907 cm^3 at week 36 and 1.953 cm^3 at week 48.

Responder rates on the GAIS evaluated by the blinded EI were significantly higher for subjects treated with VYC-20L than for controls at week 24 (87.2% vs 18.8%, respectively; $p < 0.0001$) and at weeks 8 and 16 (Figure 3A). At week 24, the subject-assessed GAIS responder rate was 91.5% for subjects treated with VYC-20L (Figure 3B). In the postcontrol

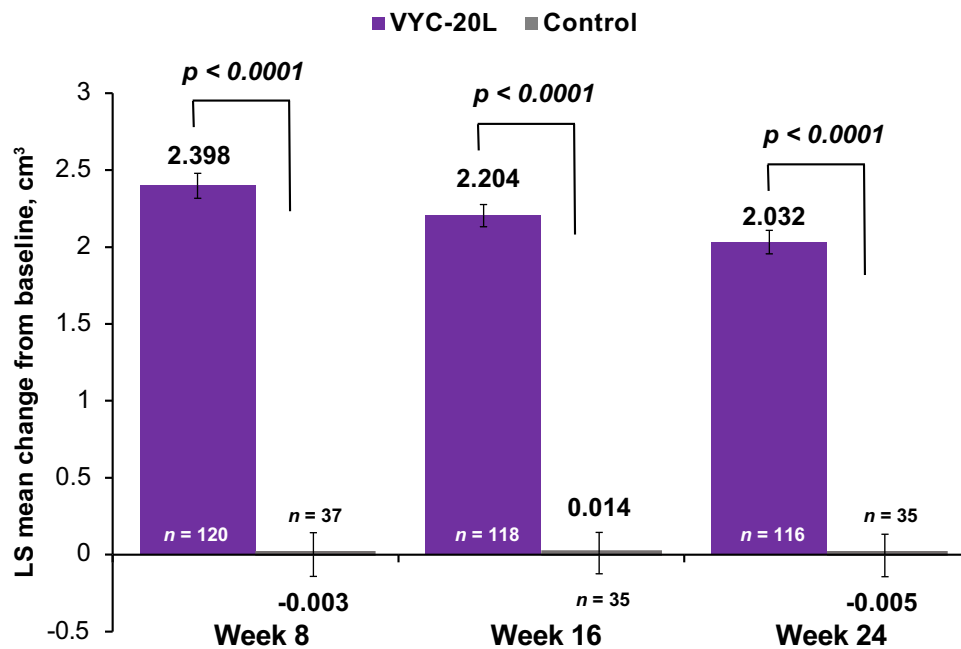


Figure 2 Change from baseline in nose area volume^a by treatment visit for subjects treated with VYC-20L vs no-treatment control (mITT population). ^aMeasured using 3D imaging; mixed-effects model for repeated measures. Error bars represent standard error of the mean. 3D, 3 dimensional; LS, least squares; mITT, modified intent-to-treat.

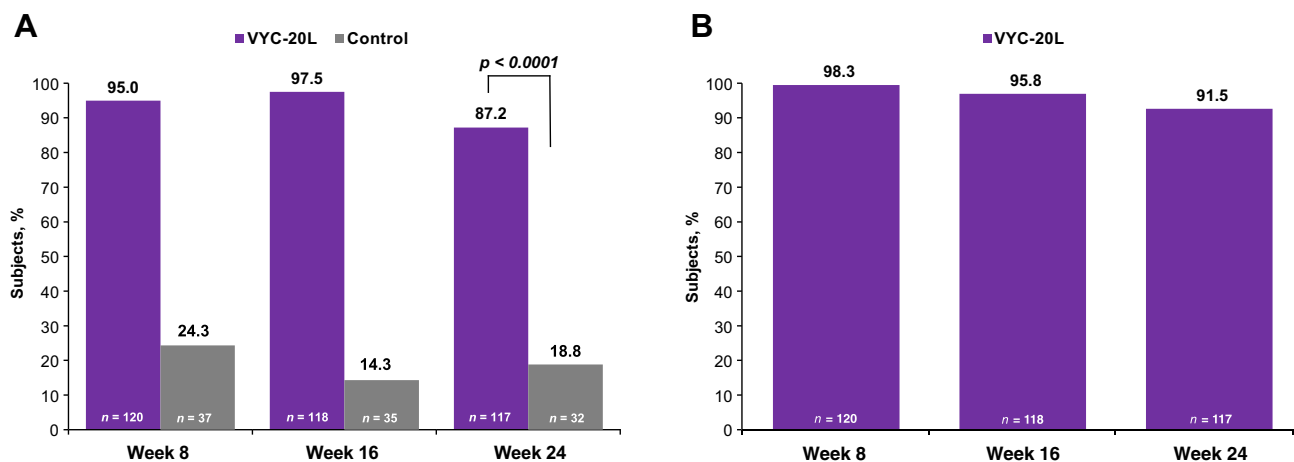


Figure 3 GAIS responder rates. **(A)** EI-assessed GAIS responder rate^a by treatment visit for subjects treated with VYC-20L vs no-treatment control (mITT population). **(B)** Subject-assessed GAIS responder rate by treatment visit for subjects treated with VYC-20L (VYC-20L Initially Treated Population). ^aProportion of subjects with noses rated by the EI or subject as “Improved” or “Much Improved” from baseline. EI, evaluating investigator; GAIS, Global Aesthetic Improvement Scale; mITT, modified intent-to-treat.

period, EI- and subject-assessed GAIS responder rates remained high at weeks 36 (91.3% and 93.0%, respectively) and 48 (89.7% and 89.7%, respectively).

The NSS responder rate was 95.7% at week 24 and was at least 93% at all time points evaluated. Changes from baseline to week 24 in 3D measures in specific nose areas are listed in Table 2. At each time point evaluated, at least 97.5% of subjects in the treatment group and 100% of control group subjects who elected for optional treatment after week 24 responded that they would recommend VYC-20L treatment to a friend. Representative results of VYC-20L treatment for nose augmentation are shown in Figure 4.

Safety

Mean procedural pain ratings of initial and touch-up treatment were 2.7 and 2.1, respectively, in the treatment group and 2.5 and 2.1, respectively, in the control group subjects who elected for optional treatment after week 24. ISRs are summarized in Table 3; most were mild or moderate in severity and resolved within 14 days. All ISRs resolved within 56 days. During the control period, 43 (35.8%) subjects in the treatment group and 17 (45.9%) subjects in the control group had treatment-emergent AEs. The most common ($\geq 5\%$ incidence in the treatment group) were nasopharyngitis (treatment group, 8.3%; control group, 13.5%) and upper respiratory tract infection (treatment group, 6.7%; control group, 5.4%). During the postcontrol period, 54 subjects (45.0%) in the treatment group and 17 subjects (54.8%) in the control group had treatment-emergent AEs. Again, the most common ($\geq 5\%$ incidence in the treatment group) were nasopharyngitis (treatment group, 10.0%; control group, 12.9%) and upper respiratory tract infection (treatment group, 8.3%; control group, 9.7%). No treatment-related AEs, including treatment-related serious AEs, occurred during the control period or the postcontrol period.

Discussion

The results of this study established that injection of VYC-20L, a soft tissue filler, was effective for volume correction of the aesthetic appearance of the nose in Chinese subjects. The primary endpoint was met; compared with the control group, the VYC-20L group showed significant improvements from baseline in nasal area volume measured on 3D digital images at week 24. This finding was also supported by the significant differences achieved with VYC-20L versus control on several secondary endpoints. EIs blinded to treatment and treated subjects reported significant improvements from baseline versus controls in aesthetic appearance on the GAIS. Treated subjects also reported high levels of satisfaction with their treatment on the NSS and showed improvements from baseline in other 3D measures. In addition, the vast majority of treated subjects stated that they would recommend VYC-20L treatment to their friends. Although treatment goals and nose areas varied among subjects, significant improvements were observed with VYC-20L treatment versus

Table 2 Mean Changes from Baseline in Specific Nose Measures at Week 24 Based on 3D Imaging Analysis (mITT Population)

3D Image Measurement, Mean (SD) Change From Baseline	VYC-20L Treatment (n = 116) ^a	Control (n = 35) ^a
Dorsal height, mm	1.51 (0.75)	-0.11 (0.42)
Dorsal width, mm	1.86 (2.00)	0.074 (1.09)
Nasofrontal angle, °	9.38 (4.08)	-0.21 (1.29)
Nasolabial angle, °	1.17 (4.24)	0.60 (3.42)
Nasal root height, mm	2.43 (1.04)	-0.13 (0.30)
Nasal length, mm	1.53 (3.12)	-0.004 (0.75)
Ala depth, mm	0.19 (0.53)	-0.031 (0.40)

Notes: ^aSubjects with analysis values at both baseline and week 24.

Abbreviation: mITT, modified intent-to-treat.

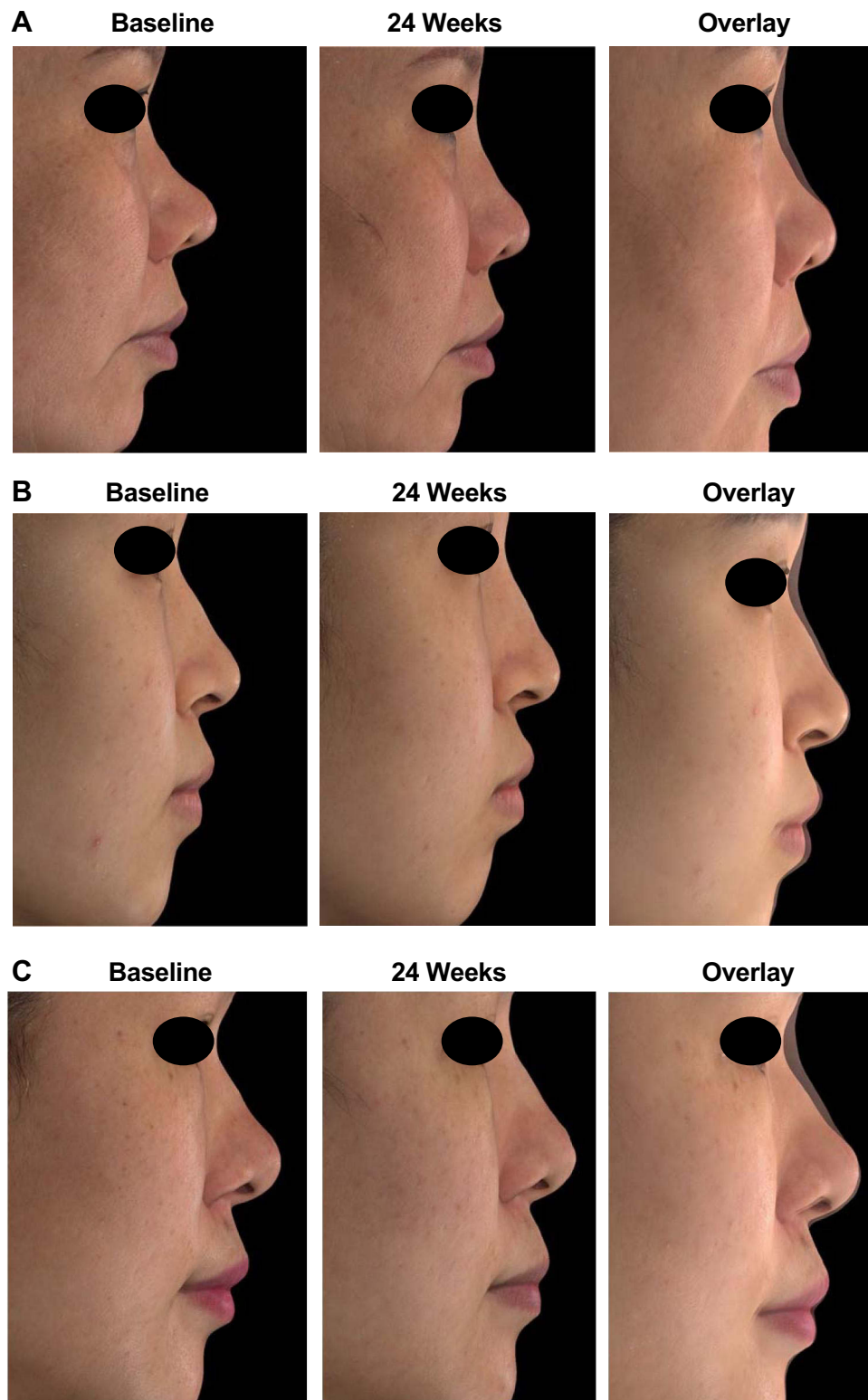


Figure 4 Three representative subjects at baseline and 24 weeks after treatment with VYC-20L, with overlay images of before/after treatment shown (baseline is solid, follow-up is ghosted). **(A)** A 46-year-old female was injected with 1.3 mL of VYC-20L in the nasal dorsum at initial treatment and 0.6 mL of VYC-20L at touch-up treatment. **(B)** A 24-year-old female was injected with 1.0 mL of VYC-20L in the nasal dorsum (0.9 mL) and columella (0.1 mL) at initial treatment, followed by 0.2 mL of VYC-20L in the nasal dorsum at touch-up treatment. **(C)** A 33-year-old female was injected with 1.2 mL of VYC-20L in the nasal dorsum (1.1 mL) and columella (0.1 mL) at initial treatment, followed by 0.6 mL of VYC-20L in the nasal dorsum at touch-up treatment.

Table 3 Injection Site Responses Occurring in Subjects Randomized to Treatment with VYC-20L

	Initial Treatment (n = 119) ^a n (%)	Touch-up Treatment (n = 46) ^a n (%)
Any ISR	109 (91.6)	36 (78.3)
Tenderness to touch	97 (81.5)	27 (58.7)
Pain after injection	92 (77.3)	26 (56.5)
Swelling	85 (71.4)	21 (45.7)
Firmness	76 (63.9)	13 (28.3)
Redness	68 (57.1)	18 (39.1)
Bruising	47 (39.5)	12 (26.1)
Lumps/bumps	39 (32.8)	9 (19.6)
Itching	23 (19.3)	5 (10.9)
Discoloration ^b	15 (12.6)	1 (2.2)

Notes: ^aNumber of subjects with ISR diary entries. ^bNot redness or bruising.

Abbreviation: ISR, injection site response.

control on 3D images and investigator- and patient-reported outcomes. Given that surgical augmentation rhinoplasty is a common procedure performed in Asian subjects dissatisfied with their appearance due to structural features of their nose,¹ the current findings suggest that VYC-20L may offer an attractive and effective alternative for subjects who desire nose augmentation but do not want to undergo the surgery of rhinoplasty.

The results of this study support and extend previous findings of a noncomparative, open-label study that used 2D images and physician- and subject-reported outcome measures to demonstrate the effectiveness of VYC-20L for correction of the nose in 29 Asian subjects over 12 months.⁴ In contrast, the current study was much larger (157 subjects in the mITT population), had a randomized, multicenter design with a 48-week duration of follow-up, and used 3D digital images, as well as physician- and subject-reported outcome measures, for treatment evaluation.

Treatment of the nose area with VYC-20L using a standardized injection procedure had acceptable safety and tolerability profiles. Mean procedural pain ratings were low at both initial and touch-up treatment, which may reflect the effect of the lidocaine component of VYC-20L. Tenderness to touch, pain after injection, and swelling were the most common ISRs, similar to other studies of VYC-20L,^{4,13} and most were mild or moderate in severity. Although no treatment-related AEs or serious AEs were reported in this study, we must emphasize caution when performing soft tissue filler injections in the nose area. The complexity of this area requires that the injections be performed by highly trained, advanced skilled physicians with extensive experience and a thorough understanding of facial anatomy and management of potential severe complications.^{4,13,16} Reported risks that are typically irreversible include tissue necrosis and vision loss/blindness.^{16–20} The VYC-20L directions for use include a warning stating that accidental intravascular injections of soft tissue fillers into the face have resulted in rare serious AEs of vision impairment, blindness, cerebral ischemia, or cerebral hemorrhage, resulting in stroke, skin necrosis, and damage to facial structures. Soft tissue filler injections should not be performed in individuals who have previously experienced trauma to the nose or undergone surgical rhinoplasty (both exclusion criteria of this study) because distortion and scarring may result.²⁰ Soft tissue filler injections are also not recommended for patients with severe saddle nose for whom the estimated required volume needed may be greater than 3 mL for a single treatment, which exceeds the mean volume of 1.18 mL used in this study during initial treatment. Larger volumes of soft tissue filler may potentially lead to product displacement and additional AEs. In addition to appropriate patient selection, a thorough understanding of facial anatomy and standardized injection techniques is important for preventing complications. Injections along the midline minimize the risk of vascular compromise,^{21,22} while injections into the nasal tip (not permitted in this study) may increase the risk of ischemia^{4,22} because the nasal tip has a tight overlying skin envelope.^{23,24}

In conclusion, these results suggest that VYC-20L treatment using a standardized injection procedure is safe and effective for improvement of the volume and aesthetic appearance of the nose in Chinese adults. The mean change in nose area volume from baseline to week 24 was significantly larger with VYC-20L compared with no treatment, treated subjects reported high satisfaction levels, and no unexpected ISRs or treatment-related AEs occurred.

Data Sharing Statement

AbbVie is committed to responsible data sharing regarding the clinical trials we sponsor. This includes access to anonymized, individual and trial-level data (analysis data sets), as well as other information (eg, protocols and Clinical Study Reports), as long as the trials are not part of an ongoing or planned regulatory submission. This includes requests for clinical trial data for unlicensed products and indications.

This clinical trial data can be requested by any qualified researchers who engage in rigorous, independent scientific research, and will be provided following review and approval of a research proposal and Statistical Analysis Plan (SAP) and execution of a Data Sharing Agreement (DSA). Data requests can be submitted at any time and the data will be accessible for 12 months, with possible extensions considered. For more information on the process, or to submit a request, visit the following link: <https://www.abbvie.com/our-science/clinical-trials/clinical-trials-data-and-information-sharing/data-and-information-sharing-with-qualified-researchers.html>.

Acknowledgments

The authors would like to acknowledge the technicians at Canfield Scientific (Fairfield, NJ) for imaging support.

Author Contributions

Study design: Dong Li, Jiaming Sun, Yuguang Zhang, Xiaojun Wang, and Songlin Yang. Study investigator: Dong Li, Jiaming Sun, Yuguang Zhang, Xiaojun Wang, and Songlin Yang. Enrolled patients: Dong Li, Jiaming Sun, Yuguang Zhang, Xiaojun Wang, and Songlin Yang. Collection and assembly of data: Dong Li, Jiaming Sun, Yuguang Zhang, Xiaojun Wang, and Songlin Yang. All authors made a significant contribution to the work reported, whether that is in the conception, study design, execution, acquisition of data, analysis and interpretation, or in all these areas; took part in drafting, revising or critically reviewing the article; gave final approval of the version to be published; have agreed on the journal to which the article has been submitted; and agree to be accountable for all aspects of the work.

Funding

This study was sponsored by Allergan Aesthetics, an AbbVie company. Writing and editorial assistance was provided to the authors by Maria Lim, PhD of Peloton Advantage, LLC, an OPEN Health company, Parsippany, NJ, and was funded by Allergan Aesthetics. Neither honoraria nor other form of payment was made for authorship.

Disclosure

Candice Harvey and Lijuan Zhang are employees of Allergan Aesthetics, an AbbVie Company, and may own stock. The authors report no other conflicts of interest in this work.

References

1. Jang YJ, Yi JS. Perspectives in Asian rhinoplasty. *Facial Plast Surg*. 2014;30:123–130. doi:10.1055/s-0034-1371899
2. Kim P, Ahn JT. Structured nonsurgical Asian rhinoplasty. *Aesthetic Plast Surg*. 2012;36:698–703. doi:10.1007/s00266-012-9869-2
3. Wu WT, Liew S, Chan HH, et al. Consensus on current injectable treatment strategies in the Asian face. *Aesthetic Plast Surg*. 2016;40:202–214. doi:10.1007/s00266-016-0608-y
4. Liew S, Scamp T, de Maio M, et al. Efficacy and safety of a hyaluronic acid filler to correct aesthetically detracting or deficient features of the Asian nose: a prospective, open-label, long-term study. *Aesthet Surg J*. 2016;36:760–772. doi:10.1093/asj/sjw079
5. Bhangoo KS. Aesthetic rhinoplasty: avoiding unfavourable results. *Indian J Plast Surg*. 2013;46:349–358. doi:10.4103/0970-0358.118613
6. Surowitz JB, Most SP. Complications of rhinoplasty. *Facial Plast Surg Clin North Am*. 2013;21:639–651. doi:10.1016/j.fsc.2013.07.003
7. Bray D, Hopkins C, Roberts DN. Injection rhinoplasty: non-surgical nasal augmentation and correction of post-rhinoplasty contour asymmetries with hyaluronic acid: how we do it. *Clin Otolaryngol*. 2010;35:227–230. doi:10.1111/j.1749-4486.2010.02125.x

8. Ferril GR, Wudel JM, Winkler AA. Management of complications from alloplastic implants in rhinoplasty. *Curr Opin Otolaryngol Head Neck Surg.* 2013;21:372–378. doi:10.1097/MOO.0b013e3283628e40
9. Redaelli A. Medical rhinoplasty with hyaluronic acid and botulinum toxin A: a very simple and quite effective technique. *J Cosmet Dermatol.* 2008;7:210–220. doi:10.1111/j.1473-2165.2008.00391.x
10. Solomon P, Sklar M, Zener R. Facial soft tissue augmentation with Artecoll[®]): a review of eight years of clinical experience in 153 patients. *Can J Plast Surg.* 2012;20:28–32. doi:10.1177/229255031202000110
11. Tanaka Y, Matsuo K, Yuzuriha S. Westernization of the asian nose by augmentation of the repositioned anterior nasal spine with an injectable filler. *Eplasty.* 2011;11:e7.
12. Xue K, Chiang CA, Liu K, Gu B, Li Q. Multiplane hyaluronic acid rhinoplasty. *Plast Reconstr Surg.* 2012;129:371e–372e. doi:10.1097/PRS.0b013e31823af0bd
13. Jones D, Murphy DK. Volumizing hyaluronic acid filler for midface volume deficit: 2-year results from a pivotal single-blind randomized controlled study. *Dermatol Surg.* 2013;39:1602–1611.
14. Callan P, Goodman GJ, Carlisle I, et al. Efficacy and safety of a hyaluronic acid filler in subjects treated for correction of midface volume deficiency: a 24 month study. *Clin Cosmet Investig Dermatol.* 2013;6:81–89. doi:10.2147/CCID.S40581
15. Bae JM, Lee DW. Three-dimensional remodeling of young Asian women's faces using 20-mg/mL smooth, highly cohesive, viscous hyaluronic acid fillers: a retrospective study of 320 patients. *Dermatol Surg.* 2013;39:1370–1375. doi:10.1111/dsu.12239
16. de Maio M, Codes[™]: MD. a methodological approach to facial aesthetic treatment with injectable hyaluronic acid fillers. *Aesthetic Plast Surg.* 2021;45:690–709. doi:10.1007/s00266-020-01762-7
17. Carle MV, Roe R, Novack R, Boyer DS. Cosmetic facial fillers and severe vision loss. *JAMA Ophthalmol.* 2014;132:637–639. doi:10.1001/jamaophthalmol.2014.498
18. Park KH, Kim YK, Woo SJ, et al. Iatrogenic occlusion of the ophthalmic artery after cosmetic facial filler injections: a national survey by the Korean Retina Society. *JAMA Ophthalmol.* 2014;132:714–723. doi:10.1001/jamaophthalmol.2013.8204
19. Park SW, Woo SJ, Park KH, Huh JW, Jung C, Kwon OK. Iatrogenic retinal artery occlusion caused by cosmetic facial filler injections. *Am J Ophthalmol.* 2012;154:653–662.e651. doi:10.1016/j.ajo.2012.04.019
20. Grunebaum LD, Bogdan Allemann I, Dayan S, Mandy S, Baumann L. The risk of alar necrosis associated with dermal filler injection. *Dermatol Surg.* 2009;35(Suppl 2):1635–1640. doi:10.1111/j.1524-4725.2009.01342.x
21. Rohrich RJ, Agrawal N, Avashia Y, Savetsky IL. Safety in the use of fillers in nasal augmentation-the liquid rhinoplasty. *Plast Reconstr Surg Glob Open.* 2020;8:e2820. doi:10.1097/GOX.0000000000002820
22. Humphrey CD, Arkins JP, Dayan SH. Soft tissue fillers in the nose. *Aesthet Surg J.* 2009;29:477–484. doi:10.1016/j.asj.2009.09.002
23. Sun ZS, Zhu GZ, Wang HB, et al. Clinical outcomes of impending nasal skin necrosis related to nose and nasolabial fold augmentation with hyaluronic acid fillers. *Plast Reconstr Surg.* 2015;136:434e–441e. doi:10.1097/PRS.0000000000001579
24. Burget GC. Aesthetic reconstruction of the tip of the nose. *Dermatol Surg.* 1995;21:419–429. doi:10.1111/j.1524-4725.1995.tb00209.x

Clinical, Cosmetic and Investigational Dermatology

Dovepress

Publish your work in this journal

Clinical, Cosmetic and Investigational Dermatology is an international, peer-reviewed, open access, online journal that focuses on the latest clinical and experimental research in all aspects of skin disease and cosmetic interventions. This journal is indexed on CAS. The manuscript management system is completely online and includes a very quick and fair peer-review system, which is all easy to use. Visit <http://www.dovepress.com/testimonials.php> to read real quotes from published authors.

Submit your manuscript here: <https://www.dovepress.com/clinical-cosmetic-and-investigational-dermatology-journal>