

# Subretinal recombinant tissue plasminogen activator and pneumatic displacement for the management of subretinal hemorrhage occurring after anti-VEGF injections for wet AMD

Daniele Tognetto  
Eirini Skiadaresi  
Paolo Cecchini  
Giuseppe Ravalico

Eye Clinic, University of Trieste,  
Trieste, Italy

**Abstract:** We describe three cases of submacular hemorrhage that occurred two to four days after anti-VEGF intravitreal injection for occult choroidal neovascularisation in age-related macular degeneration and their management with 25 gauge pars plana vitrectomy with injection of subretinal recombinant tissue plasminogen activator (rTPA) followed by fluid-air exchange and postoperative prone position. Vitrectomy, subretinal rTPA injection and fluid-gas exchange apply as a safe and effective treatment in these cases. Functional results seem to be positive especially if surgical treatment is promptly performed.

**Keywords:** vitrectomy, rTPA subretinal injection, gas tamponade, blood displacement

## Introduction

We describe three cases of submacular hemorrhage (SMH) that occurred two to four days after anti-vascular endothelial growth factor (anti-VEGF) intravitreal injection for occult choroidal neovascularisation (CNV) in age related macular degeneration<sup>1</sup> (AMD) and their management.

## Methods

Almost 2500 anti-VEGF intravitreal injections for neovascular AMD were performed in our Department between January 2007 and December 2009. Three patients developed an acute SMH after the injection involving most of the macular region. Fundus fluorescein angiography (FFA), indocyanine green angiography (ICGA) and optical coherence tomography (OCT) were carried out. After diagnosis, patients underwent 25 gauge pars plana vitrectomy with posterior hyaloid removal. An injection of 0.2 mL of subretinal recombinant tissue plasminogen activator (rTPA) (125 µg/mL) through a 41-gauge flexible translocation microcannula (DORC-dual bore BSS injection needle 0.1 mm tip) followed.<sup>2</sup> The rTPA was injected inferiorly to the SMH in order to create a bullous retinal detachment encompassing the entire blood clot. Finally a fluid-air exchange was performed and patients maintained a supine position for 45 minutes followed by a postoperative prone position.

## Case I

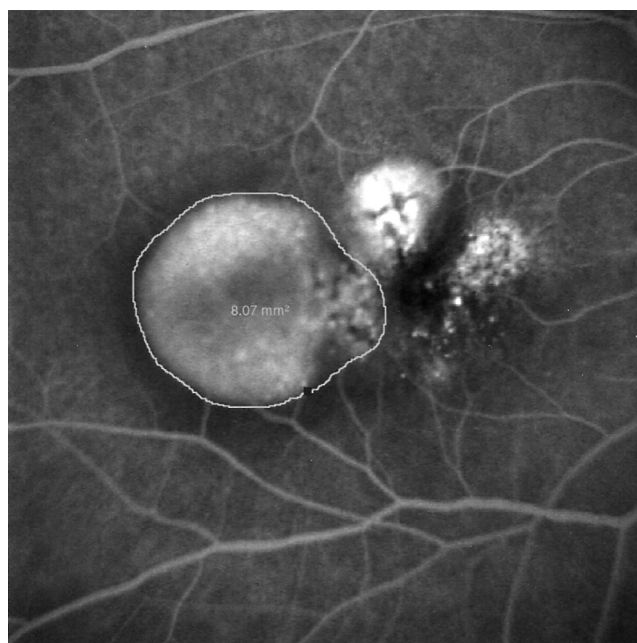
In January 2008, a 67-year old woman with 20/20 visual acuity and metamorphopsia in her right eye (RE) had been treated for seven months with an injection of ranibizumab

Correspondence: Daniele Tognetto  
Istituto di Clinica Oculistica, Università  
di Trieste, Ospedale Maggiore Piazza  
Ospedale I, 34129 Trieste, Italy  
Phone +39 040 772449  
Fax +39 040 772449  
Email tognetto@univ.trieste.it

each month for an occult CNV. The FFA performed at that time demonstrated, in the RE, a paramacular pigment epithelial detachment of 8.07 mm<sup>2</sup> and a serous neuroepithelial detachment involving the fovea (Figure 1). Four days after the 8th intravitreal anti-VEGF injection a SRH developed and the visual acuity dropped to light perception. The patient underwent surgical treatment the day after the appearance of the hemorrhage. No intraoperative or postoperative complications occurred. A complete displacement of submacular hemorrhage from the fovea was obtained. Visual acuity one month after treatment rose to 20/63 with metamorphopsia. The patient had four further intravitreal injections of bevacizumab between May 2008 and August 2008. Significant cataract developed which required extraction in August 2008. One year following cataract surgery the patient's visual acuity was stable at 20/63.

## Case 2

An 84-year old woman, affected by cardiac arrhythmia treated with amiodarone, presented in January 2008 complaining of metamorphopsia in her RE. An occult CNV due to AMD was identified and she underwent three intravitreal bevacizumab injections in the RE. In April 2008 her visual acuity was 20/125 in the RE and 20/63 in the left eye (LE), and the FFA and ICGA demonstrated an occult choroidal neovascularisation of 18.55 mm<sup>2</sup> in the LE. Two days after the first intravitreal injection of bevacizumab, she developed a thick SMH and her visual acuity decreased to hand motion. Two days after



**Figure 1** Fundus fluorescein angiography of case 1. The DEP area is measured in mm<sup>2</sup>.

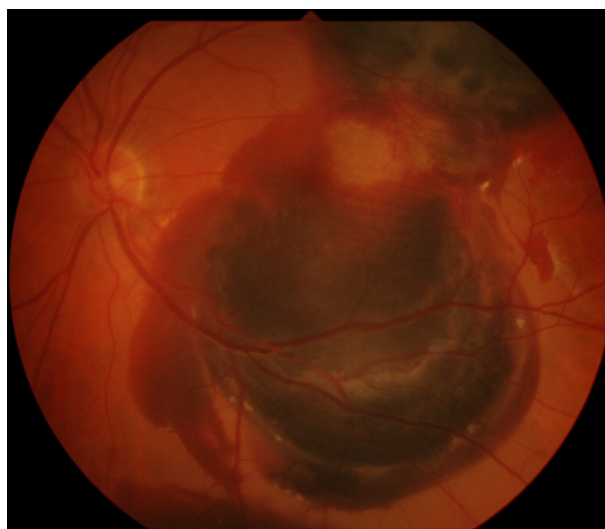
the hemorrhage occurred, she underwent surgical treatment. No intra or postoperative complications were observed. Four days after surgery the hemorrhage was displaced from the fovea. The visual acuity in the LE one month after treatment was 20/160 with metamorphopsia. Two months after surgery she underwent another bevacizumab injection in the LE. Her visual acuity remained 20/160 for the following year.

## Case 3

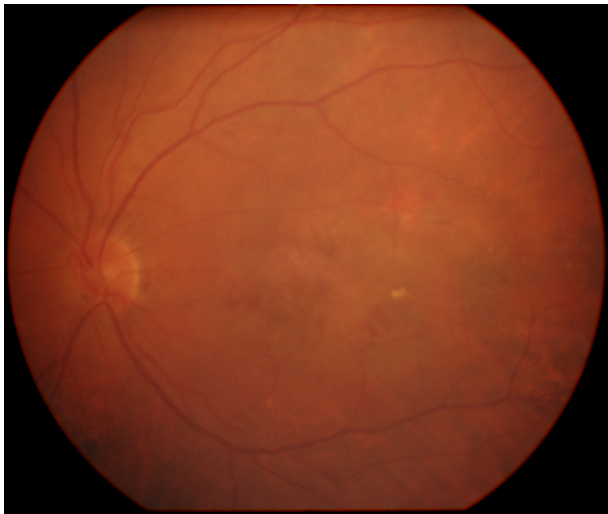In June 2007 a 72-year old woman, who had already undergone in her RE four ranibizumab injections for a wet AMD, started complaining of metamorphopsia in her LE with a visual acuity of 20/20. FFA and ICGA demonstrated a lesion area of 4.15 mm<sup>2</sup> due to occult CNV. A ranibizumab intravitreal injection was carried out in her LE and two days after a SMH occurred (Figure 2). The visual acuity in the LE dropped to counting fingers. Two days later she underwent surgical treatment. No intraoperative complications were noticed. Four days after treatment an almost complete displacement of the hemorrhage was achieved. Visual acuity was 20/160 one month after surgery and she underwent another ranibizumab injection. One year after surgery (Figure 3) her visual acuity was unmodified and no other treatment was performed.

## Discussion

Submacular hemorrhage is not a rare complication during the natural history of occult neovascularisation in AMD. It has been reported that it occurs in 17.0% of AMD cases with the presence of retinal pigment epithelial detachment (PED).<sup>3</sup> This complication has been also described after photodynamic therapy especially in cases of AMD with PED.<sup>4-9</sup> In our



**Figure 2** Submacular hemorrhage of case 3 pre-treatment.



**Figure 3** Submacular hemorrhage of case 3 post treatment.

cases only in one of the three patients was a PED present before the treatment (case 1). In that case the area involving the PED was 8.07 mm<sup>2</sup> (Figure 1).

Recently a few studies have described the occurrence of large submacular hemorrhages after the intravitreal injection both of bevacizumab and ranibizumab. Karagiannis has hypothesized that this event might also be due to changing from bevacizumab to ranibizumab.<sup>10</sup> In the cases that we report, only one kind of anti-VEGF was injected in each patient before the occurrence of the hemorrhage.

The mechanism of submacular hemorrhage in these cases remains unknown, but it has been hypothesized that the contraction of the neovascular membrane could lead to new vessels rupturing, especially in large lesions.<sup>11,12</sup> In addition, a reduction of tight junctions in retinal pigment epithelial and endothelial cells related to the decrease in VEGF availability could promote the vessel rupture,<sup>13</sup> even though recently Peng et al have demonstrated that permeability and selectivity of the junctions are not affected by VEGF, bevacizumab or ranibizumab.<sup>14</sup>

Vascular endothelial growth factor regulates crucial processes, such as embryo- and organogenesis as well as immune system, endocrinology, hematopoiesis, (lymphoid) vessel architecture and reparative processes in adults.<sup>15,16</sup> It might be therefore expected that its inhibition could cause multiple adverse effects. Although the intravitreal administration of smaller doses can drastically reduce systemic exposure, and current and past clinical trials do not provide sufficient statistical power when evaluating whether systemic events significantly differ between the treatment and control groups,<sup>17–21</sup> possible local side effects on retinal

perfusion and survival of neuronal tissue must be taken into consideration.<sup>22</sup>

Goverdhan and Lochhead<sup>1</sup> has described four cases of submacular hemorrhage after intravitreal bevacizumab all occurring in large neovascular lesions and the same finding was described by Baeteman et al reporting six cases of submacular hemorrhage after ranibizumab injection.<sup>23</sup> In these series the hemorrhages developed at a median of 14 to 25 days after the anti-VEGF injection, while in our cases the median was 2.6 days.

Moreover it is interesting to note that the patient described in our third case developed a large subretinal hemorrhage after the injection but the initial lesion was relatively small and no PED was noticed.

The occurrence of submacular hemorrhage has been also related to anticoagulant therapy and to increased blood pressure.<sup>24–26</sup> In our series no patients had history of systemic hypertension or anticoagulant treatment.

The toxicity of subretinal blood to the neurosensory retina has been demonstrated in clinical studies<sup>27</sup> and in animal models.<sup>28</sup> Possible mechanisms of blood-induced retinotoxicity include mechanical effects such as fibrotic shearing of photoreceptors, hypoxia, and metabolic disruption imposed by the clot as a diffusion barrier. Direct neurotoxicity seems to be induced by the migration of blood components, such as iron, to the photoreceptor layer.<sup>29</sup>

The management of submacular hemorrhage has evolved greatly during the past 15 years. A variety of therapeutic approaches have been developed, all with the common goal of clearing the submacular blood to minimize permanent damage to the photoreceptors and retinal pigment epithelium. Many options have been proposed including intravitreal gas injection;<sup>30,31</sup> pars plana vitrectomy and submacular surgery, both with and without the assistance of rTPA;<sup>32–38</sup> intravitreal injection of gas and pneumatic displacement of the submacular hemorrhage with associated intravitreal injection of rTPA;<sup>39–41</sup> pars plana vitrectomy; subretinal injection of r-TPA and fluid gas exchange;<sup>42</sup> pars plana vitrectomy and subretinal rTPA injection, followed by evacuation of the liquefied blood through a 500 µm retinotomy with the aid of perfluorocarbon compression of the overlying retina;<sup>43</sup> intravitreal anti-VEGF;<sup>44</sup> combined rTPA, expansile gas and bevacizumab;<sup>45</sup> and co-application of rTPA and bevacizumab.<sup>46</sup> Many procedures include the use of rTPA. Subretinal rTPA has recently been demonstrated to achieve best anatomical results than intravitreal rTPA.<sup>47</sup>

Patients with subretinal hemorrhages secondary to AMD are psychologically distressed as a result of acute loss of

vision.<sup>48</sup> In our series subretinal r-TPA injection followed by gas tamponade allowed the displacement of the hemorrhage in all the three cases enabling the follow-up and the further treatment of the AMD. No intraoperative or postoperative complications were noted.

In conclusion, large subretinal hemorrhage is a possible complication of intravitreal anti-VEGF treatment in AMD and it may occur days or weeks after the injection. Further studies are required for the complete comprehension of the mechanism of the pathogenesis.

The surgical approach with vitrectomy, subretinal rTPA injection and fluid-gas exchange is a safe and effective treatment. Functional results seem to be positive, especially if surgical treatment is promptly performed.

## Disclosure

The authors report no conflicts of interest in the work.

## References

- Goverdhan SV, Lochhead J. Submacular hemorrhages after intravitreal bevacizumab for large occult choroidal neovascularisation in age-related macular degeneration. *Br J Ophthalmol*. 2008;92:210–212.
- Olivier S, Chow DR, Packo KH, MacCumber MW, Awh CC. Subretinal recombinant tissue plasminogen activator injection and pneumatic displacement of thick submacular hemorrhage in Age-Related macular degeneration. *Ophthalmology*. 2004;111:1201–1208. Erratum in: *Ophthalmology*. 2004;111:1640.
- Poliner LS, Olk RJ, Burgess D, Gordon ME. Natural history of retinal pigment epithelial detachments in age-related macular degeneration. *Ophthalmology*. 1986;93:543–551.
- Theodossiadis GP, Panagiotidis D, Georgalas IG, Moschos M, Theodossiadis PG. Retinal hemorrhage after photodynamic therapy in patients with subfoveal choroidal neovascularization caused by age-related macular degeneration. *Graefes Arch Clin Exp Ophthalmol*. 2003;241:13–18.
- Arnold JJ, Blinder KJ, Bressler NM, et al. Acute severe visual acuity decrease after photodynamic therapy with verteporfin: case reports from randomized clinical trials TAP and VIP report no. 3. *Am J Ophthalmol*. 2004;137:683–696.
- Gelissen F, Inhoffen W, Karim-Zoda K, et al. Subfoveal hemorrhage after verteporfin photodynamic therapy in treatment of choroidal neovascularization. *Graefes Arch Clin Exp Ophthalmol*. 2005;243:198–203.
- Do DV, Bressler NM, Bressler SB. Large submacular hemorrhages after verteporfin therapy. *Am J Ophthalmol*. 2004;137:558–560.
- Chaudhry NA, Lavaque AJ, Tom DE, Liggett PE. Large submacular hemorrhage following PDT with verteporfin in patients with occult CNVM secondary to age-related macular degeneration. *Ophthalmic Surg Lasers Imaging*. 2007;38:64–68.
- Matsushita S, Naito T, Takebayashi M, Sato H, Shiota H. The prognosis of cases with massive subretinal hemorrhage after photodynamic therapy. *J Med Invest*. 2008;55:231–235.
- Karagiannis DA, Ladas ID, Parikakis E, et al. Changing from bevacizumab to ranibizumab in age-related macular degeneration. Is it safe? *Clin Interv Aging*. 2009;4:457–461.
- Honda S, Hirabayashi H, Tsukahara Y, Negi A. Acute contraction of the proliferative membrane after an intravitreal injection of bevacizumab for advanced retinopathy of prematurity. *Graefes Arch Clin Exp Ophthalmol*. 2008;246:1061–1063.
- Gibran SK, Sachdev A, Stappeler T, Newsome R, Wong D, Hiscott P. Histological findings of a choroidal neovascular membrane removed at the time of macular translocation in a patient previously treated with intravitreal bevacizumab treatment (Avastin). *Br J Ophthalmol*. 2007;91:602–604.
- Ghassemifar R, Lai CM, Rakoczy PE. VEGF differentially regulates transcription and translation of ZO-1alpha+ and ZO-1alpha- and mediates trans-epithelial resistance in cultured endothelial and epithelial cells. *Cell Tissue Res*. 2005;323:117–125.
- Peng S, Adelman RA, Rizzolo LJ. Minimal effects of VEGF and anti-VEGF drugs on the permeability or selectivity of RPE tight junctions. *Invest Ophthalmol Vis Sci*. 2010;51:3216–3225.
- Lohela M, Bry M, Tammela T, Alitalo K. VEGFs and receptors involved in angiogenesis versus lymphangiogenesis. *Curr Opin Cell Biol*. 2009;21:154–165.
- Ziemssen F, Heiduschka P, Peters S, Grisanti S, Schraermeyer U. Chances and risks of anti-VEGF therapy. *Klin Monbl Augenheilkd*. 2008;225:770–778.
- Schmidt-Erfurth U. Clinical safety of ranibizumab in age-related macular degeneration. *Expert Opin Drug Saf*. 2010;9:149–165.
- Rosenfeld PJ, Brown DM, Heier JS, et al. Ranibizumab for neovascular age-related macular degeneration. *N Engl J Med*. 2006;355:1419–1431.
- Brown DM, Michels M, Kaiser PK, Heier JS, Sy JP, Ianchulev T; ANCHOR Study Group. Ranibizumab versus verteporfin photodynamic therapy for neovascular age-related macular degeneration: Two-year results of the ANCHOR study. *Ophthalmology*. 2009;116:57–65.
- Schmidt-Erfurth U. Clinical safety of ranibizumab in age-related macular degeneration. *Expert Opin Drug Saf*. 2010;9(1):149–165.
- Boyer DS, Heier JS, Brown DM, Francom SF, Ianchulev T, Rubio RG. A Phase IIIb study to evaluate the safety of ranibizumab in subjects with neovascular age-related macular degeneration. *Ophthalmology*. 2009;116:1731–1739.
- Ziemssen F, Bartz-Schmidt KU, Grisanti S. (Side) effects of VEGF inhibition. *Ophthalmologie*. 2006;103:484–492.
- Baeteman C, Hoffart L, Galland F, Ridings B, Conrath J. Subretinal hemorrhage after intravitreal injection of anti-VEGF for age-related macular degeneration: a retrospective study. *J Fr Ophtalmol*. 2009;32:309–313.
- Tilanus MA, Vaandrager W, Cuypers MH, Verbeek AM, Hoyng CB. Relationship between anticoagulant medication and massive intraocular hemorrhage in age-related macular degeneration. *Graefes Arch Clin Exp Ophthalmol*. 2000;238:482–485.
- Kiernan DF, Hariprasad SM, Rusu IM, Mehta SV, Mieler WF, Jager RD. Epidemiology of the association between anticoagulants and intraocular hemorrhage in patients with neovascular age-related macular degeneration. *Retina*. 2010;30:1573–1578.
- Iguchi Y, Ito Y, Kikuchi M, et al. Seasonal variations of acute massive submacular hemorrhage associated with age-related macular degeneration. *Br J Ophthalmol*. 2006;90:1256–1258.
- Grossniklaus HE, Wilson DJ, Bressler SB, et al. Clinicopathologic studies of eyes that were obtained postmortem from four patients who were enrolled in the submacular surgery trials: SST Report No. 16. *Am J Ophthalmol*. 2006;141:93–104.
- Glatt H, Machemer R. Experimental subretinal hemorrhage in rabbits. *Am J Ophthalmol*. 1982;94:762–773.
- Bhisitkul RB, Winn BJ, Lee OT, et al. Neuroprotective effect of intravitreal triamcinolone acetonide against photoreceptor apoptosis in a rabbit model of subretinal hemorrhage. *Invest Ophthalmol Vis Sci*. 2008;49(9):4071–4077.
- Daneshvar H, Kertes PJ, Leonard BC, Peyman GA. Management of submacular hemorrhage with intravitreal sulfurhexafluoride: a pilot study. *Can J Ophthalmol*. 1999;34:385–388.
- Ohji M, Saito Y, Hayashi A, Lewis JM, Tano Y. Pneumatic displacement of subretinal hemorrhage without tissue plasminogen activator. *Arch Ophthalmol*. 1998;116:1326–1332.

32. Peyman GA, Nelson NC Jr, Alturki W, et al. Tissue plasminogen activating factor assisted removal of subretinal hemorrhage. *Ophthalmic Surg.* 1991;22:575–582.
33. Lim JL, Drews-Botsch C, Sternberg P, Capone A, Aaberg TM. Submacular hemorrhage removal. *Ophthalmology.* 1995;102:1393–1399.
34. Scheider A, Gundisch O, Kampik A. Surgical extraction of subfoveal choroidal new vessels and submacular hemorrhage in age-related macular degeneration: results of a prospective study. *Graefes Arch Clin Exp Ophthalmol.* 1999;237:10–15.
35. Lewis H. Intraoperative fibrinolysis of submacular hemorrhage with tissue plasminogen activator and surgical drainage. *Am J Ophthalmol.* 1994;118:559–568.
36. Yang PM, Kuo HK, Kao ML, Chen YJ, Tsai HH. Pneumatic displacement of a dense submacular hemorrhage with or without tissue plasminogen activator. *Chang Gung Med J.* 2005;28(12):852–859.
37. Thompson JT, Sjaarda RN. Vitrectomy for the treatment of submacular hemorrhages from macular degeneration: a comparison of submacular hemorrhage/membrane removal and submacular tissue plasminogen activator-assisted pneumatic displacement. *Trans Am Ophthalmol Soc.* 2005;103:98–107; discussion 107.
38. Kamei M, Tano Y. Tissue plasminogen activator-assisted vitrectomy: surgical drainage of submacular hemorrhage. *Dev Ophthalmol.* 2009;44:82–88.
39. Hassan AS, Johnson MW, Schneiderman TE, et al. Management of submacular hemorrhage with intravitreal tissue plasminogen activator injection and pneumatic displacement. *Ophthalmology.* 1999;106:1900–1906.
40. Ratanasukon M, Kittantong A. Results of intravitreal tissue plasminogen activator and expansile gas injection for submacular hemorrhage in Thais. *Eye (Lond).* 2005;19:1328–1332.
41. Chen CY, Hooper C, Chiu D, Chamberlain M, Karia N, Heriot WJ. Management of submacular hemorrhage with intravitreal injection of tissue plasminogen activator and expansile gas. *Retina.* 2007;27:321–328.
42. Hauptert CL, McCuen BW, Jaffe GJ, et al. Pars plana vitrectomy, subretinal injection of tissue plasminogen activator, and fluid-gas exchange for displacement of thick submacular hemorrhage in age-related macular degeneration. *Am J Ophthalmol.* 2001;131:208–215.
43. Kamei M, Tano Y, Maeno T, Ikuno Y, Mitsuda H, Yuasa T. Surgical removal of submacular hemorrhage using tissue plasminogen activator and perfluorocarbon liquid. *Am J Ophthalmol.* 1996;121:267–275.
44. Stifter E, Michels S, Prager F, et al. Intravitreal bevacizumab therapy for neovascular age-related macular degeneration with large submacular hemorrhage. *Am J Ophthalmol.* 2007;144:886–892.
45. Meyer CH, Scholl HP, Eter N, Helb HM, Holz FG. Combined treatment of acute subretinal hemorrhages with intravitreal recombinant tissue plasminogen activator, expansile gas and bevacizumab: a retrospective pilot study. *Acta Ophthalmol.* 2008;86:490–494.
46. Treumer F, Klatt C, Roider J, Hillenkamp J. Subretinal co-application of recombinant tissue plasminogen activator and bevacizumab for neovascular age-related macular degeneration with submacular hemorrhage. *Br J Ophthalmol.* 2010;94:48–53.
47. Hillenkamp J, Surguch V, Framme C, Gabel VP, Sachs HG. Management of submacular hemorrhage with intravitreal versus subretinal injection of recombinant tissue plasminogen activator. *Graefes Arch Clin Exp Ophthalmol.* 2010;248:5–11.
48. Mozaffarieh M, Sacu S, Benesch T, Wedrich A. Subretinal hemorrhages secondary to age-related macular degeneration: psychological and vision-related functional perspectives. *Ophthalmologica.* 2008;222:199–204.

## Clinical Ophthalmology

### Publish your work in this journal

Clinical Ophthalmology is an international, peer-reviewed journal covering all subspecialties within ophthalmology. Key topics include: Optometry; Visual science; Pharmacology and drug therapy in eye diseases; Basic Sciences; Primary and Secondary eye care; Patient Safety and Quality of Care Improvements. This journal is indexed on

Submit your manuscript here: <http://www.dovepress.com/clinical-ophthalmology-journal>

Dovepress

PubMed Central and CAS, and is the official journal of The Society of Clinical Ophthalmology (SCO). The manuscript management system is completely online and includes a very quick and fair peer-review system, which is all easy to use. Visit <http://www.dovepress.com/testimonials.php> to read real quotes from published authors.