

Case of retinal detachment due to retinal break splitting macula vertically in a patient with cognitive disorder

Takayuki Baba
Tomoaki Tatsumi
Toshiyuki Oshitari
Shuichi Yamamoto

Department of Ophthalmology
and Visual Science, Chiba University
Graduate School of Medicine,
Chiba, Japan

Abstract: We report a patient with cognitive disorder who had a rhegmatogenous retinal detachment (RRD). A 17-year-old Japanese man presented with a RRD with a vitreous hemorrhage in his right eye. An unusual vertical splitting of the macula accompanied by a giant retinal tear was observed intraoperatively. The retina was successfully reattached by pars plana vitrectomy with silicone oil tamponade and scleral buckling. Visual function appeared to have improved from the behavior of the patient. Although the precise mechanism causing the break which split the macula was not determined, self-inflicted blunt trauma to the eye was suspected.

Keywords: macular break, cognitive disorder, retinal detachment

Introduction

Fifty-nine percent of patients with cognitive disorders have been reported to have ocular diseases, and about 2% of these patients have a rhegmatogenous retinal detachment (RRD).¹ The main cause for the RRDs is self-inflicted injuries leading to a high incidence of traumatic retinal breaks. The RRD in these patients is easily missed because these patients do not usually complain of visual symptoms. A delay in finding a RRD is not good because the RRD can progress to proliferative vitreoretinopathy (PVR), and the visual prognosis of PVR is poor even after multiple vitreoretinal surgeries. The detection of a RRD at an early stage has a better visual prognosis.²

In traumatic RRD cases, typical retinal breaks are caused by oral dialysis at the border of the vitreous base or necrotic breaks located at the equator.³ We present an unusual case of RRD caused by a large retinal break that split the macula in half vertically.

Case report

A 17-year-old Japanese man presented with a RRD and vitreous hemorrhage in his right eye. The left eye was completely normal including the macula with normal central foveal reflex. He was mentally retarded because of hydrocephalus noted soon after birth, and we had difficulty in communicating with him. His mother had recently noticed that he had been hitting his right eye with his fist frequently. Ophthalmological examination showed a retinal detachment, and the patient was referred to Chiba University Hospital for surgical treatment. At the first examination, his visual acuity could not be determined because of his mental retardation. The axial length of the affected eye was approximately 24.5 mm based on B-mode echography. The patient's refractive error was -3.5 diopters in the uninjured eye and

Correspondence: Takayuki Baba
Department of Ophthalmology
and Visual Science, Chiba University
Graduate School of Medicine,
1-8-1 Inohana, Chuo-ku, Chiba
260-0856, Japan
Tel +81 43 226 2124
Fax +81 43 224 4162
Email babatakayuki@nifty.com

not measurable in the affected eye. There was a posterior subcapsular cataract but no sign of a foreign body in his right eye. Even though the fundus visibility was limited by vitreous hemorrhage, a RRD with multiple retinal breaks could be seen in his right eye.

The patient underwent lensectomy and pars plana vitrectomy under general anesthesia. During the vitrectomy, the macular break was found to be a vertical split of the retina through the fovea (Figure 1, left). Xanthophyll pigments were seen at the lateral edges of the retinal break indicating that this was where the macula was split in half. A massive subretinal hemorrhage was also observed which was removed through the retinal break. In addition to the retinal break, there was a giant retinal tear at the temporal retina of about 90° in length (Figure 1, right). The posterior vitreous was already separated from the retina, and no pre- or subretinal proliferative membrane was observed.

Peripheral vitrectomy was performed with scleral depression and photocoagulation followed by fluid-air exchange. Because the vitreous hemorrhage and rolled edge of the retinal breaks suggested that a PVR might develop, and because of the difficulty of maintaining a face-down position and the possibility of further self injury, a 7 mm wide encircling silicone buckle was placed, and the eye was filled with silicone oil.

Postoperatively, the retina was reattached, and his mother reported that the frequency of self-inflicted trauma to his right eye decreased markedly. This decrease suggested some degree of recovery of visual function in his right eye. Electroretinograms were not performed even under general anesthesia because we could not obtain the parents' consent. The silicone oil was removed six months after the surgery, and the retina was observed to be still attached (Figure 2).

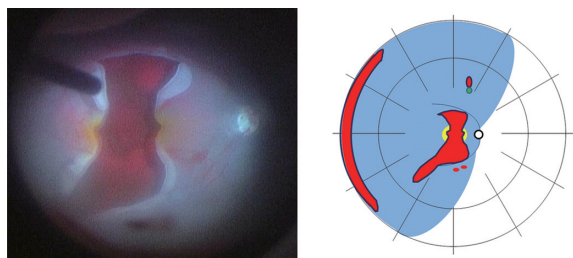


Figure 1 Fundus photograph and drawing of the fundus of a patient with a large macular splitting tear. **Left:** Fundus photograph showing a large macular break splitting the macula vertically. The edge of the break is rolled over, and the subretinal hemorrhage covers the retinal pigment epithelium over the macula. Note that macular xanthophyll pigment can be seen at both lateral edges of the retinal break. **Right:** Schematic drawing of the fundus showing the retinal detachment in the right eye. Multiple retinal breaks including a macular split are shown. A retinal break with an operculum can be seen at the 12:30 o'clock position.

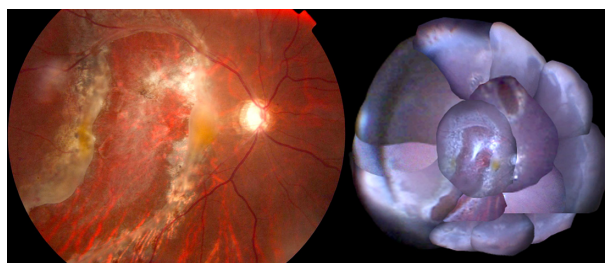


Figure 2 **Left:** Photograph of the posterior pole during the removal of the silicone oil. Note the macular splitting break is sealed with a small glial recurrence. **Right:** Montage of the postoperative eye. The entire retina is attached with an encircling scleral buckle. The perisilicone proliferation was minimal in this case.

Discussion

The cause of the retinal break which split the macula vertically in this patient was not definitively determined. A large retinal break along the arcade vessel is sometimes observed, but a retinal tear passing vertically across the macula is extremely rare, and we could not find any reports of macular splitting after blunt trauma through a MEDLINE search.

Retinal breaks near the ora serrata and necrotic retinal breaks at the equator are two typical primary breaks in eyes with a RRD after blunt trauma. However, the deformation of the eye following blunt trauma may cause a tangential traction on the posterior retina and choroid. This probably explains why the choroid ruptures following blunt trauma, but in our case there was no choroidal rupture at the posterior pole. In addition, our case had other retinal breaks including a superior break associated with the retinal vessels and a giant retinal tear caused by vitreoretinal traction on the vitreous base. Collectively, our findings suggest that the vertical splitting of the retina, retinal tears, giant retinal tear, and hemorrhage may have been due to the repeated trauma inducing different degrees and direction of tractional force on the retina and choroid.

Earlier, we found that pars plana vitrectomy with retinotomy and 360° scleral buckling was effective in treating eyes with severe proliferative vitreoretinopathy in patients with cognitive disorders.⁴ In this current case, the giant retinal tear may have reduced the force of the tangential traction. A mild glial proliferation on the surface of retina is inevitable after silicone oil tamponade.⁵ Scleral buckling and a giant retinal tear may help prevent recurrence of the retinal detachment caused by the perisilicone-induced proliferation in complicated cases of retinal detachments.

In conclusion, we reported a patient with a cognitive disorder who had a rhegmatogenous retinal detachment. An unusual vertical splitting of the macula accompanied by a giant retinal tear was observed intraoperatively. The retina

was successfully reattached by pars plana vitrectomy with silicone oil tamponade and scleral buckling and remained attached after silicone oil removal.

Disclosure

The authors have not received grant support or research funding and do not have any proprietary interests in materials described in the article.

References

1. Jacobson L. Ophthalmology in mentally retarded adults. A clinical survey. *Acta Ophthalmol (Copenh)*. 1988;66(4):457–462.
2. Kuwabara R, Minamoto A, Yamane K, Kajikawa T, Mizote H, Mishima HK. Retinal detachment in the mentally retarded. *Jpn J Ophthalmol*. 2003;47(1):93–96.
3. Johnston PB. Traumatic retinal detachment. *Br J Ophthalmol*. 1991;75(1):18–21.
4. Baba T, Tanaka S, Maesawa A, Teramatsu T, Noda Y. Closed funnel-shaped proliferative vitreoretinopathy in patients with cognitive disabilities. *Ophthalmic Surg Lasers Imaging*. 2007;38(3):189–195.
5. Lewis H, Burke JM, Abrams GW, Aaberg TM. Perisilicone proliferation after vitrectomy for proliferative vitreoretinopathy. *Ophthalmology*. 1988;95(5):583–591.

Clinical Ophthalmology

Publish your work in this journal

Clinical Ophthalmology is an international, peer-reviewed journal covering all subspecialties within ophthalmology. Key topics include: Optometry; Visual science; Pharmacology and drug therapy in eye diseases; Basic Sciences; Primary and Secondary eye care; Patient Safety and Quality of Care Improvements. This journal is indexed on

Submit your manuscript here: <http://www.dovepress.com/clinical-ophthalmology-journal>

Dovepress

PubMed Central and CAS, and is the official journal of The Society of Clinical Ophthalmology (SCO). The manuscript management system is completely online and includes a very quick and fair peer-review system, which is all easy to use. Visit <http://www.dovepress.com/testimonials.php> to read real quotes from published authors.