

Multifunctional Irrigation-Assisted Vacuum Drainage versus Traditional Drainage in the Treatment of Odontogenic Deep Fascial Infection: A Retrospective Cohort Study

Di He^{1,2,*}
Yuanyi Qian^{1,2,*}
Limei Zhou³
Haozhao Qi^{1,2}
Yanming Liu^{1,2}

¹Department of Oral and Maxillofacial Surgery, The Second Affiliated Hospital, Zhejiang University School of Medicine, Hangzhou, 310009, People's Republic of China; ²Clinical Research Center for Oral Diseases of Zhejiang Province, Hangzhou, 310020, People's Republic of China; ³Hangzhou Dental Hospital, Hangzhou, 310002, People's Republic of China

*These authors contributed equally to this work

Purpose: Odontogenic deep fascial space infection in the head and neck is a common potentially fatal clinical problem. Traditional drainage method is considered laborious and gravity-dependent. In this study, we aimed to evaluate the clinical effect of a modified multifunctional irrigation-assisted vacuum drainage (MIVD) by comparing it with the traditional drainage method in the treatment of odontogenic deep fascial infection.

Patients and Methods: Patients diagnosed with odontogenic deep fascial space infection in the Second Affiliated Hospital, Zhejiang University School of Medicine, China between March 2018 and March 2021 were studied. We divided the patients into two groups based on the drainage method they received: patients with the MIVD device were included in the MIVD group, patients with traditional drainage were included in the traditional group. Data were collected retrospectively including baseline characteristics and treatment outcome variables.

Results: A total of 65 patients were included. All the patients were eventually cured. There were no significant differences in age, gender, diabetes, end stage renal disease, autoimmune diseases, other systemic diseases, tobacco use, number of the infected spaces, preoperative white blood cell count and C-reactive protein between the two groups. The number and frequency of manual irrigation by clinicians (MIC), time required for white blood cell count to return to normal levels (TWBC), time required for C-reactive protein to return to normal levels (TCRP), the length of hospitalization and the length and total cost of antibiotics use were significantly less in the MIVD group. There was no significant difference in the cost of hospitalization between the 2 groups.

Conclusion: The MIVD device significantly reduced the number and frequency of MIC, TWBC, TCRP, the length of hospitalization and the length and total cost of antibiotics use in comparison with the traditional drainage method. It provided a favorable treatment method for patients with odontogenic deep fascial space infection in the head and neck.

Keywords: deep fascial space infection, odontogenic infection, irrigation, vacuum drainage, head and neck

Correspondence: Yanming Liu
Department of Oral and Maxillofacial Surgery, The Second Affiliated Hospital, Zhejiang University School of Medicine, 88 Jiefang Road, Shangcheng District, Hangzhou, Zhejiang, People's Republic of China
Tel/Fax +86571-87783741
Email liuyanming@zju.edu.cn

Introduction

Deep fascial space infection in the head and neck is a common problem encountered in clinics that usually requires emergency surgery. These infections mostly arise from odontogenic infections.¹ Without prompt and proper management, odontogenic deep fascial space infections may result in serious consequences

such as mediastinitis, necrotizing fasciitis, sepsis and osteomyelitis.^{2–8} Among the infections of all potential spaces, those located in the lower head and upper cervical region can be particularly dangerous for their close anatomy location to the trachea. As the infection progresses, the trachea can be oppressed. Airway obstruction is inclined to happen under this circumstance, thus putting the patient's life at risk.⁹

Effective treatment usually includes an incision adequate for thorough exploration of the involved spaces and a drain placement to the abscess cavity. Traditional drainage method is merely gravity-dependent. Regular irrigations are often required at least once a day to guarantee effective drainage and abscess elimination.¹⁰ The most common shortcomings we find in clinical practice of the traditional method are: (1) the workload of clinicians is relatively heavy; (2) gravity-dependent drainage with regular irrigations cannot achieve the effect of continuous purulence removal.

Recently, negative pressure irrigation has been applied to the treatment of abdominal infection, and excellent clinical effect has been received.^{11,12} Based on this idea, we proposed a modified drainage device that combined continuous vacuum drainage with internal irrigation for odontogenic deep fascial space infections three years ago, in the hope to achieve high clinical efficacy and overcome the disadvantages of traditional drainage method. The aim of this study is to describe the structure of this multifunctional irrigation-assisted vacuum drainage (MIVD) device and evaluate the clinical effect of it by comparing it with the traditional treatment of odontogenic deep fascial space infections in the head and neck.

Patients and Methods

Subjects

This was a retrospective cohort study. We included 65 patients (38 males and 27 females) admitted into the Department of Oral and Maxillofacial Surgery, the Second Affiliated Hospital, Zhejiang University School of Medicine, China, from March 2018 to March 2021. Inclusion criteria were as follows: (1) patients with a confirm diagnosis of deep fascial space infection; (2) patients whose infection was odontogenic; (3) patients who received surgical operation. Patients were excluded if (1) their infections were confined to temporal space and infraorbital space; (2) their clinical data was not complete; (3) they did not receive surgical treatment due to

nonmedical reasons. Involved spaces were buccal space, pterygomandibular space, masseteric space, sublingual space, parapharyngeal space, submandibular space and submental space. For patients with infraorbital space infection, intraoral incision and Penrose drains are generally chosen.¹⁰ Tubular drainage device is also inapplicable for patients with temporal space infection, considering the dense anatomical structure of the temporal space.^{13,14} Therefore, suborbital space infection and temporal space infection were not included in this study. Drainage method was chosen by the patients or their representatives after clinicians fully explained the benefits and risks of both the MIVD device and traditional drainage. According to the drainage method, the patients were divided into 2 groups: 33 patients with MIVD device were included in the MIVD group, 32 patients with traditional drainage were included in the traditional group.

Device Structure

The MIVD device consisted of three parts: a drainage tube, an external irrigation tube and an internal irrigation tube. The drainage tube was a disposable silicone catheter with the diameter of 7.33mm, manufactured by Suzhou McLean medical equipment co., Ltd., Jiangsu, China. Scale lines could be seen on the tube wall near the end which would later be placed into the abscess cavity (the free end), and the other end would be connected with a negative pressure device. Several side holes were arranged on the tube wall near the free end, each with a diameter of 4–6mm. Two small holes, both with the diameter of about 3mm, were set symmetrically on the drainage tube wall, 15–20cm away from the free end. They worked as the entrances for the irrigation tubes to extend themselves into the drainage tube. Both irrigation tubes were disposable PVC plastic catheters with a closing cap (F6, type one) manufactured by Suzhou Jingle polymer medical apparatus co., Ltd., Jiangsu, China. The end of the internal irrigation tube remained inside the drainage tube, while the external irrigation tube stretched out from either the free end of the drainage tube or one of the side holes on the drainage tube wall, according to the different locations of the abscess cavity (Figure 1). The number of side holes, the length of the side-hole area, and the distance from the entrance holes to drainage tube's free end depended on the size and depth of the abscess cavity.

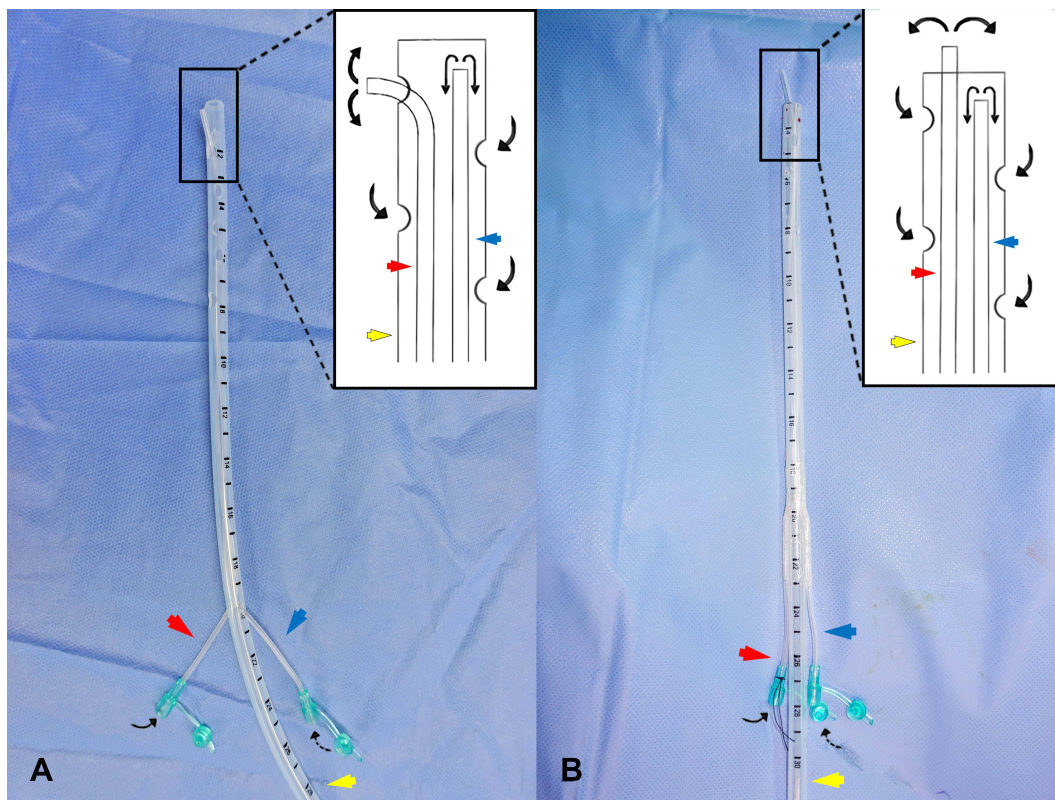


Figure 1 The structure of the MIVD device (red arrows, the external irrigation tube; blue arrows, the internal irrigation tube; yellow arrows, the drainage tube; black arrows, external irrigation fluid flow; dotted black arrows, internal irrigation fluid flow). **(A)** The external irrigation tube stretched out from one of the side holes on the drainage tube wall. **(B)** The external irrigation tube stretched out from the free end of the drainage tube.

Abbreviation: MIVD, multifunctional irrigation-assisted vacuum drainage.

Treatment Methods

Before the surgery, all patients underwent contrast-enhanced CT scan to identify the location and range of the infected abscess cavity. Incisions were designed based on the abscess cavity's location and range. A submandibular incision was mostly used, referring to the extraoral incision 2cm below and parallel to the lower edge of the mandibular body. The platysma muscle and the superficial layer of the deep fascia were incised successively, followed by a blunt separation into the abscess cavity to provide access for purulence removal. Proper amount of purulence was extracted and sent for bacterial culture and drug sensitivity testing. After thoroughly removing the purulence, we irrigated the abscess cavity with 1% hydrogen peroxide, normal saline and 0.5% iodophor. Drainage was established afterwards. Surgical procedures are shown in Figure 2.

In the MIVD group, we achieved drainage by the MIVD device described above. After the device was assembled and successfully put into the patient's body (Figure 3), we sutured the incision closely. Postoperative

continuous vacuum drainage and internal irrigation were established as described in below: (1) the drainage tube was connected with a negative pressure device (maintained at the pressure of 150–200 kPa) to provide a vacuum drainage environment; (2) large amounts of normal saline was infused into the abscess cavity constantly (3000mL a day, 125mL an hour) through the external irrigation tube's closing cap, allowing for continuous irrigation; (3) by manually infusing 100mL normal saline once 2–3 days through the internal irrigation tube's closing cap, the drainage tube was internally irrigated and prevented from blockage by purulence and debris; (4) irrigation and drainage volume was checked every 12 hours to keep the irrigation-drainage balanced. In case of any device-related incident that might threaten the patient's health, the MIVD device could be altered immediately into a traditional drainage by cutting the drainage tube short and removing the irrigation tubes.

In the traditional group, drainage was established by a semi rubber tube and the incision was intermittently sutured. The drainage was gravity-dependent. Manual

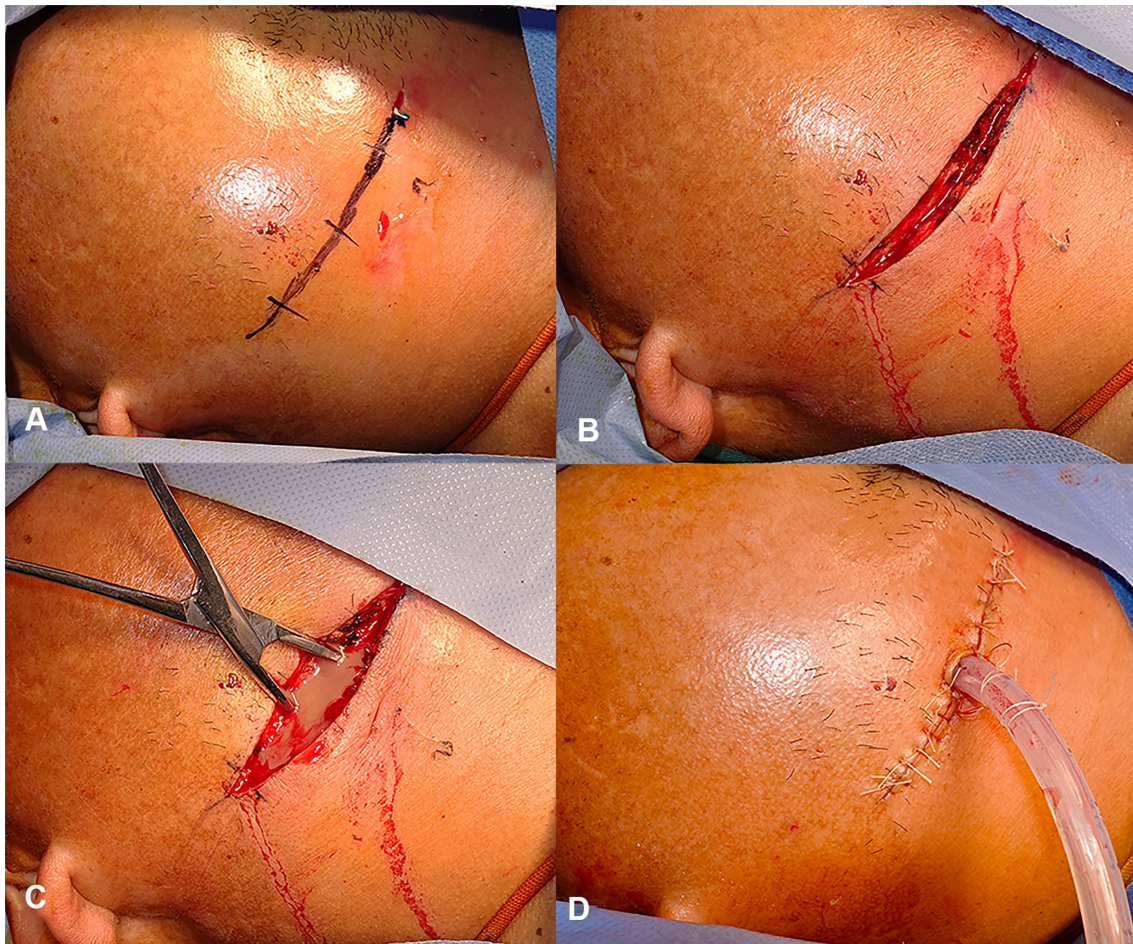

Figure 2 Surgical procedures of a patient treated with the MIVD device. (A) A submandibular incision was design. (B) The platysma muscle and the superficial layer of the deep fascia were incised successively. (C) A blunt separation was made into the abscess cavity to thoroughly remove purulence. (D) The incision was sutured closely after the MIVD device being put into the patient's body.

Abbreviation: MIVD, multifunctional irrigation-assisted vacuum drainage.

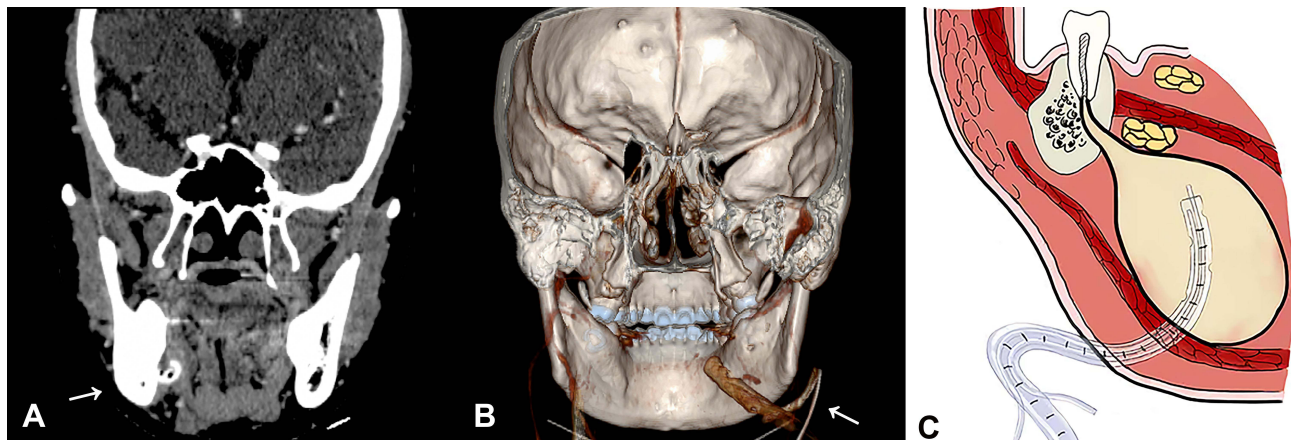


Figure 3 An example of the MIVD device in the patient's body. (A) Contrast-enhanced CT scan showed the location of the MIVD device in the patient body (anterior coronal position) (A, the white arrow). (B) Corresponding 3D reconstruction image of the patient with the MIVD device (posterior coronal position) (B, the white arrow). (C) An illustration of the MIVD device in the abscess cavity.

Abbreviation: MIVD, multifunctional irrigation-assisted vacuum drainage.

irrigation of normal saline by clinicians was required daily, usually 1–2 times a day, according to the amount and characteristics of the drainage fluid. Indications of drainage removal for both groups included: (1) no purulence was observed in the drainage fluid; (2) the patient's post-operative white blood cell count and C-reactive protein had approached normal levels.

Variables

We recorded and collected the demographic data and treatment outcome variables from all the patients involved. Baseline characteristics included age, gender, diabetes, end stage renal disease (ESRD), autoimmune diseases, other systemic diseases, tobacco use, number of the infected spaces, and preoperative white blood cell count and C-reactive protein. Treatment outcome variables included number and frequency of manual irrigation by clinicians (MIC), time required for white blood cell count to return to normal levels (TWBC), time required for C-reactive protein to return to normal levels (TCRP) and length and total cost of antibiotics use and hospitalization.

Statistical Analysis

Numerical variables were presented as mean \pm standard deviation, while categorical variables were expressed in absolute numbers. After checking the normal distribution and the homogeneity of the variance, statistical comparisons of categorical variables between the MIVD group and the traditional group were carried out via Pearson Chi-square test and Fisher's exact test, while numerical variables were compared via Student's *t*-test. Statistical differences were considered significant when $p < 0.05$. All the data was analyzed by software SPSS 21.0 (IBM Analytics, Armonk, NY).

Results

The baseline characteristics of patients in the MIVD group and traditional group are shown in Table 1. There were no significant differences in age, gender, diabetes, ESRD, autoimmune diseases, other systemic diseases, tobacco use, number of the infected spaces, preoperative white blood cell count and C-reactive protein between the two groups ($p > 0.05$). Patients in both groups were eventually cured. No MIVD-related incident has occurred.

The results of the treatment outcome variables are presented in Figure 4. We assessed the clinician's workload by the number and frequency of MIC. As is shown in the Figure 4A and B, the number and frequency of MIC in

Table 1 Baseline Characteristics of the 65 Patients Involved in This Study

Variables	MIVD Group n=33 (%)	Traditional Group n=32 (%)	P value
Age/years	50.15 \pm 16.75	49.22 \pm 17.33	0.747 ^a
Gender			
Male	18 (54.5)	20 (62.5)	0.515 ^b
Female	15 (45.5)	12 (37.5)	
Diabetes			
Yes	10 (30.3)	6 (18.8)	0.280 ^b
No	23 (69.7)	26 (81.3)	
ESRD			
Yes	1 (3.0)	0 (0.0)	1.000 ^c
No	32 (97.0)	32 (100.0)	
Autoimmune diseases			
Yes	0 (0.0)	1 (3.1)	0.492 ^c
No	33 (100.0)	31 (96.9)	
Other systemic diseases ^d			
Yes	17 (51.5)	14 (43.8)	0.531 ^b
No	16 (48.5)	18 (56.3)	
Tobacco use			
Yes	14 (42.4)	14 (43.8)	0.914 ^b
No	19 (57.6)	18 (56.3)	
Infected spaces	2.48 \pm 1.00	2.16 \pm 1.02	0.537 ^a
Preoperative WBC ($\times 10^9/L$)	17.67 \pm 4.81	15.53 \pm 5.10	0.933 ^a
Preoperative CRP	106.33 \pm 71.32	105.11 \pm 79.30	0.580 ^a

Notes: ^aStatistical analysis using Student's *t*-test; ^bStatistical analysis using Pearson Chi-square test; ^cStatistical analysis using Fisher's exact test; ^dOther systemic diseases included cardiovascular diseases, cerebrovascular diseases, nervous system diseases, viral hepatitis and tuberculosis.

Abbreviations: MIVD, multifunctional irrigation-assisted vacuum drainage; ESRD, end stage renal disease; WBC, white blood cells; CRP, C-reactive protein.

the MIVD group (4.97 \pm 1.90 times, 0.37 \pm 0.12 times a day) were significantly lower than those in the traditional group (23.31 \pm 9.78 times, 1.76 \pm 0.78 times a day). The differences between the two groups were statistically significant ($p < 0.05$).

TWBC and TCRP of the MIVD group were 6.06 \pm 2.33 days and 8.48 \pm 2.81 days, while those of the traditional group were 8.31 \pm 3.08 days and 11.06 \pm 3.58 days, as are described in Figure 4C and D. The results showed that TWBC and TCRP of the MIVD group were significantly shorter than those of the traditional group ($p < 0.05$).

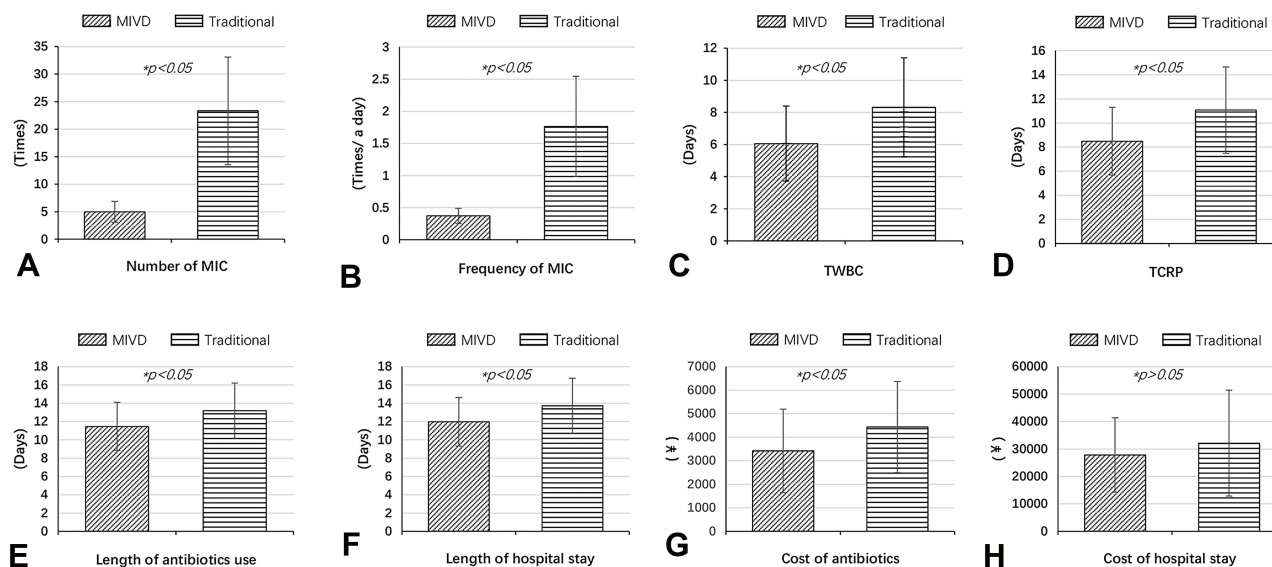


Figure 4 Comparative results of the treatment outcome variables between the MIVD group and the traditional group. *Statistical analysis using Student's *t*-test. (A) The comparative result of the number of MIC between the 2 groups. (B) The comparative result of the frequency of MIC between the 2 groups. (C) The comparative result of TWBC between the 2 groups. (D) The comparative result of TCRP between the 2 groups. (E) The comparative result of the length of antibiotics use between the 2 groups. (F) The comparative result of the length of hospital stay between the 2 groups. (G) The comparative result of the cost of antibiotics between the 2 groups. (H) The comparative result of the cost of hospital stay between the 2 groups.

Abbreviations: MIVD, multifunctional irrigation-assisted vacuum drainage; MIC, manual irrigation by clinicians; TWBC, time required for white blood cell count to return to normal levels; TCRP, time required for C-reactive protein to return to normal levels.

Antibiotics use was less in the patient of the MIVD group than the traditional group (Figure 4E and G). The length and total cost of antibiotics use in MIVD group were 11.45 ± 2.62 days and 3418.85 ± 1776.23 ¥, significantly less in comparison with 13.18 ± 3.01 days and 4433.53 ± 1936.88 ¥ in the traditional group ($p < 0.05$).

The length of hospitalization of the MIVD group was 11.97 ± 2.66 days, shorter than 13.72 ± 2.30 days of the traditional group ($p < 0.05$) (Figure 4F). However, there was no significant difference in the cost of hospitalization between the 2 groups ($27,807.17 \pm 13,532.01$ ¥ versus $32,094.57 \pm 19,307.15$ ¥, $p > 0.05$) (Figure 4H).

Discussion

Deep fascial space infection in the head and neck is a common clinical problem which may lead to fatal outcomes. The majority of deep fascial space infections in the head and neck can be originated from odontogenic infections.^{15,16} However, patients are easily inclined to overlook the importance of seeking medical help during the early stages, resulting in severe consequences.²⁻⁸ In scenarios where the infections are located in the lower head and upper cervical region, the patient's life could be threatened within minutes by airway obstruction.⁹ Therefore, once the pus cavity is formed, prompt surgical

drainage establishment is imperative to remove purulence and provide a healing environment.

Current traditional drainage method is passive and gravity-dependent. Penrose drain and its alternatives are some of the most frequently used forms of traditional drains.^{10,17} This method requires heavy workload of clinicians and lacks the ability to provide continuous purulence removal. The patient often needs relatively large amount of antibiotics and long length of hospitalization. Compared with the traditional method, our modified MIVD device provides better drainage and irrigation after surgical treatment for patients suffer from odontogenic deep fascial space infection, especially for those whose infections are located in the lower head and upper cervical region.

Negative pressure therapy has been proven to effectively remove necrotic debris and avoid reaccumulating of purulence in the wound bed.¹⁸ Researches have also shown that negative pressure drainage can avoid contamination and cross-infection by closely suturing the incision as well as improve granulation tissue coverage and promote epithelial regeneration.^{19,20} Meanwhile, continuous irrigation of normal saline can provide a gentle way of infection cleansing and promote better wound healing.²¹⁻²³ By combining negative pressure drainage with continuous

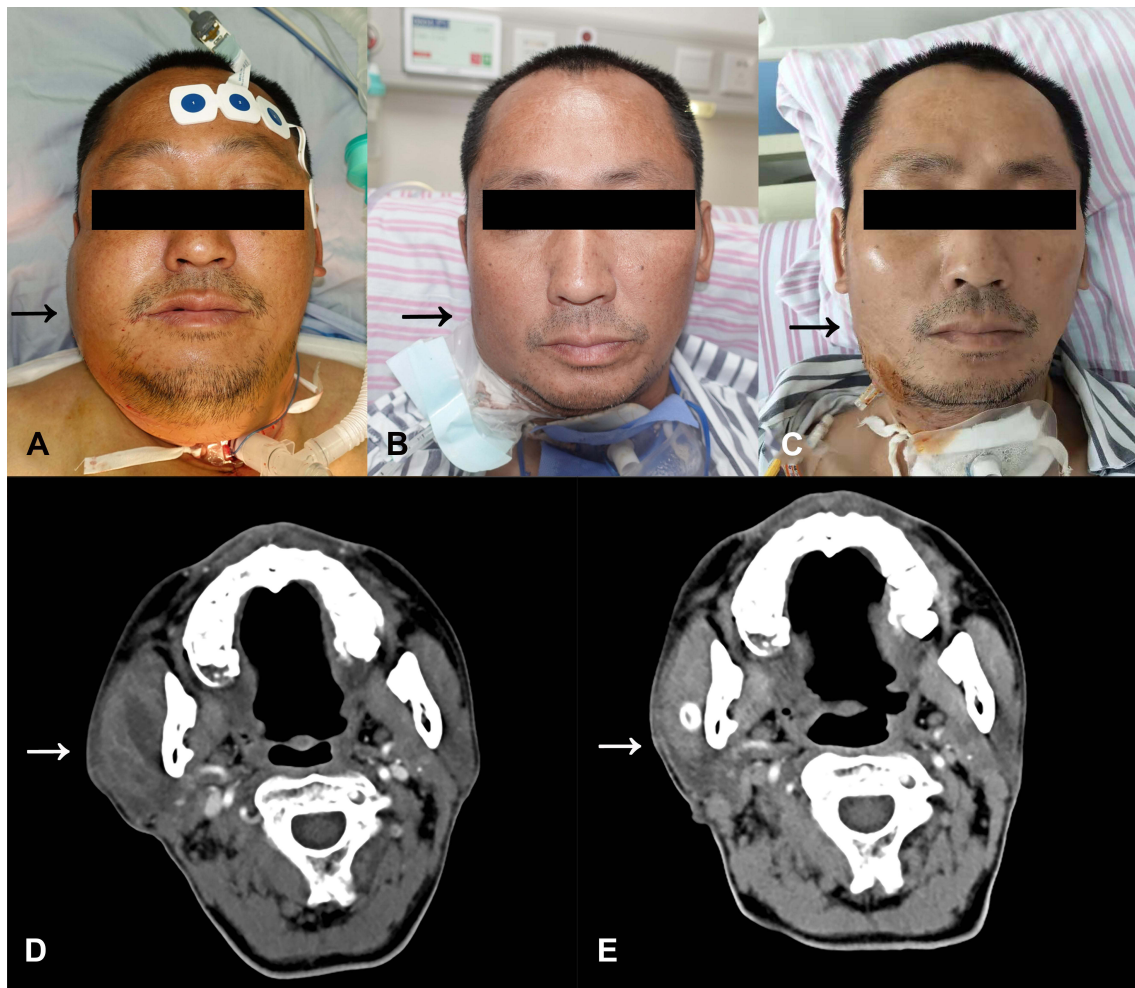


Figure 5 The swelling of the infected area was notably improved after the patient being treated with the MIVD device. **(A)** The preoperative picture of the patient. Asymmetry in the head and neck area was obvious **(A, the black arrow)**. **(B)** The picture of the patient on the fifth day after the surgery. The swelling subsided effectively **(B, the black arrow)**. **(C)** The picture of the patient on the seventh day after the surgery. The patient's facial appearance returned to normal **(C, the black arrow)**. **(D)** The preoperative contrast-enhanced CT scan showed swelling of the infected area. Abscess cavities were found **(D, the white arrow)**. **(E)** Contrast-enhanced CT scan on the fifth day after the surgery. The swelling markedly subsided and abscess cavities were controlled **(E, the white arrow)**.

Abbreviation: MIVD, multifunctional irrigation-assisted vacuum drainage.

irrigation, our modified MIVD device received better clinical outcome than the traditional drainage method. Firstly, clinicians' workload was effectively reduced. Instead of manual irrigation 1–2 times a day, the MIVD device allowed for automatic continuous irrigation. Clinicians only needed to irrigate the internal irrigation tube once every 2–3 days to prevent potential tube blockage, depending on the characteristics of the drainage fluid. Furthermore, infection was better controlled. As are shown in the results, time required for inflammation-related indicators (white blood cell count and C-reactive protein) to return to normal levels was shortened. The features of patients with deep fascial space infection in the head and neck usually include swelling or asymmetry of the infected region. After being treated with the MIVD

device, the swelling of the infected area was notably improved in all patients. A typical case is shown in **Figure 5**. Postoperative contrast-enhanced CT scan also displayed shrinkage of the abscess cavity. Meanwhile, drainage samples were collected and sent for bacterial culture and drug sensitivity testing every 2–3 days. Negative results were obtained. All the outcomes above indicated that the MIVD device was effective in infection elimination. Moreover, the length of antibiotics use and total hospitalization were both shortened. This reduced the possibility of bacterial resistance, on the other hand, accelerated the healing process. The cost of antibiotics use was therefore reduced. However, despite the fact that the average cost of hospitalization in the MIVD group was less than that in the traditional group, there was no significant

difference between them. We believed this was because the total cost of hospitalization could be affected by many factors, such as the patient's age and systemic diseases.

Previously, negative pressure drainage with irrigation device has been applied for maxillofacial space infections by some scholars and favorable effect has been achieved.²⁴ However, the drainage tube and irrigation tube of their device were separated. This required more surgical incisions, thus increasing the patient's operational trauma and complexity of the surgery. As for our MIVD device, the irrigation tubes are nested within the drainage tube, requiring only one incision for each device. Due to its integrative and concise structure, the MIVD device can be used flexibly both individually or in combinations according to the number of the abscess cavity. Postoperative contrast-enhanced CT scan showed that the MIVD device extended well in abscess cavities, even in those with complex anatomical structures, for example, areas beneath the skull base (Figure 6). Another previous study also involved integrative drainage tube and irrigation tube.²⁵ Nevertheless, their device lacked the structure of internal irrigation. To the best of our knowledge, negative pressure drainage system is prone to tube blockage. As Qiu et al mentioned in their study, there was a 12.7% incidence rate of clogging about the negative pressure drainage technique.²⁶ In our study, we equipped the MIVD device with an internal irrigation tube, which successfully protected the drainage tube from blockage by purulence or necrotic debris.

There was no absolute contraindication to the MIVD device in the treatment of odontogenic deep fascial space infection. However, patients with uncontrolled mental disorder or delirium caused by various reasons (for example, traumatic head injury, brain tumor and alcohol withdrawal syndrome) were less recommended to receive the MIVD device, in order to avoid accidental patient-initiated device removal. The main shortcoming of our device was the patient's postoperative activity limitation, for the drainage tube was connected to a negative pressure device (usually a central negative pressure system). The patient's activity limitation may increase the risk of thrombus of lower extremity veins. In order to prevent thrombus, we have taken active VTE (Venous Thromboembolism) preventive measures, including application of the gradient pressure band, pneumatic compression therapy and requiring the patient to do 10 minutes of moderate bedside exercise three times a day.

Conclusion

Compared with the traditional drainage method, the MIVD device significantly reduced the number and frequency of

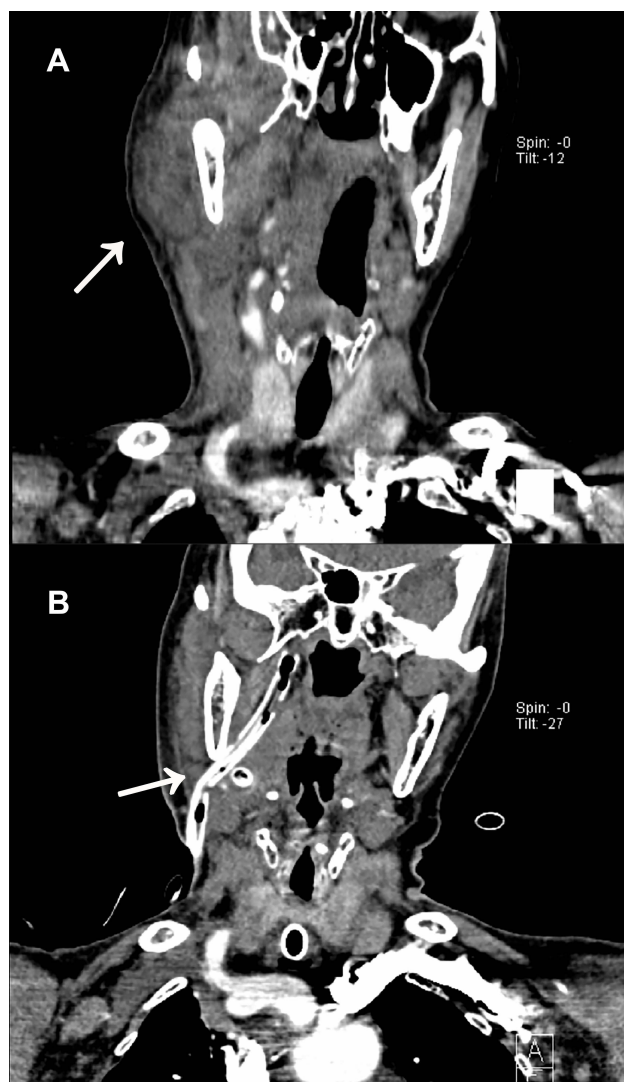


Figure 6 Contrast-enhanced CT scan of a patient treated with the MIVD device. (A) Preoperative contrast-enhanced CT scan of the patient. Abscess cavities can be seen (A, the white arrow). (B) The contrast-enhanced CT scan on the seventh day after the surgery. Abscess cavities were effectively eliminated. The MIVD device extended well in the abscess cavity beneath the skull base (B, the white arrow).

Abbreviation: MIVD, multifunctional irrigation-assisted vacuum drainage.

MIC, TWBC, TCRP, the length of hospitalization and the length and total cost antibiotics use. Thus, it is a promising treatment method for patients with odontogenic deep fascial space infections in the head and neck.

Abbreviations

MIVD, multifunctional irrigation-assisted vacuum drainage; ESRD, end stage renal disease; MIC, manual irrigation by clinicians; TWBC, time required for white blood cell count to return to normal levels; TCRP, time required for C-reactive protein to return to normal levels; VTE, venous thromboembolism.

Data Sharing Statement

The datasets used and analyzed during the current study are available from the corresponding author on reasonable request.

Ethics Approval and Informed Consent

This study was approved by the Human Research Ethics Committee of the Second Affiliated Hospital, Zhejiang University School of Medicine (No.2021-0543). Here we would like to give more explanations on ethics issue. Every inpatient was informed that their medical records might be used and informed consent was gotten. As for the choice of treatment method between the MIVD and the traditional drainage method, informed consent was granted by all patients included in this study. In the stage of this retrospective study, we only included patients' clinical data. No physical contact or surgical procedure was performed on the patients, thus there was no adverse effect on the patients' physical health. All patients' information was kept anonymous to ensure privacy protection. Therefore, informed consent was not required for this study.

We strictly abided by the Declaration of Helsinki, clinical research ethics and national laws and regulations on clinical human researches.

Consent for Publication

The authors confirm that the details of all images can be published.

Acknowledgments

The authors thank Menghua Yu, Tian Zhang, Qin Yan and Xiahan Sheng for their help with acquisition of data, photo collecting and illustration.

Author Contributions

All authors made a significant contribution to the work reported, whether that is in the conception, study design, execution, acquisition of data, analysis and interpretation, or in all these areas; took part in drafting, revising or critically reviewing the article; gave final approval of the version to be published; have agreed on the journal to which the article has been submitted; and agree to be accountable for all aspects of the work.

Funding

This study was funded by the Key Program of Medical Health Science and Technology Project of Zhejiang

Provincial Health Commission, National Health and Family Planning Commission of the People's Republic of China (WKJ-ZJ-1718), and Basic Public Welfare Research Program of Zhejiang Province (LGF21H14002).

Disclosure

The authors report no conflicts of interest in this work.

References

1. Topazian RG, Goldberg MH, Hupp JR. *Oral and Maxillofacial Infections*. 4th ed. WB Saunders Company: Philadelphia; 2002.
2. Gaber Hassanein A, Mohamed EEH, Hazem M, et al. Assessment of prognosis in odontogenic descending necrotizing mediastinitis: a Longitudinal Retrospective Study. *Surg Infect*. 2020;21(8):709–715. doi:10.1089/sur.2019.302
3. Wong T. A nationwide survey of deaths from oral and maxillofacial infections: the Taiwanese experience. *J Oral Maxillofac Surg*. 1999;57(11):1297–1299. doi:10.1016/s0278-2391(99)90863-7
4. Bulut M. Fatal descending necrotizing mediastinitis. *Emerg Med J*. 2004;21(1):122–123. doi:10.1136/emj.2003.002865
5. Carter L, Lowis E. Death from overwhelming odontogenic sepsis: a case report. *Br Dent J*. 2007;203(5):241–242. doi:10.1038/bdj.2007.784
6. Abe M, Mori Y, Inaki R, et al. A case of odontogenic infection by *Streptococcus constellatus* leading to systemic infection in a Cogan's syndrome patient. *Case Rep Dent*. 2014;2014:793174. doi:10.1155/2014/793174
7. Bali R, Sharma P, Gaba S, et al. A review of complications of odontogenic infections. *Natl J Maxillofac Surg*. 2015;6(2):136–143. doi:10.4103/0975-5950.183867
8. Matsumoto Y, Yokoi H, Ikeda T, et al. Odontogenic infection and antiresorptive agent-related osteonecrosis of the jaw with facial subcutaneous abscess formation: a retrospective clinical study of difficult-to-diagnose cases. *Auris Nasus Larynx*. 2021;48(4):758–763. doi:10.1016/j.anl.2020.12.005
9. Lim HK, Wang JM, Hung ST, et al. A dangerous cause of airway obstruction: deep neck infection. *Signa Vitae*. 2021;17(2):4–9. doi:10.22514/sv.2020.16.0101
10. Furness J. Contemporary oral and maxillofacial surgery, 6th edition. *Br Dent J*. 2013;215(2):99. doi:10.1038/sj.bdj.2013.731
11. Tong Z, Shen X, Ke L, et al. The effect of a novel minimally invasive strategy for infected necrotizing pancreatitis. *Surg Endosc*. 2017;31(11):4603–4616. doi:10.1007/s00464-017-5522-0
12. Tong Z, Ke L, Li B, et al. Negative pressure irrigation and endoscopic necrosectomy through man-made sinus tract in infected necrotizing pancreatitis: a technical report. *BMC Surg*. 2016;16(1):1–7. doi:10.1186/s12893-016-0190-x
13. Rout S, Gautam S, Shah AK. Temporal space infection secondary to recurrent buccal space infection from mandibular deciduous molar in 7-year-old child: a case report. *J Chitwan Medical Coll*. 2019;9(1):70–73. doi:10.3126/jcms.v9i1.23789
14. Bratton T, Jackson D, Nkungula-Howlett T, et al. Management of complex multi-space odontogenic infections. *J Tenn Dent Assoc*. 2002;82:39–47.
15. Weise H, Naros A, Weise C, et al. Severe odontogenic infections with septic progress - A constant and increasing challenge: a retrospective analysis. *BMC Oral Health*. 2019;19(1):173. doi:10.1186/s12903-019-0866-6
16. Zheng LY, Yang C, Zhang WJ, et al. Comparison of multi-space infections of the head and neck in the elderly and non-elderly: part I the descriptive data. *J Cranio-Maxillofac Surg*. 2013;41(8):E208–E212. doi:10.1016/j.jcms.2013.01.020

17. Mair M, Mahmood S, Fagiry R, et al. Comparative analysis of paediatric and adult surgically drained dental infections at a university teaching hospital. *Br J Oral Maxillofac Surg.* 2020;58(10):E307–E311. doi:10.1016/j.bjoms.2020.08.043
18. Banasiewicz T, Borejsza-Wysocki M, Meissner W, et al. Vacuum-assisted closure therapy in patients with large postoperative wounds complicated by multiple fistulas. *Videosurg Other Minimally Invasive Tech.* 2011;3:155–163. doi:10.5114/wiitm.2011.24694
19. Armstrong DG. Discussion: update on Negative-Pressure Wound Therapy. *Plast Reconstr Surg.* 2011;127(1):116S–116S. doi:10.1097/PRS.0b013e3181fb5431
20. Xue X, Li N, Ren L. Effect of vacuum sealing drainage on healing time and inflammation-related indicators in patients with soft tissue wounds. *Int Wound J.* 2021. doi:10.1111/iwj.13565
21. Ding M, Lee C, Wang Y, et al. Innovative continuous-irrigation approach for wound care after deep neck infection surgery: a case report. *Int J Surg Case Rep.* 2021;80:105620. doi:10.1016/j.ijscr.2021.02.006
22. Willy C, Scheuermann-Poley C, Stichling M, et al. Importance of wound irrigation solutions and fluids with antiseptic effects in therapy and prophylaxis. *Der Unfallchirurg.* 2017;120(7):549–560. doi:10.1007/s00113-017-0375-5
23. Kim PJ, Attinger CE, Constantine T, et al. Negative pressure wound therapy with instillation: international consensus guidelines update. *Int Wound J.* 2020;17(1):174–186. doi:10.1111/iwj.13254
24. Zhao N, Liu Y, Yue J, et al. Negative pressure drainage-assisted irrigation for maxillofacial space infection. *Oral Dis.* 2020;26(7):1586–1591. doi:10.1111/odi.13421
25. Dai T, Cheng J, Ran H, et al. Application of disposable multifunctional drainage tube-assisted irrigation in patients with severe multi-space infections in oral and maxillofacial head and neck regions. *J Craniofac Surg.* 2020;31(2):e202–e205. doi:10.1097/scs.00000000000006236
26. Qiu Y, Li Y, Gao B, et al. Therapeutic efficacy of vacuum sealing drainage-assisted irrigation in patients with severe multiple-space infections in the oral, maxillofacial, and cervical regions. *J Cranio-Maxillofac Surg.* 2019;47(5):837–841. doi:10.1016/j.jcms.2019.01.031

Infection and Drug Resistance

Dovepress

Publish your work in this journal

Infection and Drug Resistance is an international, peer-reviewed open-access journal that focuses on the optimal treatment of infection (bacterial, fungal and viral) and the development and institution of preventive strategies to minimize the development and spread of resistance. The journal is specifically concerned with the epidemiology of

antibiotic resistance and the mechanisms of resistance development and diffusion in both hospitals and the community. The manuscript management system is completely online and includes a very quick and fair peer-review system, which is all easy to use. Visit <http://www.dovepress.com/testimonials.php> to read real quotes from published authors.

Submit your manuscript here: <https://www.dovepress.com/infection-and-drug-resistance-journal>