


# Scrotal Abscess in a Japanese Patient Caused by *Prevotella bivia* and *Streptococcus agalactiae*, Successfully Treated with Cefazolin and Amoxicillin: A Case Report

Haruka Watanabe<sup>1</sup>  
Yuta Norimatsu <sup>1,2</sup>  
Yuki Ohno<sup>1</sup>

<sup>1</sup>Department of Dermatology, JR Tokyo General Hospital, Tokyo, Japan;

<sup>2</sup>Department of Dermatology, University of Tokyo Graduate School of Medicine, Tokyo, Japan

**Background:** Infections caused by *Prevotella bivia*, a gram-negative anaerobic bacillus, are rare, with no reported cases in Japan. We present a novel case of scrotal abscess in a Japanese patient co-infected with *Prevotella bivia* and *Streptococcus agalactiae*.

**Case Presentation:** A 41-year-old uncontrolled diabetic man complained of swelling and pain in the scrotum. On examination, computed tomography revealed an abscess of 5-cm diameter in the scrotum. Then, the abscess was incised and drained. He was treated with cefazolin empirically. *Prevotella bivia* and *Streptococcus agalactiae* were identified in the pus cultures obtained from the abscess. However, the susceptibility tests for *Prevotella bivia* could not be submitted. Seven days following admission, the pain reduced, and the drainage slowed. The patient was discharged on day 14 when cefazolin was discontinued and oral amoxicillin (750 mg/day) was started. Amoxicillin was continued until day 42; improvement was confirmed.

**Conclusion:** To the best of our knowledge, this case is the first report of *Prevotella bivia* in Japan. We suggest that cephem antibiotics such as cefazolin may be effective against *Prevotella bivia* in Japan.

**Keywords:** case report, *Prevotella bivia*, *Streptococcus agalactiae*, cefazolin, amoxicillin

## Background

Approximately 90% of skin infections are caused by *Staphylococcus aureus* and *Streptococcus pyogenes*, sometimes in combination with anaerobic bacteria such as *Bacteroides* and *Prevotella* species.<sup>1,2</sup> *Prevotella* species are present in the vaginal flora and can cause pelvic inflammatory diseases along with perirectal abscess.<sup>3,4</sup> *Prevotella bivia* is a gram-negative anaerobic bacillus whose virulence is presumably enhanced by low oxygen tension in a polymicrobial environment.<sup>5</sup> *Prevotella bivia* infections in humans are rare, with only 18 published cases in 44 years.<sup>6–23</sup> Since most *Prevotella bivia* strains are  $\beta$ -lactamase-positive,<sup>24</sup> clindamycin, amoxicillin/clavulanate, metronidazole, and imipenem are the recommended antibacterial agents.<sup>21,25</sup> However, antibiotic resistance varies across countries,<sup>26</sup> and it is unknown whether *Prevotella bivia* strains in Japan are  $\beta$ -lactamase positive.

To the best of our knowledge, there have been no reported cases of *Prevotella bivia* infections in Japan. Herein, we present a case of scrotal abscess in a Japanese patient that was caused by *Prevotella bivia* and *Streptococcus agalactiae*, and successfully treated using cefazolin followed by amoxicillin.

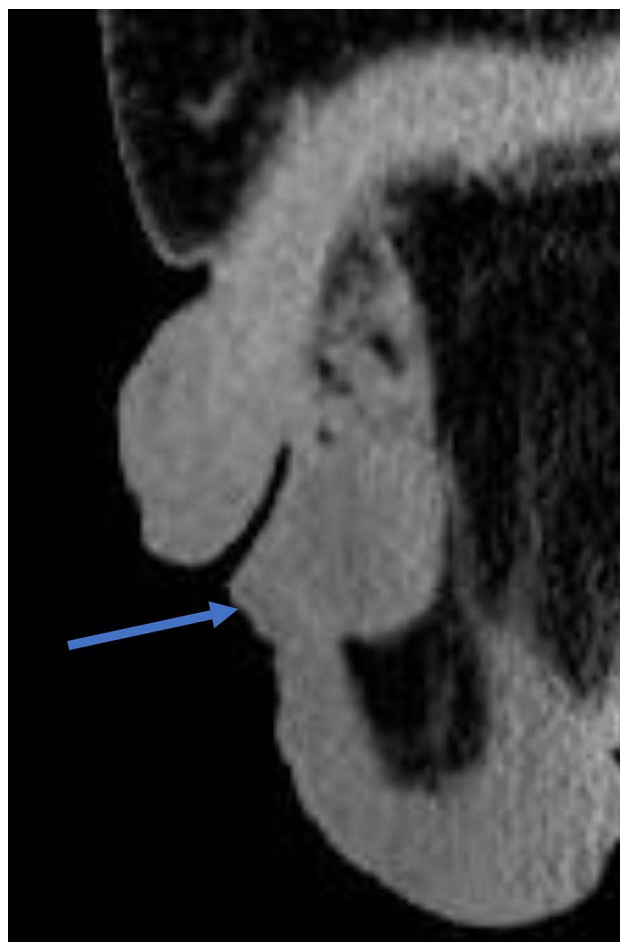
Correspondence: Yuta Norimatsu  
JR Tokyo General Hospital, 2-1-3 Yoyogi  
Shibuya-ku, Tokyo, 151-8528, Japan  
Tel +81-3-3320-2210  
Fax +81-3-3370-7478  
Email norimatsuy-der@h.u-tokyo.ac.jp

## Case Presentation

A 41-year-old man visited the urology department of JR Tokyo General Hospital with complaints of swelling and pain in the scrotum that had commenced 3 days earlier. A urologist diagnosed epididymitis and prescribed levofloxacin at 500 mg/day. However, the symptoms did not improve, and the patient visited the dermatology department of JR Tokyo General Hospital (day 0).

On admission, he presented with a temperature of 36.5°C, a blood pressure of 131/80 mmHg, and a heart rate of 100 beats per minute. His height and weight were 164 cm and 94.8 kg, respectively (body mass index: 35.2 kg/m<sup>2</sup>). Local examination revealed that the scrotum was markedly swollen. The laboratory workup on day 0 revealed elevated levels of serum C-reactive protein (6.71 mg/dL) (normal: ≤0.30 mg/dL) and white blood cells (13,800/μL) (normal: ≤8600 mg/dL). Furthermore, untreated diabetes was diagnosed owing to high hemoglobin A1c level (11.5%) (normal: ≤6.0%), and insulin-enhancing therapy was initiated on day 0. The patient's anti-streptolysin O antibody titer was 49 U/mL (normal: ≤239 U/mL), and no renal or hepatic dysfunction was observed. Test results for syphilis (rapid plasma reagin and *Treponema pallidum* hemagglutination) and human immunodeficiency virus antibodies were negative. The patient had not visited a medical institution for about 20 years; therefore, he declared no medical history. His partner was a woman, and he did not engage in commercial sex. Notably, there was no family history.

Additionally, computed tomography revealed an abscess with a diameter of 5 cm in the scrotum without gas image (Figure 1). There were no abnormal findings in the testes or epididymis. On day 0, the skin above the abscess was incised, which was drained, and the pus obtained was submitted for culture. We do not have a dedicated transport spitz for anaerobic bacteria. Therefore, we contacted the bacterial laboratory before the incision and asked them to prepare the culture in advance. About 5cc of pus was put into a sterilized spitz and transported to the bacterial laboratory within a few minutes for immediate culturing. Additionally, the blood culture was submitted on day 0. Intravenous administration of cefazolin (2 g/8 h) was empirically initiated as an antibacterial treatment for the scrotal abscess. The blood culture was negative. Culturing of the pus in the abscess revealed the presence of *Prevotella* spp. (RapID ANA II System, Thermo Fisher Scientific, United States) and



**Figure 1** Computed tomography revealed an abscess with a diameter of 5 cm in the scrotum without gas image (sagittal section).

*Streptococcus agalactiae* (group B) spp. (Prolex™ Streptococcal Grouping Latex Kit, IWAKI&CO., LTD., Japan). Furthermore, the antibiotic susceptibility pattern of *Streptococcus agalactiae* was done according to MICroFAST 7J, BECKMAN COULTER, United States; therefore, intravenous administration of cefazolin was empirically continued (Table 1). In Japan, the antibiotic susceptibility of *Prevotella bivia* could not be measured this time because it can be measured only at a specific research facility.

Although the symptoms exhibited improvements, pus drainage continued, and the pain persisted; therefore, a second pus culture was performed on day 7. A large number of gram-negative bacilli were observed and identified as *Prevotella bivia* (RapID ANA II System, Thermo Fisher Scientific, United States) on day 10 (the pus culture was negative for *Streptococcus agalactiae*). At this time, the pain subsided, and the pus drainage slowed. The patient was discharged on day 14 when cefazolin was

**Table 1** Antibacterial Sensitivity Test (MICroFAST 7), BECKMAN COULTER, United States) Results for *Streptococcus agalactiae* Cultured from the Pus Collected from the Patient's Scrotal Abscess

Drug	MIC	Interpretation
Ampicillin	0.12	Sensitive
Penicillin G	0.06	Sensitive
Amoxicillin/clavulanate	≤0.25	Not assessed
Cefotiam	≤0.5	Not assessed
Cefotaxime	≤0.12	Sensitive
Ceftriaxone	≤0.12	Sensitive
Cefepime	≤0.5	Sensitive
Cefditoren pivoxil	≤0.06	Not assessed
Cefozopran	≤0.12	Sensitive
Meropenem	≤0.12	Sensitive
Erythromycin	≤0.12	Sensitive
Clindamycin	≤0.12	Sensitive
Minocycline	≤0.5	Sensitive
Vancomycin	0.5	Sensitive
Chloramphenicol	≤4	Sensitive
Rifampicin	≤1	Not assessed
Sulfamethoxazole/trimethoprim	≤0.5	Not assessed
Levofloxacin	>8	Resistant
Azithromycin	≤0.25	Sensitive

**Abbreviation:** MIC, minimum inhibitory concentration (μg/mL).

discontinued and oral amoxicillin (750 mg/day) was commenced. In addition, the patient visited the hospital every week. We determined the need to continue antibiotics based on clinical symptoms. Amoxicillin was continued until day 42, and improvement was clinically confirmed.

## Discussion and Conclusions

We encountered a case of scrotal abscess due to *Prevotella bivia* and *Streptococcus agalactiae*. *Prevotella bivia* is predominantly associated with low-grade infections in the female urogenital tract, presenting as endometritis, pelvic inflammatory disease, or perirectal or anal abscess.<sup>3,4,27,28</sup> However, it can also cause infections in non-gynecological tissues.

Table 2 summarizes previous reports of *Prevotella bivia* infections as published in PubMed.<sup>6–23</sup> Similar to our case, the case presented by Bekasiak et al involved a scrotal abscess and co-infection with a second bacterial genus.<sup>11</sup> Additionally, co-infection occurred in 7 cases, including 2 cases with *Prevotella bivia* and *Streptococcus anginosus*, a well-known species that produces an abscess.<sup>2</sup> The presence of co-infectious bacteria is important for *Prevotella bivia* infections.

In particular, when *Prevotella bivia* and *Streptococcus agalactiae* are co-infectious, they reportedly have a 100% chance of causing infection in a mouse model.<sup>5</sup> Knowledge of other bacterial genera present is important when treating *Prevotella bivia* infections, since they may alter the pathogenicity of *Prevotella bivia*.<sup>29</sup> Abscesses occurred in seven of the 19 cases, including our case. The presence of abscess formation in approximately 37% of reported cases of *Prevotella bivia* infection is considered a non-negligible finding. *Prevotella bivia* infection should also be kept in mind when the patient has an abscess. In many cases shown in Table 2, metronidazole or clindamycin was the chosen treatment. *Prevotella bivia* is susceptible to these drugs, as well as to amoxicillin/clavulanate and imipenem.<sup>21,25</sup> However, our patient was successfully treated with cefazolin followed by oral amoxicillin. There are two possible reasons for this. First, the mixed infection by facultative anaerobe pathogen *Streptococcus agalactiae* is the factor that lowers the tissue oxygen tension and allows for the growth of anaerobic *Prevotella bivia* after eradication of the *Streptococcus agalactiae*, which was evidenced.<sup>5</sup> Second, *Prevotella bivia* strains in Japan may be sensitive to cefazolin and amoxicillin, whereas strains in other countries are resistant. In support of cefazolin sensitivity, a similar antibiotic (flomoxef) has exhibited effectiveness against *Prevotella bivia* in an experimental animal model in Japan.<sup>5</sup> Unfortunately, there was no drug susceptibility test for *Prevotella bivia* conducted in our case; thus, whether it was susceptible to cefazolin or amoxicillin is unknown.

Among the 19 patients in Table 2, five had no medical history, and 17 were 65 years old or younger. Thus, immunodeficiency and aging may not be risk factors for *Prevotella bivia* infection, as they are for cellulitis.<sup>30</sup> In Table 2, diabetes or obesity was observed in four of the 19 cases. Moreover, diabetes is common among Japanese people and thus may be a risk factor for *Prevotella bivia* infection.<sup>30</sup>

In conclusion, we encountered a case of scrotal abscess caused by *Prevotella bivia* and *Streptococcus agalactiae* in a Japanese patient. To the best of our knowledge, there have been no reported cases of *Prevotella bivia* infections in Japan. Therefore, we suggest that cephem antibiotics such as cefazolin may effectively treat *Prevotella bivia* in Japanese patients if incision and drainage are properly performed.

**Table 2** Summary of Previous Studies of *Prevotella bivia* Infections

Author	Diagnosis	Age	Co-Infection	Medical History	First Therapy	Second Therapy	Third Therapy
		Sex					
Grande-Del-Arco	Paronychia	38	<i>Staphylococcus haemolyticus</i>	Onychomycosis	Metronidazole (500 mg), cephalexin (500 mg), every 8 h per os	Moxifloxacin (400 mg/day for 2 weeks)	Rifampicin (600 mg/day)
		F					
Boucher	Nonpuerperal breast abscess	39	None	IgA nephropathy (Berger's disease), hypertension	Flucloxacillin (500 mg/6 h)	Amoxicillin/clavulanate (625 mg/8 h), metronidazole (500 mg 8 h)	None
		F					
Mohan	Renal and perinephric abscesses	26	<i>Lactobacillus jensenii</i>	Stable renal cyst	Cefepime, vancomycin	Ceftriaxone (2 g/day), metronidazole (500 mg/8 h)	None
		F					
Samantara	Intracranial abscess	50	Methicillin-resistant <i>Staphylococcus aureus</i>	Head trauma	Metronidazole	None	None
		M					
Bekasiak	Scrotal abscess	27	<i>Gardnerella vaginalis</i>	Obesity	Ceftriaxone (1 g/day)	Cephalexin (500 mg P.O., 4 times/day), metronidazole (500 mg, 3 times/day)	None
		M					
Kostov	Fulminant generalized peritonitis	39	None	None	Gentamicin (120 mg/12 h, i. m.), cefazolin (2 g every 12 h, i.v.), metronidazole (500 mg every 8 h, i.v.)	Metronidazole (500 mg every 8 h, i.v.)	None
		F					
Masadeh	Purulent proctitis	32	None	None (homosexual)	Ceftriaxone	Doxycycline, metronidazole	None
		M					
Di Marco Berardino	Empyema	78	None	Chronic obstructive pulmonary disease, chronic periodontitis	Levofloxacin (750 mg/day)	Intravenous clindamycin (600 mg/8 h)	Oral clindamycin (300 mg/6 h for 4 weeks)
		M					
Mirza	Paronychia	17	Methicillin-sensitive <i>Staphylococcus aureus</i>	None	Cefazolin	Oral ciprofloxacin	None
		F					
Mirza	Paronychia	55	<i>Enterococcus</i> spp., <i>Pseudomonas aeruginosa</i> and <i>melaninogenica</i>	None	Oral ciprofloxacin	Oral clindamycin	Oral ciprofloxacin
		F					
Janssen	Abdominal wall phlebitis	55	None	Diabetes mellitus, renal transplantation, haemodialysis, obesity	Metronidazole	Metronidazole, ceftriaxone	None
		F					

(Continued)

Table 2 (Continued).

Author	Diagnosis	Age	Co-Infection	Medical History	First Therapy	Second Therapy	Third Therapy
		Sex					
Lepivert	Necrotizing fasciitis	65	None	Diabetes mellitus	Intravenous vancomycin (2g/24 h), piperacillin/tazobactam (4g/h)	Intravenous amoxicillin-clavulanic acid (1g/6 h), levofloxacin (500 mg/12 h)	Oral amoxicillin/clavulanic acid, levofloxacin
		F					
Hsu	Chest wall abscess	77	None	None	Oral amoxicillin/clavulanate	None	None
		M					
Nalmas	Penile abscess	44	<i>Streptococcus constellatus</i>	Hypertension, obstructive sleep apnea, mild asthma	Intravenous vancomycin, clindamycin, cefepime	Intravenous vancomycin, clindamycin	Oral amoxicillin/clavulanate (875 mg, twice/day)
		M					
Huits	Lemierre's syndrome	17	None	None	Intravenous amoxicillin/clavulanic acid (1000/200 mg tds)	Benzyl-penicillin (6 million units tds IV), metronidazole (500 mg qid IV)	None
		F					
Riesbeck	Paronychia	45	$\beta$ -hemolytic streptococci group B, <i>Streptococcus milleri</i> group	Adiposity, non-insulin-dependent diabetes mellitus	Isoxazolyl penicillin	Intravenous cefuroxime, metronidazole	Oral clindamycin
		M					
Laiho	Septic arthritis	23	None	Juvenile rheumatoid arthritis	Imipenem (1000 mg)	None	None
		F					
Sagrìstà	Inguinal syndrome	34	None	None (unprotected sexual intercourse with a woman)	Doxycycline, ciprofloxacin	Oral amoxicillin/clavulanate	None
		M					
Our case	Scrotal abscess	41	<i>Streptococcus agalactiae</i> (group B)	Diabetes mellitus	Levofloxacin	Cefazolin	Oral amoxicillin
		M					

Abbreviations: F, female; M, male.

## Ethics Approval and Consent to Participate

Submission of this manuscript has been approved by the JR Tokyo General Hospital's ethics review board.

## Consent for Publication

We obtained written signed informed consent from the patient to publish his clinical details.

## Informed Consent

We obtained written signed consent from the patient to publish his clinical details.

## Acknowledgments

We would like to thank Editage ([www.editage.jp](http://www.editage.jp)) for English language editing.

## Author Contributions

All authors contributed to data analysis, drafting or revising the article, gave final approval of the version to be published, agreed to the submitted journal, and agree to be accountable for all aspects of the work.

## Funding

There is no funding to report.

## Disclosure

The authors report no conflicts of interest in this work.

## References

- Jeng A, Beheshti M, Li J, Nathan R. The role of beta-hemolytic streptococci in causing diffuse, nonculturable cellulitis: a prospective investigation. *Medicine (Baltimore)*. 2010;89(4):217–226. doi:10.1097/MD.0b013e3181e8d635
- Asam D, Spellerberg B. Molecular pathogenicity of *Streptococcus anginosus*. *Mol Oral Microbiol*. 2014;29(4):145–155. doi:10.1111/omi.12056
- Brook I, Frazier EH. The aerobic and anaerobic bacteriology of perirectal abscesses. *J Clin Microbiol*. 1997;35(11):2974–2976. doi:10.1128/jcm.35.11.2974-2976.1997
- Gossling J. Occurrence and pathogenicity of the *Streptococcus milleri* group. *Rev Infect Dis*. 1988;10(2):257–285. doi:10.1093/clinids/10.2.257
- Mikamo H, Kawazoe K, Izumi K, Watanabe K, Ueno K, Tamaya T. Studies on the pathogenicity of anaerobes, especially *Prevotella bivia*, in a rat pyometra model. *Infect Dis Obstet Gynecol*. 1998;6(2):61. doi:10.1002/(SICI)1098-0997(1998)6:2<61::AID-IDOG6>3.0.CO;2-A
- Holdeman LV, Johnson JL. *Bacteroides disiens* sp. nov. and *Bacteroides bivius* sp. nov. from human clinical infections. *Int J Syst Bacteriol*. 1977;27:337–345. doi:10.1099/00207713-27-4-337
- Grande-Del-Arco J, Jimenez-Cristino MD, García-de-la-peña R, Fernández-Espejo E, Córdoba-Fernández A, Rare A. Paronychia with superinfection with *Prevotella bivia* and *Staphylococcus haemolyticus*: the importance of early microbiological diagnosis. *Pathogens*. 2020;9(12):999. doi:10.3390/pathogens9120999
- Boucher A, Quaranta D, Emonet S, Serratrice J, Coen M. Nonpuerperal breast abscess due to *Prevotella bivia*. *Clin Case Rep*. 2020;8(8):1399–1402. doi:10.1002/ccr3.2824
- Mohan A, Rubin J, Chauhan P, Ramirez JL, Giese G. Renal and perinephric abscesses involving *Lactobacillus jensenii* and *Prevotella bivia* in a young woman following ureteral stent procedure. *J Commun Hosp Intern Med Perspect*. 2020;10(2):162–165. doi:10.1080/20009666.2020.1742494
- Samantaray S, Biswas R, Sasidharan GM. Intracranial abscess due to *Prevotella bivia*: first case report from India. *Anaerobe*. 2020;65:102249. doi:10.1016/j.anaerobe.2020.102249
- Bekasiak A, Dammann F, Nader C, Rare A. Cause of a scrotal abscess due to the symbiotic infection of *Gardnerella vaginalis* and *Prevotella bivia* in an adult male. *Pathogens*. 2020;9(2):93. doi:10.3390/pathogens9020093
- Kostov S, Slavchev S, Dzhnikov D, Strashilov S, Yordanov A. An unusual case of fulminant generalized peritonitis secondary to purulent salpingitis caused by *Prevotella bivia* - case report with literature review. *GERMS*. 2020;10(1):51–54. doi:10.18683/germs.2020.1185
- Masadeh M, Hossain S, Dunkelberg J, Gerke H. Purulent proctitis caused by *Prevotella bivia* in a homosexual male. *ACG Case Rep J*. 2016;3(4):e178. doi:10.14309/crj.2016.151
- Di Marco Berardino A, Inchingolo R, Smargiassi A, et al. Empyema caused by *Prevotella bivia* complicating an unusual case of spontaneous chylothorax. *J Clin Microbiol*. 2014;52(4):1284–1286. doi:10.1128/JCM.03282-13
- Mirza A, Bove JJ, Litwa J, Appelbe G. Mixed infections of the paronychium with *Prevotella bivia*. *J Hand Microsurg*. 2012;4(2):77–80. doi:10.1007/s12593-011-0054-7
- Janssen S, van Donselaar-van der Pant KA, van der Weerd NC, et al. Abdominal wall phlebitis due to *Prevotella bivia* following renal transplantation in a patient with an occluded inferior vena cava. *Infection*. 2013;41(1):271–274. doi:10.1007/s15010-012-0335-5
- Lepivert JC, Guinet V, Auquit-Auckbur I. Necrotizing fasciitis of the hand and wrist due to *Prevotella bivia*. *J Hand Surg Eur*. 2015;40(7):757–758. doi:10.1177/1753193414545942
- Hsu GJ, Chen CR, Lai MC, Luh SP. Chest wall abscess due to *Prevotella bivia*. *J Zhejiang Univ Sci B*. 2009;10(3):233–236. doi:10.1631/jzus.B0820289
- Nalmas S, Bishburg E, Chan T. *Streptococcus constellatus* and *Prevotella bivia* penile abscess. *Scientific World J*. 2007;7:1631–1633. doi:10.1100/tsw.2007.240
- Huits RM, van Assen S, Wildeboer-Veloo AC, Verschuuren EA, Koeter GH. *Prevotella bivia* necrobacillosis following infectious mononucleosis. *J Infect*. 2006;53(2):e59–e63. doi:10.1016/j.jinf.2005.10.016
- Riesbeck K. Paronychia due to *Prevotella bivia* that resulted in amputation: fast and correct bacteriological diagnosis is crucial. *J Clin Microbiol*. 2003;41(10):4901–4903. doi:10.1128/JCM.41.10.4901-4903.2003
- Laiho K, Kotilainen P. Septic arthritis due to *Prevotella bivia* after intra-articular hip joint injection. *Joint Bone Spine*. 2001;68(5):443–444. doi:10.1016/S1297-319X(01)00303-7
- Sagrístà M, Martín-Ezquerro G, Gallardo F, et al. Inguinal syndrome secondary to *Prevotella bivia* after accidental bite in orogenital sex. *Sex Transm Infect*. 2012;88(4):250–251. doi:10.1136/sextrans-2011-050348
- Wybo I, Piérard D, Verschraegen I, et al. Third Belgian multicentre survey of antibiotic susceptibility of anaerobic bacteria. *J Antimicrob Chemother*. 2007;59(1):132–139. doi:10.1093/jac/dkl458
- Stein GE, Schooley S, Tyrrell KL, Citron DM, Goldstein EJ. Human serum activity of telithromycin, azithromycin and amoxicillin/clavulanate against common aerobic and anaerobic respiratory pathogens. *Int J Antimicrob Agents*. 2007;29(1):39–43. doi:10.1016/j.ijantimicag.2006.08.041
- Johnson AP, Davies J, Guy R, et al. Mandatory surveillance of methicillin-resistant *Staphylococcus aureus* (MRSA) bacteraemia in England: the first 10 years. *J Antimicrob Chemother*. 2012;67(4):802–809. doi:10.1093/jac/dkr561
- Jousimies-Somer H. Recently described clinically important anaerobic bacteria: taxonomic aspects and update. *Clin Infect Dis*. 1997;25(Suppl 2):S78–S87. doi:10.1086/516227
- Strömbeck L, Sandros J, Holst E, et al. *Prevotella bivia* can invade human cervix epithelial (HeLa) cells. *APMIS*. 2007;115(3):241–251. doi:10.1111/j.1600-0463.2007.apm\_512.x
- Brook I. The role of anaerobic bacteria in tonsillitis. *Int J Pediatr Otorhinolaryngol*. 2005;69(1):9–19. doi:10.1016/j.ijporl.2004.08.007
- Norimatsu Y, Ohno Y. Predictors for readmission due to cellulitis among Japanese patients. *J Dermatol*. 2021;48(5):681–684. doi:10.1111/1346-8138.15771

### International Medical Case Reports Journal

Dovepress

#### Publish your work in this journal

The International Medical Case Reports Journal is an international, peer-reviewed open-access journal publishing original case reports from all medical specialties. Previously unpublished medical posters are also accepted relating to any area of clinical or preclinical science. Submissions should not normally exceed 2,000 words or 4

published pages including figures, diagrams and references. The manuscript management system is completely online and includes a very quick and fair peer-review system, which is all easy to use. Visit <http://www.dovepress.com/testimonials.php> to read real quotes from published authors.

Submit your manuscript here: <https://www.dovepress.com/international-medical-case-reports-journal-journal>