



Functional and Structural Changes Following Corneal Neurotisation in the Management of Neurotrophic Keratopathy: UK Single Centre Series

Mohamed Elalfy ^{1,2}
 Sundas Maqsood ¹
 Scott Hau³
 Ruben Y Kannan⁴
 Charles Nduka⁴
 Samer Hamada¹
 Raman Malhotra¹

¹Corneo Plastic Unit, Queen Victoria Hospital, East Grinstead, UK; ²Research Institute of Ophthalmology, Giza, Egypt; ³Moorfields Eye Hospital, London, UK; ⁴Plastic Surgery Department, Queen Victoria Hospital, East Grinstead, UK

Objective: To report the functional and anatomical outcomes including structural changes in corneal nerve density and morphology using in vivo confocal microscopy (IVCM) after corneal neurotisation in patients with neurotrophic keratopathy (NK), using a sural nerve graft.

Patients and Methods: Prospective study of patients undergoing corneal neurotisation for NK. Functional outcomes were measured through visual acuity, slit-lamp examination of corneal and conjunctival staining, tear production (Schirmer's 1 test), tear film break-up time, tear film meniscus height, quality and osmolarity, central corneal thickness and corneal sensation using Cochet–Bonnet esthesiometry. Structural outcomes were assessed from changes in corneal nerve density and morphology with IVCM. Subjective outcomes were assessed using VFQ-25 and latest telephonic consultation.

Results: Between February 2016 and April 2018, 11 corneal neurotisations were performed on 11 patients (3 males, 8 females). Median age was 43 (range 25–62) years. Mean follow-up was 14.5 (range, 4–36) months. Snellen visual acuity improved in 6 patients, corneal and conjunctival staining decreased in 10, tear film breakup time increased in 9, tear meniscus height increased in 7, Schirmers test readings increased in 4, tear film osmolarity reduced in 8 and central corneal thickness increased in 10 patients. Corneal sensation improved in nine patients. Complete IVCM data were available in five cases and demonstrated an improvement of corneal nerve density and length at 12 months.

Conclusion: This series confirms the fact that the outcomes of this technique are reproducible and that corneal neurotisation surgery helps restore trophic nerve function more consistently than touch-related sensation.

Keywords: corneal neurotisation, neurotrophic keratopathy, sural nerve, corneal sensations

Introduction

The management of neurotrophic keratopathy is challenging due to an impaired blink reflex, abnormal epithelial healing complicated by recurrent epithelial breakdown, persistent epithelial defects, neurotrophic ulcers, chronic corneal scarring and corneal perforation.^{1–5} Targeted medical and surgical modalities have been proposed to halt the progression of the disease at early stages to prevent globe threatening complications. Therefore, improving underlying corneal anesthesia is of utmost significance in successful long-term management of neurotrophic keratopathy.

Correspondence: Mohamed Elalfy
 Research Institute of Ophthalmology,
 El-Khalifa, Oula, Giza, 12557, Egypt
 Tel +20235718304
 Email m.s.elalfy@gmail.com

Corneal neurotisation surgery aims at regaining the structure and function of corneal nerves, leading to regaining corneal sensation and epithelial trophic functions.^{6–8} Its concept was introduced by Samii in 1972 and described in his textbook in 1981.⁹ In 2009, Terzis et al described a novel surgical approach of direct corneal neurotisation using contralateral supratrochlear and supraorbital nerves in patients with unilateral facial nerve palsy.⁶ Elbaz et al in 2014 evaluated the efficacy of corneal neurotisation utilizing sural nerve graft in bilateral cases of neurotrophic corneas.⁷ Minimally invasive techniques using direct nerve transfer is also emerging.¹⁰ A recent study comparing the outcomes of direct corneal neurotisation (DCN) with indirect corneal neurotisation (ICN) confirmed comparable outcomes.¹¹

In vivo confocal microscopy (IVCM) has been used extensively in analyzing corneal nerves in health and disease.¹² The aim of this retrospective study was to evaluate the functional changes of the cornea and ocular surface, and the IVCM structural changes in corneal nerve density and morphology after corneal neurotisation surgery. We report herein the functional and anatomical outcomes of 11 patients with neurotrophic keratopathy who underwent corneal neurotisation surgery.

Patients and Methods

A prospective, non-comparative, consecutive case series of patients with neurotrophic keratopathy undergoing corneal neurotisation surgery between February 2016 and April 2018 at Queen Victoria Hospital, East Grinstead, UK, was conducted. All patients operated during this period were included.

The study was approved as a prospective audit by the local institutional review board and adhered to the tenets of the Declaration of Helsinki. Surgery was performed by a multi-disciplinary team of corneal, oculoplastic and plastic surgeons.

Patients who were selected and consented for corneal neurotisation were considered to have significant ocular morbidity secondary to irreversible neurotrophic keratopathy, and had already undergone failed conservative medical and surgical treatments. All patients included in the study had episodes of recurrent persistent epithelial defects or corneal ulceration aggressively treated with conventional therapy including temporary tarsorrhaphy, with corneal neurotisation procedure performed once their ocular surface were stabilized. All patients had 0 corneal sensation on Cochet–Bonnet aesthesiometer before surgery and

full corneal sensation in the contralateral eye. Objective evidence for worsening keratopathy despite conventional treatment modalities included reduced visual acuity, tear film breakup time (TFBT), tear meniscus height, tear film quality and osmolarity, corneal thickness and increased corneal and conjunctival staining.

The functional outcomes therefore included bilateral assessment of visual acuity, slit-lamp examination of corneal and conjunctival staining using fluorescein sodium 1% eye drops, tear production (Schirmer's 1 test), tear film break-up time, tear film meniscus height, quality and osmolarity using TearLab[®], CA, USA, central corneal thickness using Pentacam[®] HR scan, Oculus, WA, USA and measurement of corneal sensation using Cochet–Bonnet esthesiometer, Luneau Technology, France.

The structural outcomes were assessed for changes in corneal nerve density and morphology by IVCM. Both functional and structural outcomes were measured preoperatively and at early (1–3 months), intermediate (3–6 months) and late (9–12 months and more) postoperative periods.

Subjective results were collected from patients using National Eye Institute visual functioning questionnaire –25 (NEI VFQ-25) version 2000.¹³ The questionnaire explored the general health, vision, difficulties with activities (near, distance, driving) and responses to vision problems (levels of disability, discomfort and psychosocial impact). Subjective outcomes were also assessed by a questionnaire survey of patients reporting frequency of lubricants, visits to the hospital up to 6 months after surgery and the frequency of corneal ulcers 2 years before and up to 6 months after surgery.

Surgical Technique

The surgical technique is clearly outlined in our review.¹⁰ It is similar to that currently carried out and advised by Drs Borschel, Zuker and Ali.^{7,8} The sural nerve was harvested and then reversed, for grafting. It is harvested proximally to distally, using a nerve harvesting device placed around the nerve and passed distally, freeing the nerve from surrounding tissues. The length harvested was approximately 10 to 15 cm long, and the peroneal component of the nerve was preserved. The supratrochlear nerve was accessed through a skin-crease incision (helps avoid a visible eyelid scar), extended medially, and pre-septal /sub-orbicularis dissection to expose the superior orbital rim to find the nerve as it exits the orbit through the supratrochlear notch. In some cases, the nerve may exit

from a bony foramen. If the supratrochlear nerve is considered too thin then the supraorbital nerve is located. The selected nerve is divided to allow end-to-end coaptation. Coaptation was performed using 10-0 nylon sutures and fibrin glue (Tisseel). In unilateral cases, the contralateral supratrochlear or supraorbital nerve was used, requiring tunneling of the reversed nerve graft over the nasal bridge to the perilimbal area of the cornea.

On the ipsilateral anesthetic cornea side, the orbital septum is dissected through a skin-crease incision to expose the post-septal space. By blunt dissection, a submuscular, preperiosteal tunnel over the nasal bridge is made to connect both upper eyelid skin-crease incisions. A size 10 suction tube is passed through this tunnel. The reversed sural nerve end is placed into the orifice of the tube, and using suction from the anesthetic cornea end, it is atraumatically passed from the contralateral side for it then to be transferred to the conjunctival fornix via a supratarsal blepharotomy medial to levator palpebrae superioris.

Distally, under the ophthalmic operating microscope view, the epineurium was removed and the individual fascicles were separated. In order to minimize handling and trauma to fascicles, we handle the distal most tip of each fascicle when passing subconjunctivally. This tip is then trimmed off to leave a freshly cut end. The four to five fascicles are each inserted into pre-prepared corneoscleral lamella tunnels around the entire limbal circumference and secured with fibrin glue (Tisseel). Placement in these tunnels is an attempt to facilitate more direct nerve-to-nerve coaptation.

One or two fascicles are left in the perilimbal sub-Tenon's space either at 3 or 9 o'clock, within the area of the palpebral aperture and secured with fibrin glue in an attempt to restore sensation to the bulbar conjunctiva in the region of the palpebral aperture.

Since our first eight cases, we have now begun wrapping amniotic membrane around the coaptation of a reversed sural nerve graft to the supraorbital or supratrochlear nerve. The amniotic membrane is placed basement-membrane face down around the nerve. Amniotic membrane has an abundance of neurotrophic factors, particularly NGF, which may also contribute to promoting nerve regeneration.

We do not use lateral tarsorrhaphies and simply pad the anesthetic eye overnight. Topical lubricants and chloramphenicol drops were prescribed in all cases.

Surgical time has gradually been reduced from up to 5 hours to 3 hours, largely thanks to two surgeons

concurrently harvesting the sural nerve and exposing the supratrochlear and supraorbital nerves and ipsilateral blepharo-conjunctival route.

Technique for Nerve Regeneration Analysis via IVCM

IVCM was performed on the operated eye in five subjects by a single experienced observer (SH) with the HRT II/RCM (Heidelberg Engineering GmbH, Dossenheim, Germany) confocal microscope following a Standard Operating Procedure. A sterile Tomocap (Heidelberg Engineering GmbH, Dossenheim, Germany) was mounted over the objective of the microscope and carbomer gel 0.2% (GelTears, Bausch & Lomb UK Limited) was used as a coupling agent between the cap and the lens objective. A drop of topical anesthetic (proxymetacaine hydrochloride 0.5%, Bausch & Lomb UK Limited) and carmellose sodium (Celluvisc 1%, Allergan, Ireland) was instilled into the eye being examined. Ten non-overlapping images of the central cornea at the level of the sub-basal nerve plexus, that is, immediately at or posterior to the basal epithelial layer and anterior to Bowman's layer at a depth of 40–60 μm , were obtained. A custom-made fixation target was used for maintaining fixation, using the unaffected contralateral eye, during image acquisition. To ensure the same part of the cornea was scanned at follow-up visit, the subject was asked to look at the same fixation target for each subsequent image acquisition appointment. A good quality image was defined as an image with the highest number of well-defined sub-basal nerves, with maximal contrast, and without any distortion or folds. Stromal nerves were not analyzed because of the variability in the way they appear in the stroma making accurate quantification of the nerves difficult. All the images were analyzed by an experienced confocal microscopy operator (SH). The sub-basal nerve fibre density was analyzed using the ACCMetrics corneal nerve fiber analyzer (CNFA) V.25,6 and the following nerve parameters were defined: nerve fiber density (CNFD) - number of main nerve fibers per mm^2 , nerve branch density (CNBD) - number of main branches per mm^2 , nerve fiber length (CNFL) - total length of all nerves in the image mm/mm^2 , and total branch density (CTBD) - total number of branch points per mm^2 . The wavelength of the laser employed in the HRT II/RCM is 670 nm and the microscope provides en-face sections of the cornea. Each standard two-dimensional image consists

of 384×384 pixels covering an area of 400 μm x 400 μm with the lateral resolution of 1–2 μm/pixel and axial resolution of 4 μm.

Results

Corneal neurotisation was performed on 11 eyes of 11 patients (3 males, 8 females). The cause of corneal neurotrophic keratopathy for each patient is shown in Table 1. Median age was 43 (range 25–62) years. Mean follow-up was 14.5 (range, 4–36) months.

Five patients received sural nerve graft from the contralateral side and six patients from the ipsilateral side. Patient 4 had corneal neovascularization, patient 2 had corneal scarring and patients 7, 8 and 11 had superficial corneal scarring preoperatively. No other ocular comorbidities were detected in any of the patients that could affect the final visual outcome. Figure 1 shows preoperative neurotrophic keratopathy demonstrated by scarring and punctate keratopathy improving to clear cornea and improving corneal sensations in patient 6.

Variation in Sural Nerve Graft Coaptation

All patients underwent end-to-end nerve coaptation. Four patients had both supratrochlear and supraorbital nerves coapted, four had supraorbital nerve only and three with supratrochlear nerve only. In the last three cases of our series, amniotic membrane was also wrapped around the coaptation.

Functional outcome data are summarized in Table 2. Vision (Snellen acuity) improved in six patients, stabilized in three patients and deteriorated in two patients at the last follow-up compared to preoperative status. Corneal and conjunctival staining decreased in 91% of the patients (Figure 2). Tear film breakup time (TFBT) increased in 82%, tear meniscus height increased in 64%, Schirmers test reading increased in 36% and remained stable in 64% of the patients, tear film osmolarity reduced in 73%, central corneal thickness increased in 91% of the patients. Corneal sensation assessed by Cochet–Bonnet esthesiometry improved in 73% of the patients. Late recovery of corneal sensation was noted in one patient where corneal sensation improved from 0 to 10 at 24 months, having been recorded 0 at 6 and 12 months post corneal neurotisation.

No significant difference in either rate or extent of nerve function recovery was observed in the three cases who underwent wrapping of amniotic membrane over the nerve graft coaptation.

Table 1 Patient Demographics, Characteristics and Aetiology of Neurotrophic Keratopathy (NK)

	Patient 1	Patient 2	Patient 3	Patient 4	Patient 5	Patient 6	Patient 7	Patient 8	Patient 9	Patient 10	Patient 11
Sex/Age	F/40	M/28	F/46	M/61	F/60	M/43	F/38	F/62	F/51	F/25	F/38
Eye	Left	Left	Left	Left	Left	Left	Right	Left	Left	Left	Right
Aetiology	Posterior fossa infarction	Traumatic multiple cranial nerve palsy	Vestibular Schwannoma	Traumatic multiple cranial nerve palsy	Ethmoidal carcinoma and craniofacial Resection	Cerebral vascular accident	Vestibular schwannoma	Vestibular schwannoma	Polynuropathy due to chemotherapy	Herpes simplex keratitis	Trigeminal schwannoma
Surgery	Jan 2016	Feb 2016	Jun 2016	Jan 2017	May 2017	Jun 2017	Jul 2017	Sep 2017	Nov 2017	Feb 2018	Apr 2018
Surgical approach	Supraorbital (end to end)	Supraorbital +supratrochlear (end to end)	Supratrochlear (end to end)	Supraorbital +supratrochlear (end to end)	Supraorbital +supratrochlear(end to end)	Supraorbital (end to end)	Supraorbital (end to end)	Supratrochlear (end to end)	Supratrochlear (end to end) +AMT	Supraorbital (end to end) +AMT	Supraorbital +supratrochlear (end to end) +AMT
Follow-up	18 months	36 months	12 months	18 months	9 months	15 months	9 months	12–24 months	9 months	4 months	8 months

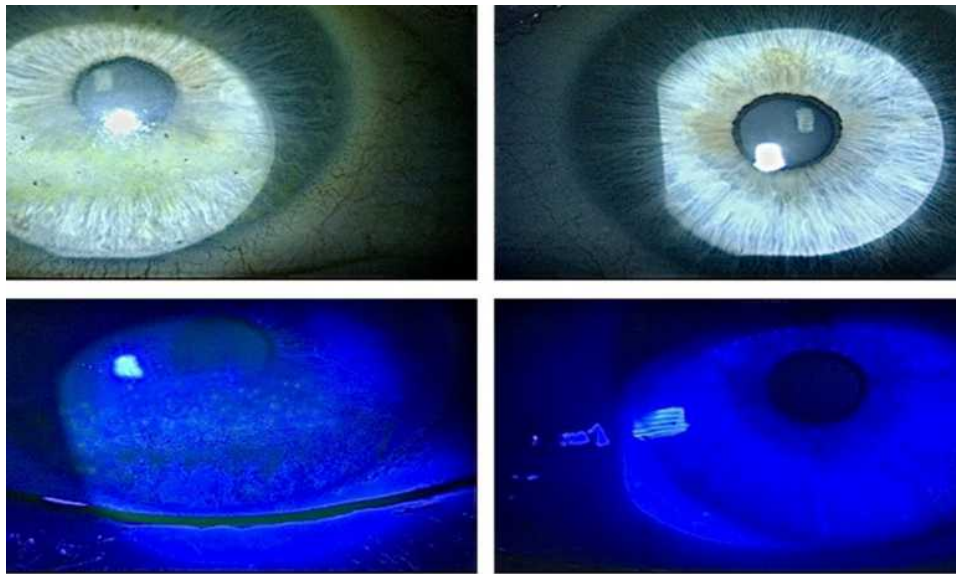


Figure 1 Preoperative neurotrophic keratopathy demonstrated by scarring and punctate keratopathy with improvement in corneal sensations and clear cornea in patient 6.

No intraoperative or post complications were observed in any patients at both donor and recipient sites.

Nerve Analysis

The IVCN nerve analysis was performed on five patients (patients 2, 3, 4, 5 and 7) (Table 3) who attended their scanning appointments. The remaining cohort did not manage to attend for the IVCN scan due to the long distance they had to travel to Moorfields Eye Hospital.

A scan was not performed on patient 5 at 12 months because she needed eyelid surgery for lagophthalmos. Apart from this patient, where the measurements seem to have decreased over time, the remainder of patients' scans demonstrated a general improvement of nerve parameters, including corneal nerve density and length from preoperatively, with patient 7 demonstrating the greatest improvement in corneal nerve parameters (Figure 2).

Table 4 and Figure 3 show the mean change in values compared to preoperatively and the nerve parameter showing the biggest increase was CTBD. Apart from patients 5 and 4, both CNFD and CNFL were higher in the other subjects at the 12 months compared to preoperatively.

Subjective Improvement

All these patients had total loss of corneal sensation before surgery. One patient had some corneal sensation restored at 6 weeks, one patient at 3 months, two patients at 6 months, two at 9 months, two patients at 12 months and one at 18 months. Table 4 shows the frequency of

lubricants use 6 months postoperatively, the frequency of hospital visits in the first 6 months, postoperatively and the corneal ulcer rate at 2 years before and 6 months postoperatively. Three (27%) patients reported a reduction in their use of their ocular lubricants from hourly to 4-hourly following neurotisation, while the remainder reported no change in frequency from before neurotisation surgery. In five patients, the frequency of hospital visits reduced postoperatively, but no change in frequency in the remainder except for one patient (patient 5) who had an increase in the number of their visits. No patient developed any further corneal ulcers following the procedure.

VFQ-25

The questionnaire explores the general health, vision, difficulties with activities (near, distance, driving) and responses to vision problems (levels of disability, discomfort and psychosocial impact).¹³ Eight patients completed the pre-neurotisation questionnaire and six patients completed both pre- and post-neurotisation. One patient out of six reported overall vision to remain poor; the remaining five reported it to be between fair and good, postoperatively. Despite neurotrophic keratopathy, all patients were reported to have moderate ocular discomfort, preoperatively. Four improved to mild discomfort and three continued to experience moderate discomfort, postoperatively. Reading improved in four patients from being extremely and moderately difficult, preoperatively to no or mild difficulty, post-operatively. The remaining two

Table 2 Functional Outcome Data of Patients with Neurotrophic Keratopathy

	Patient 1	Patient 2	Patient 3	Patient 4	Patient 5	Patient 6	Patient 7	Patient 8	Patient 9	Patient 10	Patient 11
Vision (Snellen)	6/12 → 6/18	6/36 → 6/18	6/30 → 6/15	CF → 4/60	6/15 → 6/15	6/36 → 6/24	6/12 → 6/7.5	6/15 → 6/9	6/12 → 6/24	6/6 → 6/6	6/7.5 → 6/7.5
Corneal Staining (Oxford grade)	III → I	IV → I	III → 0	III → I	II → I	II → I	II → II	II → I	II → 0	II → I	I → 0
TFBT (sec)	3 → 5	5 → 8	4 → 7	2 → 5	1 → 4	3 → 4	8 → 4	4 → 10	1 → 5	1 → 3	2 → 10
TMH (mm)	0.2 → 0.8	0.8 → 1.5	0.5 → 1	0.5 → 0.5	0.5 → 0.6	0.5 → 1	0.1 → 0.6	0.5 → 0.5	0.6 → 0.6	0.2 → 0.2	1 → 2
Schirmer (mm)	14 → 14	7 → 18	10 → 14	5 → 5	12 → 12	8 → 18	10 → 10	12 → 12	5 → 5	15 → 24	10 → 10
Tear Osmolarity (mOsmol/L)	279 → 281	276 → 277	278 → 267	289 → 276	292 → 208	288 → 288	306 → 291	374 → 323	276 → 276	328 → 315	299 → 293
Pachymetry (micrometer)	462 → 520	360 → 448	553 → 543	456 → 466	553 → 560	540 → 557	501 → 526	557 → 596	521 → 529	499 → 499	523 → 527
Cochet-Bonnet Corneal Sensation (mm)	0 → 10	0 → 60	0 → 10	0 → 0	0 → 50	0 → 10	0 → 0	0 → 10	0 → 30	0 → 50	0 → 10

Abbreviations: AMT, amniotic membrane; CF, counting fingers; F, female; M, male; TFBT, tear film break-up time; TMH, tear meniscus height.

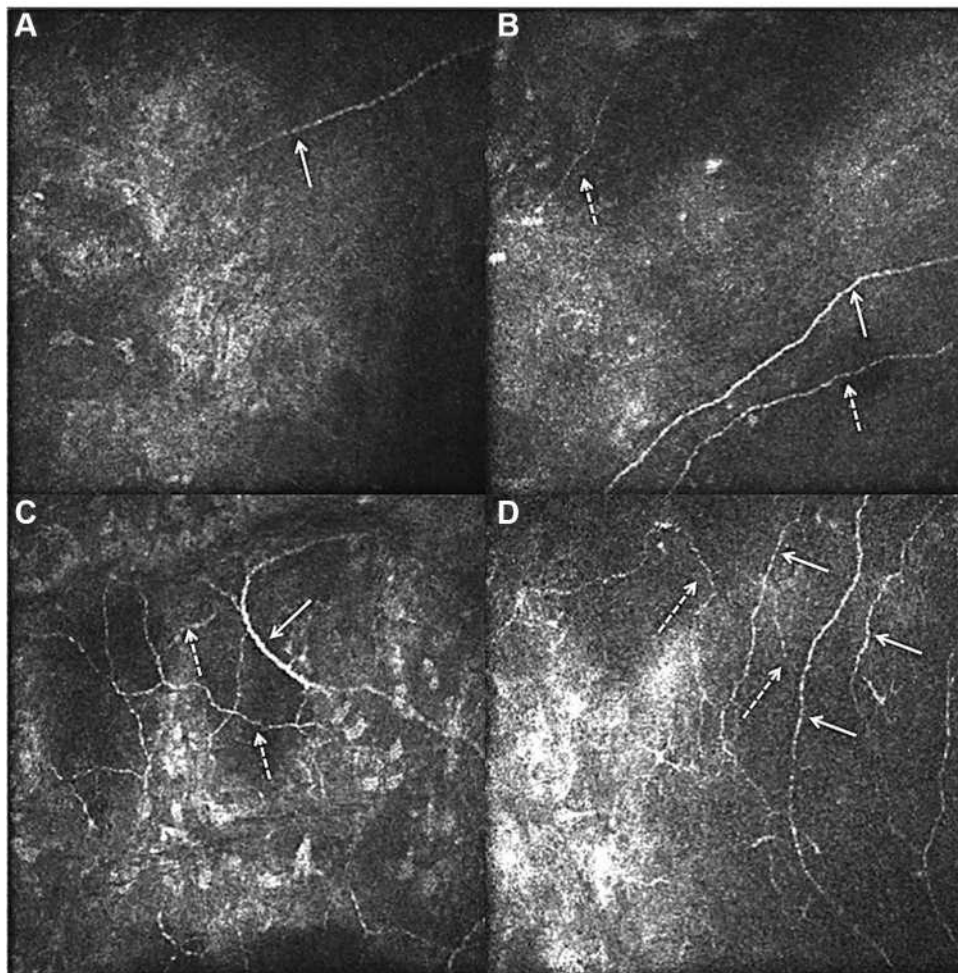


Figure 2 In vivo confocal microscopy images of the subbasal nerve plexus for patient 7 taken at 50µm depth- Pre op presence of one main nerve fibre (arrow) (A); one main nerve fibre (arrow) and nerve branches (dotted arrow) at 3 month (B); one main nerve fibre (arrow) and multiple nerve branches (dotted arrow) at 6 month (C); three main nerve fibres and multiple nerve branches at 12 month (D) after corneal neurotisation surgery (-: main nerve, -: nerve branches showing nerve regeneration).

patients reported no change in difficulty reading. Two patients were reported to have given up driving due to visual reasons, preoperatively. This remained unchanged. Four patients reported no or mild difficulty with distance vision, postoperatively. All six patients reported discomfort, limitation of activities and psychosocial impact of the disease as most of the time, preoperatively. These all improved to none or some time, postoperatively.

Discussion

Neurotrophic keratopathy (NK) can present as a broad spectrum of changes at the level of ocular surface, ranging from superficial punctate keratopathy to corneal melting and perforation.¹⁴ Based on the site and nature of the fifth nerve damage, some corneas still maintain to

have trophic functions despite hypoesthesia and would not develop hallmark signs and symptoms of neurotrophic keratopathy described by Mackie.¹⁵ According to NK severity, the management can be followed in a step-wise approach starting from preservative free tear substitute to newer topical therapies like serum-derived agents and nerve growth factors, which in two trials published in 2018, have shown to incite and enhance nerve regeneration in corneas with moderate to severe NK.^{16,17} Cenegermin (recombinant form of human nerve growth factor) has been approved in Europe for treatment of NK but has not been declared cost effected by NICE (July 2018) and is not available in the UK. Surgical therapies to optimize lid closure and keratoplasty is reserved for much complex cases with their

Table 3 Nerve Parameters of Five Patients with IVCN Data

Subject	Mean Corneal Nerve Parameters and Duration Post-Surgery																			
	Preop					3 Months					6 Months					12 Months				
	NFD	NBD	NFL	TBD		NFD	NBD	NFL	TBD		NFD	NBD	NFL	TBD		NFD	NBD	NFL	TBD	
Patient 2	0 (0)	0 (0)	0 (0)	0 (0)		4.1 (2.9)	10.4 (7.8)	4.9 (1.2)	20.8 (7.8)		4.7 (8.1)	6.3 (10.8)	7.6 (2.8)	20.3 (20.9)		3.1 (3.1)	4.7 (8.1)	8.1 (2.1)	21.9 (16.8)	
Patient 3	0 (0)	0 (0)	0.2 (0.3)	0 (0)		0 (0)	0 (0)	3.4 (0.4)	3.1 (5.4)		4.7 (2.7)	7.8 (8.1)	6.5 (1.1)	21.8 (13.6)		6.2 (0.1)	1.6 (2.7)	6.5 (0.9)	15.6 (14.3)	
Patient 4	0 (0)	0 (0)	0.9 (0.8)	3.1 (3.1)		0 (0)	0 (0)	3.1 (0.5)	3.1 (2.1)		1.6 (2.7)	0 (0)	3.1 (1.4)	3.1 (3.1)		0 (0)	0 (0)	4.3 (0.6)	10.9 (9.2)	
Patient 5	7.8 (2.8)	26.5 (19.4)	8.6 (1.5)	42.1 (17.4)		1.6 (2.7)	0 (0)	5.1 (1.9)	7.8 (6.8)		0 (0)	0 (0)	4.9 (1.6)	21.8 (6.9)		NA	NA	NA	NA	
Patient 7	9.4 (3.2)	0 (0)	4.7 (0.8)	3.1 (5.4)		20.3 (9.2)	4.7 (5.2)	12.8 (1.6)	18.7 (4.4)		6.2 (0)	18.7 (8.8)	11.2 (1.5)	56.2 (25.4)		19.9 (4.2)	19.2 (4.5)	11.6 (3.1)	58.3 (4.5)	

Note: Values in parenthesis = standard deviation.
Abbreviations: NFD, nerve fibre density in number of fibers/mm²; NBD, nerve branch density in number of branches/mm²; NFL, nerve fibre length in mm/mm²; TBD, total branch density per mm².

Table 4 Nerve Parameters (Mean Change of Nerve Parameters) for the Five Patients at Different Postoperative Time Points

	3 Months				6 Months				12 Months			
	NFD	NBD	NFL	TBD	NFD	NBD	NFL	TBD	NFD	NBD	NFL	TBD
Patient 2	4.1	10.4	4.9	20.8	4.7	6.3	7.6	20.3	3.1	4.7	8.1	21.9
Patient 3	0	0	3.2	3.1	4.7	7.8	6.3	21.8	6.2	1.6	6.3	15.6
Patient 4	0	0	2.2	0	1.6	0	2.2	0	0	0	3.4	7.8
Patient 5	-6.2	-26.5	-3.5	-34.3	-7.8	-26.5	-3.7	-20.3	NA	NA	NA	NA
Patient 7	10.9	4.7	8.1	15.6	-3.2	18.7	6.5	53.1	10.5	19.2	6.9	55.2

Abbreviations: NFD, nerve fibre density per mm²; NBD, nerve branch density per mm²; NFL, nerve fibre length in mm/mm²; TBD, total branch density per mm²; NA, not available.

outcomes strongly influenced by the poor corneal sensations with them not addressing the root cause of the disease.¹⁸

We report the functional and anatomical outcomes through IVCM structural changes in corneal nerve density and morphology after corneal neurotisation surgery in 11 patients with neurotrophic keratopathy, using a sural nerve graft with end-to-end coaptation to the contralateral supra-trochlear and supraorbital nerves. This represents the second largest series to date, the largest in the UK and second

only to that recently reported by the original authors of this particular technique,¹⁹ and a larger number of IVCM outcomes following corneal neurotisation. Our series confirms that outcomes of this technique are reproducible and that restoration of trophic nerve function is more consistent than touch-related sensation.

In this study, corneal sensation assessed by Cochet-Bonnet aesthesiometer readings improved in 9 of the 11 patients. This finding is consistent with previous studies reporting an improvement in corneal sensation as the

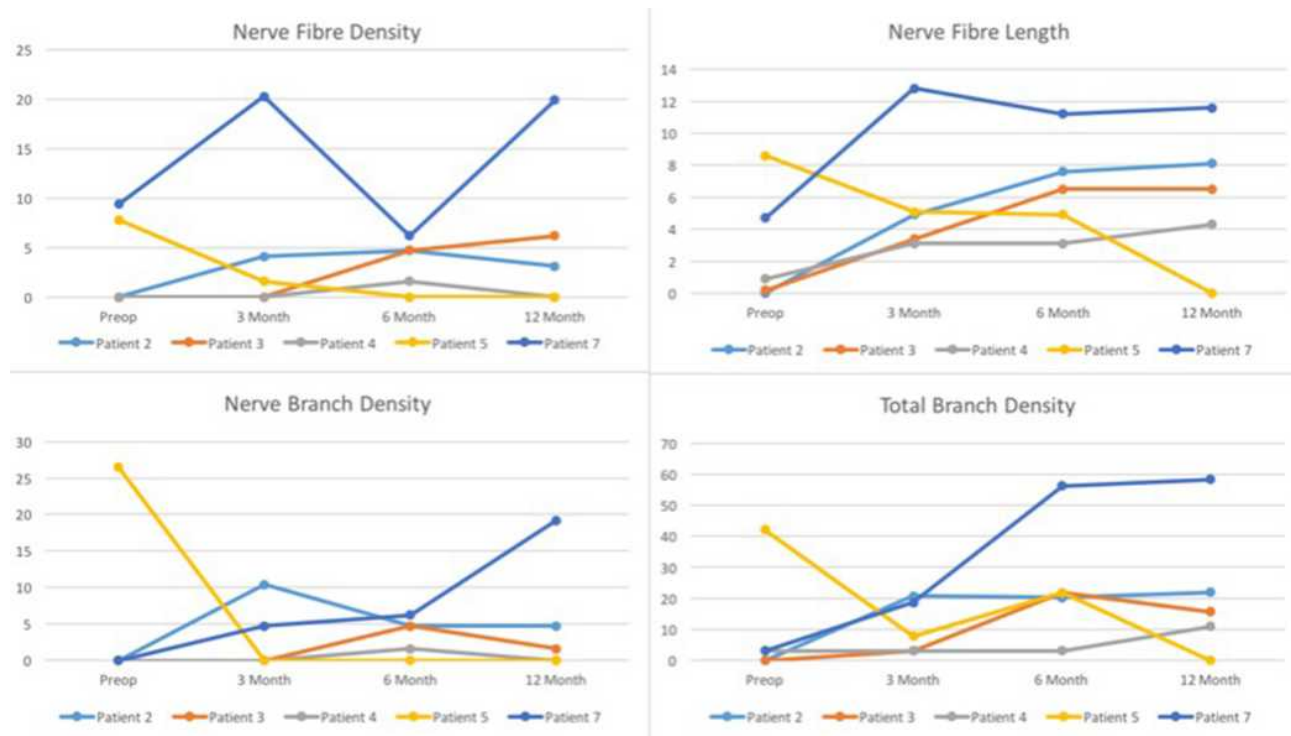


Figure 3 Nerve parameters (nerve fiber density, nerve fiber length, nerve branch density and total branch density) in patients 2, 3, 4, 5 and 7 improving from preoperative to early (3 month), intermediate (6 months) and late (12 months) postoperative follow-up.

primary outcome measure. Two patients (patients 4 and 8), did not show any improvement in corneal sensations despite the improvement in visual acuity and ocular surface parameters. This interesting finding can be explained by the hypothesis that corneal neurotisation surgery improves corneal trophic functions independent of corneal sensations through nerve growth factors. Outcomes of TFBT showed improved in 9 patients, tear meniscus height improved in 7 patients, Schirmer's test reading improved in 4 patients and remained stable in 7 patients, tear film osmolarity improved in 8 patients, while central corneal thickness improved in 10 patients. To the best of our knowledge, improvement in tear film quality and corneal thickness after corneal neurotisation has not been previously studied. Amniotic membrane is widely used in cases of severe and ocular surface diseases due to the anti-inflammatory effect and the presence of neurotrophic factors.^{20,21} Three patients in our series received amniotic membrane to wrap the nerve graft coaptation. No significant difference in either rate or extent of nerve function recovery was observed in these cases. However, a larger series is required to reliably draw any conclusions whether there is any benefit in the use of amniotic membrane and its influence on nerve growth factors in corneal neurotisation surgery in humans.^{22,23}

In vivo confocal microscopy is currently the mainstay for real-time examination of the human cornea and conjunctiva at a cellular level.^{24,25} We were able to scan and analyze corneal nerves in five patients. Apart from one of the subjects who needed surgery at 12 months, all the other subjects demonstrated a general improvement in nerve parameters including sub-basal nerve density and length, with subject 7 demonstrating the greatest increase. The confocal images of patient 5 however showing an overall reduction in all corneal nerve parameters from preoperative stage to 6 months postoperative stage could imply that the corneal neurotisation process has not occurred in this patient. Fung et al²⁵ showed growth of corneal nerves in two cases in their study for the first time using IVCN. Ting et al²⁶ also used IVCN to assess corneal nerves postoperatively with only one of his study subjects who had detectable sub-basal and stromal corneal nerves. Despite encouraging improvement in nerve parameters starting at 3 months postoperative stage, the rate of increase seems to have plateaued, especially with NFD, with no further increase seen at 12 months. While our observation of one patient (patient 8) regaining sensation (as assessed by Cochet-

Bonnet esthesiometry) at 18 months suggests that nerve growth continues to occur beyond 12 months, further longitudinal studies are needed to establish whether nerve growth is maintained beyond 1 year as well as long-term survival of these nerves, given that return of complete corneal anesthesia at 2 years despite earlier recovery, post-corneal neurotisation has been reported.²⁶

No complications were observed in our series. Terzis et al⁶ reported one patient developing a subgaleal hematoma requiring evacuation and an asymptomatic subconjunctival neuroma. Ting et al²⁶ reported recurrence of complete corneal anesthesia 2 years postoperatively in one of their patients. With visual acuity of light perception, the eye was eviscerated due to persistent ocular pain and poor cosmesis. Through a histological assessment of excised corneoscleral disc, they were able to show normal sized central corneal nerves not connected structurally to peri-limbal nerve bundles. They explained the paracrine neurotrophic support from peri-limbal transplanted nerve fascicles playing a possible role in regeneration and maintenance of corneal nerves after corneal neurotisation.

Longer term follow-up is required in order to identify any recurrence of complete corneal anesthesia and also, ultimately, the outcomes of keratoplasties following neurotisation. Catapano et al¹⁹ reported full re-epithelialization and improved sensation in four eyes of children who underwent keratoplasties after neurotisation surgery.

Our study is also one of the first to establish patient reported outcomes using VFQ-25 and helps to provide valuable data to evaluate the health economics benefit for this procedure. Overall, the results are promising with improvement in vision, limitation of activities and psychosocial impact on life with neurotrophic disease.

In conclusion, this series with up to 36 months follow-up with one of the patients confirms that the outcomes of this technique are reproducible, corneal neurotisation surgery helps restore trophic nerve function more consistently than touch-related sensation and touch-sensation may take up to 24 months to return.

Ethics Approval and Informed Consent

The study was approved as a prospective audit by the local institutional review board at Queen Victoria Hospital and adhered to the Declaration of Helsinki. All participants provided informed consent for participation in the study.

Acknowledgments

1. Parwez Hossain, FRCOphth: Professor of Ophthalmology, University of Southampton.
2. Petrina Tan, FRCS: Corneoplastic Unit, Queen Victoria Hospital NHS Trust, UK.

Author Contributions

All authors made a significant contribution to the work reported, whether that is in the conception, study design, execution, acquisition of data, analysis and interpretation, or in all these areas; took part in drafting, revising or critically reviewing the article; gave final approval of the version to be published; have agreed on the journal to which the article has been submitted; and agree to be accountable for all aspects of the work.

Funding

There is no funding to report.

Disclosure

No financial and non-financial conflicting interests exist for any author.

References

1. Nishida T. Neurotrophic mediators and corneal wound healing. *Ocul Surf*. 2005;3(4):194–202. doi:10.1016/S1542-0124(12)70206-9
2. Muller LJ, Marfurt CF, Kruse F, et al. Corneal nerves: structure, contents and function. *Exp Eye Res*. 2003;76:521–542.
3. Khokhar S, Natung T, Sony P, et al. Amniotic membrane transplantation in refractory neurotrophic corneal ulcers. *Cornea*. 2005;24(6):654–660. doi:10.1097/01.ico.0000153102.19776.80
4. Garcia-Hirschfeld J, Lopez-Briones LG, Belmonte C. Neurotrophic influences on corneal epithelial cells. *Exp Eye Res*. 1994;59(5):597–605. doi:10.1006/exer.1994.1145
5. Rosenberg ML. Congenital trigeminal anaesthesia: a review and classification. *Brain*. 1984;107(4):1073–1082. doi:10.1093/brain/107.4.1073
6. Terzis JK, Dryer MM, Bodner BI. Corneal neurotization: a novel solution to neurotrophic keratopathy. *Plast Reconstr Surg*. 2009;123:112–120.
7. Elbaz U, Bains R, Ali A, et al. Restoration of corneal nerves with regional nerve transfers and nerve grafts: a new approach to a difficult problem. *JAMA Ophthalmol*. 2014;132:1289–1295. doi:10.1001/jamaophthalmol.2014.2316
8. Bains RD, Elbaz U, Zuker RM, et al. Corneal neurotization from the supratrochlear nerve with sural nerve grafts: a minimally invasive approach. *Plast Reconstr Surg*. 2015;135:397e–400. doi:10.1097/PRS.0000000000000994
9. Samii M. Reconstruction of the trigeminal nerve. In: Samii M, Jannetta PJ, editors. *The Cranial Nerves*. Berlin Heidelberg New York: Springer-Verlag; 1981:352–358.
10. Malhotra R, Elalfy MS, Ruben K, et al. Update in corneal neurotisation. *Br J Ophthalmol*. 2018:1–10.
11. Fogagnolo P, Giannaccare G, Bolognesi F, et al. Direct versus indirect corneal neurotization for the treatment of neurotrophic keratopathy: a multicenter prospective comparative study. *Am J Ophthalmol*. 2020;220:203–214. doi:10.1016/j.ajo.2020.07.003
12. Patel DV, McGhee CN. In vivo confocal microscopy of human corneal nerves in health, in ocular and systemic disease, and following corneal surgery: a review. *Br J Ophthalmol*. 2009;93(7):853–860. doi:10.1136/bjo.2008.150615
13. Nickels S, Schuster AK, Singer S, et al. The National Eye Institute 25-Item Visual Function Questionnaire (NEI VFQ-25) – reference data from the German population-based Gutenberg Health Study (GHS). *Health Qual Life Outcomes*. 2017;15(1):156. doi:10.1186/s12955-017-0732-7
14. Mackie IA. Neuroparalytic keratitis. In: Frauenfelder F, Roy FH, Meyer SM, editors. *Current Ocular Therapy*. Philadelphia: WB Saunders; 1995:452–454.
15. Dhillon VK, Elalfy MS, Al-Aqaba M, et al. Corneal hypoesthesia with normal sub-basal nerve density following surgery for trigeminal neuralgia. *Acta Ophthalmol*. 2016;94(1):e6–e10. doi:10.1111/aos.12697
16. Bonini S, Lambiase A, Rama P, et al.; REPARO Study Group. Phase I trial of recombinant human nerve growth factor for neurotrophic keratitis. *Ophthalmology*. 2018;125(9):1468–1471. doi:10.1016/j.ophtha.2018.03.004
17. Bonini S, Lambiase A, Rama P, et al.; REPARO Study Group. Phase II randomized, double-masked, vehicle-controlled trial of recombinant human nerve growth factor for neurotrophic keratitis. *Ophthalmology*. 2018;125(9):1332–1343. doi:10.1016/j.ophtha.2018.02.022
18. Reed JW, Joyner SJ, Knauer WJ 3rd. Penetrating keratoplasty for herpes zoster keratopathy. *Am J Ophthalmol*. 1989;107(3):257–261. doi:10.1016/0002-9394(89)90309-7
19. Catapano J, Fung SSM, Halliday W, et al. Treatment of neurotrophic keratopathy with minimally invasive corneal neurotisation: long-term clinical outcomes and evidence of corneal reinnervation. *Br J Ophthalmol*. 2019;103(12):1724–1731. doi:10.1136/bjophthalmol-2018-313042
20. Cheng AMS, Zhao D, Chen R, et al. Accelerated restoration of ocular surface health in dry eye disease by self-retained cryopreserved amniotic membrane. *Ocul Surf*. 2016;14:56–63. doi:10.1016/j.jtos.2015.07.003
21. Banerjee A, Nürnberger S, Hennerbichler S, et al. In toto differentiation of human amniotic membrane towards the Schwann cell lineage. *Cell Tissue Bank*. 2014;15:227–239. doi:10.1007/s10561-013-9401-1
22. Touhami A, Grueterich M, Tseng SC. The role of NGF signaling in human limbal epithelium expanded by amniotic membrane culture. *Invest Ophthalmol Vis Sci*. 2002;43:987–994.
23. Al-Aqaba MA, Fares U, Suleman H, et al. Architecture and distribution of human corneal nerves. *Br J Ophthalmol*. 2010;94(6):784–789. doi:10.1136/bjo.2009.173799
24. Nathaniel EJH, Pease DC. Collagen and basement membrane formation by Schwann cells during nerve regeneration. *J Ultrastruct Res*. 1963;9:550–560. doi:10.1016/S0022-5320(63)80084-2
25. Fung SSM, Catapano J, Elbaz U, et al. In vivo confocal microscopy reveals corneal reinnervation after treatment of neurotrophic keratopathy with corneal neurotization. *Cornea*. 2018;37(1):109–112. doi:10.1097/ICO.0000000000001315
26. Ting DSJ, Figueiredo GS, Henein C, et al. Corneal neurotization for neurotrophic keratopathy. *Cornea*. 2018;37:641. doi:10.1097/ICO.0000000000001522

Clinical Ophthalmology

Dovepress

Publish your work in this journal

Clinical Ophthalmology is an international, peer-reviewed journal covering all subspecialties within ophthalmology. Key topics include: Optometry; Visual science; Pharmacology and drug therapy in eye diseases; Basic Sciences; Primary and Secondary eye care; Patient Safety and Quality of Care Improvements. This journal is indexed on PubMed

Central and CAS, and is the official journal of The Society of Clinical Ophthalmology (SCO). The manuscript management system is completely online and includes a very quick and fair peer-review system, which is all easy to use. Visit <http://www.dovepress.com/testimonials.php> to read real quotes from published authors.

Submit your manuscript here: <https://www.dovepress.com/clinical-ophthalmology-journal>