

Extensor Indicis Brevis Muscle: A Case Report

Damtew Solomon¹
Daniel Atlaw¹
Habtamu Gezahegn²

¹Anatomy Department, Madda Walabu University, Bale Goba, Ethiopia;
²Physiology Department, Madda Walabu University, Bale Goba, Ethiopia

Abstract: Even though anatomical variations in the hand, involving muscles and their tendons are common, the majority of anomalous variations are asymptomatic throughout a lifetime. Such variations are commonly appreciated during surgical procedures involving the hand or during routine cadaver dissection. The index finger has two independent extensor tendons, and in some cases, has lower incidence of anomalous variations than other extensor tendons. We found muscular variant of extensor indicis proprius (EIP) during a cadaver dissection while teaching medical anatomy students at Addis Ababa University Black Lion Specialized and Teaching Hospital, 2018. While dissecting of right hand of unknown age male cadaver, proper tendons attaching to the indicis finger are present and anomalous muscle, the so named extensor indicis brevis, was observed. The muscle originates from ulnar styloid process and inserted as a single tendon to the base of proximal phalanx of index finger. Attention is needed during surgical procedures like tendon reconstruction because anatomical variation of EIB may affect a surgical procedure.

Keywords: extensor indicis brevis muscle, variation

Introduction

During routine cadaver dissection procedures, variations of hand muscles and tendons are commonly observed. Such variations can be discovered incidentally during surgical procedures or during routine dissection. However, these variations are rarely associated with clinical significance, especially when the variant muscle occupies the narrow dorsal compartments of the wrist. Hence, it is important to expect the existence of muscular variations of the hand. During reconstructive surgeries of the dorsum of the hand, it is mandatory to expect such muscular variant.¹

Extensor indicis brevis muscle (EIB) is variant muscle that is found on the dorsum of the hand and it is slightly dominant among males. This muscle is found in approximately 2% to 3% of the population which may be easily mistaken for other dorsal hand pathology.^{2,3}

Materials and Methods

The case report involved routine dissection of unknown age male cadaver. The dissection of upper limb carried out in the Department of Anatomy of Black Lion Specialized and Teaching Hospital, Addis Ababa, Ethiopia, 2018. Skin and superficial fascia was removed, the dorsum of the hand was exposed to look for variant muscle origin, insertion, action and its neuro vascular supply. The so named EIB muscle was followed from its origin to its insertion. Other nearby structures were thoroughly observed to detect variation. An elastic tape measure was used to measure the length and thickness of variant muscle. Fresh cadaver, which was preserved by injection of formalin (10% formalin) based preservative, was dissected during first year medical anatomy course.

Correspondence: Damtew Solomon
Anatomy Department, Madda Walabu University, PO Box 302, Bale Goba, Ethiopia
Tel +251920023076
Email fraolsolomon675@gmail.com

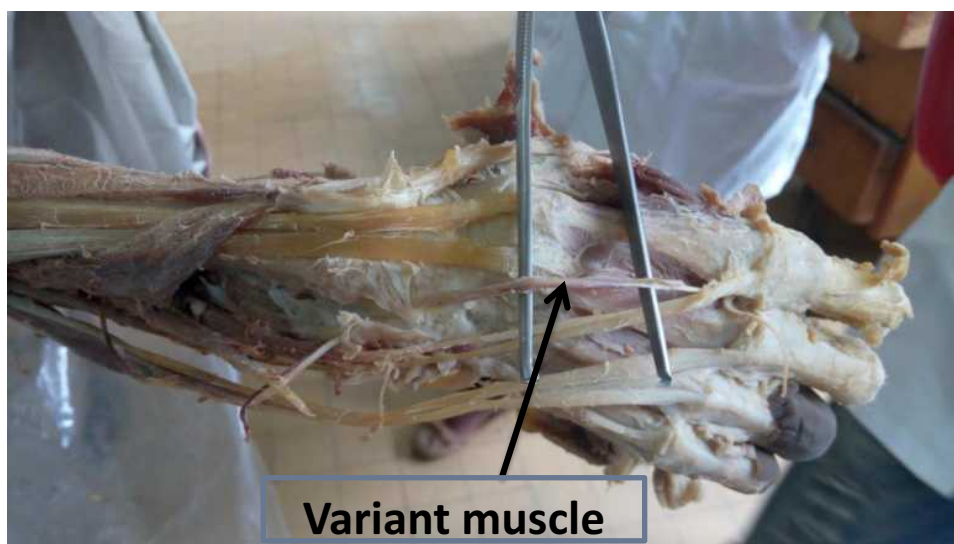


Figure 1 Photograph of the extensor indicis brevis muscle taken from right hand of male cadaver at Black lion Hospital, Addis Ababa, Ethiopia, 2018.

Results

Routine anatomical dissection of the right upper extremity of an anonymous-aged and formaldehyde-fixed cadaver at Black Lion Specialized and Teaching Hospital for 1st year medical students (Figure 1).

Ethiopian male cadaver, from department of Anatomy at Black Lion Specialized and Teaching Hospital, muscular variation was observed (Figure 1). Skin and superficial fascia was removed, the dorsum of the hand was exposed to look for variant muscle origin, insertion, action and its neurovascular supply. The variant muscle originates from ulnar styloid process and inserted as a single tendon to base of proximal phalanx of index finger. The action of the variant muscle is extension of index finger at metacarpophalangeal joint (MPJ). Belly of the muscle was fusiform and it was innervated by small branches of radial nerve (posterior interosseous nerve). The blood supply was provided by the posterior interosseous artery.

Discussion

For interpretation of unusual presentation of musculoskeletal system, diagnosis and planning of surgical tendon transfer, it is important to understand anatomical variations.¹⁰ In our case report, which was found during routine cadaver dissection, we have found variant extensor indicis brevis (EIB) of single belly. The variant muscle measured about 4.1cm long and 0.4cm thick. Even though cases with two bellies of EIB have been reported,³ commonly the variant muscle has a single belly.⁴⁻⁶ Based on

findings of different authors, different origin and insertion of EIB has been explained (Table 1).

Based on its insertion, Ogura et al⁷ classified this variant muscle into three types which includes Type I – inserted onto the dorsal aponeurosis of index finger, Type II – inserted on the index finger and Type III – inserted on the long finger. In different clinical case reports, the EIB is commonly misdiagnosed as a dorsal wrist ganglion.^{4,5} In the case of Murakami and Todani, together with a dorsal wrist ganglion an EIB was found lying over the ganglion.⁵

In conclusion, knowledge of muscle variation is not only important for differential diagnosis but also for elimination of bad outcomes of surgical procedure. Therefore, EIB is a muscle structure that can present as variant on the dorsum of the hand which needs consideration in case of surgical intervention and during routine dissection.

Abbreviations

EIB, extensor indicis brevis; EIP, extensor indicis proprius; M, male; MPJ, metacarpophalangeal joint.

Data Sharing Statement

Any data used to support the findings of this study are available from the corresponding author upon request.

Ethical Approval and Consent to Participate

Ethical approval for the study was obtained from Addis Ababa University, Black Lion Specialized and Teaching Hospital, Anatomy Department. The hospital secured the

Table 1 Showing Comparison of Origin and Insertion of Variant Extensor Indicis Brevis Muscle of Different Authors

Author	Origin	Insertion	Innervation	Blood Supply	Dissected Hand	Length in cm	Thickness in cm	Sex
Iliev, et.al ⁸	Joint capsule and ligaments of scaphoid and lunate bones	Ulnar side of the index extensor digitorum communis tendon	Posterior interosseous nerve	Posterior interosseous artery	Left	4.4	0.55	M
Li, Ren ⁹	Joint capsule ligament	Ulnar side of the extensor digitorum communis index finger	Posterior interosseous nerve	Not explained	Left	3.6	1.1	M
Jing Li, Zhen Fengren	Joint capsule and ligaments of scaphoid and lunate	Single tendon to the ulnar of index extensor digitorum communis tendon	Posterior interosseous nerve	Not explained	Right	4.6	0.75	M
Garbelotti Junior, et.al	Ligament and over the scaphoideum and trapezoideum	Dorsal aponeurosis of the indicis	Not explained	Not explained	Left	6.6	2.1	M

written consent from families of cadaver, as it is involved for teaching and research purposes. Families of the cadaver also informed as the information obtained will be kept confidential.

Acknowledgments

We thank Addis Ababa University, Anatomy Department for their preparation and offering of fresh cadaver during our study stay.

Disclosure

The authors report no conflicts of interest in this work.

References

- Cauldwell E, Anson B, Wright R. The extensor indicis proprius muscle. A study of 263 consecutive specimens. *Quart Bull Northwestern Univ Med School.* 1943;17:267–269.
- Coudert X, Deghrar A, Lavarde G. Supernumerary muscle on the dorsal surface of the hand. A case report. *Ann Chir Main Memb Super.* 1993;12:230–232. doi:10.1016/s0753-9053(05)80108-5
- Paraskevas G, Papaziogas B, Spanidou S, Papadopoulos A. Unusual variation of the extensor digitorum brevis manus: a case report. *J Eur Orthop Surg Traumatol.* 2002;12:158–160. doi:10.1007/s00590-002-0035-4
- Macalister A. Additional observations on muscular anomalies in human anatomy (third series), with a catalogue of the principal muscular variations hitherto published. *Trans Roy Irish Acad.* 1875;25:1–130.
- Murakami Y, Todani K. The extensor indicis brevis muscle with an unusual ganglion. *Clin Orthop Relat Res.* 1982;162:207–209.
- Fernandez Vazquez J, Linscheid R. Anomalous extensor muscles simulating dorsal wrist ganglion. *Clin Orthop Relat Res.* 1972;83:84–86. doi:10.1097/00003086-197203000-00014
- Ogura T, Inoue H, Tanabe G. Anatomic and clinical studies of the extensor digitorum brevis manus. *J Hand Surg Am.* 1987;12:100–107. doi:10.1016/S0363-5023(87)80171-5
- Iliev A, Georgiev GP, Dimitrova IN, Landzhov B. Extensor indicis brevis muscle: anatomical and clinical considerations. *Acta Morphol Anthropol.* 2015;22:75–78.
- Li J, Ren ZF. Bilateral extensor indicis brevis: a rare muscular variant. *Rom J Morphol Embryol.* 2012;53(1):185–187.
- Garbelotti Junior S, Yukio Fukuda T, Rodrigues Pereira V, Garcia Lucareli P, Olave E. Extensor indicis brevis muscle: an unusual muscular variant. *Int J Morphol.* 2012;30(3):1071–1073. doi:10.4067/S0717-95022012000300050

International Medical Case Reports Journal

Publish your work in this journal

The International Medical Case Reports Journal is an international, peer-reviewed open-access journal publishing original case reports from all medical specialties. Previously unpublished medical posters are also accepted relating to any area of clinical or preclinical science. Submissions should not normally exceed 2,000 words or 4

published pages including figures, diagrams and references. The manuscript management system is completely online and includes a very quick and fair peer-review system, which is all easy to use. Visit <http://www.dovepress.com/testimonials.php> to read real quotes from published authors.

Submit your manuscript here: <https://www.dovepress.com/international-medical-case-reports-journal-journal>

Dovepress