




Interhemispheric Functional Connectivity Alterations in Diabetic Optic Neuropathy: A Resting-State Functional Magnetic Resonance Imaging Study

Si-Wen Tan ^{1,2,*}Guo-Qian Cai ^{3,*}Qiu-Yu Li ^{1,*}Yu Guo ³Yi-Cong Pan ¹Li-Juan Zhang ¹Qian-Min Ge ¹Hui-Ye Shu ¹Xian-Jun Zeng ³Yi Shao ¹

¹Department of Ophthalmology, The First Affiliated Hospital of Nanchang University, Nanchang, 330006, Jiangxi Province, People's Republic of China;

²The First Clinical Medical College, Nanchang University, Nanchang, 330006, Jiangxi Province, People's Republic of China; ³Department of Radiology, The First Affiliated Hospital of Nanchang University, Nanchang, 330006, Jiangxi Province, People's Republic of China

*These authors contributed equally to this work

Correspondence: Yi Shao
Department of Ophthalmology, The First Affiliated Hospital of Nanchang University, No. 17, YongWaiZheng Street, DongHu District, Nanchang, 330006, Jiangxi, People's Republic of China
Tel/Fax +86 791-88692520
Email freebee99@163.com

Xian-Jun Zeng
Department of Radiology, The First Affiliated Hospital of Nanchang University, No. 17, YongWaiZheng Street, DongHu District, Nanchang, 330006, Jiangxi, People's Republic of China
Tel/Fax +86 791-88694639
Email 375135747@qq.com

Purpose: Previous research suggests that diabetic optic neuropathy (DON) can cause marked anatomical and functional variations in the brain, but to date altered functional synchronization between two functional hemispheres remains uncharacterized in DON patients. Voxel mirrored homotopic connectivity (VMHC) is a voxel-based method to evaluate the synchronism between two mirrored hemispheric by determining the functional connectivity between each voxel in one hemisphere and its counterpart. In this study, we aim to assess abnormal changes in interhemispheric functional connectivity in DON patients via the VMHC method.

Methods: The study included 28 adult DON patients (12 male, 16 female) and 28 healthy controls (12 male, 16 female) who were closely matched for sex and age. Participants were examined using resting-state functional magnetic resonance imaging. The VMHC method was applied to investigate the abnormal state in bilateral hemispheres in DON patients and the same regions in healthy controls, as well as the receiver operating characteristic (ROC) curves were used to evaluate characteristics. Associations between altered VMHC values in distinct cerebral regions and clinical features were assessed via correlational analysis.

Results: Markedly lower VMHC values were evident in the right temporal inferior, the left temporal inferior, the right mid-cingulum, the left mid-cingulum, the right supplementary motor region, and the left supplementary motor region in DON patients compared with healthy controls. ROC curve analysis suggested that the application of VMHC is reliable for the diagnosis of DON.

Conclusion: Anomalous interhemispheric functional connectivity in specific brain areas caused by DON may indicate neuropathologic mechanisms of vision loss and blurry vision in patients with DON.

Keywords: diabetes, diabetic optic neuropathy, magnetic resonance imaging, resting-state functional MRI

Introduction

Diabetes is a chronic illness that threatens the health and quality of life of the elderly. It is associated with many long-term complications including nephropathy, neuropathy, and retinopathy.¹ Clinically, diabetic patients exhibit specific defects in visuospatial construction and visual memory, central nerve involvement can lead to many uncomfortable symptoms such as optic disc edema and optic disc

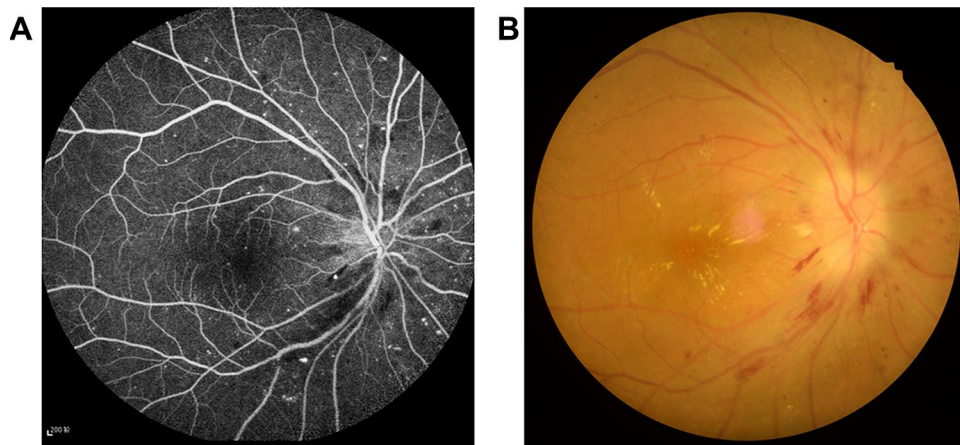


Figure 1 Example of diabetes optic neuropathy seen on fluorescence fundus angiography (A) and fundus camera (B).

angiogenesis (Figure 1), which progress to intraocular hemorrhage, cataract, retinal detachment, and optic atrophy in severe cases.²

The incidence of diabetic optic neuropathy (DON) is high. In the early stage, papilledema predominates and some papillae only exhibit different degrees of toning, which can easily go unnoticed in the clinic.³ To date, the pathogenesis of DON has not been completely explained. One widely held theory is metabolic abnormality theory. The optic nerve pertains to the central nerve, which has the same high sensitivity as the brain tissue and is vulnerable to internal damage. The main mechanisms of pathogenesis involve increased vascular permeability around the optic

papilla, increased leakage, and some histopathological changes.⁴ Diabetes leads to metabolic disorders, toxic effects of metabolites, and destruction of the microvascular barrier, resulting in abnormal blood flow, vascular structure, and hemodynamics, leading to the insufficient blood supply and oxygen composition of the optic nerve, thus disrupting its normal nutrient metabolism.⁵ Growing evidence suggests that there is a positive association between diabetes and optic neuropathy. As well as affecting blood vessel structure, diabetes affects the functioning of neurons and glial cells, and the metabolism of the retina, which eventually gives rise to the development of apoptotic death of retinal ganglion cells⁶ (Figure 2).

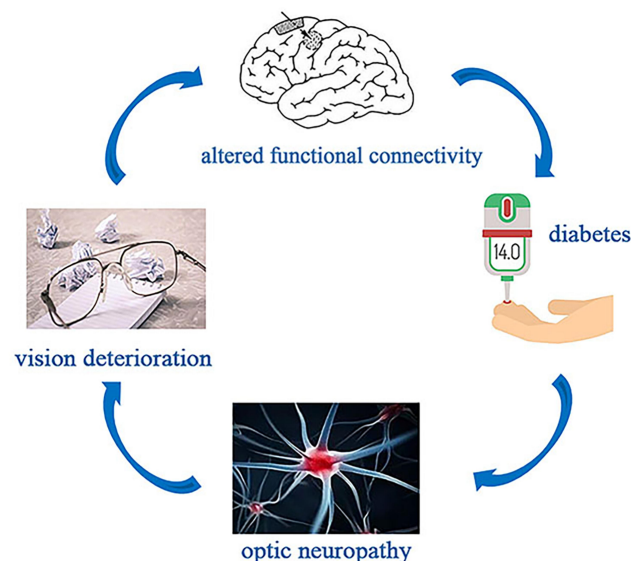


Figure 2 Relationship between magnetic resonance imaging and DON. Diabetes may cause DON. Once DON occurs, it may affect the function of vision and lead to abnormal nerve activity in areas of the brain that are related to visual discrimination.

Abbreviation: DON, diabetes optic neuropathy.

Table 1 VMHC Method Applied in Ophthalmological and Neurogenic Diseases in the Literature

Author, Year	Disease	Brain Areas		(Refs.)
		UDs>NCs	UDs<NCs	
Hou et al, 2017	Early blindness		MTG, MFG, ITG	[17]
Shi et al, 2019	Corneal ulcer		LING/CAL, PreCG/PoCG, MFG	[18]
Ye et al, 2018	Unilateral acute open globe injury		CAL, Ling, Cun, MOG	[19]
Zhang et al, 2018	Comitant exotropia	STG,MFG	PreCG, IPL, SPL	[20]
Shao et al, 2018	Left eye monocular blindness	Insula,MFG	Cun/CAL/LING	[47]
Shao et al, 2018	Right eye monocular blindness		Cun/CAL/LING, M1/S1,SPL	[47]
Dong et al, 2019	Acute eye pain		LING/CAL, PreCG/PosCG,MFG	[48]
Wang et al, 2020	Diabetic nephropathy retinopathy		BMTG, BMOG, BMFG	[21]

Abbreviations: UD, unusual disease; NC, normal controls; MTG, middle temporal gyrus; MFG, medial frontal gyrus; ITG, inferior temporal gyrus; LING, lingual; CAL, calcarine; PreCG, Precentral; PosCG, postcentral gyrus; Cun, Cuneus; MOG, Middle Occipital Gyrus; IPL, inferior parietal lobule; SPL, superior parietal lobule; M1, primary motor cortex; S1, primary somatosensory cortex; BMTG, bilateral middle temporal gyrus; BMOG, bilateral middle occipital gyrus; BMFG, bilateral medial frontal gyrus.

Functional magnetic resonance imaging (fMRI) is a specialized imaging modality that was first used by Biswal⁷ as a means of quantifying spontaneous changes in functional connectivity (FC) in specific brain tissues of patients with specific conditions. It is radiotracer-free and non-invasive, and it can be used to accurately evaluate alteration associated with regional cerebral blood flow and assess spontaneous intrinsic neural activity in the brain. Salvador et al reported that the visual outcome has a strong correlation with interhemispheric synchrony.⁸ Due to advantages such as precise positioning and a relative lack of radioactivity, many ophthalmic diseases studies have utilized resting-state fMRI, including those investigating monocular blindness,⁹ primary angle-closure glaucoma,¹⁰ and acute eye pain.¹¹ Four main fMRI methods have been developed to date: degree centrality, independent component analysis, regional homogeneity, and voxel-mirrored homotopic connectivity (VMHC). The VMHC technique is a concise way to analyze interhemispheric synchrony, which is suited to evaluating altered states in the same regions of bilateral hemispheres and provides an imaging basis for the pathophysiology of DON.¹² It has been suggested¹³ that the intention of VMHC is associated with the degree of regional functional specialization. The regional discrimination reflects different extents of lateralization of function in the brain correspond with the various developmental paths of homotopic connectivity.¹⁴ Functional disorder of the cerebra may cause abnormal neuronal synchrony, and is to the disadvantage of the neural information processing accordingly. Liang et al¹⁵ have demonstrated that altered VMHC values in lingual and fusiform gyruces were detected in

strabismic amblyopia and anisometric patients. These observations suggest that specific changes involving interhemispheric connections may reflect the clinical manifestation of pathological damage.¹⁶

The VMHC method has also been used in many studies of ocular diseases (Table 1) including early blindness,¹⁷ corneal ulcer,¹⁸ acute open globe injury,¹⁹ comitant exotropia,²⁰ and diabetic nephropathy retinopathy.²¹ Despite this, to date very little is known about interhemispheric functional synchronization changes in DON patients. In the current study, the VMHC method was used to analyze hemispheric FC and its mirrored counterpart with the time-series of the corresponding voxel. As far as we know, this study is the first to investigate interhemispheric changes in DON patients via the VMHC method.

At last, the receiver operating characteristic (ROC) curve was applied to describe the accuracy of our diagnostic tests. As well as the area under the curve (AUC) provides an overall sight to evaluate the property of this test. ROC curves have been extensively acknowledged as credible means for comparing and evaluating the accuracy of radiologic imaging.²² Moreover, the ROC curve and AUC are superior to other test facilities because of the independence of the prevalence of disease and it can summary measures of accuracy.²³ The AUC serves as a single measure to reflect the reliability and validity of the test to distinguish patients with healthy controls.²⁴ The AUC value is intermediate between 0 and 1, in these bounds, the higher the AUC value, the better the exam.

Methods

Study Design and Subjects

In total, 56 adults (28 healthy individuals and 28 DON patients) were selected randomly from the Department of Ophthalmology of the First Affiliated Hospital of Nanchang University in Nanchang, China. The standard used to diagnose DON²⁵ were (a) an explicit history of diabetes; (b) optic disc edema (non-specific congestive edema), or optic nerve atrophy and ischemic optic neuropathy; (c) sudden loss of vision and visual field defects, the foundation of visual impairment was not obvious clinically, no standard measures were discovered in the visual field examination, and visual field examination showed physiological blind spot enlargement; (d) leaky fluorescence, low fluorescence, and obscure fluorescence were present in some early stages of part or full optic nipples as determined via fluorescein fundus angiography; (e) non-existence of other diseases that may induce optic disc edema (eg, optic nerve trauma and systemic lesions); and (f) optic disc edema was resolved or treated after approximately 6 months. All healthy controls were required to have no neurological or psychiatric diseases, no eye disorders, and normal brain parenchyma as determined by MRI. The two groups were matched for age, weight, sex, and educational level.

All methods used in this research have got approval from the medical ethics of the First Affiliated Hospital of Nanchang University and were in accord with the Helsinki declaration (1964) and its amendments. Moreover, all of the participated subjects and their statutory guardians were notified about the methods, process, purposes, and potential risks of the study before the study started as well as provided an informed consent form.

MRI Data Acquisition

A 3-Tesla MRI scanner with an eight-channel head coil (Trio, Siemens AG, Munich, Germany) was applied to scan all subjects. During the fMRI, all subjects remained conscious. The detailed description and parameters are reported by a previous study.²⁶

fMRI Data Preprocessing

The collected fMRI figures were entered into the Data Processing Assistant for Resting-State fMRI Advanced (DPARSFA; <http://rfmri.org/DPARSFA>) and Statistical Parametric Mapping (SPM8; refer to <http://www.fil.ion.ucl.ac.uk/spm>) with MATLAB 2013a (Mathworks, Natick, MA, USA).

Table 2 Conditions of Participants Included in the Study

Condition	DON	HCS	t	P-value*
Male/female	12/16	12/16	N/A	>0.99
Age (years)	58.85±5.72	57.56±5.83	0.471	0.954
Weight (kg)	65.32±7.76	62.52±9.14	0.214	0.874
Handedness	28R	28R	N/A	>0.99
Duration of DON (days)	48.42±5.84	N/A	N/A	N/A
Best-corrected Va-left eye	0.40±0.28	1.05±0.20	-4.032	0.022
Best-corrected Va-right eye	0.25±0.12	1.05±0.15	-3.643	0.017

Notes: *P < 0.05 Independent t-tests comparing two groups.

Abbreviations: DON, diabetic optic neuropathy; HCS, healthy controls; N/A, not applicable.

VMHC Analysis

To improve normality, the VMHC mapping data were transformed into z values via a Fisher z-transformation using REST software (<http://resting-fmri.sourceforge.net>). A random-effects two-sample t-test with VMHC as the covariate was used to compare the two groups and identify VMHC differences in a voxel-wise manner (false discovery rate corrected, $p < 0.05$, and cluster > 20).

Statistical Analysis

The t-test for independent samples was used to analyze cumulative clinical measurements via SPSS version 16.0 (SPSS Inc., Chicago, IL, USA). Changes in the z map evidently after transforming VMHC mapping data in the DON group and the healthy controls were assessed via independent sample t-tests by the SPM8 toolkit. The average differences in the VMHC values derived from different brain areas in DON patients and the healthy controls were used to generate ROC curves. In the DON group, correlations between clinical characteristics and the VMHC values derived from specific brain areas were assessed via Pearson's correlational analysis. $p < 0.05$ was regarded as statistically significant.

Results

Demographic and Visual Measurements

There were no statistically significant differences in sex, age, weight, or handedness between the DON group as well as the healthy control group. There were significant differences in the right eye ($p = 0.017$) and the left eye ($p = 0.022$) best-corrected visual acuity between the two

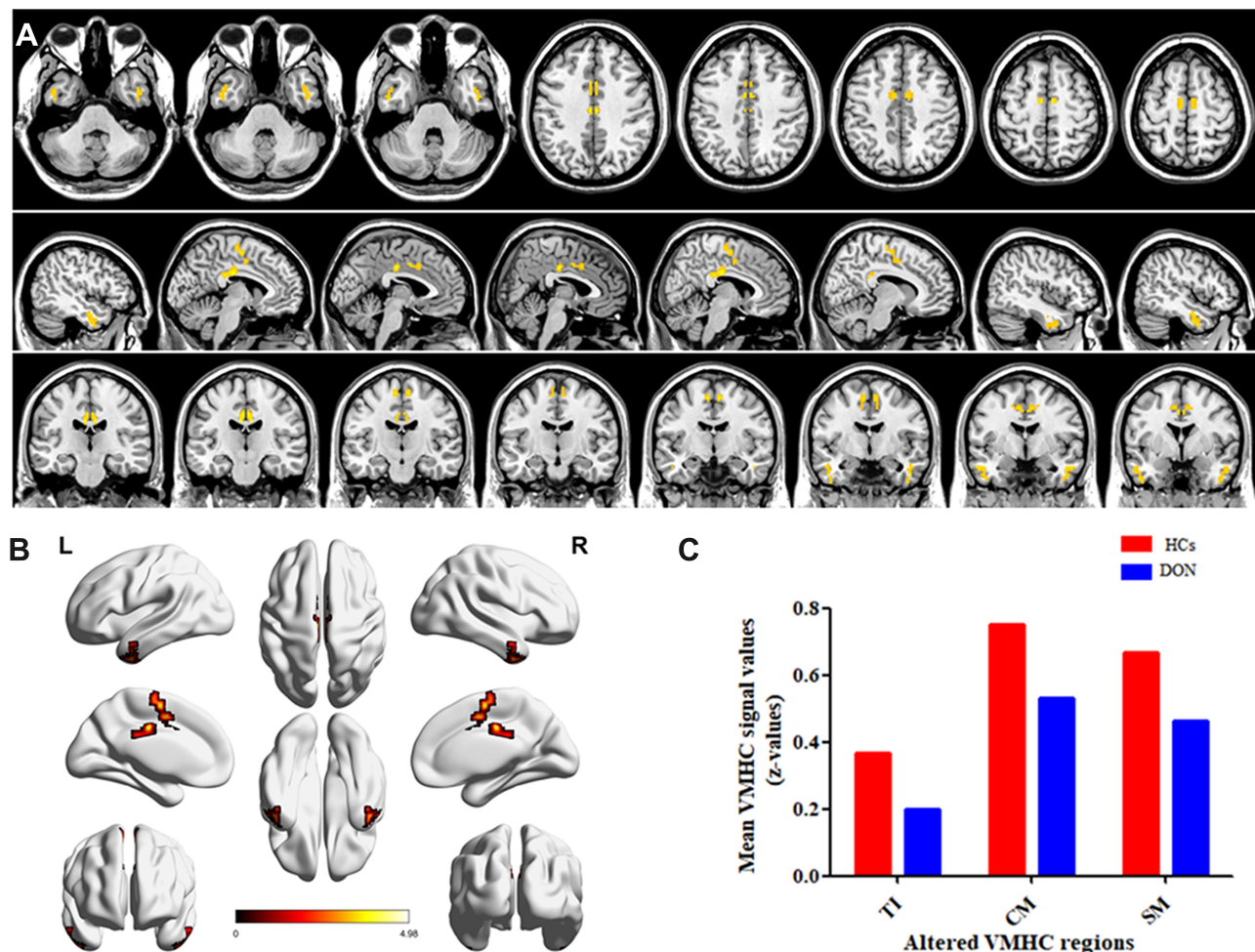


Figure 3 Spontaneous brain activity in patients with diabetes optic neuropathy (DONs) versus healthy controls (HCs). (A and B) Significant activity differences were observed in the right temporal inferior area, left temporal inferior area, right cingulum mid area, left cingulum mid area, right sup motor area, and left sup motor area. Red or yellow denote higher voxel mirrored homotopic connectivity (VMHC) values. $P < 0.01$ for multiple comparisons using Gaussian random field theory ($z > 2.3$; $P < 0.01$; cluster > 40 voxels, AlphaSim corrected). (C) Mean values of altered VMHC values between the two groups.

Abbreviations: TI, temporal inf; CM, cingulum mid; SM, sup motor; VMHC, voxel mirrored homotopic connectivity; HCs, healthy controls; DON, diabetes optic neuropathy.

groups. The mean duration of DON was 48.42 ± 5.84 . Further details are shown in Table 2.

Voxel-Mirrored Homotopic Connectivity Differences

Compared with healthy controls, the DON group shows lower VMHC values in the bilateral inferior temporal cortex, bilateral mid-cingulum, and bilateral supplementary motor area. The means of altered VMHC values in those brain areas in both groups are shown in Figure 3, and further details are shown in Table 3.

Correlational Analysis of Eye Parameters and VMHC Values

In the DON group, the VMHC values derived from the mid-cingulum were negatively correlated with best-corrected

visual acuity in the left eye ($r = 0.7913$; $p < 0.0001$) (Figure 4A). Similarly, best-corrected visual acuity in the right eye was negatively correlated with the VMHC values derived from the supplementary motor area ($r = 0.4080$; $p = 0.0003$) (Figure 4B, Table 4). It can be inferred that with the improvement of best-corrected visual acuity in the left eye, the mean VMHC value derived from the mid-cingulum gradually decreases. With the improvement of best-corrected visual acuity in the right eye, the mean VMHC value derived from the supplementary motor area gradually decreases.

Receiver Operating Characteristic Curves

To compare differences between the DON group as well as the healthy control group in different brain regions, changes in the mean VMHC values were investigated as potential clinical

Table 3 Brain Areas with Significantly Different VMHC Values Between HCs and DON

Brain Areas	MNI Coordinates			BA	Peak Voxels	T value
	X	Y	Z			
HCs>DON						
RTI	48	-6	-33	21	49	4
LTI	-48	-6	-33	21	49	4
RCM	3	-18	39	24	34	4.9
LCM	-3	-18	39	24	34	4.9
RSM	6	-9	57	24	49	4.1
LSM	-6	-9	57	24	49	4.1

Abbreviations: HCs, healthy controls; DON, diabetic optic neuropathy; RTI, right temporal inf; LTI, left temporal inf; RCM, right cingulum mid; LCM, left cingulum mid; RSM, right supp motor; LSM, left supp motor.

Table 4 Conversion Between the Five-Level Classification Method and Snellen and Log MAR

Five-Level Classification	Snellen	Snellen	Log MAR
3.0	5/500	0.01	2
4.0	5/50	0.1	1
4.1	5/40	0.12	0.9
4.2	5/32	0.15	0.8
4.3	5/25	0.2	0.7
4.4	5/20	0.25	0.6
4.5	5/16	0.3	0.5
4.6	5/13	0.4	0.4
4.7	5/10	0.5	0.3
4.8	5/8	0.6	0.2
4.9	5/6	0.8	0.1
5.0	5/5	1.0	0.0
5.1	5/4	1.2	-0.1
5.2	5/3	1.5	-0.2
5.3	5/2.5	2.0	-0.3

markers.²⁷ The areas under ROC curves (AUCs) were 0.858 for bilateral inferior temporal cortex, 0.835 for bilateral mid-cingulum, and 0.813 for the bilateral supplementary motor area (Figure 5).

Discussion

With the increasing incidence of diabetes around the world, growing attention has been paid to diabetic retinopathy, but not enough attention has been paid to DON.²⁸ This study is the first to determine changes in hemispheric

FC in specific brain areas and their mirrored counterparts in DON patients. Compared with healthy controls, the VMHC values derived from the temporal inferior cortex, mid-cingulum, and supplementary motor area were significantly lower in the DON group (Figure 6).

The inferotemporal (IT) is located in the latter half of the ventral visual pathway. The previous study has demonstrated that ablation of bilateral IT cortex could cause a severe obstruct in the learning process of tasks that need visual recognition or discrimination ability. Based on the previous behavioral and anatomical discoveries, the IT cortex is deemed to play an important role in object vision.²⁹ Another previous study determined that the anterior part of the IT cortex participates in the final stage of the visual pathway, which plays a major role in object recognition.³⁰ IT cortex neurons have big visual receptive fields and exhibit selective reactions to stimulus features such as size, contrast, color, and shape.³¹ In previous studies monkeys with IT, lesions have exhibited deficiencies in visual discrimination.^{31,32} A previous study suggested that the convergent input onto single inferotemporal neurons from diffusely separated retinal regions provide a mechanism for stimulating equally from various brain regions of the visual field, and the visual discrimination insufficiency after the IT damage may be due to the lack of the above-mentioned mechanism.³³ Early electrophysiology and pathology researches in macaques indicated the importance of the IT region in high-level object vision process and behavioral deficiencies to object recognition after the injury of the IT cortex.³⁴ Ghita et al³⁵ investigated visually evoked potentials and surmised that diabetes leads to changes in visual signal transmission and central processing and that persistent high glycemic values could produce a progressive increase in the delay of the visual

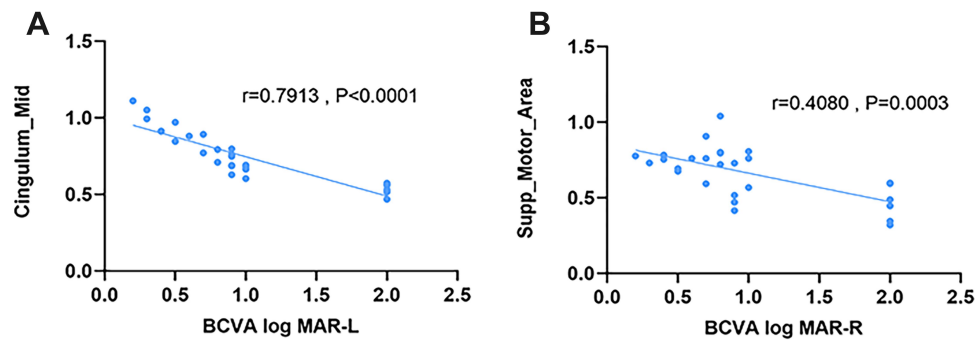


Figure 4 The VMHC results of brain activity in the DON group. **(A)**The mean VMHC value of the mid cingulum showed a negative correlation with the left best-corrected VA ($r=0.7913$, $P<0.0001$). **(B)**The best-corrected VA of the right eye negatively correlated with VMHC signal values of the supp motor area ($r=0.4080$, $P=0.0003$).

Abbreviations: VMHC, voxel mirrored homotopic connectivity; DON, diabetes optic neuropathy; HC, healthy control; VA, visual acuity.

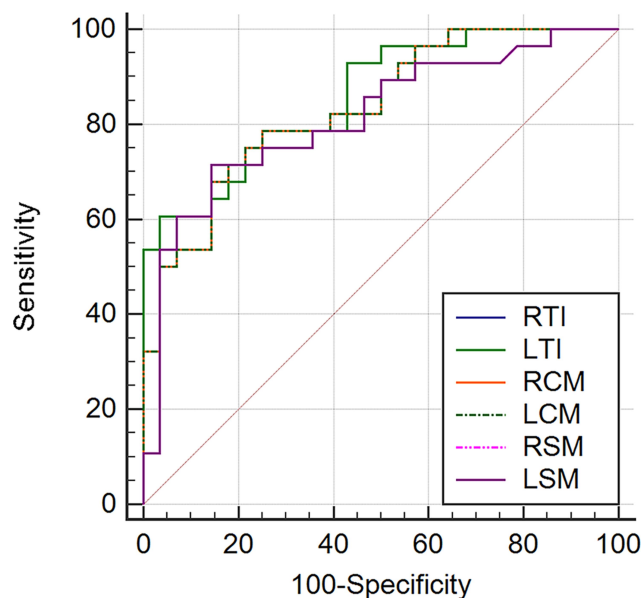


Figure 5 ROC curve analysis of mean VMHC values for altered brain regions.

Notes: The area under the ROC curve for VMHC values: RTI/LTI (0.858), RCM/LCM (0.835), and RSM/LSM (0.813).

Abbreviations: ROC, receiver operating characteristic; VMHC, voxel-mirrored homotopic connectivity; RTI, right temporal inferior; LTI, left temporal inferior; RCM, right cingulum mid; LCM, left cingulum mid; RSM, right supp motor; LSM, left supp motor.

signal. In the present study, significantly lower VMHC values were derived from the inferior temporal cortex in DON patients, indicating that impaired interhemispheric FC in the visual cortex may explain vision deterioration in DON patients.

The cingulate mainly participates in internally engendered sections of eye movement. Sikes et al³⁶ also discovered cingulate neurons in rabbits, which participated in the course of quick-phase eye movements during nystagmus. Another research reported that the frontal, parietal, and cingulate cortex contribute to a functional anatomical

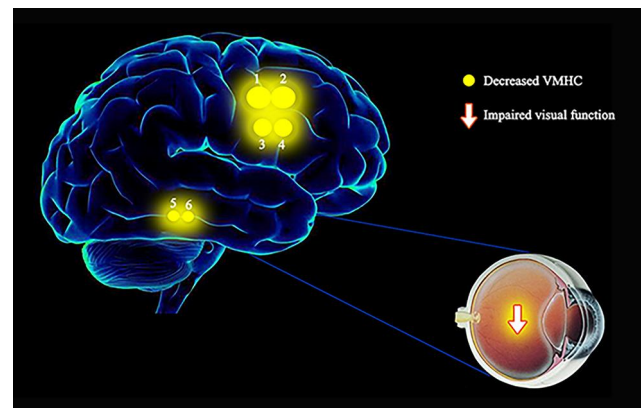


Figure 6 The voxel mirrored homotopic connectivity (VMHC) results of brain activity in the DON group. Compared with the healthy controls (HCs), the VMHC of the following regions in the DON group were decreased to various extents: 1, right cingulum mid area ($t=4.9$); 2, left cingulum mid area ($t=4.9$); 3, right supp motor area ($t=4.1$); 4, left supp motor area ($t=4.1$); 5, right temporal inferior area ($t=4$); 6, left temporal inferior area ($t=4$). The sizes of the spots denote the degree of quantitative changes.

system, which may lead the eyes and the directing attention to motorial or resting targets.³⁷ These results suggest that the cingulate cortex may involve in various high-order cognitive oculomotor functions. In the current study, DON patients exhibited markedly lower VMHC values in the mid-cingulum, suggesting that interhemispheric FC obstruction may be a useful clinical marker for the diagnosis of DON.

The supplementary motor area is located behind the superior frontal gyrus and is approximately equivalent to the medial part of Brodmann's area 6.³⁸ The supplementary eye field (SEF) is related in the anterior part of the supplementary motor area and is participated in the preparation and implementation of saccadic and pursuit eye movements.³⁹ A previous study⁴⁰ on behaving monkeys has indicated that SEF takes part in spatial attention and saccade production. The frontal impairment that includes the SEF may lead to

Table 5 Brain Regions Alternation and Its Potential Impact

Brain Regions	Experimental Result	Brain Function	Anticipated Results
Temporal inf	DONs<HCs	Object vision ²⁹	Deficit in visual discrimination or recognition
Cingulum mid	DONs<HCs	Eye movement ⁴⁹	Reflects visual impairment
Supp motor	DONs<HCs	Saccadic and pursuit eye movements ³⁹	Deficits in saccade sequences generation

Abbreviations: HCs, healthy controls; DON, diabetes optic neuropathy; HCs, healthy controls; DON, diabetes optic neuropathy.

significant disorders to induce saccade sequences when the visual cues lack.⁴¹ Patients with SEF lesions also show pursuit obstacles, especially for predictable stimulus.⁴² In the present study, markedly lower VMHC values were detected in supplementary motor areas in DON patients, implying impaired interhemispheric FC (Table 5).

In our study, we have also found that the VMHC values derived from the mid-cingulum of DON patients were negatively correlated with best-corrected visual acuity in the left eye, and the best-corrected visual acuity in the right eye was also negatively correlated with the VMHC values of the supplementary motor area. A previous study demonstrated that the retinal nerve fiber layer thickness (RNFLT) in normal eyes exists a significant asymmetry between the left and right eye. The RNFLT was markedly thinner in the left than in the right eye in the temporal cortex, as well as thinner in the right eye than in the left eye in an inferior-nasal part.⁴³ Besides, Michele et al assessed the optic nerve head in patients with Chiari I malformation (CMI) using the spectral-domain optical coherence tomography (OCT) method and observed that the RNFLT thickness in patients with CMI⁴⁴ reduced due to the damage of the retinal nerve fibers. Similarly, the two correlations of the left and right eyes in this research may also be due to different own signal pathways of both eyes, as well as the influence of DON.

ROC curve analysis is a distinct statistical method used to investigate abnormal changes associated with medical disorders. When the AUC value is >0.7 the accuracy can be considered high.⁴⁵ In the current study, the AUC values of each brain region were all >0.7 in the ROC curve analysis, suggesting high diagnostic accuracy of specific VMHC differences for the identification of DON. In conclusion, results demonstrated by our study indicate that abnormal changes in the inferior temporal cortex, mid-cingulum, and supplementary motor area may be useful

clinical markers for the diagnosis of DON. The results of the study also offer a possible explanation for the visual impairments that appeared in DON patients. The group sizes were small, which compromised the statistical power of the study. Notably, the “matched pairs” design reduced the effects of the small sample sizes, however, at least to an extent.

Conclusion

DON patients exhibited abnormal FC between corresponding brain areas in the present study. DON is relatively common in clinical practice, but due to its diverse and non-specific fundus manifestations—and sometimes complete lack of any obvious abnormality in the optic disc observed under the ophthalmoscope—sometimes it is often ignored because of the coexistence of severe diabetic retinopathy. In a previous study, diabetes duration and diabetic retinopathy severity were both risk factors for DON in patients with diabetic retinopathy.⁴⁶ Changes in VMHC values can be useful for the clinical diagnosis of DON, and also constitute an innovative parameter via which to investigate relationships between DON and interhemispheric connections.

Data Sharing Statement

All data generated or analysed during this study are included in this published article.

Ethics Statement

All methods used in this research have got approval from the medical ethics of the First Affiliated Hospital of Nanchang University (CDYFY-LL2017021) and were in accord with the Helsinki declaration (1964) and its amendments. Moreover, all of the participated subjects and their statutory guardians were notified about the methods, process, purposes, and potential risks of the study before the study started as well as provided an informed consent form.

Acknowledgments

The authors will thank Dr Yi Shao for his support in formulating and designing this study.

Funding

Health Development Planning Commission Science Foundation of Jiangxi Province (No: 20201032).

Disclosure

The authors report no conflicts of interest in this work.

References

- Klein R, Klein BEK, Moss SE. The Wisconsin epidemiologic study of diabetic retinopathy: an update. *Ophthalmology*. 1990;18(1):19–22.
- Li LM, Zhang XM, Wang J. The value of FFA diagnosis for diabetic optic neuropathy. *Chin J Lab Diagn*. 2007.
- Liao D, Wang J, Zheng Y, et al. Characteristics of optical coherence tomography image in diabetic optic neuropathy. *Int Eye Sci*. 2016;16(10):1917–1920.
- Margalit E, Sadda SR. Retinal and optic nerve diseases. *Artif Organs*. 2003;27(11):963–974. doi:10.1046/j.1525-1594.2003.07304.x
- Ryan CM, Geckle MO, Orchard TJ. Cognitive efficiency declines over time in adults with Type 1 diabetes: effects of micro- and macrovascular complications. *Diabetologia*. 2003;46(7):940–948. doi:10.1007/s00125-003-1128-2
- Nakamura M, Kanamori A, Negi A. Diabetes mellitus as a risk factor for glaucomatous optic neuropathy. *Ophthalmologica*. 2005;219(1):1–10. doi:10.1159/000081775
- Biswal BB. Resting state fMRI: a personal history. *Neuroimage*. 2012;62(2):938–944. doi:10.1016/j.neuroimage.2012.01.090
- Salvador R, Suckling J, Schwarzbauer C, Bullmore E. Undirected graphs of frequency-dependent functional connectivity in whole brain networks. *Philos Trans R Soc Lond B Biol Sci*. 2005;29(1457):937–946.
- Li Q, Xin H, Lei Y, et al. Altered spontaneous brain activity pattern in patients with late monocular blindness in middle-age using amplitude of low-frequency fluctuation: a resting-state functional MRI study. *Clin Interv Aging*. 2016;11:1773–1780. doi:10.2147/CIA.S117292
- Jian DX, Huang X, Zhong YL, et al. Disturbed spontaneous brain activity pattern in patients with primary angle-closure glaucoma using amplitude of low-frequency fluctuation: a fMRI study. *Neuropsychiatr Dis Treat*. 2015;11:1877–1883.
- Pan ZM, Li HJ, Jing B, et al. Altered intrinsic brain activities in patients with acute eye pain using amplitude of low-frequency fluctuation: a resting-state fMRI study. *Neuropsychiatr Dis Treat*. 2018;14:251–257. doi:10.2147/NDT.S150051
- Hermesdorf M, Sundermann B, Feder S, et al. Major depressive disorder: findings of reduced homotopic connectivity and investigation of underlying structural mechanisms. *Human Brain Mapping*. 2016;37:1209–1217. doi:10.1002/hbm.23097
- Stark DE, Margulies DS, Shehzad ZE, Reiss P, Milham MP. Regional variation in interhemispheric coordination of intrinsic hemodynamic fluctuations. *J Neurosci*. 2009;28(51):13754–13764.
- Marshall O, Uh J, Lurie D, et al. The influence of mild carbon dioxide on brain functional homotopy using resting-state fMRI. *Human Brain Mapping*. 2015;36(10):3912–3921. doi:10.1002/hbm.22886
- Liang M, Xie B, Yang H, et al. Altered interhemispheric functional connectivity in patients with anisometropic and strabismic amblyopia: a resting-state fMRI study. *Neuroradiology*. 2017;59(5):517–524. doi:10.1007/s00234-017-1824-0
- Zuo XN, Kelly C, Mennes M, et al. Growing together and growing apart: regional and sex differences in the lifespan developmental trajectories of functional homotopy. *J Neurosci*. 2010;30(45):15034–15043. doi:10.1523/JNEUROSCI.2612-10.2010
- Hou F, Xia L, Zhou Z, Zhou J, Li H. Reduction of interhemispheric functional brain connectivity in early blindness: a resting-state fMRI study. *Biomed Res Int*. 2017;2017:1–8.
- Shi WQ, Liu JX, Yuan Q, et al. Alternations of interhemispheric functional connectivity in corneal ulcer patients using voxel-mirrored homotopic connectivity: a resting state fMRI study. *Acta Radiol*. 2019;60(9):1159–1166. doi:10.1177/0284185118815308
- Ye L, Wei R, Huang X, Shi WQ, Shao Y. Reduction in interhemispheric functional connectivity in the dorsal visual pathway in unilateral acute open globe injury patients: a resting-state fMRI study. *Int J Ophthalmol*. 2018;11(6):1056–1060. doi:10.18240/ijo.2018.06.26
- Zhang Y, Zhu PW, Huang X, et al. Alternations of interhemispheric functional connectivity in patients with comitant exotropia: a resting state fMRI study. *Int J Clin Exp Med*. 2018;11(10):10966–10973.
- Wang Y, Wang X, Chen W, et al. Brain function alternations in patients with diabetic nephropathy complicated by retinopathy under resting state conditions assessed by voxel-mirrored homotopic connectivity. *Endocr Pract*. 2020;26(3):291–298. doi:10.4158/EP-2019-0355
- Metz CE. ROC methodology in radiologic imaging. *Invest Radiol*. 1986;21(9):720–733. doi:10.1097/00004424-198609000-00009
- Obuchowski NA, Lieber ML, Wians FH. ROC curves in clinical chemistry: uses, misuses, and possible solutions. *Clin Chem*. 2004;50(7):1118–1125. doi:10.1373/clinchem.2004.031823
- Akobeng AK. Understanding diagnostic tests 3: receiver operating characteristic curves. *Acta Paediatrica*. 2009;96(5):644–647.
- Levin LA, Arnold AC. Neuro-ophthalmology: the practical guide. Thieme. 2005.
- Cai F, Gao L, Gong H. Network centrality of resting-state fMRI in primary angle-closure glaucoma before and after surgery. *PLoS One*. 2015;10(10):e0141389. doi:10.1371/journal.pone.0141389
- Carter JV, Pan J, Rai SN, Galanduk S. ROC-ing along: evaluation and interpretation of receiver operating characteristic curves. *Surgery*. 2016;159(6):1638–1645. doi:10.1016/j.surg.2015.12.029
- Krajka-Lauer J, Łukaszewicz M, Sawko A. Optic neuropathy in diabetic patients. *Ann Acad Med Stetin*. 2007;53 Suppl 1(Suppl 1):72–75.
- Tanaka K. Inferotemporal cortex and higher visual functions. *Curr Opin Neurobiol*. 1992;2(4):502–505. doi:10.1016/0959-4388(92)90187-P
- Wang G, Tanaka K, Tanifuji M. Optical imaging of functional organization in the monkey inferotemporal cortex. *Science*. 1996;272(5268):1665–1668. doi:10.1126/science.272.5268.1665
- Fuster JM, Jervey JP. Neuronal firing in the inferotemporal cortex of the monkey in a visual memory task. *J Neurosci*. 1982;2(3):361–375. doi:10.1523/JNEUROSCI.02-03-00361.1982
- Cowey A, Gross C. Effects of foveal prestriate and inferotemporal lesions on visual discrimination by rhesus monkeys. *Experimental Brain Research*. 1970;11(2):128–144. doi:10.1007/BF00234318
- Rocha-Miranda CE, Bender DB, Gross CG, Mishkin M. Visual activation of neurons in inferotemporal cortex depends on striate cortex and forebrain commissures. *J Neurophysiol*. 1975;38(3):475–491. doi:10.1152/jn.1975.38.3.475
- Kanwisher N. The quest for the FFA and where it led. *J Neurosci*. 2017;37(5):1056. doi:10.1523/JNEUROSCI.1706-16.2016
- Ghita A, Parvu D, Sava R, Georgescu L, Zagrean L. Electrophysiological changes in optic neuropathy of streptozotocin induced diabetic rats. *J Med Life*. 2013;6(3):340–348.
- Sikes RW, Vogt BA, Swadlow HA. Neuronal responses in rabbit cingulate cortex linked to quick-phase eye movements during nystagmus. *J Neurophysiol*. 1988;59(3):922–936. doi:10.1152/jn.1988.59.3.922

37. Berman RA, Colby CL, Genovese CR, Voyvodic JT, Sweeney JA. Cortical networks subserving pursuit and saccadic eye movements in humans: an fMRI study. *Hum Brain Mapp.* 2015;8(4):209–225. doi:10.1002/(SICI)1097-0193(1999)8:4<209::AID-HBM5>3.0.CO;2-0
38. Wei L, Lai JJ, Qu YM. Surgical treatment of gliomas involving the supplementary motor area in the superior frontal gyrus. *Chin J Surg.* 2004;42(13):781–783.
39. Jamadar SD, Joanne F, Egan GF. Quantitative meta-analysis of fMRI and PET studies reveals consistent activation in fronto-striatal-parietal regions and cerebellum during antisaccades and prosaccades. *Front Psychol.* 2013;4. doi:10.3389/fpsyg.2013.00749
40. Schlag J, Schlag-Rey M. Evidence for a supplementary eye field. *J Neurophysiol.* 1987;57(1):179–200. doi:10.1152/jn.1987.57.1.179
41. Gaymard B, Pierrot-Deseilligny C, Rivaud S. Impairment of sequences of memory-guided saccades after supplementary motor area lesions. *Ann Neurol.* 2010;28(5):622–626. doi:10.1002/ana.410280504
42. Heide W, Kurzdin K, Kmpf D. Deficits of smooth pursuit eye movements after frontal and parietal lesions. *Brain Struct Funct.* 1997;119(6):1951–1969.
43. Joon Jeong P, Dong Ryeul O, Sung Pyo H, Kyoo Won L. Asymmetry analysis of the retinal nerve fiber layer thickness in normal eyes using optical coherence tomography. *Korean J Ophthalmol.* 2005;19(4):281. doi:10.3341/kjo.2005.19.4.281
44. Michele F, Chiara P, Francesco N, et al. Optical coherence tomography in patients with Chiari I malformation. *Biomed Res Int.* 2015;2015:1–7.
45. Sedgwick P. How to read a receiver operating characteristic curve. *BMJ.* 2015;350:h2464.
46. Hua R, Qu L, Ma B, et al. Diabetic optic neuropathy and its risk factors in Chinese patients with diabetic retinopathy. *Invest Ophthalmol Vis Sci.* 2019;60(10):3514–3519. doi:10.1167/iovs.19-26825
47. Shao Y, Bao J, Huang X, Zhou FQ, Zhou Q. Comparative study of interhemispheric functional connectivity in left eye monocular blindness versus right eye monocular blindness: a resting-state functional MRI study. *Oncotarget.* 2018;9(18):14285–14295. doi:10.18632/oncotarget.24487
48. Dong ZZ, Zhu FY, Shi WQ, et al. Abnormalities of interhemispheric functional connectivity in individuals with acute eye pain: a resting-state fMRI study. *Int J Ophthalmol.* 2019;12(4):634–639. doi:10.18240/ijo.2019.04.18
49. Coiner B, Pan H, Bennett ML, Bodien YG, Stern E. Functional neuroanatomy of the human eye movement network: a review and atlas. *Brain Struct Funct.* 2019;224(8):2603–2617. doi:10.1007/s00429-019-01932-7

Diabetes, Metabolic Syndrome and Obesity: Targets and Therapy

Dovepress

Publish your work in this journal

Diabetes, Metabolic Syndrome and Obesity: Targets and Therapy is an international, peer-reviewed open-access journal committed to the rapid publication of the latest laboratory and clinical findings in the fields of diabetes, metabolic syndrome and obesity research. Original research, review, case reports, hypothesis formation, expert opinion

and commentaries are all considered for publication. The manuscript management system is completely online and includes a very quick and fair peer-review system, which is all easy to use. Visit <http://www.dovepress.com/testimonials.php> to read real quotes from published authors.

Submit your manuscript here: <https://www.dovepress.com/diabetes-metabolic-syndrome-and-obesity-targets-and-therapy-journal>