

Fungal keratitis

Sonal S Tuli

University of Florida, Gainesville, FL,
USA

Date of preparation: 5th February 2011
Conflict of interest: None declared

Clinical question: What is the most appropriate management of fungal keratitis?

Results: Traditionally, topical Natamycin is the most commonly used medication for filamentous fungi while Amphotericin B is most commonly used for yeast. Voriconazole is rapidly becoming the drug of choice for all fungal keratitis because of its wide spectrum of coverage and increased penetration into the cornea.

Implementation: Repeated debridement of the ulcer is recommended for the penetration of topical medications. While small, peripheral ulcers may be treated in the community, larger or central ulcers, especially if associated with signs suggestive of anterior chamber penetration should be referred to a tertiary center. Prolonged therapy for approximately four weeks is usually necessary.

Keywords: fungal keratitis, keratomycosis, antifungal medications, debridement

Fungal keratitis

Definition: Fungal keratitis (keratomycosis) is a fungal infection of the cornea. It primarily affects the corneal epithelium and stroma, although the endothelium and anterior chamber of the eye may get involved in more severe disease.

Incidence: Fungal keratitis is primarily seen in tropical climates and is rare in temperate areas. Its incidence is between 6%–20% of all microbial keratitis cases depending on the geographic location.^{1,2} Traditionally, it is considered a disease of rural areas and is frequently caused by trauma with vegetative material. However, the major risk factor in developed countries is contact lens use at this time.³ Its incidence has been reported to be increasing due to widespread use of contact lenses, especially bandage contact lenses, and topical steroid usage.^{3,4} While tropical climates show a preponderance of filamentous fungi, temperate climates show higher percentages of yeast infections.^{1,5,6}

Economics: Although no studies evaluating the economic implications of fungal keratitis are available, this is primarily a disease of young, working adults and is becoming more common. These facts, combined with the need for prolonged, intensive treatment and relatively poor visual outcomes, suggest that the adverse economic implications are significant.

Level of evidence: Systematic reviews and randomized controlled trials (RCTs). Cohort and observational studies were also reviewed for additional data.

Search sources: PubMed, Cochrane Library.

Outcomes: The main outcomes are:

- Resolution of the infectious process as rapidly as possible
- Good visual outcome

Correspondence: Sonal S Tuli
University of Florida, PO Box 100284,
1600 SW Archer Road, Gainesville, FL
32610-0284, USA
Tel +1 352 273 7541
Fax +1 352 392 8554
Email stuli@ufl.edu

- Decrease in adverse outcomes such as the need for a therapeutic keratoplasty or loss of the eye.

Consumer summary: Fungal keratitis is an infection of the cornea by fungal organisms. It was traditionally thought to be caused by trauma with vegetative matter but contact lenses are now the most common etiology in developed countries. It is a

difficult infection to treat and adverse outcomes such as the need for a corneal transplant or even eye removal are much more common compared to bacterial infections. Evidence suggests that this is because the current therapies are not very effective. Prolonged and aggressive therapy with antifungal medication and repeated debridement is necessary to treat this infection.⁷

The evidence

Systematic reviews	3
RCTs	7
Others	2

There were three systematic reviews that evaluated the medical therapy of fungal keratitis. The Cochrane review⁸ in 2008 concluded that there was no evidence that the current available and investigational antifungal agents were effective. The review identified the need for large multicenter randomized trials. However, none of the studies they evaluated used either Amphotericin B or Voriconazole. The Hariprasad et al review⁹ evaluated over 40 laboratory studies and clinical case reports of treatment with voriconazole and concluded that it may be used safely and effectively against a broad range of fungal pathogens. In 2000, the O'Day and Head review¹⁰ concluded that although there had been progress in the treatment and outcomes of fungal keratitis, it was painfully slow. This was partly due to the almost total absence of interest in the problem by the pharmaceutical industry.

Table 1 shows the various RCTs that compared various antifungal medications to each other in terms of clinical outcomes. However, there was no specific medication that was shown to be superior to the others. Only three studies evaluated the visual outcomes and adverse outcomes between medication and are shown in Table 2. In addition, there were two laboratory studies; one comparing antifungal medications for aspergillus in rabbits; and candida (isolates from 41 countries) by disk diffusion shown in Table 3.

Conclusion

As the studies indicate, there is no one good broad spectrum anti-fungal medication that is effective in all cases of fungal keratitis. The initial therapy should be based on the organism suspected. While Natamycin is the only commercially available medication, it has a limited therapeutic spectrum. Voriconazole or Amphotericin B may be better first line drugs in unknown cases as they have broader efficacy. Other medications do not offer any improvement over these drugs and should be reserved for therapeutic failures.

Table 1 RCTs comparing the clinical response of different antifungal medications

RCT	Intervention	Number of patients	Outcome criteria	Outcomes
Mohan 1988 ¹⁵	Topical Silver sulphadiazine vs Miconazole 1%	40	Clinical response by healing of ulcer	Silver sulphadiazine superior to miconazole
Rahman 1998 ¹⁶	Topical chlorhexidine 0.2% vs Natamycin 2.5%	70	Response at day 5 and healing by day 21	Chlorhexidine superior at both time points especially with severe ulcers
Prajna 2003 ¹⁷	Topical econazole 2% vs Topical Natamycin 5%	112	Clinical response by healing of ulcer	No difference
Kalavathy 2005 ¹⁸	Topical Itraconazole 1% vs Topical Natamycin 5%	100	Clinical response by healing of ulcer	No difference overall but Natamycin superior in Fusarium
Mahdy 2010 ¹⁹	Topical Amphotericin B 0.05% + subconjunctival injection Fluconazole 0.2% vs Topical Amphotericin 0.05%	48	Clinical response by healing of ulcer	Combination therapy superior to monotherapy
Prajna 2010 ²⁰	Topical Voriconazole 1% vs Topical Natamycin 5%	120	Time to re-epithelialization	No difference
Arora 2010 ²¹	Topical Voriconazole 1% vs Topical Natamycin 5%	30	Clinical response by healing of ulcer	No significant difference

Table 2 RCTs evaluating the visual outcomes or adverse outcomes between antifungal medications

RCT	Intervention	Number	Outcome criteria	Outcome
Mahdy 2010 ¹⁹	Topical Amphotericin B 0.05% + subconjunctival Fluconazole 0.2% vs Topical Amphotericin 0.05%	48	Number of perforations and visual outcome	Both therapies equivalent in both criteria
Prajna 2010 ²⁰	Topical Voriconazole 1% vs Topical Natamycin 5%	120	Visual acuity and number of perforations and corneal transplants	Visual acuity slightly superior in Voriconazole but not statistically significant. No difference in rate of complications
Arora 2010 ²¹	Topical Voriconazole 1% vs Topical Natamycin 5%	30	Visual acuity	No significant difference

Table 3 Laboratory studies

Trial	Intervention	Number	Outcome criteria	Outcome
Panda 2003 ¹²	Topical PHMB 0.02% vs povidone iodine 1% vs Natamycin 5%	24 Aspergillus rabbit infections	Healing time and perforations	Natamycin most effective, PHMB less effective, povidone-iodine not effective
Pfaller 2010 ²²	Fluconazole (25 µg) vs voriconazole (1 µg)	256,882 Candida isolates	80% growth inhibition	Voriconazole slightly superior but resistant organisms common to both

The practice

Potential pitfalls

Fungal organisms can penetrate through the corneal stroma without perforation of the cornea resulting in an infectious hypopyon or endothelial plaque. The problem is that the majority of antifungal medications have very poor penetration especially in the face of an intact epithelium. Unlike bacterial keratitis, the corneal epithelium overlying a stromal fungal infection can heal despite the presence of active infection once treatment is initiated and should not, by itself, be used as a guide to successful therapy.

Management

Fungal keratitis should be suspected in cases of keratitis that do not respond to antibacterial agents especially in cases of vegetative trauma or extended wear contact lens usage. These cases should be scraped and sent for KOH or Gomorimethenamine silver stains as well as culture on Sabouraud agar.

Assessment

Feathery borders, ring infiltrate, endothelial plaque, fibrinoid aqueous, and satellite lesions should raise the suspicion of fungal keratitis (Figure 1). Endothelial plaques or an anterior chamber reaction usually indicate a more severe infection with penetration of fungal elements into the anterior chamber (Figure 2). Response to therapy is usually indicated

by blunting of the feathery edges, re-epithelialization, or reduction in the anterior chamber reaction.

Treatment

The only commercially available antifungal drug in the United States is Natamycin (also called Pimaricin) available as a 5% suspension. In other parts of the world where keratomycosis is seen much more frequently such as India, additional antifungal agents such as Fluconazole and Miconazole are available. However, various other drugs can be compounded into eye drops (by compounding pharmacies) and are effective. The most commonly used drugs are Voriconazole (1%),^{7,11} Amphotericin B (0.15%), Fluconazole, and Miconazole. Antiseptics such as Chlorhexidine 0.2% and Povidone iodine (5%) have also been advocated as cheap and easily available alternatives but are not as effective.¹² Systemic antifungal medications have been advocated as adjunctive therapy in severe cases, especially ulcers with anterior chamber reaction but there have been no controlled studies showing a clear benefit of adding systemic antifungals.^{13,14}

Therapy should be aggressive and most authors advocate dual therapy to avoid the risk of resistance. Typically, the topical antifungals are given every hour initially. The duration of treatment is from 3–4 weeks on average. If efficacy is not noted within a week or there is worsening, consideration

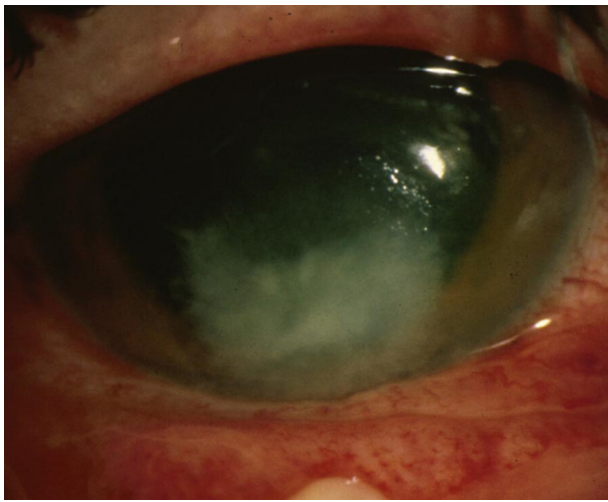


Figure 1 Typical fungal ulcer with feathery borders.

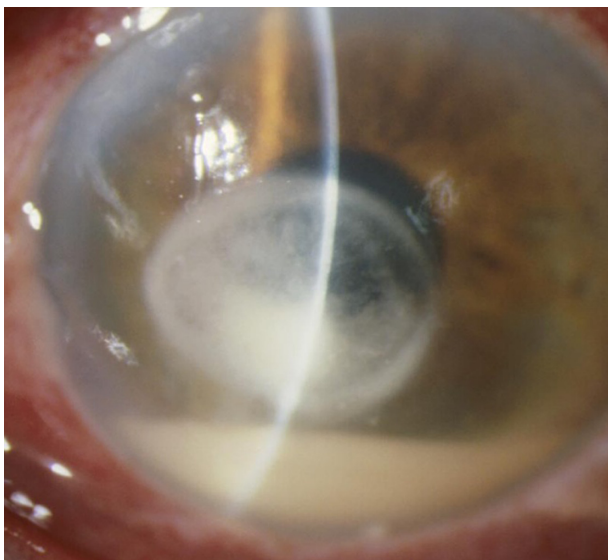


Figure 2 Endothelial plaque, ring infiltrate, and hypopyon indicating a more advanced infection.

should be given to changing the medication to another class or asking the laboratory to run sensitivities on the cultured fungus.

If the infection continues to worsen or there is worsening anterior chamber reaction, surgical management may be indicated. This includes therapeutic keratoplasty and, in severe cases, enucleation may be necessary.

Indications for specialist referral

Small, superficial, peripheral ulcers can be managed in the community with a combination of frequent antifungal agents and epithelial debridement every three days. Large, deep, or central ulcers with an endothelial plaque, a hypopyon or

fibrinoid aqueous should preferably be referred to a cornea specialist within a day. Paracentral ulcers may be managed in the community if smaller and without evidence of anterior chamber penetration. However, if no response is noted within a week, the physician should consider referring the patient to a specialist.

Further reading

- Krachmer JH, Mannis MJ, Holland EJ. Cornea 3rd edition, volume 1. Fundamentals, diagnosis and management. Elsevier Mosby: Philadelphia, PA; 2010.
- Kalkanci A, Ozdek S. Ocular fungal infections. *Curr Eye Res.* 2010;15: Epub.

References

1. Liesegang TJ, Forster RK. Spectrum of microbial keratitis in South Florida. *Am J Ophthalmol.* 1980;90:38–47.
2. Gopinathan U, Sharma S, Garg P, Rao GN. Review of epidemiological features, microbiological diagnosis and treatment outcome of microbial keratitis: experience of over a decade. *Indian J Ophthalmol.* 2009;57:273–279.
3. Iyer SA, Tuli SS, Wagoner RC. Fungal keratitis: emerging trends and treatment outcomes. *Eye Contact Lens.* 2006;32:267–271.
4. Gower EW, Keay LJ, Oechsler RA, et al. Trends in fungal keratitis in the United States, 2001 to 2007. *Ophthalmology.* 2010;117:2263–2267.
5. Gopinathan U, Garg P, Fernandes M, Sharma S, Athmanathan S, Rao GN. The epidemiological features and laboratory results of fungal keratitis: a 10-year review at a referral eye care center in South India. *Cornea.* 2002;21:555–559.
6. Ritterband DC, Seedor JA, Shah MK, Koplin RS, McCormick SA. Fungal keratitis at the new york eye and ear infirmary. *Cornea.* 2006;25:264–267.
7. Loh AR, Hong K, Lee S, Mannis M, Acharya NR. Practice patterns in the management of fungal corneal ulcers. *Cornea.* 2009;28: 856–859.
8. Florcruz NV, Peczon I, Jr. Medical interventions for fungal keratitis. *Cochrane Database Syst Rev.* 2008;CD004241.
9. Hariprasad SM, Mieler WF, Lin TK, Sponsel WE, Graybill JR. Voriconazole in the treatment of fungal eye infections: a review of current literature. *Br J Ophthalmol.* 2008;92:871–878.
10. O'Day DM, Head WS. Advances in the management of keratomycosis and Acanthamoeba keratitis. *Cornea.* 2000;19:681–687.
11. Jurkunas UV, Langston DP, Colby K. Use of voriconazole in the treatment of fungal keratitis. *Int Ophthalmol Clin.* 2007;47:47–59.
12. Panda A, Ahuja R, Biswas NR, Satpathy G, Khokhar S. Role of 0.02% polyhexamethylene biguanide and 1% povidone iodine in experimental *Aspergillus* keratitis. *Cornea.* 2003;22:138–141.
13. Thakar M. Oral fluconazole therapy for keratomycosis. *Acta Ophthalmol (Copenh).* 1994;72:765–767.
14. Agarwal PK, Roy P, Das A, Banerjee A, Maity PK, Banerjee AR. Efficacy of topical and systemic itraconazole as a broad-spectrum antifungal agent in mycotic corneal ulcer. A preliminary study. *Indian J Ophthalmol.* 2001;49:173–176.
15. Mohan M, Gupta SK, Kalra VK, Vajpayee RB, Sachdev MS. Topical silver sulphadiazine—a new drug for ocular keratomycosis. *Br J Ophthalmol.* 1988;72:192–195.
16. Rahman MR, Johnson GJ, Husain R, Howlader SA, Minassian DC. Randomised trial of 0.2% chlorhexidine gluconate and 2.5% natamycin for fungal keratitis in Bangladesh. *Br J Ophthalmol.* 1998;82:919–925.
17. Prajna NV, John RK, Nirmalan PK, Lalitha P, Srinivasan M. A randomised clinical trial comparing 2% econazole and 5% natamycin for the treatment of fungal keratitis. *Br J Ophthalmol.* 2003;87: 1235–1237.

18. Kalavathy CM, Parmar P, Kaliyamurthy J, et al. Comparison of topical itraconazole 1% with topical natamycin 5% for the treatment of filamentous fungal keratitis. *Cornea*. 2005;24:449–452.
19. Mahdy RA, Nada WM, Wageh MM. Topical amphotericin B and subconjunctival injection of fluconazole (combination therapy) versus topical amphotericin B (monotherapy) in treatment of keratomycosis. *J Ocul Pharmacol Ther*. 2010;26:281–285.
20. Prajna NV, Mascarenhas J, Krishnan T, et al. Comparison of natamycin and voriconazole for the treatment of fungal keratitis. *Arch Ophthalmol*. 2010;128:672–678.
21. Arora R, Gupta D, Goyal J, Kaur R. Voriconazole versus natamycin as primary treatment in fungal corneal ulcers. *Clin Experiment Ophthalmol*. 2010. In press.
22. Pfaller MA, Diekema DJ, Gibbs DL, et al. Results from the ARTEMIS DISK Global Antifungal Surveillance Study, 1997 to 2007: a 10.5-year analysis of susceptibilities of *Candida* Species to fluconazole and voriconazole as determined by CLSI standardized disk diffusion. *J Clin Microbiol*. 2010;48:1366–1377.

Clinical Ophthalmology

Publish your work in this journal

Clinical Ophthalmology is an international, peer-reviewed journal covering all subspecialties within ophthalmology. Key topics include: Optometry; Visual science; Pharmacology and drug therapy in eye diseases; Basic Sciences; Primary and Secondary eye care; Patient Safety and Quality of Care Improvements. This journal is indexed on

Submit your manuscript here: <http://www.dovepress.com/clinical-ophthalmology-journal>

Dovepress

PubMed Central and CAS, and is the official journal of The Society of Clinical Ophthalmology (SCO). The manuscript management system is completely online and includes a very quick and fair peer-review system, which is all easy to use. Visit <http://www.dovepress.com/testimonials.php> to read real quotes from published authors.