




# Combined Phacoemulsification and 360-Degree Endocyclophotocoagulation with and without a Kahook Dual Blade in Patients with Primary Open-Angle Glaucoma

This article was published in the following Dove Press journal:  
*Clinical Ophthalmology*

Juan Carlos Izquierdo <sup>1,2</sup>  
Natalia Agudelo <sup>1</sup>  
Bárbara Rubio <sup>1</sup>  
Jorge Camargo <sup>1</sup>  
Katia Ruiz-Montenegro <sup>1</sup>  
Consuelo Gajardo <sup>1</sup>  
Mirel Rincon <sup>1</sup>

<sup>1</sup>Research Department, Oftalmosalud Instituto de Ojos, Lima, Perú; <sup>2</sup>Glaucoma Department, Oftalmosalud Instituto de Ojos, Lima, Perú

**Purpose:** The present study aimed to compare the outcomes of combined phacoemulsification and 360-degree endocyclophotocoagulation with and without goniotomy using a Kahook Dual Blade in patients with glaucoma.

**Patients and Methods:** We enrolled 37 patients, 21 of whom underwent combined phacoemulsification with 360-degree endocyclophotocoagulation and goniotomy using a Kahook Dual Blade (tri-modal therapy (T-MT) group). The remaining 16 patients underwent phacoemulsification with endocyclophotocoagulation (bi-modal therapy (B-MT) group). Visual acuity, intraocular pressure, and number of glaucoma medications were recorded before the study and postoperatively on the first day, at week 1, and at 1, 3, 6, 9, and 12 months. Surgical success was defined as an IOP  $\leq 12$  mmHg and  $\geq 6$  mmHg or an at least 20% reduction in IOP from baseline with (qualified success) or without medications (complete success).

**Results:** Forty-nine eyes were included. Baseline mean IOP was  $16.96 \pm 3.66$  mmHg and  $15.64 \pm 4.88$  mmHg in the T-MT and B-MT groups ( $p=0.122$ ), respectively. At the 12-month follow-up, mean IOP values were  $11.44 \pm 2.15$  mmHg and  $12.45 \pm 1.90$  mmHg ( $p=0.031$ ) in the T-MT and B-MT groups, respectively. Complete success rates were 37% in the T-MT group and 31% in the B-MT group, while qualified success rates were 74% and 50%, respectively. Glaucoma medications decreased from  $2.0 \pm 1.4$  to  $0.8 \pm 1.0$  ( $p < 0.001$ ) in the T-MT group and from  $1.5 \pm 1.3$  to  $1.0 \pm 1.5$  in the B-MT group ( $p=0.032$ ). Similar improvements in visual acuity were observed in both groups. Complications were mild and resolved without intervention.

**Conclusion:** The tri-modal treatment is safe and may be more effective in reducing IOP and glaucoma medication requirements than bi-modal treatment.

**Keywords:** micro-incisional glaucoma surgery, glaucoma surgery, MIGS, trabecular meshwork

## Introduction

Glaucoma and cataracts can co-occur in older adults, leading to irreversible and reversible blindness, respectively.<sup>1</sup> The worldwide prevalence of primary open-angle glaucoma (POAG) for individuals between 40 and 80 years of age is 3.54%, although rates as high as 4.20% have been reported in Africa. In 2013, an estimated 64.3 million people were living with glaucoma globally, with the number

Correspondence: Natalia Agudelo  
Oftalmosalud Instituto de Ojos, Av. Javier Prado Este 1142, San Isidro, Lima 27, Peru  
Tel +51 1-985148485  
Fax +51 1-970584766  
Email drnataliaagudelo@gmail.com

expected to increase to 111.8 million by 2040.<sup>2</sup> The natural history of both diseases is usually parallel, and glaucoma is the most common ocular comorbidity in patients with cataracts;<sup>3</sup> therefore, there is increasing interest in treating both conditions with a single procedure to reduce intraocular pressure (IOP), the unique treatable risk factor in patients with glaucoma.<sup>4,5</sup>

The standard filtering surgery procedure is associated with innumerable early and late complications,<sup>6,7</sup> necessitating the development of safer or minimally invasive procedures. Relevant studies have evaluated the efficacy of such procedures even in the early stages of glaucoma when control of IOP has not been attained using medical therapy.<sup>8,9</sup>

Cataract extraction as a standalone procedure improves visual acuity and reduces IOP. In their meta-analysis, Armstrong et al observed decreases in IOP in patients with OAG of at least 36 months (9% IOP reduction), with gradual loss of the initial result after 2 years.<sup>10</sup> Endocyclophotocoagulation (ECP) allows for direct visualization of the ciliary processes and ablation of the pigmented ciliary epithelium, causing thermal damage to the non-pigmented ciliary epithelium, which reduces aqueous humor production in a more target-controlled manner. The procedure can be performed through the same clear corneal incision used for phacoemulsification, which is why ECP can easily be performed during the same procedure in a safe and effective manner.<sup>11</sup>

The Kahook Dual Blade (KDB) (New World Medical, Rancho Cucamonga, CA, USA) safely reduces IOP via the creation of a goniotomy incision and removal of the pathological trabecular meshwork, one of the main sites of resistance of conventional aqueous outflow, using a minimally invasive ab interno approach. The KDB is usually combined with cataract extraction through the same corneal incision. Short-term results in a prospective interventional case series of 71 eyes by Greenwood et al indicated that IOP had decreased from 17.4 mmHg to 12.8 mmHg at the 6-month follow-up.<sup>12</sup>

## Patients and Methods

We enrolled 60 randomly selected eyes of 47 patients. Thirty eyes were included in the tri-modal therapy (T-MT) group, 30 eyes were included in the bi-modal therapy (B-MT) group, and 11 eyes were excluded. Two eyes had previously undergone glaucoma surgery, five did not meet the minimum follow-up period criterion, and four had undergone previous selective laser trabeculoplasty

within 6 months before surgery. Forty-nine eyes of 37 patients remained for analysis.

Twenty-one patients underwent combined phacoemulsification, ECP, and goniotomy using a KDB (T-MT group), while 16 patients underwent phacoemulsification and ECP (B-MT group). All surgeries were performed by the same glaucoma surgeon (J.C.I.V) at the Instituto de Ojos Oftalmosalud from January 2017 to June 2018. The study was approved by the Ethics Committee of the Instituto de Ojos Oftalmosalud, in accordance with the Declaration of Helsinki. All patients provided written informed consent prior to enrolment.

Criteria for inclusion were as follows: uncontrolled mild and advanced POAG (Hodapp-Parrish-Anderson Glaucoma Grading Scale), cataracts, and use of two or more glaucoma medications. Uncontrolled glaucoma was defined as a change in at least two visual fields (Humphrey Field Analyzer, Zeiss, Jena/Germany) and/or a decrease in the retinal nerve fiber layer on spectral domain optical coherence tomography (sdOCT). Exclusion criteria were as follows: angle closure glaucoma, previous ocular glaucoma procedures, corneal or retinal surgeries, and secondary glaucoma.

Preoperatively, all patients underwent a complete ophthalmic evaluation including assessments of visual acuity, biomicroscopy examinations, IOP measurements with a Goldmann applanation tonometer (average of three IOP readings from the last three visits for reference/baseline and one reading at postoperative visits), gonioscopy, and fundus examinations. Postoperative control was performed at the first day, at 1 week, and at 1, 3, 6, 9, and 12 months.

The primary outcomes evaluated were mean preoperative and postoperative IOP and complete/qualified success rates. Complete success was established as an IOP  $\leq 12$  mmHg and  $\geq 6$  mmHg or an at least 20% reduction in IOP from baseline without glaucoma medications. Qualified success was established as an IOP  $\leq 12$  mmHg and  $\geq 6$  mmHg or an at least 20% reduction in IOP from baseline with glaucoma medications. Failure was defined as the need for additional glaucoma surgery or best-corrected visual acuity (BCVA) with no light perception at postoperative follow-up. Secondary outcomes included the number of glaucoma medications, changes in BCVA, and descriptions of surgical or postoperative complications.

## Surgical Technique

All patients underwent intracameral anesthesia and deep intravenous sedation. Standard phacoemulsification surgery was performed with capsular bag intraocular lens

implantation. An ECP endoscope (Endo Optiks<sup>®</sup>, Beaver-Visitec International, E2 Ophthalmic Laser Endoscopy System, Inc. Waltham, MA, USA) was inserted into the anterior chamber through a temporal clear corneal incision. Then, 360° diode laser ablation (power of 2,000 MW and duration of 0.20 ms) of the ciliary processes was performed until shrinkage and whitening had occurred. Care was taken to avoid damage to the tissue. Miosis was achieved with 0.1 mL of 0.01% intracameral carbachol, which was applied through the same temporal corneal incision and at the same time as visualization of the angle using a gonioscope (AVG; Surgical<sup>®</sup> Gonio Lens, Volk Alcon, Mentor, OH, USA) (Figure 1A). The KDB was then engaged to the pigmented trabecular meshwork (Figure 1B), following which it was advanced at 120° aligned to the wall of Schlemm's canal (Figure 1C). Finally, corneal incisions were sutured with 10-0 nylon, and all patients received 0.1 mL cefuroxime and intracameral diluted triamcinolone (50 mg/5 mL).

The postoperative regimen included topical administration of tobramycin (0.3%) and dexamethasone (1%) (Tobradex<sup>®</sup>) drops every 4 h for 15 days, pilocarpine (2%) (Pil, Sophia, México) drops every 6 h for 15 days, and nepafenac (0.1%) (Nevanac, Alcon, Belgium) every 8 h for 15 days. In all cases, glaucoma medications were suspended at the time of surgery and resumed depending on the follow-up IOP.

## Statistical Analysis

The R 3.6.0 version statistical package (<https://www.r-project.org/>) was used for statistical analysis. The exact Wilcoxon signed-rank test was used to compare changes in IOP, glaucoma medications, and BCVA between the groups. Pairwise comparisons were performed between pairs of proportions with correction for multiple testing. The level of statistical significance was set at  $p < 0.05$ .

## Results

Baseline mean age was  $69.1 \pm 8.1$  years in the T-MT group and  $75.2 \pm 6.5$  years in the B-MT group ( $p = 0.345$ ). The T-MT group included 12 men (54.5%) and nine women (64.3%), while the B-MT group included 11 men (45.5%) and five women (35.7%). Ten right eyes and 17 left eyes were included in the T-MT group, while 12 right eyes and 10 left eyes were included in the B-MT group. Baseline demographic characteristics were comparable between the groups, which exhibited no clinically significant differences in age, baseline IOP, or medications.


## IOP

Mean IOP at baseline was  $16.96 \pm 3.66$  mmHg in the T-MT group and  $15.64 \pm 4.88$  mmHg in the B-MT group ( $p = 0.122$ ). At the 12-month follow-up, IOP was  $11.44 \pm 2.15$  mmHg (32.5% reduction) and  $12.45 \pm 1.90$  mmHg (20.3% reduction) ( $p = 0.031$ ) in the T-MT and B-MT groups, respectively. Decreases in IOP were significantly greater in the T-MT group (11.6 mmHg) than in the B-MT group (12.5 mmHg) beginning from the 9-month follow-up ( $p = 0.009$ ).

At the 12-month follow-up, complete success was observed in 37% of eyes (10/27 eyes) in the T-MT group and 31% of eyes (7/22 eyes) in the B-MT group. Qualified success was observed in 74% of eyes (20/27 eyes) in the T-MT group and 50% of eyes in the B-MT group (11/22 eyes). The failure rate at the 12-month follow-up was 7.4% (2/27 eyes) in the T-MT group and 9.0% (2/22 eyes) in the B-MT group. All patients who experienced failure required additional glaucoma surgery (micropulse transscleral cyclophotocoagulation) to control IOP (Figure 2).

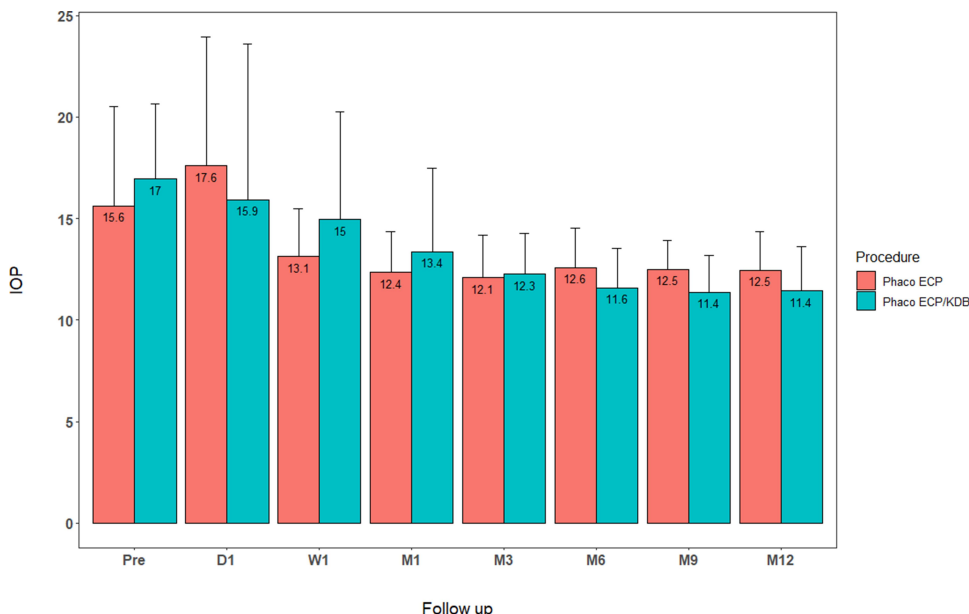
## Glaucoma Medications

In the T-MT group, the mean number of medications was  $2.0 \pm 1.4$ . By the end of the follow-up period, this number had decreased to  $0.8 \pm 1.0$  ( $p < 0.001$ ), resulting in a 60% reduction. In the B-MT group, the mean



**Figure 1** Ab interno goniotomy with a Kahook Dual Blade. **(A)** Visualization of angle structures with a surgical angle lens. **(B)** The KDB was engaged in the pigmented trabecular meshwork and then advanced at 120° parallel toward the wall of Schlemm's canal. **(C)** Blood reflux in the angle at the end of the procedure.

**Abbreviations:** ECP, endoscopic cyclophotocoagulation; KDB, Kahook Dual Blade.

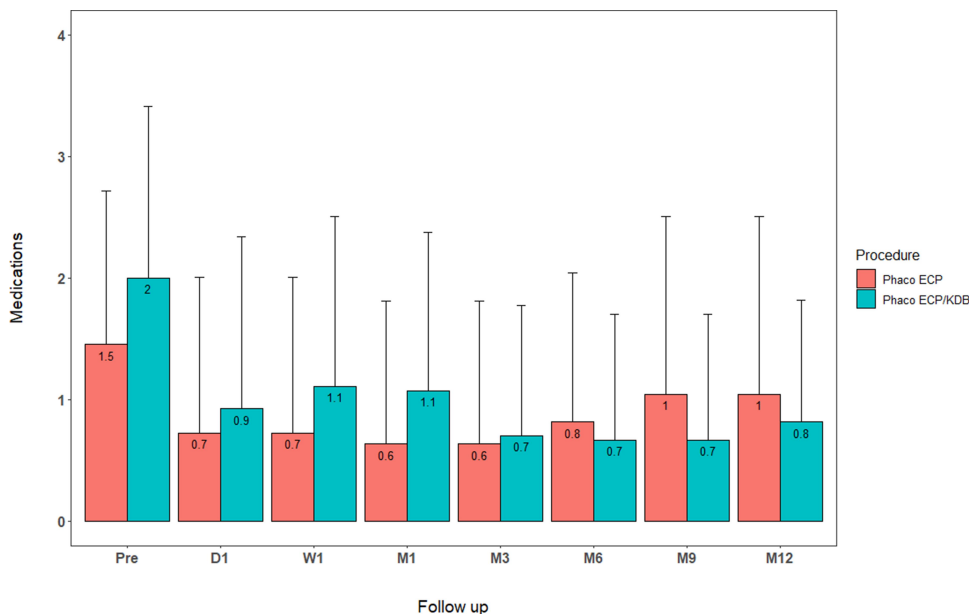


**Figure 2** Comparison of mean IOP over time in the T-MT and B-MT groups. The figure shows a reduction in IOP at every visit during the 12-month follow-up. **Abbreviations:** T-MT, tri-modal therapy; B-MT, bi-modal therapy; IOP, intraocular pressure.

number of medications was  $1.5 \pm 1.3$ . Again, by the end of the follow-up period, this number had decreased to  $1.0 \pm 1.5$  ( $p = 0.032$ ), resulting in a 33% reduction. In addition, the percentage of patients without any glaucoma medications at the last follow-up was 59% in the T-MT group and 44.1% in the B-MT group (Figure 3).

### Visual Acuity

Before surgery, visual acuity was  $0.36 \pm 0.19$  LogMAR in the T-MT group and  $0.26 \pm 0.44$  LogMAR in the B-MT group ( $p=0.706$ ). By 12 months, these values had changed to  $0.21 \pm 0.41$  LogMAR and  $0.19 \pm 0.19$  LogMAR in the T-MT and B-MT groups ( $p=0.430$ ), respectively. Both groups exhibited significant improvements in mean visual acuity



**Figure 3** Comparison of number of glaucoma medications over time in the T-MT and B-MT groups. The figure shows a decrease in the number of glaucoma medications at every visit and during the 12-month follow-up. **Abbreviations:** T-MT, tri-modal therapy; B-MT, bi-modal therapy.

from baseline to the 12-month follow-up. This improvement was more significant for the T-MT group ( $p < 0.001$ ) than for the B-MT group ( $p = 0.049$ ). However, no significant differences in mean visual acuity were observed between the groups at the 12-month follow-up ( $p = 0.430$ ) (Figure 4).

## Complications

Overall, unfavorable events were self-limiting and non-sight-threatening. IOP spikes were found in 3/27 eyes (11.11%) in the T-MT group and 7/22 eyes (31.81%) in the B-MT group. Corneal edema within the first postoperative week occurred in seven eyes of the T-MT group (25.92%) and four eyes of the B-MT group (18.18%), although this resolved within a week in all cases. Hyphema ( $< 1$  mm) was more frequently observed in the T-MT group than in the B-MT group (10 eyes, 37.03%). Corneal keratitis and posterior capsular opacification were observed in one eye (4.55%) of the T-MT group and four eyes (18.18%) of the B-MT group. No adverse events or complications required additional surgery during the 12-month follow-up period.

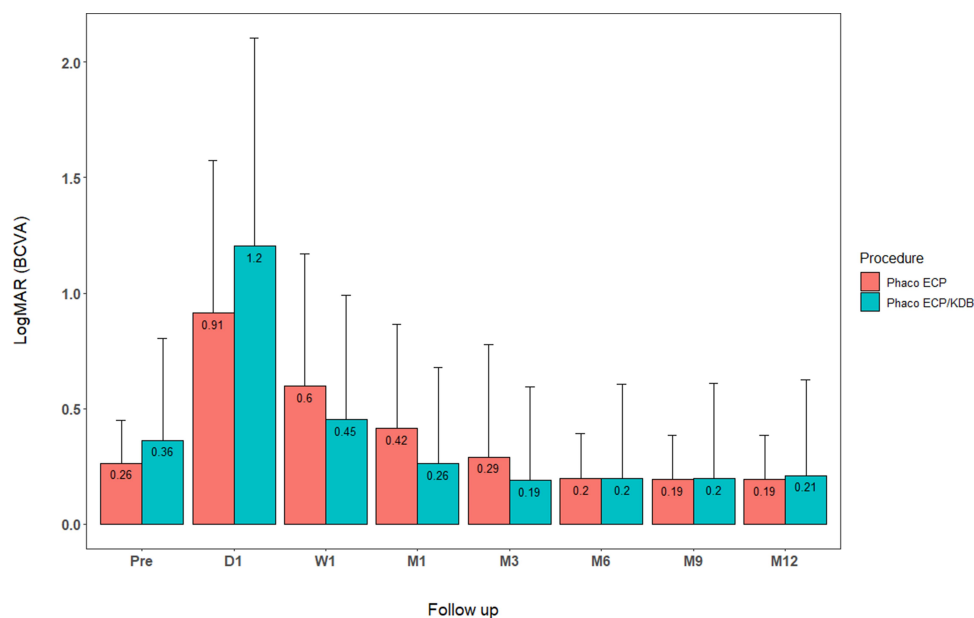
## Discussion

ECP and ab interno goniotomy are complementary treatments that reduce aqueous humor production and increase aqueous humor drainage in order to control IOP in patients with POAG. Both procedures are easily performed when combined with cataract surgery, as they can be completed through the same clear corneal incision.<sup>13</sup> In the present study, we

observed a clinically significant difference in IOP reduction between the T-MT and B-MT groups at the 9- and 12-month follow-up visits. Decreases in IOP after 9 months may be related to the process of wound healing at the site of the goniotomy. More specifically, such differences may be attributable to remodeling and gradual degradation of the extracellular matrix and the formation of mature collagen<sup>14</sup> in Schlemm's canal, which would in turn permit better drainage of the aqueous humor. Slabaugh et al<sup>15</sup> demonstrated that greater anterior chamber depth, older age, and preoperative IOP were the factors most strongly linked to lower postoperative IOP.

Francis et al compared combined ECP and cataract extraction versus cataract extraction alone, reporting IOP decreases of  $13.6 \pm 15.6\%$  and  $5.1 \pm 10.4\%$  at the 36-month follow-up, respectively.<sup>16</sup> In the present study, we observed a 20.3% decrease in IOP in the B-MT group at the 12-month follow-up. Additional, longer-term studies are required to investigate the causes of lower efficacy over time given reports regarding increases in regeneration<sup>17</sup> and re-perfusion<sup>18</sup> of ciliary processes.

Smith et al<sup>19</sup> reported that IOP decreased from 18.7 mmHg preoperatively to 13.3 mmHg and 14.0 mmHg at 1 and 3 years postoperatively in a patient treated with phacemulsification and ECP, respectively. Siegel et al<sup>20</sup> also reported an approximately 20% reduction in IOP at the 36-month follow-up in patients treated with combined phacemulsification and ECP. In their study, the reduction was



**Figure 4** Comparison of best-corrected visual acuity (BCVA) in both groups over time. The figure shows the changes in BCVA during the study period for both groups. **Abbreviation:** BCVA, best-corrected visual acuity.

observed from the 6th to 36th month of follow-up, and the number of glaucoma medications decreased from 1.3 to 0.2.

Of the few studies that have investigated the KBD, all have utilized it in combination with phacoemulsification. Dorairaj et al<sup>21</sup> studied 12-month outcomes in 52 patients treated with phacoemulsification and KBD, reporting a 26.2% reduction in IOP and a 50% reduction in the number of glaucoma medications.

Clement et al<sup>22</sup> studied outcomes following phacoemulsification and 270–360° ECP in patients with OAG. In their patients, IOP decreased from 20.80±5.61 mmHg to 16.26±5.41 mmHg, and success was defined as an IOP decrease of 20% from baseline, with IOP values ranging from 6–21 mmHg in 55% of patients at the 12-month follow-up. The most common complication reported by Smith et al<sup>20</sup> was cystoid macular edema (8.4%), an inflammation-related complication not observed in our study. In fact, none of our patients experienced fibrinous uveitis or inflammation, which may be attributable to the use of intracameral steroids at the end of the procedure.

Weiner et al<sup>23</sup> investigated outcomes in patients who underwent cataract surgery with and without ab interno trabeculectomy. IOP had decreased by 3, 4, and 20 hours later. Furthermore, the procedure was associated with a decrease in IOP spikes and an increase in hyphema rates, similar to findings observed in the present study.

## Conclusion

Combined phacoemulsification and ECP with ab interno goniotomy is a safe and effective procedure that can decrease IOP spikes and reduce IOP as well as glaucoma medication requirements in patients with POAG, when compared to findings observed for phacoemulsification and ECP without ab interno goniotomy. Our findings may be of clinical significance for patients with glaucoma requiring further decreases in IOP, as they may benefit from minimally invasive glaucoma surgery combined with phacoemulsification.

## Abbreviations

T-MT, tri-modal therapy; B-MT, bi-modal therapy; MIGS, minimally invasive glaucoma surgery; OAG, open-angle glaucoma; IOP, intraocular pressure; ECP, endoscopic cyclophotocoagulation; KBD, Kahook Dual Blade; BCVA, best-corrected visual acuity; LogMAR, logarithm of the minimum angle of resolution.

## Data Sharing Statement

The datasets used and analyzed during this study are available via the corresponding author upon reasonable request.

## Ethics Approval and Informed Consent

The study was approved by the Ethics Committee of the Instituto de Ojos Oftalmosalud. All research was conducted in accordance with the Declaration of Helsinki. All participants provided written informed consent prior to enrolment. This report does not contain any personal information that could lead to patient identification. We do not require any administrative permissions and/or licenses to access the data used in our research.

## Acknowledgments

We wish to thank Jose Chauca and Carmen Maldonado for statistical analysis and technical support.

## Author Contributions

All authors made a significant contribution to the work reported in the following areas: study conception, study design, study execution, acquisition of data, analysis and interpretation of data, drafting/writing of the manuscript, substantial revision or critical review of the article, agreement on the journal to which the article will be submitted. All authors have reviewed and agreed on all versions of the article before submission, during revision, the final version accepted for publication, and any significant changes introduced at the proofing stage. We agree to take responsibility and be accountable for the contents of the article.

## Disclosure

The authors report no conflicts of interest related to this work.

## References

1. Flaxman SR, Bourne RRA, Resnikoff S, et al. Global causes of blindness and distance vision impairment 1990–2020: a systematic review and meta-analysis. *Lancet Global Health*. 2017;5(12):e1221–1234. doi:10.1016/S2214-109X(17)30393-5
2. Tham Y-C, Li X, Wong TY, Quigley HA, Aung T, Cheng C-Y. Global prevalence of glaucoma and projections of glaucoma burden through 2040. *Ophthalmology*. 2014;121(11):2081–2090. doi:10.1016/j.ophtha.2014.05.013
3. Tseng VL, Yu F, Lum F, Coleman AL. Risk of fractures following cataract surgery in medicare beneficiaries. *JAMA*. 2012;308(5). doi:10.1001/jama.2012.9014

4. Sommer A. Relationship between intraocular pressure and primary open angle glaucoma among white and black Americans: the Baltimore eye survey. *Arch Ophthalmol.* 1991;109(8):1090–1095. doi:10.1001/archophth.1991.01080080050026
5. Kass MA, Heuer DK, Higginbotham EJ, et al. The ocular hypertension treatment study: a randomized trial determines that topical ocular hypotensive medication delays or prevents the onset of primary open-angle glaucoma. *Arch Ophthalmol.* 2002;120(6):701–713. doi:10.1001/archophth.120.6.701
6. Gedde SJ, Herndon LW, Brandt JD, Budenz DL, Feuer WJ, Schiffman JC. Postoperative complications in the tube versus trabeculectomy (TVT) study during five years of follow-up. *Am J Ophthalmol.* 2012;153(5):804–814.e1. doi:10.1016/j.ajo.2011.10.024
7. Olayanju JA, Hassan MB, Hodge DO, Khanna CL. Trabeculectomy-related complications in Olmsted County, Minnesota, 1985 through 2010. *JAMA Ophthalmol.* 2015;133(5):574–580. doi:10.1001/jamaophthol.2015.57
8. Brandão LM, Grieshaber MC. Update on minimally invasive glaucoma surgery (MIGS) and new implants. *J Ophthalmol.* 2013;2013:1–12. doi:10.1155/2013/705915
9. Lavia C, Dallorto L, Maule M, Ceccarelli M, Fea AM, Virgili G. Minimally-invasive glaucoma surgeries (MIGS) for open angle glaucoma: a systematic review and meta-analysis. *PLoS One.* 2017;12(8):e0183142. doi:10.1371/journal.pone.0183142
10. Armstrong JJ, Wasiuta T, Kiatos E, Malvankar-Mehta M, Hutnik CML. The effects of phacoemulsification on intraocular pressure and topical medication use in patients with glaucoma: a systematic review and meta-analysis of 3-year data. *J Glaucoma.* 2017;26(6):511–522. doi:10.1097/IJG.0000000000000643
11. Cohen A, Wong SH, Patel S, Tsai JC. Endoscopic cyclophotocoagulation for the treatment of glaucoma. *Surv Ophthalmol.* 2017;62(3):357–365. doi:10.1016/j.survophthal.2016.09.004
12. Greenwood MD, Seibold LK, Radcliffe NM, et al. Goniotomy with a single-use dual blade: short-term results. *J Cataract Refract Surg.* 2017;43(9):1197–1201. doi:10.1016/j.jcrs.2017.06.046
13. Izquierdo JC, Mejías J, Cañola RL, Agudelo N, Rubio B. Primary outcomes of combined cataract extraction technique with Ab-Interno trabeculectomy and endoscopic cyclophotocoagulation in patients with primary open angle glaucoma. *BMC Ophthalmol.* 2020;20(1):406. doi:10.1186/s12886-020-01643-2
14. Wang P-H, Huang B-S, Horng H-C, Yeh -C-C, Chen Y-J. Wound healing. *J Chin Med Assoc.* 2018;81(2):94–101. doi:10.1016/j.jcma.2017.11.002
15. Slabaugh MA, Bojikian KD, Moore DB, Chen PP. The effect of phacoemulsification on intraocular pressure in medically controlled open-angle glaucoma patients. *Am J Ophthalmol.* 2014;157(1):26–31. doi:10.1016/j.ajo.2013.08.023
16. Francis BA, Berke SJ, Dustin L, Noecker R. Endoscopic cyclophotocoagulation combined with phacoemulsification versus phacoemulsification alone in medically controlled glaucoma. *J Cataract Refract Surg.* 2014;40(8):1313–1321. doi:10.1016/j.jcrs.2014.06.021
17. Lin SC. Vascular effects on ciliary tissue from endoscopic versus trans-scleral cyclophotocoagulation. *Br J Ophthalmol.* 2006;90(4):496–500. doi:10.1136/bjo.2005.072777
18. Pantcheva MB, Kahook MY, Schuman JS, Noecker RJ. Comparison of acute structural and histopathological changes in human autopsy eyes after endoscopic cyclophotocoagulation and trans-scleral cyclophotocoagulation. *Br J Ophthalmol.* 2007;91(2):248–252. doi:10.1136/bjo.2006.103580
19. Smith M, Byles D, Lim L-A. Phacoemulsification and endocyclophotocoagulation in uncontrolled glaucoma: three-year results. *J Cataract Refract Surg.* 2018;44(9):1097–1102. doi:10.1016/j.jcrs.2018.06.025
20. Siegel MJ, Boling WS, Faridi OS, et al. Combined endoscopic cyclophotocoagulation and phacoemulsification versus phacoemulsification alone in the treatment of mild to moderate glaucoma: ECP and phaco versus phaco alone. *Clin Experiment Ophthalmol.* 2015;43(6):531–539. doi:10.1111/ceo.12510
21. Dorairaj SK, Seibold LK, Radcliffe NM, et al. 12-Month outcomes of goniotomy performed using the Kahook dual blade combined with cataract surgery in eyes with medically treated glaucoma. *Adv Ther.* 2018;35(9):1460–1469. doi:10.1007/s12325-018-0755-4
22. Clement CI, Kampougeris G, Ahmed F, Cordeiro MF, Bloom PA. Combining phacoemulsification with endoscopic cyclophotocoagulation to manage cataract and glaucoma: endoscopic cyclophotocoagulation. *Clin Experiment Ophthalmol.* 2013;41(6):546–551. doi:10.1111/ceo.12051
23. Weiner Y, Severson ML, Weiner A. Intraocular pressure 3 to 4 hours and 20 hours after cataract surgery with and without ab interno trabeculectomy. *J Cataract Refract Surg.* 2015;41(10):2081–2091. doi:10.1016/j.jcrs.2015.10.048

## Clinical Ophthalmology

### Publish your work in this journal

Clinical Ophthalmology is an international, peer-reviewed journal covering all subspecialties within ophthalmology. Key topics include: Optometry; Visual science; Pharmacology and drug therapy in eye diseases; Basic Sciences; Primary and Secondary eye care; Patient Safety and Quality of Care Improvements. This journal is indexed on PubMed

Submit your manuscript here: <https://www.dovepress.com/clinical-ophthalmology-journal>

Dovepress

Central and CAS, and is the official journal of The Society of Clinical Ophthalmology (SCO). The manuscript management system is completely online and includes a very quick and fair peer-review system, which is all easy to use. Visit <http://www.dovepress.com/testimonials.php> to read real quotes from published authors.