

Treatment of Auricular Pseudocyst with Intralesional Steroid: A Study with Short-Term Follow-Up

This article was published in the following Dove Press journal:
Clinical, Cosmetic and Investigational Dermatology

Ramesh Parajuli ¹
Jiwan Kshetry²

¹Department of ENT, Chitwan Medical College, Bharatpur, Nepal; ²Department of Pathology, Narayani Samudayik Hospital, Bharatpur, Nepal

Introduction: A pseudocyst is an uncommon, painless, benign cystic swelling on the lateral surface of the auricle with an unknown etiology. Various treatment modalities have been used with varying rates of success as this condition has high propensity for recurrence. We have used a minimally invasive treatment method for this condition to evaluate its efficacy in our setup.

Patients and Methods: This is a prospective study carried out in the department of ENT of Chitwan Medical College from May 2018 to April 2020. Complete aspiration of the pseudocyst with intralesional steroid (40 mg, triamcinolone acetonide) injection was done in 30 patients. They were followed up weekly for 4 weeks. Additional doses were injected in cases with persistence or recurrence before 3 weeks. Disappearance of the swelling, considered treatment success, was the main outcome. The total number of doses required for the complete resolution of the swelling along with the number of recurrences or complications, if any, were noted at the final follow-up at 4 weeks.

Results: All of our patients responded completely with intralesional triamcinolone. However, the total dose requirement for different patients varied. Out of the 30 patients, 21 (70%) responded to the single dose of the drug. Six (20%) required a second dose, while the remaining 3 (10%) patients required a third dose for complete resolution of the swelling. All three (10%) patients who received a third dose of triamcinolone complained of skin thickening, but there was no obvious cosmetic deformity.

Conclusion: Aspiration with intralesional steroid injection shows an immediate positive response in patients with auricular pseudocyst. It can achieve complete resolution of the swelling without any serious complications. Thus, it appears to be a simple and effective management of the condition in the short term.

Keywords: pseudocyst, pinna, intralesional, triamcinolone

Introduction

An auricular pseudocyst is a relatively uncommon benign condition. It presents as a spontaneous, painless, cystic swelling occurring on the lateral surface of pinna. It is called a pseudocyst because it lacks a true epithelial lining. On examination there is usually localized, oval-shaped swelling sized 1 to 5 cm containing 0.5 to 10 mL sterile fluid which is serous or serosanguinous in nature.¹ It is an idiopathic condition. However, trivial trauma that occurs following various daily activities such as sleeping on hard pillows, wearing helmets, earphones or headphones, rubbing and ear-pulling have been considered as predisposing factors. The most common sites of involvement

Correspondence: Ramesh Parajuli
Department of ENT, Chitwan Medical College, P.O. Box 42, Bharatpur 10, Nepal
Tel +977-56532933
Email drrameshparajuli@gmail.com

include the scaphoid fossa, triangular fossa and concha. It has a predilection for males, the reason for which is not known. It usually affects a unilateral auricle and is more frequently seen in adults. However, cases of bilateral auricular involvement and presentation in the pediatric age group have also been reported.¹ Exact etiology of this condition is not known. Chronic low-grade trauma and congenital embryonic dysplasia with residual tissue planes in the auricular cartilage are the two main theories to explain the formation of the auricular pseudocyst.² There are various treatment modalities for this condition ranging from simple aspiration of fluid with and without positive pressure dressing, to more invasive surgical procedures.³ The aim of the management of this condition is to treat the pseudocyst while maintaining the normal anatomical architecture of the auricle and avoiding complications and recurrences. Medical treatments include systemic (oral/intramuscular) or intralesional steroid therapy and intralesional sclerosing agents such as minocycline, tincture of iodine, trichloroacetic acid and fibrin glue. Surgical treatment options include aspiration and pressure dressing with plaster of paris, bolsters or button, quilting suture with corrugated rubber drain, incision and drainage with mastoid dressing, cartilage curettage with drainage tube, and open de-roofing and cartilage window procedure. Although multiple treatment options are available for this condition, there is no gold standard treatment because the less invasive methods tend to have higher rates of recurrences while more invasive methods have higher risk of complications such as perichondritis and cauliflower-like deformity of the auricle.⁴

Intralesional steroid therapy is a minimally invasive treatment option for the auricular pseudocyst. It is a simple and short procedure that can be carried out easily in an outpatient department (OPD). That is also convenient for both the surgeons and the patients. We carried out this study with an aim to evaluate the efficacy of this therapy in our clinical setup. There is no documented report on this modality of therapy for pseudocysts being tried in our country so far.

Patients and Methods

This is a prospective study carried out in the department of ENT of Chitwan Medical College from May 2018 to April 2020. The sample size for the study was calculated using a survey system. Accordingly, 30 patients clinically diagnosed with an auricular pseudocyst were selected for this study. Patients were fully explained about the nature of the disease and available treatment options including probable therapeutic complications and recurrence.

Patients of both genders having primarily been diagnosed with auricular pseudocyst of age more than 14 years were included in the study. Patients with external ear infection and diabetes mellitus were excluded. Informed consents were taken. Similarly, the patients whose photographs were used in this study provided informed consent for the images to be published. The institutional review board of the medical college approved this study. This study was conducted in accordance with the Declaration of Helsinki. All of the patients were males. Their age range was from 19 to 53 years.

Under aseptic conditions, complete aspiration of the pseudocyst was performed with a 23 gauge needle attached to a 3 mL syringe. Another syringe was loaded with 1 mL of 40 mg triamcinolone acetonide solution beforehand. While keeping the needle in situ, the syringe with aspirated fluid was removed and the syringe with triamcinolone acetonide was attached. Then, the drug was injected into the pseudocyst cavity (Figure 1). Spirit swab was used gently to press the needle puncture site for a few seconds to stop bleeding and to prevent escape of medicine from the needle puncture hole. Local anesthetic was not used as it was a brief procedure with mild discomfort. No pressure dressing was applied either. Oral ciprofloxacin 500 mg twice daily for a week was prescribed to the patients to prevent perichondritis as this is a minimally invasive procedure carried out in the OPD. Each patient was followed up weekly for 4 weeks. In the case of persistence or recollection of fluid (visual observation confirmed by needle aspiration on first, second or third follow-up), an additional 40 mg triamcinolone was injected on a weekly basis for a maximum of 3 doses in total. No further steroid injection was carried out on fourth follow-up as this was the time to evaluate for overall treatment efficacy. The calculation of the total number of doses injected and the resolution or persistence of the pseudocyst was noted at 4 weeks. The complete resolution of the auricular swelling was considered treatment success. The serious complications of the treatment such as perichondritis, perichondrial abscess or cartilage deformity, if present, were noted.

Results

Of the 30 patients involved in this study, all of them were adult males (100%). The age range of the patients was from 19 to 53 years. The most commonly affected age group was 31–40 years, with 18 (60%) patients (Table 1). None of the patients had bilateral disease. The most

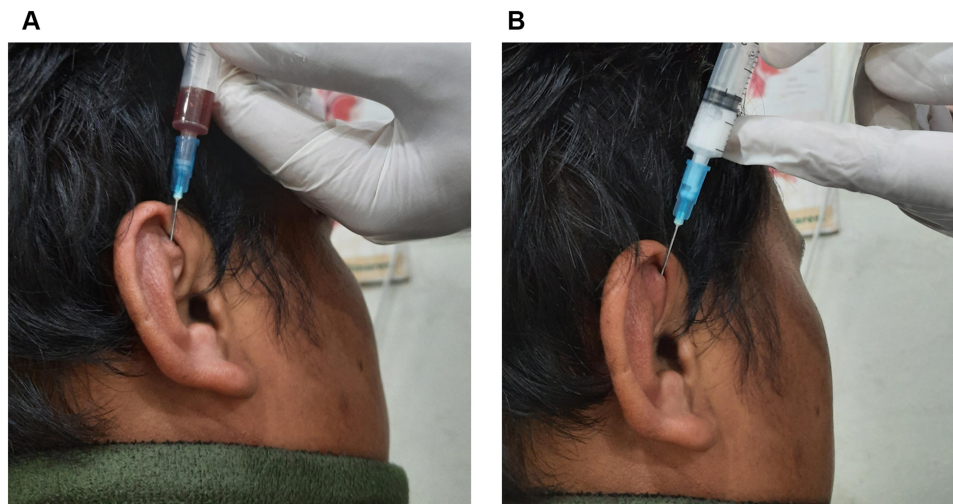


Figure 1 (A) Aspiration of the auricular pseudocyst. (B) Intralesional triamcinolone injection.

common site of involvement by the disease was the scaphoid fossa, followed by the triangular fossa and the concha region (Table 2). However there was a case of auricular pseudocyst diffusely involving the concha and scaphoid fossa (Figure 2). The auricular pseudocysts encountered in our study were small in size, with the volume of fluid content ranging from 0.5 to 3 mL. The response of intralesional steroid therapy varied among our patients (Table 3). Out of the total 30 patients, 21 (70%) patients had complete disappearance of the pseudocyst with a single dose of therapy. Six (20%) required a second dose at the second follow-up while 3 (10%) patients required a third dose of steroid. As all of our

patients responded to up to 3 doses, none had persistent swelling at the final follow-up at 4 weeks (Figure 3). Serious complications such as perichondritis, perichondrial abscess or cauliflower-like deformity were not seen in any of our patients. However, 3 (10%) patients who had received a third dose of triamcinolone complained of skin thickening, but there was no obvious visible cosmetic deformity.

Discussion

An auricular pseudocyst presents as a benign, noninflammatory swelling that develops spontaneously. It is painless with itching sensation in some patients while the majority have cosmetic concern. Histological examination reveals an intercartilaginous cavity without a true epithelial lining, and with thinned cartilage and hyaline degeneration, along with cystic space and granulation tissue.⁵ It was first described by Hartmann in 1846 but was first described in the English literature by Engle in 1966. It is found in all racial groups, although initially it was reported in a Chinese population.

The true incidence of auricular pseudocysts is difficult to measure as the terms auricular seroma and auricular hematoma have also been used synonymously by some authors.^{6–8} Some authors consider auricular seroma, auricular pseudocyst and otohematoma as the spectrum of the same disease process.⁹ Kikura et al have described the true differences between these three conditions although there can be overlap of pathophysiology of these conditions.⁸ In the auricular pseudocyst, the viscous fluid collects in the intracartilaginous space. But in the otohematoma there is collection of blood in the subperichondrial plane, while in

Table 1 Age Distribution of the Patients (n=30)

Age Group	Number of Patients
<20 years	1
20–30 years	6
31–40 years	18
41–50 years	4
>50 years	1

Table 2 Sites of Involvement (n=30)

Site	Number (%) of Patients
Scaphoid fossa	15 (50%)
Triangular fossa	9 (30%)
Concha	5 (17%)
Diffuse involvement of concha and scaphoid fossa	1 (3%)

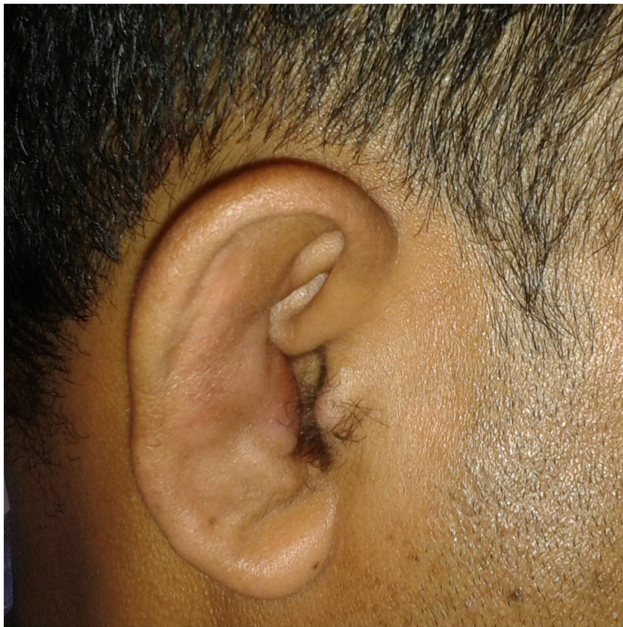

Figure 2 Diffuse auricular pseudocyst involving the concha and scaphoid fossa.

case of auricular seroma there is collection of the fluid above the perichondrium that is in the hypodermis region. The anatomical location of the fluid is usually not mentioned in many studies. It has been said that the intracartilaginous location of the pseudocyst is made apparent by incision as there is a distinct gritty sensation felt when incising through the fibrotic cartilaginous wall of the pseudocyst.¹⁰ This sensation can be missed with needle aspiration. Hence, it may be difficult to determine the exact anatomical site clinically. Thus, the invasive procedures requiring incision of the pseudocyst and the subsequent histological examination of the specimen should be carried out to determine the location of the fluid.

As the exact etiology of this condition is not known, two hypotheses have been put forward for its etiopathogenesis.² According to the first, trauma to the auricle with low intensity and chronic duration releases lysosomal enzymes that induce cartilage degeneration. This causes progressive dilatation and cyst formation

within the auricular cartilage. All of our patients were thoroughly asked about any history of trauma to find out possible traumatic etiology but none of them gave any significant history of trauma or insect bite. They also denied a personal habit of ear pulling or rubbing. There was no known history of drug or food allergy. They did not have any history of skin diseases such as eczema and atopic dermatitis. However, one thing was common in all of our patients: they commuted to and from their workplaces daily on motorbikes. The trauma and friction from helmet use could be the factor responsible for low-grade trauma to the auricle. The hypothesis of traumatic etiology can be supported by the examination of the isoenzymes in the aspirated fluid. It has been found that the auricular cartilage is rich in two isoenzymes, lactate dehydrogenase (LDH) 4 and 5. The raised level of these in the pseudocyst fluid is probably due to degeneration of cartilage by the repeated minor trauma.¹¹ However, this theory was not supported by other authors who did not find a raised level of the enzymes on the fluid.¹² We did not measure LDH as it would add further financial burden to the patient.

According to the second hypothesis the congenital embryonal dysplasia of the auricular cartilage is thought to be responsible for the formation of a pseudocyst. The auricle develops from six tubercles around the first and the second branchial arches. Residual tissue planes present within the cartilages due to the maldevelopment of these arches which may re-open later in life, resulting in a pseudocyst. This hypothesis was supported by the study of Zhu and Wang, who histologically examined 42 auricles from the 18 fetuses and 3 adults and found the intracartilaginous fibrous tissue with blood vessels and lymphatics in 12 (29%) ears and interruption of the auricular cartilage in 22 (52%) ears.¹³ The intracartilaginous connective tissue with blood vessels and lymphatics linked together with the connective tissue outside the auricular cartilage in the other (10%) cases. Hence, these findings support the concept of potential intracartilaginous space. Probably, another stimulus is necessary to cause re-opening and dilatation of this potential space resulting in pseudocyst formation.¹² Further investigations are required to determine the etiology of this condition.

Presumptive diagnosis of this condition can be made easily with history and clinical examination. It can be confirmed with aspiration of straw-colored viscous fluid like olive oil. Occasionally, there can be blood-tinged fluid due to breakage of capillaries during needle aspiration of

Table 3 Frequency of Intralesional Steroid Injection and Response Rate (n=30)

Number of Steroid Injections	Patients (%) with Resolution of Pseudocyst
Single dose only	21 (70%)
Two doses	6 (20%)
Three doses	3 (10%)

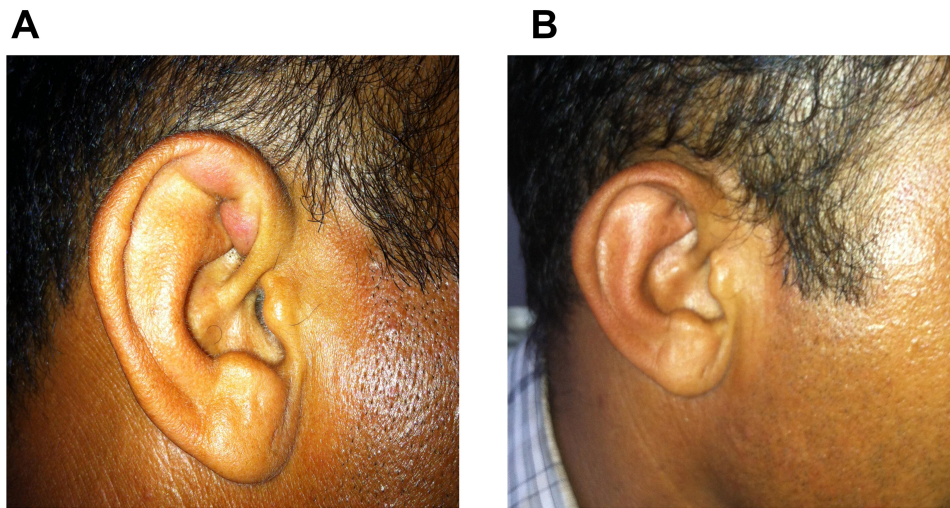


Figure 3 (A) Auricular pseudocyst before treatment. (B) Post-treatment appearance of the auricle after 4 weeks.

the fluid, as happened in one of our cases. Differential diagnosis of this condition includes hematoma, cellulitis, relapsing polychondritis, chondrodermatitis nodularis helix, chondroma, sebaceous cyst and skin adnexal neoplasms. History and clinical examination along with needle aspiration are generally enough to exclude a pseudocyst from the other diseases.

There are various treatment methods such as aspiration, incision and drainage, compression methods, systemic or topical steroid, sclerosing agents and surgical methods. Both medical and surgical treatment methods have a varying rate of success and complications so there is no uniformity among otolaryngologists to consider any particular method as the gold standard. Both systemic as well as local steroids have been used to treat this condition. The use of systemic steroid is not only controversial but also has additional risk of systemic side effects.¹⁴ So, its use has been abandoned. However, the rate of success with intralesional steroid therapy has been variable as reported in the literature.⁷ The varied response rate of intralesional steroid therapy among various studies is shown in [Table 4](#).

In our study, 70% of the patients recovered after the first injection and another 20% and 10% recovered after the second and third doses respectively. There were no serious complications. Patigaroo et al reported a success rate of 57% with intralesional steroid injection plus pressure dressing, in their study.³ A similar success rate was achieved by Miyamoto et al, in their study where they found 2 doses of intralesional steroid to be effective in the majority of the patients (50%); however, one patient

required 11 doses and developed auricular deformity.¹⁵ Im et al also treated their patients successfully with intralesional steroid. They found just a single dose was effective in 41.2% of the patients, while 44.1% and 14.7% of the patients received intralesional steroid two and three times respectively in a weekly interval.¹⁶ Similarly, Bhandary and Mannil demonstrated a 40% success rate in pseudocyst patients with the weekly intralesional steroid for 3 weeks.⁶ Another study conducted by Rai and Shetty also demonstrated promising results with aspiration with a steroid injection treatment method as they found it effective in all of 30 patients without any recurrence during 1-year follow-up.⁷ In a study by Juan, 60% of the patients had improvement of this condition with just a single dose of intralesional steroid, while 30% of patients required a second dose and the remaining 10% had their pseudocyst disappearance after the third dose. Hence, they advocated this type for treatment as worth attempting.¹⁷ Kim et al successfully treated a recurrent case of auricular pseudocyst with intralesional steroid and clip compression dressing having good cosmetic outcome without further recurrences during 6-month follow-up.² Karabulut et al also recommended this type of treatment method for non-recurrent cases of pseudocyst.¹⁸ In a busy setup like ours, intralesional steroid therapy can be a time-saving, simple and acceptable treatment alternative.

In our study, the total number of injected steroids was limited to a maximum 3 doses only, to avoid possible complications of multiple steroid injections such as atrophy of auricular cartilage, deformity and skin pigmentation. There have been reports of complications of intralesional steroid

Table 4 Comparison of the Response Rates of Intralesional Steroid Therapy in Various Studies

Authors	Study Type	Total Number of Patients with Intralesional Steroid Therapy	Total Number of Doses	Response Rate	Recurrence	Follow-Up	Complications
Patigaroo et al ³	P	7	3	57.1%	42.8%	3 months	Thickened pinna (14.2%)
Bhandary and Mannil ⁶	P	10	3	40%	60%	N.A.	Thickened pinna (30%)
Rai and Shetty ⁷	P	30	1	100%	None	1 year	Nil
Miyamoto et al ¹⁵	P	8	(1–11) 1 2 >2	(87.5%) 12.5% 50% 25%	12.5%	1 month	Auricular deformity (12.5%)
Im et al ¹⁶	R	34	(3) 1 2 3	(100%) 41.2% 44.1% 14.7%	None	1 year	Nil
Juan ¹⁷	P	10	(3) 1 2 3	(100%) 60% 30% 10%	None	2 months	Nil
Our study	P	30	(3) 1 2 3	(100%) 70% 20% 10%	None	1 month	Mild thickening of pinna (10%)

Abbreviations: N.A., not available; P, prospective; R, retrospective.

therapy.³ But we did not encounter any serious complications such as perichondritis, perichondrial abscess or cauliflower-like deformity, although 3 (10%) patients complained of mild skin thickening. Thickening of the pinna was also documented as the complication of this type of therapy in the studies by Patigaroo et al and Bhandary and Mannil.^{3,6} There was no gross cosmetic deformity, hence the patients were reassured. Since this study shows a satisfactory short-term result, this appears to be an acceptable and convenient treatment method for both the surgeon and the patients who are apprehensive of surgery. The more invasive surgical procedures such as derroofing of the pseudocyst wall are reserved for the late or multiple recurrences.

There can be multiple mechanisms of action of the intralesional steroid which effectively treats various conditions such as pseudocyst, hemangioma, otohematoma, seroma and keloids. Examples of such possible mechanisms include regulation of cytokine expression resulting in preferential blockade of pro-inflammatory cytokines, and angiostatic effects causing vasoconstriction, pre-capillary sphincter narrowing and the coating of endothelial walls by leukocytes, thereby decreasing vascular permeability.¹⁶

This is an observational study in a small number of patients having a small-sized nonrecurrent auricular pseudocyst of short duration. This study can only generate level 4 evidence. Proper randomization could not be achieved in our study as there was a similar group of patients with the majority being middle-aged men, hence the sample obtained may not provide an accurate representation of the population, so there can be selection bias. Similarly, there seems a chance of interpretation bias in this study as all of our patients positively responded to up to 3 doses of intralesional steroids, although a small number of patients were treated with short-term follow-up. The incidence of later recurrences of this condition is not included in this study, hence it limits the generalization of the results of this study. These types of bias can be minimized by using randomization and control groups in a large number of patients with longer follow-up. It would have been more informative if we had carried randomized control trials in a large number of patients with long-term follow-up comparing different treatment modalities measuring both the short and long-term outcomes, early and late recurrences and the true incidence of complications

over a long run of time. Long-term follow-up was not possible in our study as the patients were referred from remote villages by the primary care physicians. Patients are often lost to follow-up once their condition improves knowing that the condition is benign without any risk of malignancy.

Conclusion

Intralesional steroid therapy is a minimally invasive treatment modality for the auricular pseudocyst. It has an immediate positive response without serious complications. Small and nonrecurrent auricular pseudocysts with short history can be satisfactorily treated with this therapy. The conclusion from this study cannot be generalized due to its small sample size. Thus, randomized control trials in a large number of patients comparing different treatment modalities are recommended to generate a higher level of evidence. Similarly, studies with longer follow-up are necessary to measure efficacy of the therapy and the prevalence of recurrence more accurately.

Author Contributions

All authors made a significant contribution to the work reported, whether that is in the conception, study design, execution, acquisition of data, analysis and interpretation, or in all these areas; took part in drafting, revising or critically reviewing the article; gave final approval of the version to be published; have agreed on the journal to which the article has been submitted; and agree to be accountable for all aspects of the work.

Disclosure

The authors report no conflicts of interest in this work.

References

1. Dutsch-Wicherek M, Trzebuniak I, Szymońska I, et al. Bilateral pseudocyst of the auricles in a 4-week neonate-case report and world literature review. *Int J Pediatr Otorhinolaryngol*. 2019;122:1–5. doi:10.1016/j.ijporl.2019.03.027

2. Kim TY, Kim DH, Yoon MS. Treatment of a recurrent auricular pseudocyst with intralesional steroid injection and clip compression dressing. *Dermatol Surg*. 2009;35(2):245–247. doi:10.1111/j.1524-4725.2008.34416.x
3. Patigaroo SA, Mehfooz N, Patigaroo FA, Kirmani MH, Waheed A, Bhat S. Clinical characteristics and comparative study of different modalities of treatment of pseudocyst pinna. *Eur Arch Otorhinolaryngol*. 2012;269(7):1747–1754. doi:10.1007/s00405-011-1805-6
4. Bhat VS, Shilpa N, Ks R. Deroofing of auricular pseudocyst: our experience. *J Clin Diagn Res*. 2014;8(10):KC05-KC7. doi:10.7860/JCDR/2014/6788.3956
5. Ramadass T, Ayyaswamy G. Pseudocyst of auricle - etiopathogenesis, treatment update and literature review. *Indian J Otolaryngol Head Neck Surg*. 2006;58(2):156–159.
6. Bhandary S, Mannil TV. A comparative study in the management of auricular pseudocysts. *Indian J Otolaryngol Head Neck Surg*. 2000;52(3):246–250. doi:10.1007/BF03006193
7. Rai S, Shetty D. Aspiration and steroid injection-an effective approach for auricular seroma. *Iran J Otorhinolaryngol*. 2019;31(106):267–271.
8. Kikura M, Hoshino T, Matsumoto M, Kikawada T, Kikawada K. Auricular seroma: a new concept, and diagnosis and management of 16 cases. *Arch Otolaryngol Head Neck Surg*. 2006;132(10):1143–1147. doi:10.1001/archotol.132.10.1143
9. Kopera D, Soyer HP, Smolle J, Kerl H. “Pseudocyst of the auricle”, othematoma and otoseroma: three faces of the same coin? *Eur J Dermatol*. 2000;10(6):451–454.
10. Glamb R, Kim R. Pseudocyst of the auricle. *J Am Acad Dermatol*. 1984;11(1):58–63. doi:10.1016/S0190-9622(84)70135-6
11. Chen PP, Tsai SM, Wang HM, et al. Lactate dehydrogenase isoenzyme patterns in auricular pseudocyst fluid. *J Laryngol Otol*. 2013;127(5):479–482. doi:10.1017/S0022215113000534
12. Choi S, Lam K, Chan KW, Cohadially FN, Anthony SM. Endochondral pseudocyst of the auricle in Chinese. *Arch Otolaryngol*. 1984;110(12):792–796. doi:10.1001/archotol.1984.00800380022007
13. Zhu L, Wang X. Histological examination of the auricular cartilage and pseudocyst of the auricle. *J Laryngol Otol*. 1992;106(2):103–104. doi:10.1017/S002221510011881X
14. Kanotra SP, Lateef M. Pseudocyst of pinna: a recurrence-free approach. *Am J Otolaryngol*. 2009;30(2):73–79. doi:10.1016/j.amjoto.2008.02.008
15. Miyamoto H, Oida M, Onuma S, Uchiyama M. Steroid injection therapy for pseudocyst of the auricle. *Acta Derm Venereol*. 1994;74:140–142.
16. Im GJ, Chae SW, Choi J, Kim YS, Kim WJ, Jung HH. Intralesional steroid injection for the management of othematoma. *Otolaryngol Head Neck Surg*. 2008;139(1):115–119. doi:10.1016/j.otohns.2008.01.006
17. Juan KH. Pseudocyst of the auricle: steroid therapy. *Auris Nasus Larynx*. 1994;21(1):8–12. doi:10.1016/S0385-8146(12)80003-4
18. Karabulut H, Acar B, Selcuk K. Treatment of the nontraumatic auricula pseudocyst with aspiration and intralesional steroid injection. *N Engl J Med*. 2009;26:117–119.

Clinical, Cosmetic and Investigational Dermatology

Dovepress

Publish your work in this journal

Clinical, Cosmetic and Investigational Dermatology is an international, peer-reviewed, open access, online journal that focuses on the latest clinical and experimental research in all aspects of skin disease and cosmetic interventions. This journal is indexed on CAS.

The manuscript management system is completely online and includes a very quick and fair peer-review system, which is all easy to use. Visit <http://www.dovepress.com/testimonials.php> to read real quotes from published authors.

Submit your manuscript here: <https://www.dovepress.com/clinical-cosmetic-and-investigational-dermatology-journal>