

Marfan syndrome with acute abdomen: a case report

Beyazit Zencirci

Kahramanmaras Sutcu Imam
University Medical Faculty,
Department of Anesthesiology and
Reanimation Kahramanmaras, Turkey

Introduction: Marfan syndrome is an autosomal dominant connective tissue disorder characterized by a combination of clinical manifestations in different organ systems. Patients with Marfan syndrome (MFS) whose lifetimes are extended may be encountered as acute abdomen (appendicitis) cases apart from the obligatory reasons and emergencies arising naturally out of their disease, as in the case reported.

Case presentation: In a 28-year-old Turkish male, arachnodactyly, pectus excavatum, kyphoscoliosis and, according to pulmonary roentgenogram, a density increase in the left apical field were detected. In addition, according to the echocardiographic examination, Ebstein's anomaly, mitral valve prolapse, pulmonary hypertension, and inferior deficiency of mitral, aorta, and tricuspid valves were present. The patient was planned to be operated on with the prediagnosis of acute abdomen.

Conclusion: Taking into consideration the pathologies that may accompany MFS and the probable future complications, the patients must be closely monitored during anesthesia applications and required measures should be taken beforehand.

Keywords: Marfan syndrome, acute abdomen

Introduction

Marfan syndrome (MFS) is an autosomal dominant condition of abnormal connective tissue. The gene that causes MFS, *FBNI*, is located on chromosome 15 and encodes fibrillin-1. The condition affects the skeletal, skin/integumentary, ocular, pulmonary, and cardiovascular systems.¹

Although MFS is a multisystem disorder, the most clinically significant manifestation is cardiovascular disease. Because of the abnormal supporting tissues of the aorta and cardiac valves, individuals with MFS are predisposed to the development of aortic dilatation and valvular insufficiency. Mitral valve prolapse with regurgitation is common and can lead to the development of endocarditis or congestive heart failure. The natural history of the disease includes a substantial risk of sudden and premature death from aortic dissection. Life expectancy is almost halved in patients with MFS, cardiovascular complications being responsible for 95% of deaths.² However, with rapid advances in medical and surgical treatments, together with reduction of physical and hemodynamic stress, effective management of patients has improved life expectancy.³

The MFS patients whose lifetimes are thereby extended may be encountered as acute abdomen (appendicitis) cases apart from the obligatory reasons and emergencies arising naturally out of their disease, as in the case reported here.

Correspondence: Beyazit Zencirci
M. Akif Inan Mah, Alparslan Turkes
Bulvari, Seyhan Apt. No: 209 D: 5
Merkez-Kahramanmaras, Turkey
Tel +90 344-2258300
Fax +90 344-2258303
Email bzencirci@fastmail.fm

Case presentation

The case was 28-year-old Turkish male, 40 kg in weight and 172 cm tall. It was learned/understood from the anamnesis that the patient's elder brother had the same disease and that two other brothers died after birth (unexplained sudden death). Blindness in the left eye (probably ocular features of MFS), long arms and legs, arachnodactyly (Figure 1), kyphoscoliosis, pectus excavatum (Figure 2), and severe pes planus (talipes calcaneovalgus) (Figure 3) were found to be present in the physical examination.

According to chest radiography, density increase in the left apical field (hyperlucency) (thought to be secondary to bullous structure), transpiring in the ascendent aorta, a rightward shift of the heart (due to the effect of the kyphoscoliosis and pectus excavatum), and thoracolumbar scoliosis (kyphoscoliosis) with a rightward aperture were detected (Figure 4). In addition, according to the echocardiographic examination, Ebstein's anomaly, mitral valve prolapse, pulmonary hypertension, and inferior deficiency of mitral, aorta, and tricuspid valves were present. Moreover, a right bundle block (secondary to Ebstein's anomaly) was observed in the electrocardiographic examination. The patient was planned to be operated on with the prediagnosis of acute abdomen.

During the preoperative laboratory examination no other pathology was detected besides leucocytosis ($15.8 \times 10^9/L$), CRP elevation (15.6 mg/dL), and albumin decrease (33 g/L). Preoperative blood gas values were in the normal range. A moving and soft tissue structure (connection with decreasing aortic dissection) disturbing phleb of the aorta lumen inside the composition of thoracic descendent aorta and abdominal aorta was observed in the abdominal ultrasonography. However, no findings to support the presence of acute aorta dissection were found in tomographic examination.

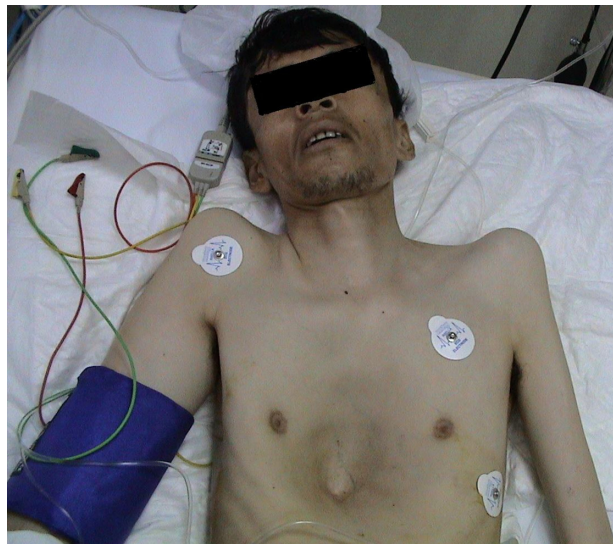

Figure 2 Pectus excavatum observed in the patient.

The patient was being monitored by the cardiology outpatient clinic due to MFS and Ebstein's anomaly. The prescribed drugs were metoprolol, digoxin, and alprazolam. More importantly, previous detailed genetic research on the patient showed that there was a mutation in the *FBNI* gene (15 g21.1) on the 15th chromosome.

Invasive arterial monitoring was conducted preoperatively from the radial artery in case prophylaxis to prevent endocarditis and aspiration pneumonia was applied. Due to the risks presented by the skeleton and pulmonary anomaly, central venous catheterization was applied from the left femoral vein with the help of local anesthesia. Two vascular accesses were opened and, as one of these was used for anesthesia induction, nitroglycerine infusion was started from the other vascular access in order to repress/prevent

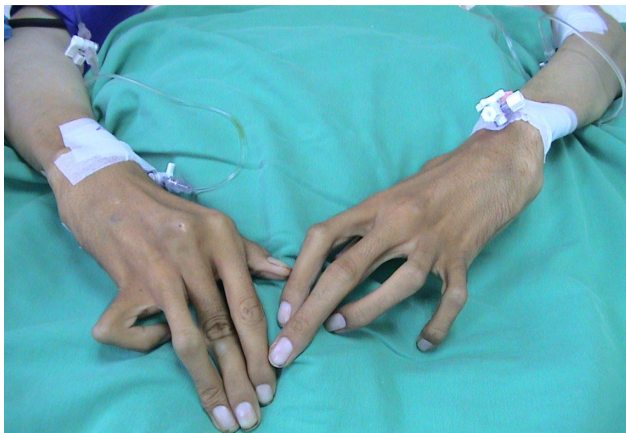

Figure 1 Patient's abnormally long and slender fingers (arachnodactyly).

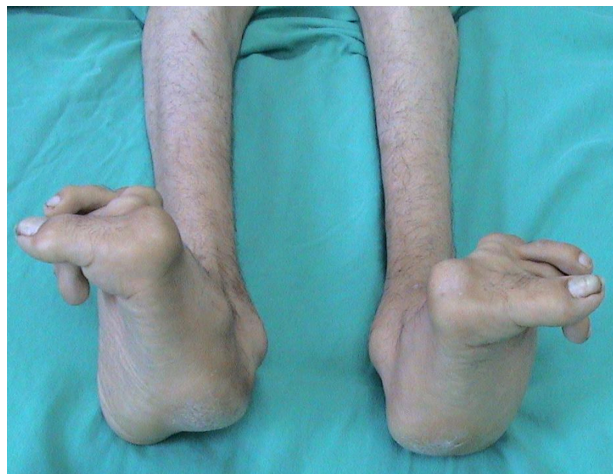

Figure 3 Severe pes planus (talipes calcaneovalgus).

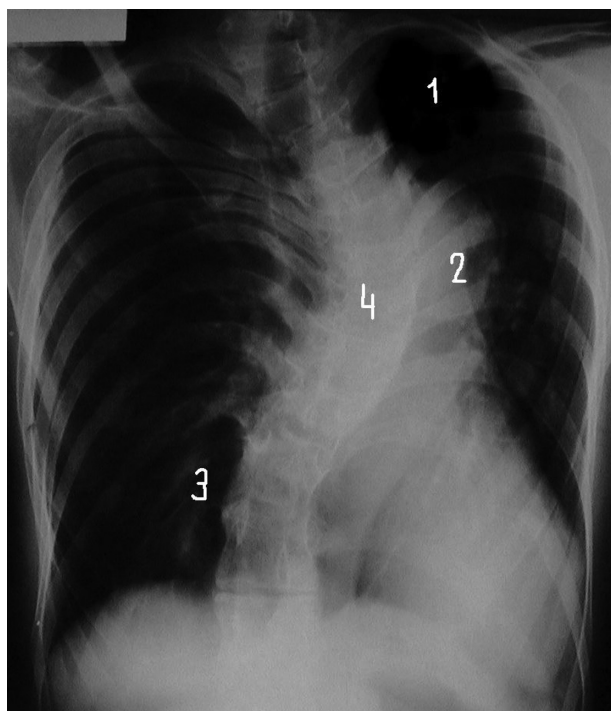


Figure 4 X-ray during preoperative preparation. 1, density increase in the left apical area; 2, transpiring in ascendent aorta; 3, a rightward shift of the heart; 4, scoliosis.

hypertension. In view of the cardiac pathology of the case, etomidate–propofol combination (co-induction) was administered for induction. Neuromuscular blocking was achieved with atracurium besylate and intubation was carried out without any stress response (hypertension and tachycardia) under the effect/pressure of sufficient anesthesia depth and nitroglycerine infusion. Because of the risk of pneumothorax, end-tidal carbon dioxide (ETCO₂), peak airway pressure and mean airway pressure values were continuously controlled and pressure-controlled mechanical ventilation was applied through low-pressure and in a way to ensure that positive end-expiratory pressure = 0 mmHg. No negativity/pathology concerning the blood gas values was encountered during the operation. At the end of the operation, the patient, in whom cutaneous and subcutaneous local anesthetic infiltrations were applied, was extubated to reverse the neuromuscular blocking effect while nitroglycerine infusion continued. While the patient was recovering consciousness, he was taken to the intensive care unit (ICU) for monitoring and intravenously patient-controlled analgesia and nitroglycerine infusion continued. The patient was observed in the ICU for 2 days after the operation and was transferred to the surgical clinic without any complications. The case was discharged from the hospital on the sixth postoperative day.

Discussion

MFS primarily affects cardiovascular, skeletal, ocular, integumentary and pulmonary systems.² Cardiovascular complications are of special importance as they constitute the primary cause of mortality.³ The most serious medical complication of MFS is dilation and dissection of the ascending aorta, which can lead to aortic rupture and premature death if untreated. But management routinely includes use of beta-adrenergic blockers, which have been shown to slow the progressive widening of the aorta in many patients with MFS.⁴ Other cardiovascular complications include mitral valve prolapse, aortic regurgitation, tricuspid valve prolapse, and dilation of the main pulmonary artery.

The skeletal manifestations of the condition include tall stature; thin habitus with increased arm span-to-height ratio; long, slender fingers (arachnodactyly); elongated face; high arched palate; pes planus; joint laxity; scoliosis; and pectus deformity. Ectopia lentis (lens dislocation) is a hallmark ocular feature present in approximately 60% of patients. Other ocular findings include corneal flatness, increased axial globe length leading to near-sightedness, and hypoplastic irides. Spontaneous pneumothorax or apical blebs are the most common pulmonary abnormalities. Other cardinal features involve skin, integument, and dura, and include striae atrophicae (ie, stretch marks), recurrent hernias, and lumbosacral ectasia.

The progressive and potentially fatal clinical features of MFS make early diagnosis very important. Due to the lack of a molecular diagnostic test, diagnosis depends on the revised (Ghent) clinical criteria.⁵ The most prominent major criteria are: a constellation of skeletal manifestations including pectus carinatum or excavatum, reduced upper-to-lower-segment ratio, or arm-span-to-height ratio >1.05, scoliosis, and reduced elbow extension; ectopia lentis; dilatation or dissection of the ascending aorta; lumbosacral dural ectasia; and inheritance of a genotype previously associated with classic MFS or an unequivocal family history.⁵ Spontaneous pneumothorax, striae atrophicae, and recurrent hernias are also useful signs for diagnosis. Diagnostic dilemmas arise due to considerable inter- and intrafamilial variability.

Cardiovascular assessment is mandatory before embarking on surgery due to the threat to life from mitral valve prolapse and aortic dilatation. Blood pressure may be maintained below normal with antihypertensive agents. Individuals are at risk from spontaneous pneumothorax, usually arising out of an apical bulla, which may complicate a present compromise.⁶

Management of anesthesia for MFS has specific precautions for valvular diseases, thoracic aortic aneurysm, and skeletal joint laxity. Patients with MFS must be carefully assessed preoperatively for specific complications. Antibiotic prophylaxis should be given before dental and other surgical procedures. The anesthesiologist should be prepared for a potentially difficult intubation.⁶

No single intraoperative anesthetic agent or technique has demonstrated superiority. But the anesthetic technique chosen should not decrease myocardial contractility and should avoid sudden increases in contractility, in order to minimize the risk of aortic dissection or rupture. Perioperative hypertension or hypotension must be avoided. The presence of significant aortic insufficiency warrants that the blood pressure be high enough to provide adequate coronary blood flow but should not be so high as to risk dissection of the aorta. Preoperative echocardiography should be considered so as to exclude cardiac or aortic pathology. A patient has been reported who had acute, intraoperative coronary artery obstruction (presumably not a coronary air embolus).⁶

Patients may have significant pulmonary problems including restriction of lung function due to pectus excavatum, kyphoscoliosis, or intrinsic pulmonary involvement with emphysema. Bronchogenic cysts and “honeycomb lung” that lead to spontaneous pneumothorax must also be kept in mind when using positive pressure ventilation.⁶ Midtracheal obstruction has been reported after Harrington rod placement⁷ and secondary to unexpected tracheomalacia after the induction of general anesthesia.⁸

Patients must be carefully positioned to avoid joint dislocations secondary to joint laxity. Although there is a possibility of temporomandibular joint dysfunction, this has not been reported to cause difficulty with laryngoscopy.⁶

At extubation, care should be taken to avoid sudden increases in blood pressure or heart rate. Adequate postoperative pain management is vitally important to avoid detrimental hypertension and tachycardia.⁶

Ebstein's anomaly includes an abnormal tricuspid valve and “atrialized” right ventricle (Figure 5), that is, the septal leaflets and often the posterior leaflets of the tricuspid valve are displaced into the right ventricle. But the anterior leaflet is usually malformed, excessively large, and abnormally attached or adherent to the right ventricular free wall. Thus, a portion of the right ventricle is “atrialized” in that it is located on the atrial side of the tricuspid valve, and the remaining functional right ventricle is small. Eighty percent of patients with Ebstein's anomaly have an interatrial communication

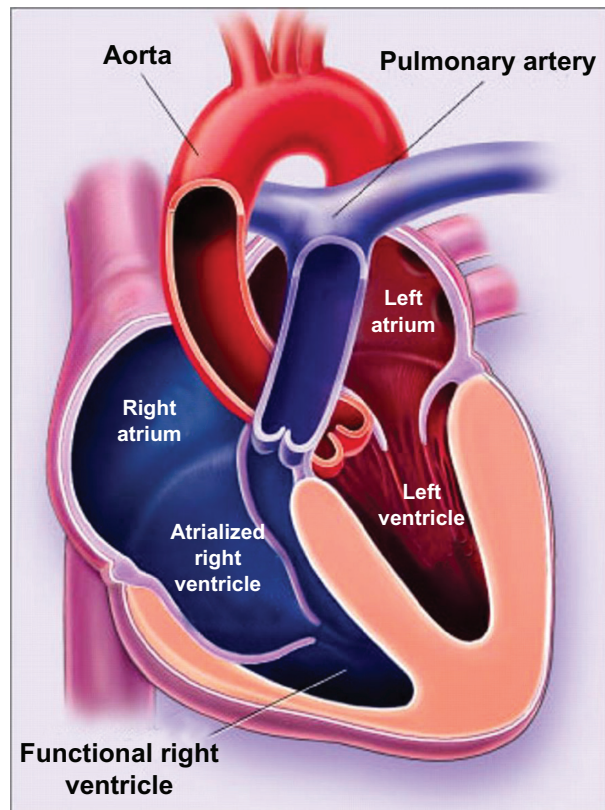


Figure 5 Ebstein's anomaly; a portion of the right ventricle is atrialized and as a result, the functional right ventricle is small. Reproduced with permission from Brickner ME, Hillis LD, Lange RA. Congenital heart disease in adults: second of two parts. *N Engl J Med.* 2000;342:334–342.¹⁰ Copyright © 2000 Massachusetts Medical Society. All rights reserved.

(atrial septal defect or patent foramen ovale) through which right-to-left shunting of blood may occur.^{9,10}

The clinical presentation of Ebstein's anomaly varies greatly. As in our case if the tricuspid valve is minimally displaced, tricuspid regurgitation may actually be mild enough to go unrecognized until adulthood. In fact, the diagnosis may be made by accident with few, if any symptoms. The electrocardiogram will show evidence of right bundle block or right atrial enlargement in over 50% of the cases.¹⁰

Anesthesia on patients with Ebstein's anomaly depends to a large degree on the clinical manifestations. The right ventricular dysfunction which puts these patients especially at a high risk for anesthesia is worsened by the tricuspid regurgitation. Similarly, poor left ventricular function is an especially ominous feature before anesthesia. One must be very observant in Ebstein's anomaly patients during the perioperative period for the occurrence of arrhythmias (especially supraventricular arrhythmias such as Wolff–Parkinson–White syndrome).¹⁰ It is important to review the chronic antiarrhythmic medications that the patient may be receiving.

Prior monitoring and treatment of the case by the cardiology clinic positively affected cardiac performance. Moreover, careful preoperative evaluation, a good preparation, close anesthesia management, and postoperative care prevented fatal complications from developing in the patient.

Conclusion

MFS cases are generally operated on to correct their present orthopedic and cardiac anatomical pathologies. However, we may encounter MFS cases in different emergency forms: in the aneurysm rupture, the cesarean section, and finally in the form of acute abdomen cases which may occur as in our case. MFS cases are generally patients that are under the threat of, first, difficult intubation; second, pneumothorax caused by the presence of pulmonary cysts; third, restrictive pulmonary diseases due to pectus excavatum and scoliosis; and last, cardiac valve diseases and transmission anomalies.

For cases of MFS, the risks of which have been detected through a detailed cardiac examination including echocardiography, we believe that they can be operated as emergency cases with close anesthesia management and after a careful, detailed but quick preparation which should be carried out by taking the risks into consideration.

Consent

Written informed consent was obtained from the patient for the publication of this case report and accompanying images.

A copy of the written consent is available for review by the Editor-in-Chief of this journal.

Disclosure

The author declares conflicts of interest in this work.

References

1. Robinson PN, Godfrey M. The molecular genetics of Marfan syndrome and related microfibrillopathies. *J Med Genet.* 2000;37:9–25.
2. Meijboom LJ, Nolle GJ, Mulder BJM. Prevention of cardiovascular complications in the Marfan syndrome. *Vas Disc Prevent.* 2004;1:79–86.
3. Dean JCS. Management of Marfan syndrome. *Heart.* 2002;88:97–103.
4. Shores J, Berger KR, Murphy EA, Pyeritz RE. Progression of aortic dilatation and the benefit of long-term beta-adrenergic blockade in Marfan's syndrome. *N Engl J Med.* 1994;330:1335–1341.
5. Ades L. Guidelines for the diagnosis and management of Marfan syndrome. *Heart Lung Circ.* 2007;16:28–30.
6. McGoldrick KE. Eye, ear, nose, and throat diseases. In: Fleisher LA, editor. *Anesthesia and Uncommon Disease.* 5th ed. Philadelphia: Saunders Elsevier; 2006:6–7.
7. Mesrobian RB, Epps JL. Midtracheal obstruction after Harrington rod placement in a patient with Marfan's syndrome. *Anesth Analg.* 1986;65:411–413.
8. Oh AY, Kim YH, Kim BK, et al. Unexpected tracheomalacia in Marfan syndrome during general anesthesia for correction of scoliosis. *Anesth Analg.* 2002;95:331–332.
9. Oliver WC, Lynch JJ. Congenital heart disease. In: Fleisher LA, editor. *Anesthesia and Uncommon Disease.* 5th ed. Philadelphia: Saunders Elsevier; 2006:115–118.
10. Brickner ME, Hillis LD, Lange RA. Congenital heart disease in adults: second of two parts. *N Engl J Med.* 2000;342:334–342.

International Journal of General Medicine

Publish your work in this journal

The International Journal of General Medicine is an international, peer-reviewed open-access journal that focuses on general and internal medicine, pathogenesis, epidemiology, diagnosis, monitoring and treatment protocols. The journal is characterized by the rapid reporting of reviews, original research and clinical studies across all disease areas.

Submit your manuscript here: <http://www.dovepress.com/international-journal-of-general-medicine-journal>

Dovepress

A key focus is the elucidation of disease processes and management protocols resulting in improved outcomes for the patient. The manuscript management system is completely online and includes a very quick and fair peer-review system. Visit <http://www.dovepress.com/testimonials.php> to read real quotes from published authors.